

## Amnesia syndrome following left anterior thalamic infarction ; With intrahemispheric and crossed cerebro-cerebellar diaschisis on brain SPECT

Man-Ho Kim, M.D., Seung-Bong Hong, M.D., Jae-Kyu Roh, M.D.

*Department of Neurology, College of Medicine, Seoul  
National University, Seoul, Korea*

*We report a 61-year-old right-handed man developing disturbance of memory after a discrete thalamic infarction. Neuropsychological assessment revealed deficits in memory with retrograde and anterograde components, especially for verbal material. Brain MRI showed a left anterior thalamic infarction with normal angiographic findings. Despite the small lesion in the thalamus, he showed prolonged memory disturbance and a Brain SPECT image revealed decreased uptake in the ipsilateral fronto-temporo-parietal cortex and contralateral cerebellum. This diaschisis, a phenomenon caused by disconnection of the neural pathway helped us to evaluate the functional state of the patient and this imaging technique was valuable for obtaining to get more information for the evaluation of the neurological state and neuronal connections. In conclusion our findings correspond well with the understanding of amnesia as a disconnection syndrome because of the evidence of diaschisis on the Brain SPECT image.*

**Key Words :** *Amnesia, Thalamic infarction, Diaschisis, Brain SPECT, Disconnection syndrome.*

### INTRODUCTION

In left anterior thalamic infarct, language or verbal memory disturbance can follow. Up to now thalamic tumor, hemorrhage(Alexander et al., 1980) and stereotaxic lesion(Riklan and Levita, 1970) have been reported. But in tumor and hemorrhage, mass effect can affect the adjacent structures and in stereotaxic operation, the exact neurological evaluation of the patient was difficult due to underlying disease. Therefore, accurate anatomical-clinical correlation is not possible in these cases. But lacunar infarction can give us more correct, valuable in-

formation about the lesion site and clinical findings because it has less limitation than tumor, hemorrhage, or stereotaxic lesion. So lacunar infarction is a very valuable case for understanding the anatomical-clinical correlation. The thalamic lacune can occasionally show language disturbance(Cohen et al., 1980 ; Mcfarling et al., 1982), verbal memory defect(Akiguchi et al., 1983 ; Speedie and Heilman, 1982 ; Mori et al., 1986), or both(Graff-Radford et al., 1984). But reported cases of these findings have been very rare.

By the way, Brain SPECT imaging technique developed in 1980 shows the lesions in their more functional aspects. And diaschisis, that is the disconnection phenomenon of the neuronal pathway, has been described frequently since then.

Therefore, we describe this rare SPECT finding in an anterior thalamic infarction with the patient's cli-

**Address for correspondence :** *Jae-Kyu Roh, MD., Department of Neurology, Seoul National University Hospital, 28 Yunkeun-dong, Chongno-gu, Seoul, 110-744, Korea. Tel : (02)760-3265, 2278, Fax : (02)744-1785.*

nical and memory test findings.

### CASE SUMMARY

A 61-year-old man, an owner of a company, suddenly developed behavioral changes which were noticed by his wife who met him at Tae-Jun railroad station where they were supposed to meet to visit his father's tomb. He had arrived there on 14th of September, 1991, a day ahead of his wife's arrival and had had an employee prepare some necessities for performing a rite (cherishing the memory of his late father) at his father's tomb. He showed up on time in the morning at the station with an employee who was working in a branch of his company. But he forgot that he had already ordered to prepare the aforementioned necessities and exhibited some strange behavior such as going to a drug store without any specific purpose, choosing the wrong road to get to his hometown or saying inappropriate things repeatedly; he said "where are my wife and relatives?" even though they were beside him or "Where is Mr Taylor? I am supposed to meet him," etc. However he finished the rite at the tomb which was located in his hometown and greeted some old familiar faces on the way to and from the tomb. He slept in the car all the way to the tomb and on the way back to Seoul. According to his wife, he slept and was sleepy almost 20 to 22 hours a day during a couple of days after onset.

The next day (16th of September), at the morning meeting of his company, he made several mistakes to recall past affairs of the company and could not remember the correct names and positions of his employees who were quite well-known to him before. His son who was working with his father at the company and noticed that his father was not normal and some staff in the company also thought that something had happened to their boss and recommended he visit a hospital. Before coming to and at the outpatient clinic of SNUH on 17th of September, he denied having any abnormality and insisted that he was only a little tired. His brain MRI was done on that day which revealed a lacunar-like increased T2 signal in the left anterior thalamic area (Fig. 1) and he was admitted to the ward.

He had been relatively healthy except for a history of peptic ulcer 5 years previously. On physical and neurologic examination, he was quite normal physically and he did not show speech abnormality nor any other speech related higher cortical func-

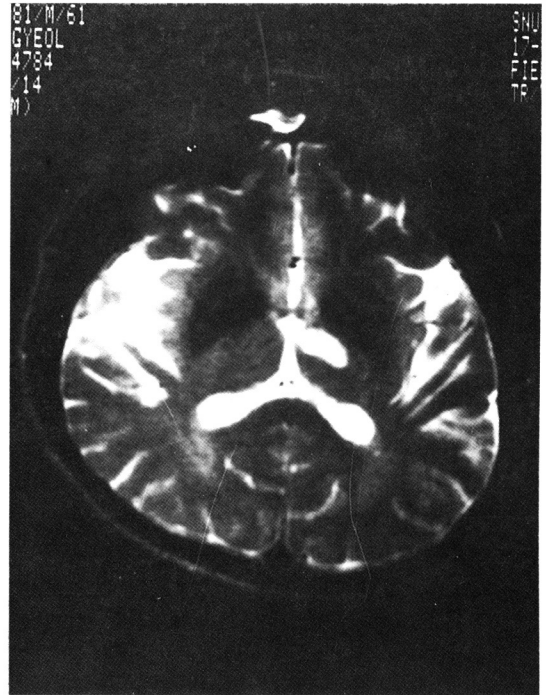


Fig. 1. MRI findings. T2 weighted axial image shows high signal intensity in the left anterior thalamic nucleus suggesting lacunar infarct.

tional anomaly. But he had some degree of patched memory defect during the previous several days. He could not recall three simple words after 3 minute's distraction with serial subtraction method. As he was an intelligent and a very self-confident man he seemed to try to pretend his defective memory was just inattention. But according to his wife and son, he was somewhat disoriented, especially in time and place after awaking from sleep and he could not remember fully some affairs which had happened during the previous several months which he had been able to remember clearly before 15th of September. His hypersomnolence continued for about a week and it was getting better up to discharge on 28th of September. At the outpatient clinic on 18th of Oct., he seemed to be quite normal in ordinary conversation, but he still had some degree of defective verbal memory.

His laboratory findings including CBC, blood chemistry, EKG, chest PA, blood lipid were all within normal range. Echocardiographic examination revealed no cardiac abnormal findings. Brain SPECT

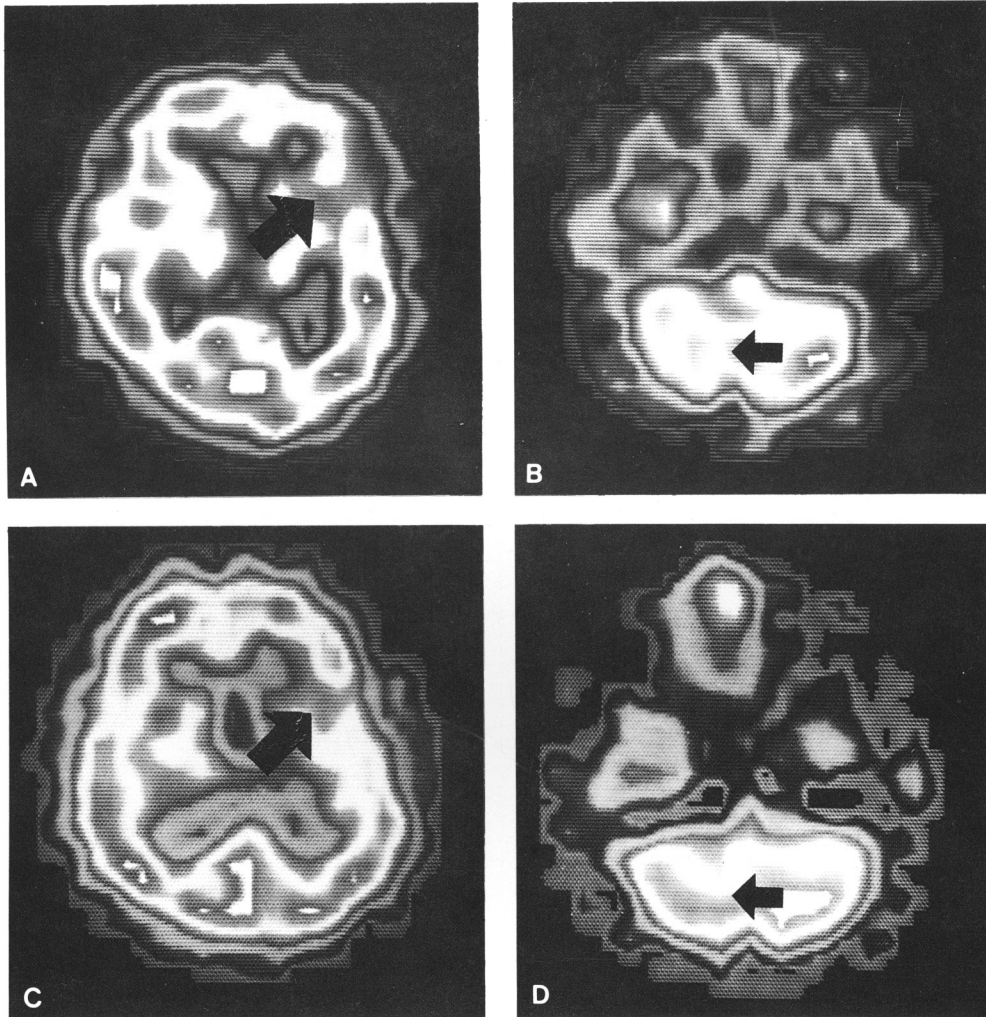


Fig. 2. Initial and follow up brain SPECT image.(A) Decreased uptake in the left fronto-temporo-parietal area and(B) decreased uptake contralateral cerebellum taken six days after onset. (C) and (D) was done seven months later. It shows a little improvement but still the decreased perfusion described above.

using Tc-99m-HMPAO done on 20th of Sep showed decreased perfusion in the left frontoparietal and temporal areas, suspicious decreased perfusion in the left basal ganglia, and slightly decreased perfusion in the right cerebellum(Fig. 2). Although MRI revealed a small lacune in the left anterior thalamus, SPECT image showed large areas of perfusion defect, and so we performed cerebral angiography on 26th of Sep to rule out medium to large vessel disease but that was shown as quite normal.

Mini-mental tests were done on Sep 24th, Oct 10th, and Oct 18th and scored 26, 27, and 28 respectively. Most of the lost score was due to his inability to recall the names of three simple preregistered objects which were thought to represent verbal memory. Wechsler Memory Scale was tested on Sep 24th, Oct 18th, 1991 and Nov 25th, 1992(Table 1). It also showed verbal rather than non-verbal memory defect.

Table 1. Wechsler memory Scale

	9/24/91	10/18/91	11/25/92	Normal value*
1. information	4	3	4	5.7±0.4
2. orientation	5	5	5	6.0±0.0
3. mental control	2	3	9	6.6±1.9
4. logical memory	3.5	6	6	8.1±2.5
5. digit total	12	12	11	10.3±2.2
6. visual reproduction	4	11	7	8.4±3.2
7. associate learning	6.5	7	8.5	13.9±3.1
Total Raw Score	37	47	50.5	58.8±7.1
Age Correction	48	48	48	48
Corrected Score	85	95	98.5	106.8±7.1
Memory Quotient	81	96	101	116 ±14.5

Logical memory and associate learning are verbal memory components and visual reproduction is a non-verbal memory component.

\* : Normal value ; normal mean±standard deviation.

## DISCUSSION

The most characteristic findings in our patient were selective memory disturbance and his Brain SPECT findings. In 1982, Warrington and Weiskrantz insisted that the memory impairment caused by thalamic lesion was a kind of disconnection syndrome between the thalamus and frontotemporal area. Cramon(1985) and Nichelli(1988) supported this finding and suggested that the damage to the mammillothalamic tract and ventral part of the lamina medullaris interna might be involved. But they could not get functional information about these memory related structures. By the way, diaschisis in SPECT that is caused by disconnection of neural pathway has been described and in our patient, diaschisis presented especially in the left frontoparietotemporal region and this strongly suggests that memory defect in left anterior thalamic infarction is a disconnection syndrome interrupting thalamocortical projection.

Bilateral thalamic infarction can affect consciousness level(Castaigne et al., 1981 ; Guberman and Stuss, 1983 ; Graff-Radford et al., 1985). Our patient had only a unilateral, rather than bilateral, lesion but he showed severe somnolence in the acute stage of thalamic infarct. This finding at least is due in part to the disturbance in maintaining alertness. We thought the probable pathomechanism of his somnolence was acute disruption of the ascending reticular activating system at the level of the intralaminar and parafascicular nuclei of the thalamus-(Steriade et al., 1986). His disorientation, just when

he was waking from sleep for one week, especially in time and place was probably related to the disturbance in alertness.

His memory disturbance was more severe in verbal rather than non-verbal type. For example, he forgot what he had ordered or his employees's names and positions and could not recall three simple words in the Mini-mental state examination(Ojemann et al., 1971). But he didn't show any language disturbance. His non-verbal memory seemed to be also partly damaged. Although he could recognize his relatives in his hometown well, he could not remember that his wife was there, even though she was beside him and showed visual reproduction impairment in the initial Wechsler memory test. He also showed retrograde amnesia of recent events. If we had tried a recognition test, we would know whether it was recall processing failure or loss of stored memory. Unfortunately we could not do this at that time.

Watson (1981) reported neglect phenomenon in a right thalamic lesion. Even though this patient had a left side lesion, we could not exclude neglect phenomenon because he denied his abnormal condition although the family said that the patient had high self esteem and intelligence and pretended be normal.

In summary, with a selective lesion in the left anterior thalamus, the patient showed verbal memory impairment and revealed disturbance in arousal and orientation. At the same time, we also observed diaschisis in the frontotemporoparietal area on Brain SPECT. This strongly suggests to us that memory

disturbance in this left anterior thalamic lesion is a kind of disconnection syndrome interrupting the thalamocortical projection and this imaging technique helped us a lot in understanding the patient's problem in its functional aspects.

## REFERENCE

- Akiguchi I, Ito T, Yamao M, et al. *Acute-onset amnesic syndrome due to unilateral paramedian thalamic infarct on the dominant side. Clin Neurol(Tokyo) 1983; 23: 948-55.*
- Alexander MP, LoVerne SR. *Aphasia after left hemispheric intracerebral hemorrhage. Neurology 1980; 30: 1193-202.*
- Castaigne P, Lhermitte F, Buge A, et al. *Paramedian thalamic and midbrain infarcts: Clinical and Neuropathological study. Ann Neurol 1981; 10: 127-48.*
- Cohen JA, Gelfer CE, Sweet RD. *Thalamic infarct producing aphasia. The Mount Sinal J of Med 1980; 47: 398-404.*
- Cramon DY, Hebel N, Schuri U. *A contribution to the anatomical basis of thalamic amnesia. Brain 1985; 108: 993-1008.*
- Graff-Radford NR, Eslinger PJ, Damasio AR, et al. *Nonhemorrhagic infarction of the thalamus: Behavioral, anatomic, and physiologic correlates. Neurology 1984; 34: 14-23.*
- Graff-Radford NR, Schelper RL, Ilinsky IA, et al. *Computed tomographic and postmortem study of a nonhemorrhagic thalamic infarction. Arch Neurol 1985; 42: 761-3.*
- Guberman A, Stuss D. *The syndrome of bilateral paramedian thalamic infarction. Neurology 1983; 33: 540-6.*
- McFarling D, Rothi LJ, Heilman KM. *Transcortical aphasia from ischemic infarcts of the thalamus: a report of two cases. J of Neurol. Neurosurg. and psychiatry 1982; 45: 107-12.*
- Mori E, Yamadori A, Mitani Y. *Left thalamic infarction and disturbance of verbal memory: a clinicoanatomical study with a new method of computed tomographic stereotaxic lesion localization. Ann Neurol 1986; 20: 671-6.*
- Nichelli P, Bahmanian-Behbahani G, Gentilini M, et al. *Preserved memory abilities in thalamic amnesia. Brain 1988; 111: 1337-53.*
- Ojemann GA, Blick KI, Ward AA. *Improvement and disturbance of short-term verbal memory with human ventrolateral thalamic stimulation. Brain 1971; 94: 225-40.*
- Riklan M, Levita E. *Psychological studies of thalamic lesions in humans. The J of Nervous and mental disease 1970; 150: 251-65.*
- Speedie LJ, Heilman KM. *Amnesic disturbance following infarction of the left dorsomedial nucleus of the thalamus. Arch Neurol 1982; 40: 183-6.*
- Steriade M, Domich L, Oakson G. *Reticularis thalami neurons revisited: activity changes during shift in states of vigilance. J. Neurosci 1986; 6: 68-81.*
- Warrington EK, Weiskrantz L. *Amnesia: a disconnection syndrome? Neuropsychologia 1982; 20: 233-48.*
- Watson RT, Valenstein E, Heilman KM. *Thalamic neglect. Possible role of the medial thalamus and nucleus reticularis in behavior. Arch Neurol 1981; 38: 501-6.*