

CASE RECORDS OF THE MASSACHUSETTS GENERAL HOSPITAL



Weekly Clinicopathological Exercises

FOUNDED BY RICHARD C. CABOT

ROBERT E. SCULLY, M.D., *Editor*

EUGENE J. MARK, M.D., *Associate Editor*

WILLIAM F. MCNEELY, M.D., *Associate Editor*

BETTY U. MCNEELY, *Assistant Editor*

CASE 15-1995

PRESENTATION OF CASE

A 70-year-old woman was admitted to the hospital because of obtundation, aphasia, and a right hemiparesis.

She had a five-year history of treated hypertension. Four months before admission a lumpectomy was performed because of breast carcinoma, with normal find-

Table 1. Laboratory Values.*

VARIABLE	VALUE
Hematocrit (%)	33.6
Mean corpuscular volume (μm^3)	87
White-cell count (per mm^3)	15,500
Differential count (%)	
Neutrophils	87
Lymphocytes	10
Monocytes	2
Basophils	1
Platelet count (per mm^3)	4,000
Prothrombin time (sec)	12.5 (control value, 10.3)
Partial-thromboplastin time (sec)	27
Sodium (mmol/liter)	136
Potassium (mmol/liter)	4.1
Chloride (mmol/liter)	103
Carbon dioxide (mmol/liter)	20.4
Magnesium (mmol/liter)	0.6
Uric acid (mg/dl)	7.2
Calcium (mg/dl)	8.2
Glucose (mg/dl)	177
Lactate dehydrogenase (U/liter)	219
Quinidine (mg/liter)	2.6 (normal)

*To convert the value for magnesium to milliequivalents per liter, multiply by 2. To convert the value for uric acid to micromoles per liter, multiply by 59.48. To convert the value for calcium to millimoles per liter, multiply by 0.250. To convert the value for glucose to millimoles per liter, multiply by 0.05551. To convert the value for quinidine to micromoles per liter, multiply by 3.082.

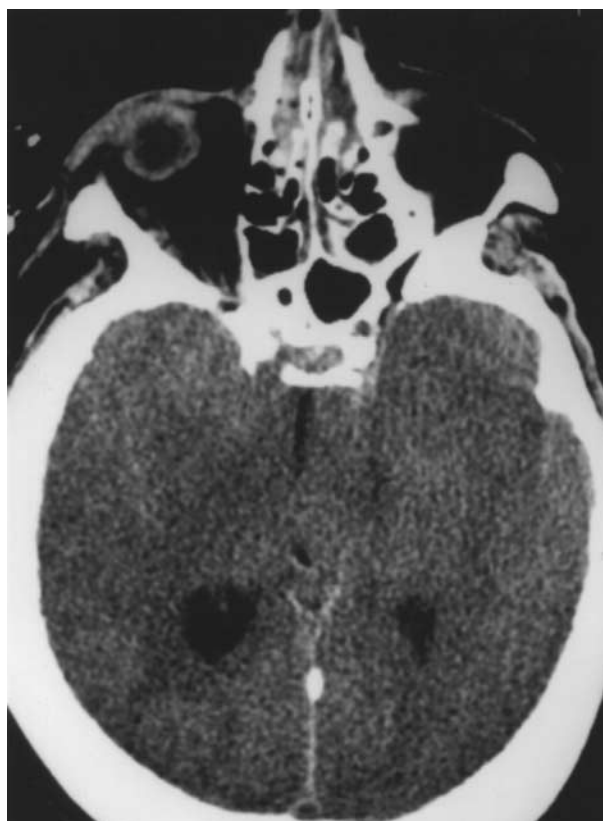


Figure 1. CT Scan of the Head, Obtained without Contrast Material, Demonstrating Diffuse Brain Swelling, with Loss of Gray-White Differentiation and Obliteration of the Ambient Cisterns.

ings on examination of axillary lymph nodes, and radiation therapy was begun. Forty-six days before admission the patient entered another hospital because of the onset of atrial fibrillation, and treatment with warfarin and quinidine was initiated. Four weeks before admission a complete blood count was normal except that the platelet count was 130,000 per cubic millimeter. The patient felt well until one day before admission, when she mentioned to her family that she had bruises around her leg veins. On the day of admission the prothrombin time, determined at another facility, was 17 seconds (international normalized ratio [INR], 2.3). At 4 p.m. the patient was alert and appeared well. One hour later she was found obtunded in a recliner, with blood at the corner of her mouth; no seizure was witnessed. Aroused by her family, she appeared not to understand speech and was unable to move her right extremities. During an ambulance ride rapid obtundation was noted, with stertorous respirations. She was brought to this hospital. In addition to warfarin and quinidine, the patient received metoprolol, ranitidine, and hydrochlorothiazide.

The temperature was 36.8°C, the pulse was 84, and the respirations were 8. The blood pressure was 220/115 mm Hg.

On physical examination the patient was unresponsive, with flaccid extremities. Innumerable, diffuse pe-

techia were present, especially over the abdomen and legs; no ecchymoses, purpuric lesions, or lymphadenopathy was found. Blood was observed in the mouth. The neck was supple, and the lungs were clear. The heart was normal except for an irregular rhythm. The breasts were normal, with healed surgical scars on the left breast and axilla. The abdomen and extremities were normal. On neurologic examination the patient was initially unresponsive except for decerebrate posturing elicited by noxious stimuli applied on either side; no purposeful withdrawal occurred. The pupils were 3 mm and constricted to 2 mm in response to bright light; the doll's-head maneuver and the corneal reflexes were intact. The ankle jerks were + + + +, with bilateral clonus; plantar stimulation evoked no response.

The urine was normal except that the sediment contained 4 white cells and 75 red cells per high-power field. The values for urea nitrogen, creatinine, bilirubin, phosphorus, protein, albumin, globulin, aspartate aminotransferase, creatine kinase, amylase, and alkaline phosphatase were normal. The other laboratory values are shown in Table 1. A screening test for drugs of abuse was negative. An electrocardiogram showed a normal rhythm at a rate of 88, with partial right-bundle-branch block. A computed tomographic (CT) scan of the cranium (Fig. 1, 2, and 3) revealed an intraparenchymal hemorrhage of the left frontal lobe meas-

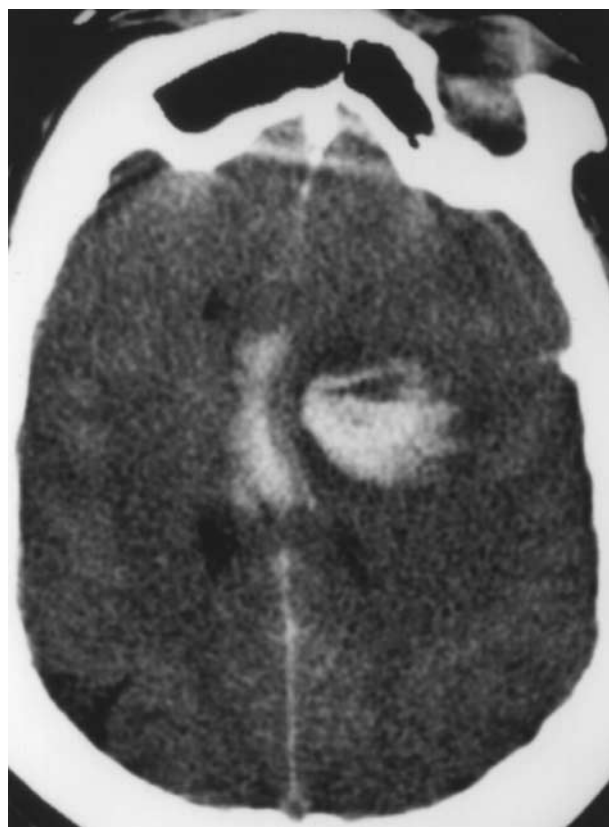


Figure 2. CT Scan of the Head, Obtained without Contrast Material, Showing Left Frontal Hemorrhage and Blood in the Body of the Corpus Callosum or Callosal Cistern or Both.

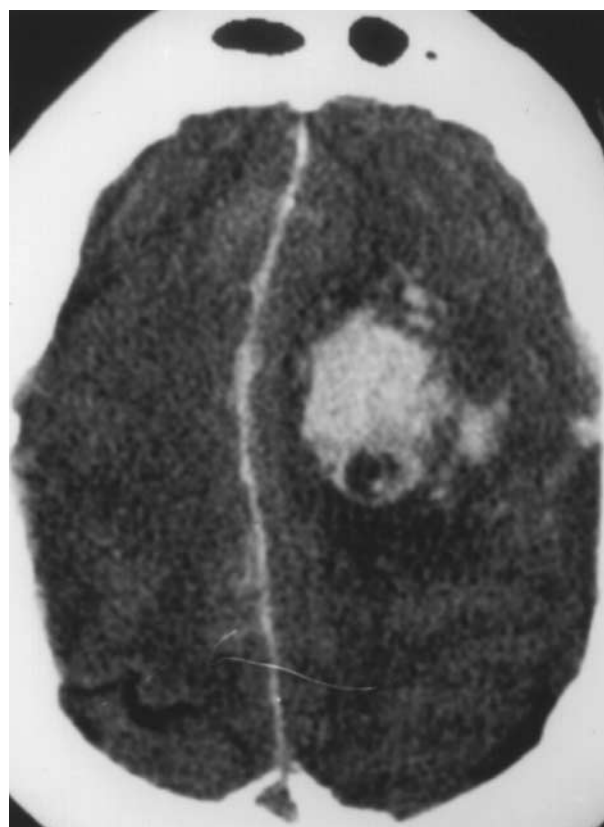


Figure 3. CT Scan of the Head, Obtained without Contrast Material, Revealing a Left Frontal Hematoma, Subarachnoid Hemorrhage, and Blood along the Falx.

uring 5 by 5 by 4 cm, intraventricular and subarachnoid blood, and hemorrhage within the corpus callosum or callosal cistern or both; generalized cerebral edema was present, and there was left-to-right subfalcial and descending transtentorial herniation, with effacement of the basilar cistern and compression of the brain stem.

An emergency nasotracheal intubation was performed with considerable difficulty, and mechanical ventilation was initiated. Phenytoin sodium, ceftriaxone, and dexamethasone were injected intravenously, and an infusion of mannitol was begun. During the next 2½ hours the patient's pupils became dilated and fixed at 8 mm; the corneal reflexes disappeared, and there was no response to the doll's-head maneuver or to cold caloric stimulation. Spontaneous decerebrate posturing appeared bilaterally. The blood pressure fell to 80/40 mm Hg; normal saline was administered intravenously, and 6 units of platelets were transfused.

A diagnostic procedure was performed.

DIFFERENTIAL DIAGNOSIS

DR. DOUGLAS B. CINES*: I shall begin by considering whether this patient's intracerebral hemorrhage

*Director, Hematology and Coagulation Laboratories, Hospital of the University of Pennsylvania; associate professor, Department of Pathology and Laboratory Medicine, University of Pennsylvania School of Medicine.

is attributable exclusively to the severe thrombocytopenia.

May we review the radiologic findings?

DR. PAMELA W. SCHAEFER: Images from the CT scan of the head (Fig. 1, 2, and 3), obtained without contrast material, show a large left frontal intraparenchymal hemorrhage, a left temporal-tip hemorrhage, diffuse subarachnoid hemorrhage, and hemorrhage in the body of the corpus callosum or the callosal cistern or both. There is diffuse cerebral edema, with downward transtentorial herniation and left-to-right subfalcine herniation.

DR. CINES: The features of the hemorrhage shown on the CT scan may provide clues to its cause. First, its epicenter is deep in the subcortical area. Blood had diffused widely to the cortical surface, subarachnoid space, and contralateral cortex. Second, the hemorrhage appeared to be nonhomogeneous, with multiple low-density areas within and surrounding it. Third, profound edema and a mass effect that was disproportionate to the size of the hemorrhage were evident. Edema had compressed the midbrain structures, accounting for several of the presenting neurologic features.

The most common conditions associated with intracerebral hemorrhage are listed in Table 2¹; several of them may have been contributing factors in this case.

The patient had a history of presumably mild hypertension controlled with hydrochlorothiazide. Hypertension is the most common cause of intracerebral hemorrhage, although its frequency may be decreasing as a consequence of improved surveillance and management. Typical sites of hypertensive bleeding include the basal ganglia, thalamus, cerebellum, and pons, but there can be a lobar distribution. Impaired vascular integrity due to chronic hypertension may have resulted in a predisposition to intracerebral hemorrhage in this patient. The severe hypertension and widened pulse pressure observed on admission were probably the result of increased intracranial pressure and were poor prognostic signs.

The second diagnosis to be considered is cerebral amyloid angiopathy. Amyloid deposition is found in the cerebral vessels in approximately 10 percent of patients with intracerebral hemorrhage at the age of 70 years.² Hemorrhage may occur without clinical evidence of Alzheimer's disease. The predisposition to bleeding has been attributed to the deposition of β -amyloid in the vessel wall, which disrupts its structural integrity. More recently, the amyloid precursor protein has been shown to inhibit several serine proteases, including coagulation factors XIa and IXa.^{3,4} Although there are no clues pointing to a diagnosis of cerebral amyloid angiopathy, a magnetic resonance imaging (MRI) study that revealed multiple deposits of hemosiderin, suggesting previous bleeding episodes, would have made this diagnosis more likely.

The third possibility, bleeding from an arterial aneurysm or an arteriovenous malformation, would have been a prominent consideration if the hemorrhage had occurred before the age of 40 years. Bleeding from

Table 2. Causes of Spontaneous Intracerebral Hemorrhage.

CAUSE	PERCENTAGE OF CASES
Hypertension	50–60
Cerebral amyloid angiopathy	10–20
Vascular malformations	5
Brain tumors	5–10
Hemorrhagic infarcts	10
Arterial — thrombotic or embolic	
atrial fibrillation	
Venous	
Miscellaneous	<5
Vasculitis or vasculopathy	
Sympathomimetic agents (e.g., amphetamines and cocaine)	
Other	
Anticoagulant and fibrinolytic agents	10

these lesions can occur in older persons, however, and neither diagnosis can be ruled out on the basis of a CT scan obtained without contrast material. Bleeding occurs most commonly in the area of the circle of Willis and the surrounding subarachnoid space. The subcortical distribution of the hemorrhage in this case is evidence against an aneurysm or arteriovenous malformation as the source of the bleeding, but an MRI study or an angiographic examination would have been necessary to exclude these possibilities.

Hemorrhage can be the first clinical manifestation of a primary or metastatic brain tumor, which is the fourth diagnosis to be considered.⁵ Highly vascular tumors, such as glioblastomas and metastatic germ-cell tumors, are most likely to bleed, but other tumors, including metastatic breast cancer, can present this way as well.⁶ A tumor should be suspected when the hemorrhage is nonhomogeneous and multifocal and extensive edema is evident on a CT scan — all features seen in this case. Indeed, four months earlier the patient had been treated for localized breast cancer. However, we have no details of the preoperative metastatic workup, the histologic type of the tumor, or the adequacy of the lymph-node dissection. We also do not know whether inspection of a peripheral-blood smear suggested a myelophthitic process. Nevertheless, metastatic breast cancer is improbable, because extensive intracerebral hemorrhage four months after the initial diagnosis and treatment of node-negative breast cancer is rare.⁷ A CT scan performed with contrast material or an MRI scan, however, would have been necessary to rule out an underlying primary or metastatic tumor.

The recent development of atrial fibrillation raises the question of whether the patient had a hemorrhagic infarct caused by cerebral embolism, the fifth possibility. Without anticoagulant therapy, symptomatic infarcts occur by the eighth decade of life in approximately 10 percent of patients with nonvalvular atrial fibrillation — a rate fivefold higher than that among age-matched controls⁸ — and the rate may be even higher among patients with concurrent hypertension or heart failure or previous thromboembolism.⁹ Atrial fi-

brillation is a predisposing factor in up to 15 percent of patients who have a stroke by the age of 70 years.^{10,11} The risk of hemorrhage into an infarct is correlated with its size but is not substantially increased by heparin or warfarin therapy.^{11,12} In this patient, however, the location of the epicenter of the hemorrhage between the areas served by the middle and anterior cerebral arteries is evidence against hemorrhagic infarction of embolic origin.

Several other causes of intracerebral hemorrhage should be mentioned. Bleeding into a venous infarct cannot be ruled out, but there were no predisposing factors, such as disseminated intravascular coagulation, and dilated vessels were not seen on the CT scan. The rapidity of the neurologic deterioration, the involvement of the midbrain function, and the extensive hemorrhage make central nervous system vasculitis improbable. That the patient was presumably taking the β -adrenergic antagonist metoprolol and had a negative screening test for drugs essentially rules out drug-induced vascular injury by a sympathomimetic agent as a predisposing factor.

Therefore, the coagulopathy is the greatest risk factor for the intracranial hemorrhage in this case. I shall now consider both the risk of intracerebral hemorrhage associated with the use of warfarin and the risk in a patient with severe thrombocytopenia.

Warfarin reduces the annual risk of cerebral infarction in patients with nonrheumatic atrial fibrillation from approximately 4 to 6 percent to 1 to 2 percent,¹³⁻¹⁵ but this beneficial effect is partially offset by an increase in the frequency of intracranial hemorrhage of approximately 0.3 percent per year (Table 3).¹⁶ The actual risk may be somewhat higher, since most of the otherwise eligible patients were excluded from these studies because they were thought to be at greater risk for bleeding.¹⁷ Indeed, the actual frequency of intracerebral hemorrhage is 5 to 10 times higher in patients taking warfarin than in age-matched controls.¹⁸⁻²⁰ The

risk is highest during the first year of therapy, when a stable therapeutic regimen has often not yet been established,^{11,20,21} perhaps because preexisting sites of disease are revealed.²² Although the importance of advanced age and hypertension is uncertain,^{18,19,21,23} the intensity of the anticoagulation regimen is the most important risk factor for intracerebral hemorrhage. In most patients anticoagulation is excessive when hemorrhage occurs.^{11,19-21,23-25} The risk of hemorrhage may be increased when drugs that impair the metabolism of warfarin, such as quinidine, are introduced.²⁶ Because of the warfarin, this patient's hemostasis was more dependent on platelet function than it would otherwise have been, although her prothrombin time was within the intended range when the bleeding occurred. The presentation with innumerable petechiae points to an inadequacy in the number or function of platelets rather than overanticoagulation with warfarin as the major risk factor for bleeding.

I conclude that the development of severe thrombocytopenia precipitated the intracerebral hemorrhage in this patient with multiple potential preexisting risk factors. Indeed, the platelet count of 4000 per cubic millimeter, by itself, is sufficient to explain all the manifestations of bleeding. It is difficult to quantify the risk of intracerebral hemorrhage, because profound thrombocytopenia occurs episodically in most conditions, treatment is generally instituted immediately, and concurrent disorders that predispose patients to bleeding are often present, as in this case. The best estimates come from studies of patients with aplastic anemia and acute leukemia, in whom the frequency of spontaneous mucosal, generally gastrointestinal, bleeding increases exponentially as the platelet count falls below 5000 per cubic millimeter.^{27,28} Although this estimate applies only to patients with hypoproliferative thrombocytopenic disorders or patients in whom local factors such as leukemic infiltrates contribute to the bleeding, spontaneous intracerebral hemorrhage also occurs in patients with diverse forms of immune thrombocytopenia, including seemingly healthy children and young adults without evidence of underlying central nervous system disease.²⁹⁻³¹ There are few descriptions of the anatomical or pathophysiologic bases of bleeding associated with coagulopathy. The occurrence of intracerebral hemorrhage in association with severe thrombocytopenia, congenital or acquired deficiencies or acquired inhibitors of coagulation proteins, use of warfarin or heparin, and previous use of fibrinolytic therapy in the absence of known risk factors³² leads to the conclusion that hemostatic stresses within the brain parenchyma are common and that auxiliary mechanisms are often insufficient to prevent or contain bleeding.

Why did severe thrombocytopenia develop in this patient? I shall base my discussion on two assumptions and one fact. The first assumption is that examination of the peripheral-blood smear confirmed the profound reduction in platelets and showed no platelet clumps, ruling out pseudothrombocytopenia. The second as-

Table 3. Frequency of Intracerebral Hemorrhage in Patients with Atrial Fibrillation Treated with Warfarin.*

STUDY	PERSON-YEARS OF TREATMENT	PROTHROMBIN TIME	REDUCTION IN INFARCTION	INTRACEREBRAL HEMORRHAGE	
				WARFARIN	PLACEBO
		INR	%	no. of events/100 person-years (%)	
AFASAK	412	2.8–4.2	58	1 (0.4)	0
SPAF I	260	2.0–3.5	67–82	1 (0.4)	1 (0.4)
BAATAF	487	1.5–2.7	86	1 (0.2)	0
CAFA	237	2.0–3.0	45	1 (0.4)	0
SPINAF	442	1.4–2.8	79	1 (0.25)	0
SPAF II	1110	2.0–4.5	67	2 (0.5)†	—‡

*Data are from six clinical studies¹⁶: the Atrial Fibrillation, Aspirin, Anticoagulation (AFASAK) study in Copenhagen, Denmark; the Stroke Prevention in Atrial Fibrillation (SPAF I and SPAF II) studies; the Boston Area Anticoagulation Trial in Atrial Fibrillation (BAATAF); the Canadian Atrial Fibrillation Anticoagulation (CAFA) study; and the Veterans Affairs Stroke Prevention in Nonrheumatic Atrial Fibrillation (SPINAF) study. INR denotes international normalized ratio.

†Among patients <75 years old (frequency of hemorrhage in patients >75 years, 1.8 percent).

‡Patients received aspirin rather than placebo (frequency of hemorrhage, 0.2 percent).

sumption is that the platelet count was normal before warfarin therapy was started. There is documentation of mild thrombocytopenia four weeks before admission and a dramatic decrease in platelets on admission. On that basis I shall limit my differential diagnosis to the causes of acquired severe thrombocytopenia (platelet count, <20,000 per cubic millimeter) (Table 4).

When considering each disorder, we should ask not only whether the hematologic data support the diagnosis but also whether the disorder, by itself, could account for the neurologic presentation. For example, neurologic dysfunction is common in thrombotic thrombocytopenic purpura but rare in the hemolytic-uremic syndrome. Massive intracranial hemorrhage would not be expected with either disorder, however, and the absence of fever, hemolysis, renal insufficiency, and a marked elevation of the serum lactate dehydrogenase level makes these diagnoses untenable.

Disseminated microvascular thrombi and intracerebral hemorrhage may occur with acute disseminated intravascular coagulation. However, there was no predisposing cause, such as sepsis, which should have been obvious by the time thrombocytopenia of this severity developed, and one would not expect to find a normal partial-thromboplastin time. The diagnosis could have been ruled out quickly by documenting a normal level of fibrinogen or fibrin-split products.

Arterial or venous infarction and thrombocytopenia develop in some patients with paroxysmal nocturnal hemoglobinuria, but this disorder is rare, massive subcortical hemorrhage would not be expected, and there are no data to suggest hemolysis. A malignant hematologic disorder such as leukemia could result in central nervous system bleeding, but profound abnormalities in other cell lines would have been expected by the time the platelet count had fallen to 4000 per cubic millimeter, and the diagnosis would have been evident on inspection of the peripheral-blood smear.

Several other causes of thrombocytopenia can be considered mainly for the sake of completeness. The absence of profound abnormalities in other cell lines is strong evidence against aplastic anemia, marrow infarction, or a megaloblastic or an infiltrative process. Hypersplenism would not have resulted in the rapid development of thrombocytopenia severe enough to cause intracerebral hemorrhage, and splenomegaly was not detected on physical examination. However, a bone marrow examination would have been required to rule out the rare amegakaryocytic thrombocytopenia caused by drugs (including alcohol and thiazides), myelodysplasia, or an autoimmune process.

I am thus led to conclude that antibody-mediated, immune thrombocytopenia was the most likely cause of the rapid development of severe thrombocytopenia in this patient. Among the possible causes, post-transfusion purpura can be ruled out because of the absence of blood transfusion in the preceding one to two weeks. Autoimmune thrombocytopenia cannot be ruled out, especially since mild thrombocytopenia was docu-

Table 4. Causes of Acquired Severe Thrombocytopenia.

Impaired production of platelets
Sepsis*
Hematologic cancers (e.g., leukemia* or myelodysplasia)
Disorders associated with infiltration or fibrosis of bone marrow
Aplastic anemia
Amegakaryocytic thrombocytopenia (related to drugs, myelodysplasia, or an immune process)
Marrow infarction
Paroxysmal nocturnal hemoglobinuria*
Loss or destruction of platelets
Disseminated intravascular coagulation or sepsis*
Thrombotic thrombocytopenic purpura† or the hemolytic-uremic syndrome
Hypersplenism
Cardiopulmonary bypass*
Massive hemorrhage* with inadequate replacement
Immune-mediated thrombocytopenia
Post-transfusion purpura
Autoimmune
Primary (idiopathic thrombocytopenic purpura)
Chronic lymphocytic leukemia
Systemic lupus erythematosus*
Antiphospholipid-antibody syndrome*
Drug-induced

*Central nervous system dysfunction may accompany thrombocytopenia.

†Central nervous system dysfunction is common.

mented several weeks before admission, although it would be unusual for this disorder to present in a 70-year-old patient in the absence of an underlying condition such as chronic lymphocytic leukemia. Autoimmune thrombocytopenia and catastrophic neurologic events may occur coincidentally in patients with systemic lupus erythematosus or the antiphospholipid syndrome. Although I cannot rule out either diagnosis without information from additional tests, we are given no history or physical findings to suggest an autoimmune vasculitis, there was no evidence of systemic emboli, and massive intracerebral hemorrhage would be a rare presentation.

It is far more likely that the thrombocytopenia was caused by a drug-dependent, platelet-reactive antibody, but determining which drug was responsible can be problematic in the acute care setting. Each of the drugs that the patient was taking (quinidine, ranitidine, hydrochlorothiazide, and metoprolol) has been implicated as a cause of thrombocytopenia.^{33,34} None can be ruled out with certainty in the absence of either specific in vitro testing, which may be time consuming and is often uninformative, or selective drug withdrawal and rechallenge, which may be ill advised if the thrombocytopenia is profound and alternative approaches are readily available.

Nevertheless, I favor the diagnosis of quinidine-induced thrombocytopenia in this case for three reasons. First, quinidine is one of the most common causes of drug-induced thrombocytopenia, occurring in approximately 1 patient per 1000 at risk.^{34,35} Second, the median duration of drug use at the time of the recognition of thrombocytopenia is 45 days,³⁴ which is very

close to the interval in this case. Third, patients with quinidine-induced thrombocytopenia, like this patient, typically present with platelet counts of less than 10,000 per cubic millimeter and diffuse petechiae and purpura, occasionally with intracranial hemorrhage.

Several atypical presentations of this disorder, which are not illustrated by this case, should be mentioned. Thrombocytopenia may be detected for the first time after intermittent drug use for several years. In that setting systemic manifestations such as fever, vomiting, and respiratory distress may also occur within a few hours after the drug use has been resumed.³⁶ Drug use may also be surreptitious or unintended.³⁷ Occasionally, patients present with leukopenia, hemolytic anemia, or a "lupus-like" syndrome.³³ Finally, the hemolytic-uremic syndrome, disseminated intravascular coagulation, or anaphylaxis has developed in a few patients after ingestion of the stereoisomer quinine.^{33,38-41}

The pathogenesis of thrombocytopenia involves several steps. First, a stable ternary complex forms between the Fab' end of the antibody molecule and an epitope that requires the presence of both the drug and one of several platelet glycoproteins.⁴²⁻⁴⁵ Quinidine-dependent antibodies are heterogeneous with respect to the structural requirements for the glycoprotein involved and the drug necessary for antibody binding. Most of these antibodies recognize determinants in the platelet glycoprotein IIb/IIIa or Ib/IX complex, or both, presumably because these glycoproteins are the most prevalent on the platelet surface, and therefore their involvement is most likely to produce clinically important disease. Antibodies to other platelet proteins, however, have been detected in some patients, as have concurrent drug-dependent and drug-independent antibodies.⁴⁶ Some of the antibodies react only with quinidine or to a variable extent with the dihydro or desmethoxy quinidine derivatives, or both; others show substantial cross-reactivity with the stereoisomer quinine or additional analogues at the C(9) position of the quinoline ring.^{47,48}

Once quinidine-dependent antibodies bind to the platelet-drug complex at the Fab' end of the molecule, the Fc portion becomes available either to bind to other platelet or leukocyte Fc receptors or to activate the complement system. Although the extent to which complement activation causes intravascular platelet lysis *in vivo* has not been established, the capacity of quinidine-dependent antibodies to fix complement *in vitro* can be exploited to make a rapid diagnosis in many cases. Plasma from the patient is mixed with an approximately equal volume of platelet-rich plasma from a normal donor. Set amounts of a soluble quinidine salt are added to this mixture. The complement system becomes activated, leading to lysis of the donor platelets within half an hour, which is often evident visually. Alternatively, lysis can be quantified by prelabeling the donor platelets with a radioactive tracer such as chromium-51 or [¹⁴C]serotonin. I suspect that such a test was used to

make a presumptive diagnosis of quinidine-associated thrombocytopenia in this case. I wish to emphasize, however, that although quinidine-dependent platelet-reactive antibodies can be detected in many patients on presentation, in some patients the antibodies appear to be consumed during the acute phase and can be detected only at a later time.^{46,49} The absence of demonstrable drug-dependent antibodies should therefore not be used as a rationale for continuing the drug if the clinical presentation is otherwise typical for quinidine-induced thrombocytopenia.

In conclusion, I believe that quinidine-induced purpura was the cause of the patient's thrombocytopenia and was the main predisposing reason for hemorrhage. I cannot rule out an underlying anatomical cause without the results of multiple radiologic examinations.

DR. WILLIAM S. BECK: I agree with your diagnosis. We tend not to think of quinidine-induced thrombocytopenia as often as we should. Quinidine, or quinine, is assimilated by persons who are not taking pills — for example, those who have "cocktail purpura."⁵⁰ Quinine water, or tonic, contains about 8 ml of quinine per 100 ml, and a number of patients have had thrombocytopenia after drinking gin and tonic. Some aperitifs also contain quinine.⁵¹ So a careful history taking is necessary to rule out this disorder.

CLINICAL DIAGNOSIS

Quinidine-induced thrombocytopenia.

DR. DOUGLAS CINES'S DIAGNOSIS

Quinidine-induced thrombocytopenia, with extensive intracerebral hemorrhage.

PATHOLOGICAL DISCUSSION

DR. DAVID H. MARGOLIN: When the patient entered the hospital we suspected that she had had a cerebral hemorrhage, but we did not yet know the platelet count and favored a warfarin-related hemorrhage. The extensive petechiae were atypical of such a hemorrhage, however, and suggested a platelet disorder. Once we knew the platelet count, we suspected that thrombocytopenia was the main contributor to the spontaneous intracerebral hemorrhage. Surgical intervention was not recommended because of a rapid, irreversible decline in neurologic function, with brain death. An autopsy was performed.

DR. MICHAEL LAPOSATA: The diagnostic procedure was indeed a serologic assay for quinidine-dependent antiplatelet antibodies, which was positive.

The autopsy revealed a massive intracerebral hemorrhage and bleeding in multiple sites, which provided strong evidence of a coagulopathy that caused the intracerebral hemorrhage. The next task was to determine whether the coagulopathy was due to a defect in the platelets or the coagulation factors or both.

As noted, the diagnosis of quinidine-induced thrombocytopenia was strongly supported by the rapid fall in

the platelet count, which can decrease from a normal value to below 20,000 per cubic millimeter within two weeks after the initiation of quinidine therapy.⁵² The serologic test for the detection of quinidine-dependent antiplatelet antibodies that is based on the lysis of platelets could not be performed, because quinidine was present in the plasma sample available for analysis. Therefore, an immunofluorescence assay was performed. Four samples of normal platelets were used as target cells for antibody detection. The patient's plasma was found to have an IgG-reactive antibody to platelets. To prove that the antibody was reactive to the quinidine-platelet glycoprotein complex, aliquots of the plasma sample were supplemented with increasing amounts of quinidine, resulting in a marked enhancement of antibody reactivity to platelets. No such enhancement was observed when the patient's plasma was supplemented with metoprolol, which was used as a control. The results of this assay indicated the presence of an antiplatelet antibody induced by quinidine. An additional test with the plasma sample showed an antibody reactive with the platelet glycoprotein Ib/IX complex in the presence of quinidine, substantiating the presence of quinidine-dependent antiplatelet antibodies in the plasma.

Although the platelet defect was the main contributor to the patient's coagulopathy, it was also necessary to determine whether a coagulation-factor defect had at least a partial role in the bleeding. The INR for the prothrombin time, now commonly used to indicate the extent of anticoagulation with warfarin, was 2.3 in this patient. The standard therapeutic INR range for anticoagulation with warfarin is 2.0 to 3.0; an acceptable higher range for more intense anticoagulation is 3.0 to 4.5. Thus, there was no evidence to support an overdose of warfarin as a cause of the bleeding. However, in the presence of profound thrombocytopenia, the decrease in factors II, VII, IX, and X produced by the ingestion of warfarin probably increased the severity of the bleeding.

PATHOLOGICAL DIAGNOSES

Quinidine-induced thrombocytopenia.
Cerebral hemorrhage.

REFERENCES

- Grossman RI, Yousem DM. Vascular diseases of the brain. In: Grossman RI, Yousem DM, eds. *Neuroradiology: the requisites*. St. Louis: Mosby-Year Book, 1994:105-47.
- Gilbert JJ, Vinters HV. Cerebral amyloid angiopathy: incidence and complications in the aging brain. I. Cerebral hemorrhage. *Stroke* 1983;14:915-23.
- Smith RP, Higuchi DA, Broze GJ Jr. Platelet coagulation factor XIa-inhibitor, a form of Alzheimer amyloid precursor protein. *Science* 1990;248:1126-8.
- Schmaier AH, Dahl LD, Rozemuller AJM, et al. Protease nexin-2/amyloid beta protein precursor: a tight-binding inhibitor of coagulation factor IXa. *J Clin Invest* 1993;92:2540-5.
- Wakai S, Yamakawa K, Manaka S, Takakura K. Spontaneous intracranial hemorrhage caused by brain tumor; its incidence and clinical significance. *Neurosurgery* 1982;10:437-44.
- Graus F, Rogers LR, Posner JB. Cerebrovascular complications in patients with cancer. *Medicine* 1985;64:16-35.
- Early Breast Cancer Trialists' Collaborative Group. Systemic treatment of early breast cancer by hormonal, cytotoxic, or immune therapy: 133 randomized trials involving 31,000 recurrences and 24,000 deaths among 75,000 women. *Lancet* 1992;339:1-15.
- Wolf PA, Dawber TR, Thomas HE Jr, Kannel WB. Epidemiologic assessment of chronic atrial fibrillation and risk of stroke: the Framingham Study. *Neurology* 1978;28:973-7.
- The Stroke Prevention in Atrial Fibrillation Investigators. Predictors of thromboembolism in atrial fibrillation. I. Clinical features of patients at risk. *Ann Intern Med* 1992;116:1-5.
- Wolf PA, Abbott RD, Kannel WB. Atrial fibrillation as an independent risk factor for stroke: the Framingham Study. *Stroke* 1991;22:983-8.
- Radberg JA, Olsson JE, Radberg CT. Prognostic parameters in spontaneous intracerebral hematomas with special reference to anticoagulant treatment. *Stroke* 1991;22:571-6.
- Cerebral Embolism Study Group. Immediate anticoagulation of embolic stroke: a randomized trial. *Stroke* 1983;14:668-76.
- Matchar DB, McCrory DC, Barnett HJM, Feussner JR. Medical treatment for stroke prevention. *Ann Intern Med* 1994;121:41-53. [Erratum, *Ann Intern Med* 1994;121:470.]
- Ezekowitz MD, Bridgers SL, James KE, et al. Warfarin in the prevention of stroke associated with nonrheumatic atrial fibrillation. *N Engl J Med* 1992;327:1406-12.
- Stroke Prevention in Atrial Fibrillation Investigators. Warfarin versus aspirin for prevention of thromboembolism in atrial fibrillation: Stroke Prevention in Atrial Fibrillation II Study. *Lancet* 1994;343:687-91.
- Atrial Fibrillation Investigators. Risk factors for stroke and efficacy of anti-thrombotic therapy in atrial fibrillation: analysis of pooled data from five randomized controlled trials. *Arch Intern Med* 1994;154:1449-57. [Erratum, *Arch Intern Med* 1994;154:2254.]
- White HD. Aspirin or warfarin for non-rheumatic atrial fibrillation? *Lancet* 1994;343:683-4.
- Whisnant JP, Cartledge NEF, Elveback LR. Carotid and vertebral-basilar transient ischemic attacks: effect of anticoagulants, hypertension, and cardiac disorders on survival and stroke occurrence — a population study. *Ann Neurol* 1978;3:107-15.
- Wintzen AR, de Jonge H, Loeliger EA, Bots GTAM. The risk of intracerebral hemorrhage during oral anticoagulant treatment: a population study. *Ann Neurol* 1984;16:553-8.
- Franke CL, de Jonge J, van Swieten JC, Op de Coul AAW, van Gijn J. Intracerebral hematomas during anticoagulant treatment. *Stroke* 1990;21:726-30.
- Landefeld CS, Goldman L. Major bleeding in outpatients treated with warfarin: incidence and prediction by factors known at the start of outpatient therapy. *Am J Med* 1989;87:144-52.
- Landefeld CS, Rosenblatt MW, Goldman L. Bleeding in outpatients treated with warfarin: relation to the prothrombin time and important remediable lesions. *Am J Med* 1989;87:153-9.
- Fihn SD, McDonnell M, Martin D, et al. Risk factors for complications of chronic anticoagulation: a multicenter study. *Ann Intern Med* 1993;118:511-20.
- Kase CS, Robinson RK, Stein RW, et al. Anticoagulant-related intracerebral hemorrhage. *Neurology* 1985;35:943-8.
- Hylek EM, Singer DE. Risk factors for intracranial hemorrhage in outpatients taking warfarin. *Ann Intern Med* 1994;120:897-902.
- Koch-Weser J, Sellers EM. Drug interactions with coumarin anticoagulants. *N Engl J Med* 1971;285:547-58.
- Slichter SJ. Controversies in platelet transfusion therapy. *Annu Rev Med* 1980;31:509-40.
- Gaydos LA, Freireich EJ, Mantel N. The quantitative relation between platelet count and hemorrhage in patients with acute leukemia. *N Engl J Med* 1962;266:905-9.
- Woerner SJ, Abildgaard CF, French BN. Intracranial hemorrhage in children with idiopathic thrombocytopenic purpura. *Pediatrics* 1981;67:453-60.
- Schattner E, Bussel J. Mortality in immune thrombocytopenic purpura: report of seven cases and consideration of prognostic indicators. *Am J Hematol* 1994;46:120-6.
- Mueller-Eckhardt C. Post-transfusion purpura. *Br J Haematol* 1986;64:419-24.
- Simoons ML, Maggioni AP, Knatterud G, et al. Individual risk assessment for intracranial haemorrhage during thrombolytic therapy. *Lancet* 1993;342:1523-8.
- McCrae KR, Cines DB. Drug-induced thrombocytopenias. In: Loscalzo J, Schafer AI, eds. *Thrombosis and hemorrhage*. Cambridge, Mass.: Blackwell Science, 1994:545-73.
- Kaufman DW, Kelly JP, Johannes CB, et al. Acute thrombocytopenic purpura in relation to the use of drugs. *Blood* 1993;82:2714-8.
- Danielson DA, Douglas SW III, Herzog P, Jick H, Porter JB. Drug-induced blood disorders. *JAMA* 1984;252:3257-60.

36. Bishop RC, Spencer HH, Bethell FH. Quinidine purpura: report of six cases. *Ann Intern Med* 1959;50:1227-40.
37. Reid DM, Shulman NR. Drug purpura due to surreptitious quinidine intake. *Ann Intern Med* 1988;108:206-8.
38. Gottschall JL, Elliot W, Lianos E, McFarland JG, Wolfmeyer K, Aster RH. Quinine-induced immune thrombocytopenia associated with hemolytic uremic syndrome: a new clinical entity. *Blood* 1991;77:306-10.
39. Spearing RL, Hickton CM, Sizeland P, Hannah A, Bailey RR. Quinine-induced disseminated intravascular coagulation. *Lancet* 1990;336:1535-7.
40. Stroncek DF, Vercellotti GM, Hammerschmidt DE, Christie DJ, Shankar RA, Jacob HS. Characterization of multiple quinine-dependent antibodies in a patient with episodic hemolytic uremic syndrome and immune agranulocytosis. *Blood* 1992;80:241-8.
41. Freiman JP. Fatal quinine-induced thrombocytopenia. *Ann Intern Med* 1990;112:308-9.
42. Visentin GP, Newman PJ, Aster RH. Characteristics of quinine- and quinidine-induced antibodies specific for platelet glycoproteins IIb and IIIa. *Blood* 1991;77:2668-76.
43. Chong BH, Du XP, Berndt MC, Horn S, Chesterman CN. Characterization of the binding domains on platelet glycoproteins Ib-IX and IIb/IIIa complexes for the quinine/quinidine-dependent antibodies. *Blood* 1991;77:2190-9.
44. Christie DJ, Mullen PC, Aster RH. Fab-mediated binding of drug-dependent antibodies to platelets in quinidine- and quinine-induced thrombocytopenia. *J Clin Invest* 1985;75:310-4.
45. Smith ME, Reid DM, Jones CE, Jordan JV, Kautz CA, Shulman NR. Binding of quinine- and quinidine-dependent drug antibodies to platelets is mediated by the Fab domain of the immunoglobulin G and is not Fc dependent. *J Clin Invest* 1987;79:912-7.
46. Nieminen U, Kekomaki R. Quinidine-induced thrombocytopenic purpura: clinical presentation in relation to drug-dependent and drug-independent platelet antibodies. *Br J Haematol* 1992;80:77-82.
47. Christie DJ, Weber RW, Mullen PC, Cook JM, Aster RH. Structural features of the quinidine and quinine molecules necessary for binding of drug-induced antibodies to human platelets. *J Lab Clin Med* 1984;104:730-40.
48. Christie DJ, Diaz-Araujo H, Cook JM. Antibody-mediated platelet destruction by quinine, quinidine, and their metabolites. *J Lab Clin Med* 1988;112:92-8.
49. van der Weerd CM. Thrombocytopenia due to quinidine or quinine: report on a series of 28 patients. *Vox Sang* 1967;12:265-72.
50. Belkin GA. Cocktail purpura: an unusual case of quinine sensitivity. *Ann Intern Med* 1967;66:583-6.
51. Siroty RR. Purpura on the rocks — with a twist. *JAMA* 1976;235:2521-2.
52. Garty M, Ilfeld D, Kelton JG. Correlation of a quinidine-induced platelet-specific antibody with development of thrombocytopenia. *Am J Med* 1985;79:253-5.

The Massachusetts General Hospital wishes to
acknowledge the generous support of

Glaxo, Inc.,

whose sponsorship makes possible the continued
preparation of the Case Records.

35-MILLIMETER SLIDES FOR THE CASE RECORDS

Any reader of the *Journal* who uses the Case Records of the Massachusetts General Hospital as a medical teaching exercise or reference material is eligible to receive 35-mm slides, with identifying legends, of the pertinent x-ray films, electrocardiograms, gross specimens, and photomicrographs of each case. The slides are 2 in. by 2 in., for use with a standard 35-mm projector. These slides, which illustrate the current cases in the *Journal*, are mailed from the Department of Pathology to correspond to the week of publication and may be retained by the subscriber. Each year approximately 250 slides from 40 cases are sent to each subscriber. The cost of the subscription is \$450 per year. Application forms for the current subscription year, which began in January, may be obtained from Lantern Slides Service, Department of Pathology, Massachusetts General Hospital, Boston, Massachusetts 02114 (Telephone [617] 726-4369).