


should enhance both the accuracy in predicting functional outcome of epilepsy surgery and our ability to relate cognitive deficits to dysfunction in discrete brain areas.

### Acknowledgments

We are grateful to the Wellcome Trust for its support and to the patients, their families, and the control subjects for giving their time and effort to this study. We also wish to thank Elizabeth Isaacs for carrying out a substantial part of the testing.

### References

1. Milner B. Psychological aspects of focal epilepsy and its neurosurgical management. *Adv Neurol* 1975;8:299-321.
2. Blakemore CB, Falconer MA. Long-term effects of anterior temporal lobectomy on certain cognitive functions. *J Neurol Neurosurg Psychiatry* 1967;30:364-367.
3. Milner B. Memory and the medial temporal regions of the brain. In: Pribram KH, Broadbent DE, eds. *Biology of memory*. New York: Academic Press, 1970:29-50.
4. Rausch R. Effects of temporal lobe surgery on behavior. *Adv Neurol* 1991;55:279-292.
5. Milner B, Penfield W. The effects of hippocampal lesions on recent memory. *Trans Am Neurol Assoc* 1955;80:42-48.
6. Dimsdale H, Logue V, Piercy M. A case of persisting impairment of recent memory following right temporal lobectomy. *Neuropsychologia* 1964;1:287-298.
7. Penfield W, Milner B. Memory deficit produced by bilateral lesions in the hippocampal zone. *Arch Neurol Psychiat* 1958;79:457-497.
8. Penfield W, Mathieson G. An autopsy and a discussion of the role of the hippocampus in experiential recall. *Arch Neurol* 1974;31:145-154.
9. Connelly A, Jackson GD, Duncan JS, King MD, Gadian DG. Magnetic resonance spectroscopy in temporal lobe epilepsy. *Neurology* 1994;44:1411-1417.
10. Jackson GD, Connelly A, Duncan JS, Grünewald RA, Gadian DG. Detection of hippocampal pathology in intractable partial epilepsy: increased sensitivity with quantitative magnetic resonance T<sub>2</sub> relaxometry. *Neurology* 1993;43:1793-1799.
11. Engel J Jr, Van Ness PC, Rasmussen TB, Ojemann LM. Outcome with respect to epileptic seizures. In: Engel J, ed. *Surgical treatment of the epilepsies*. New York: Raven Press, 1993:609-621.
12. Klose U. In vivo proton spectroscopy in presence of eddy currents. *Magn Reson Med* 1990;14:26-30.



# Alien hand syndrome: Interhemispheric motor disconnection due to a lesion in the midbody of the corpus callosum

D.H. Geschwind, MD, PhD; M. Iacoboni, MD, PhD; M.S. Mega, MD; D.W. Zaidel, PhD;  
T. Cloughesy, MD; and E. Zaidel, PhD

**Article abstract**—The neuroanatomic substrate of the alien hand syndrome has remained controversial due to the noncircumscribed nature of cerebral injuries present in most cases. There have been few cases studied in which damage was restricted to portions of the body of the callosum, and most of those involved surgical callosotomy for tumors or epilepsy. We report the case of a woman with a transient alien hand syndrome caused by a stroke limited to the middle and posterior portions of the body of the corpus callosum. This case provides supportive evidence for damage to the midbody of the corpus callosum as the anatomic basis of nondominant alien hand syndrome and conforms to a model of interhemispheric motor disconnection as the essential component of this unusual behavioral syndrome. This disconnection can occur with injuries involving interhemispheric premotor and motor fibers traveling in the midportion of the callosum in individuals with left hemisphere dominance for motor activities.

NEUROLOGY 1995;45:802-808

Alien hand syndrome remains as striking and controversial a clinical entity as when first described as a type of apraxia by Goldstein.<sup>1</sup> Although Brion and Jedynak<sup>2</sup> coined the vivid term “main étrangère,” or “alien hand,” in describing patients with callosal lesions and

neglect or alienation from their hand, the term is commonly used to describe a predominantly motor phenomenon.<sup>3</sup> The hallmark of alien hand syndrome is the patient's perception of alienation from and loss of control over one or both upper extremities coincident

From the Department of Neurology (Drs. Geschwind, Iacoboni, Mega, and Cloughesy) and the Division of Brain Mapping (Dr. Iacoboni), UCLA School of Medicine, and the Department of Psychology (Drs. Iacoboni, D.W. Zaidel, and E. Zaidel), University of California, Los Angeles, CA.

Supported by NIH grant NS 20187 (to M.I. and E.Z.) and by NIMH RSA MH 00179 (to E.Z.).

Received July 11, 1994. Accepted in final form October 3, 1994.

Address correspondence and reprint requests to Dr. Daniel H. Geschwind, Department of Neurology, Reed Neurological Research Center, 710 Westwood Plaza, Los Angeles, CA 90095.

with observable complex involuntary movements.<sup>2-4</sup> The alien hand acts at odds with the patient's will, creating a sense of intermanual conflict. The ipsilateral lower extremity is often subtly involved as well. The observed behavior is so odd that often the patient's complaint is initially dismissed as functional.

To clarify previous clinical-anatomic observations, Feinberg et al<sup>5</sup> classified alien hand syndrome into two separate syndromes. One, comparable to a frontal release syndrome involving the dominant limb, is characterized by grasping, groping, and other positive exploratory behaviors and is associated with dominant medial frontal lesions.<sup>6,7</sup> The second corresponds to the archetypal alien hand syndrome and is characterized by nondominant limb apraxia and oppositional intermanual conflict, with an absence of frontal signs.<sup>5,8,9</sup> Lesions in the second type involve the anterior corpus callosum but often extend into adjacent areas such as the supplementary motor cortex or the body of the corpus callosum. The lesion typically is caused by vascular lesions, and the damage is not well circumscribed.<sup>5,10</sup> In cases of surgical callosotomy, large areas of the callosum are transected, often sparing only the splenium.<sup>3</sup> Several reports of patients with more circumscribed callosal sections have not described alien hand phenomena,<sup>11,12</sup> although one of the first descriptions of alien hand involved a patient with a midposterior callosal tumor.<sup>13</sup> Thus, there remains debate over the extent of damage necessary to produce the archetypal alien hand syndrome and what the syndrome represents from a neurobehavioral perspective.<sup>4,5</sup>

Here we report the case of a 68-year-old woman with an archetypal transient alien hand syndrome secondary to an embolic stroke confined to the posterior two-thirds of the body of the corpus callosum, sparing the splenium and most of the anterior half of the corpus callosum. This patient did not manifest the profound callosal apraxia or deficits in intermanual somatosensory transfer previously reported with lesions in the body of the corpus callosum.<sup>3,11,12,14-17</sup> Instead, she showed a delay in visuomotor transfer, evident only on detailed laboratory testing.

**Case report.** A 68-year-old right-handed Hispanic woman was admitted for coronary artery bypass grafting. On postoperative day 11, she was noted by nursing staff to have left-sided weakness and difficulty walking. According to her family, she had complained of loss of control of her left hand for the previous 3 days, as if the hand were performing on its own. She awoke several times with her left hand choking her, and while she was awake her left hand would unbutton her gown, crush cups on her tray, and fight with the right hand while she was answering the phone. To keep her left hand from doing mischief, she would subdue it with the right hand. She described this unpleasant sensation as if someone "from the moon" were controlling her hand. She also felt some degree of clumsiness in her left arm and leg.

Neurologic consultation was called on postoperative day 11, and examination revealed her to be alert and oriented as well as pleasant and cooperative. Her speech in Spanish was fluent, without dysarthria, and her comprehension and reading were intact. She had significant ideomotor apraxia with the left hand and left leg. Although she could mimic

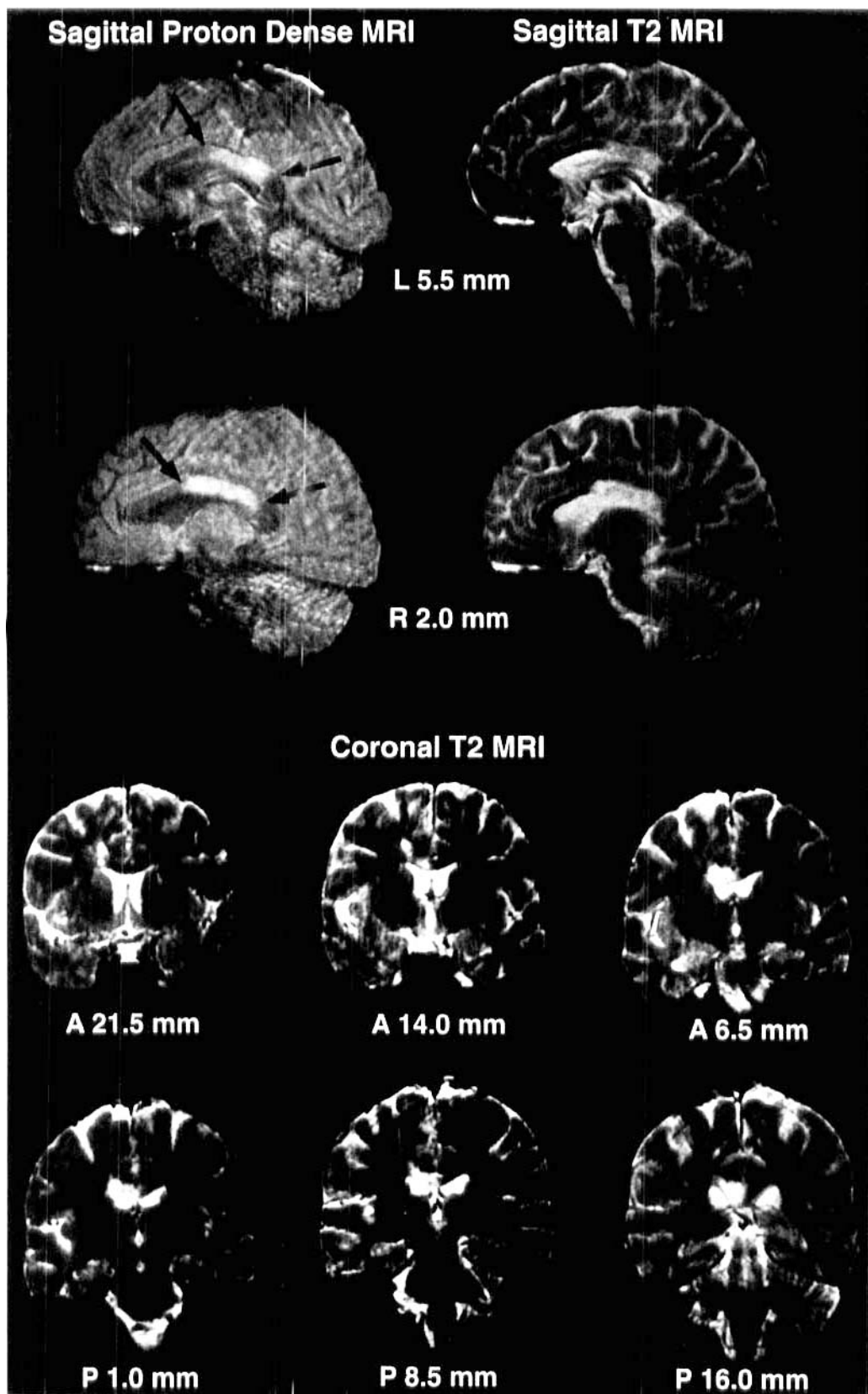
with the left hand, she did this concurrently with mirror movements of her right hand. If these mirror movements were suppressed, her praxis deteriorated. She exhibited no grasp, snout, or palmomental reflexes and performed well on alternating motor programs and in reproducing rhythms that were tapped by the examiner. She did not perseverate on verbal commands or on copying alternating sequences. Motor examination revealed a mild left-sided facial droop and a left-sided pronator drift, but strength was full and symmetric throughout. Rapid alternating movements were slowed on the left in both upper and lower extremities. She could not accomplish fine motor tasks with her left fingers or hands without mirroring them with her right. She was unaware of this until it was brought to her attention, and she had trouble suppressing the mirror movements when asked. During the examination, her left hand was observed tugging at her shirt, trying to undo her buttons. When asked to pick up the phone, she tried to do so with her left hand but had to wrestle it away with the right hand. She would crush cups given to her to hold in both hands but was able to feed herself with utensils held in her right hand. She had neither sensory neglect, tactile anomia, nor a deficit in tactile recognition in either hand. She performed cross-tactile matching equally well with both hands. Her deep tendon reflexes were normal and symmetric throughout, and plantar responses were flexor. She was initially unable to stand unassisted because she fell to the left, but she had no cerebellar ataxia or dysmetria.

On reexamination 8 hours later, she had regained most of the control over her left hand and had less asymmetry in praxis; she could carry out commands with both hands, but she demonstrated body part substitution for objects in her left hand and inappropriate proximity with her right. Handwriting was good with her right hand and grammatically intact but poorly legible with her left hand. Her walking was back to her premorbid baseline.

**Imaging.** An MRI done on postoperative day 11 revealed an area of increased signal on T<sub>2</sub>-weighted images, confined largely to the posterior body of the callosum and sparing the genu and splenium, with some extension into the right pericallosal region (figure 1). The most rostral area of high T<sub>2</sub> signal extended a few millimeters into the anterior half of the callosum. An incidental left dorsolateral frontal meningioma that has remained asymptomatic was also noted. Repeat postacute MRI obtained during postoperative week 8 revealed an area of infarction involving the posterior half of the callosal body, sparing the splenium and the anterior half of the corpus callosum, with slight extension into the white matter underlying the right cingulate cortex (figure 2).

**Clinical follow-up.** This patient has been followed for 6 months. She has had no further events but continues to complain of left hand clumsiness, manifested by occasional dropping of cups or other objects she is holding. She reports a similar sensation of clumsiness in her left leg but has had no falls. At times her two hands will collide if she is not watching them. She also complains that her right hand feels larger than her left.

Neurologic examinations at 8 weeks and at 5 months postinfarct revealed no pronator drift and normal simple fine motor movements bilaterally. But she exhibited an intermittent, effort-dependent decrease in finger and hand strength on the left. Fine motor movements during tactile exploration of objects with the left hand were also diminished. However, stereognosis and graphesthesia were intact bilaterally. No mirror movements or unusual oppositional movements of her hands were noted. Her writing was grammatically intact and intelligible with both the left and right hands.



*Laboratory neuropsychological testing.* This patient's restricted callosal lesion is unique. To our knowledge, only eight cases with lesions restricted to portions of the callosal body (sparing the genu and splenium) are discussed in the

literature.<sup>8,11-13,15</sup> Each of those cases demonstrates significant signs of callosal disconnection. While often most pronounced acutely, the signs lasted 5 to 6 months in several patients. Thus, we undertook formal laboratory testing at 8

*Figure 1. Acute proton-density and T<sub>2</sub>-weighted sagittal and coronal MRIs. Sagittal proton-density and T<sub>2</sub> views close to the midline reveal the rostral-caudal extent of the infarction, which extends approximately 3 cm. The rostral border is approximately 3 mm anterior to the midline of the callosum, and the stroke extends caudally to encompass the entire posterior half of the callosal body (arrows). Both the genu and splenium are spared, as is most of the anterior half of the callosal body. The coronal views confirm that the stroke is confined to the callosum, with slight extension into the adjacent white matter, seen in the second coronal image. An incidental, heavily calcified left frontal meningioma is seen in the first coronal image. On the coronal images, the distance from the level of the mamillary bodies is marked in millimeters (A = anterior, P = posterior).*

weeks and at 5 months after the infarction to uncover the presence of apraxia, agraphia, or auditory, sensory, motor, or visual disconnection.<sup>3</sup>

On initial bedside testing, in addition to the acute alien hand, our patient exhibited ideomotor apraxia, apraxic agraphia, and mirror movements but not aphasic agraphia, tactile anomia, or deficits in intramanual tactile transfer or localization. None of the deficits present acutely were observed during the 8-week and 5-month testing sessions. Additionally, dichotic listening (8 weeks) and several additional tests of proprioceptive and stereognostic transfer (8 weeks and 5 months), which were not done in the acute setting, demonstrated the absence of auditory or somatosensory disconnection. However, formal testing of interhemispheric visuomotor transfer at 8 weeks and at 5 months revealed a deficit in transcallosal visuomotor integration as described below.

*Interhemispheric transfer of visuomotor information.* Unimanual simple reaction times (RTs) to lateralized flashes are used to measure interhemispheric transfer time (ITT) of visuomotor information through the corpus callosum. The difference in RTs between the crossed condition (motor response contralateral to the visual stimulus) and the uncrossed condition (motor response ipsilateral to the visual stimulus) reflects the ITT, which is 3 to 4 msec in normal subjects.<sup>18</sup> Marked increases in the ITT, seen in patients with agenesis of the corpus callosum and commissurotomy patients,<sup>18</sup> support the hypothesis that the transfer occurs via the corpus callosum. The most efficient channel for interhemispheric transfer of visuomotor information is likely via callosal motor fibers.<sup>18-20</sup> Our patient's lesion interrupted these callosal motor fibers. Thus, we measured the ITT in our patient to further the understanding of the disconnection phenomena caused by the callosal lesion.

The experimental design was similar to that in a previously reported study.<sup>19</sup> The visual stimulus was presented on a high-resolution RGB monitor of a Macintosh IIsi computer. Stimuli were presented for 50 msec. A response panel placed at the midline was used for manual responses, which were carried out by the patient's pressing a key on the panel with her index finger. Sixteen blocks of 40 trials in two separate testing sessions (8 weeks and 5 months after the lesion) were performed, and the order of response hand was counterbalanced in the two testing sessions.

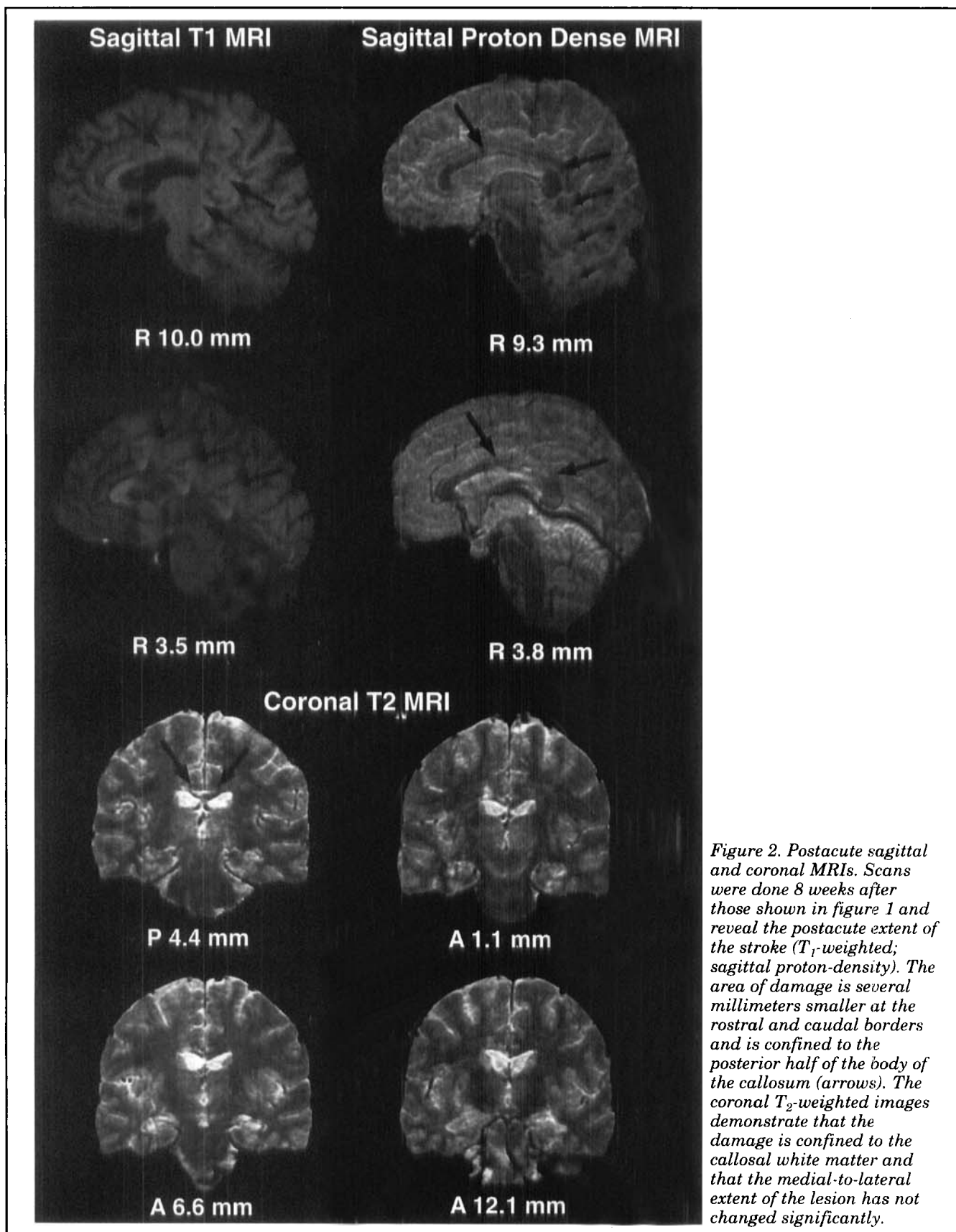
**Results.** Since the two testing sessions did not show any significant difference, data were collapsed. Any

RT that was greater than 3 SD from its respective condition mean was removed from the analysis. The highest number of outliers (13.1%) was observed in the left hand-right visual field condition, suggesting high variability of RTs for this condition. A reliable advantage of 40 msec ( $F[1, 289] = 12.02, p < 0.001$ ) was observed for the uncrossed right hand-right hemifield condition (420 msec) compared with the crossed right hand-left hemifield condition (460 msec). There was no statistical difference between the uncrossed left hand-left hemifield (496 msec) and crossed left hand-right hemifield (478 msec) conditions. The difference between the crossed and uncrossed conditions (crossed-uncrossed difference; CUD) for the right hand was of the same order as in split-brain patients.<sup>18</sup>

**Discussion.** *Alien hand syndrome and motor disconnection.* This case demonstrates that alien hand syndrome can occur with an injury restricted to the middle and posterior portions of the body of the corpus callosum, supporting the anatomic model proposed by Brion and Jedynak.<sup>13</sup> We propose that this lesion implicates interhemispheric motor disconnection in the pathogenesis of archetypal alien hand. Furthermore, it presents an intriguing example of visuomotor disconnection in the dominant hand of a patient with damage to the midbody of the corpus callosum, sparing the splenium.

Our patient had a transient alien hand syndrome that was coincident with acute edema in the most rostral extent of the posterior half of the corpus callosum with slight extension anteriorly and into the adjacent subcortical white matter (figure 1). Her postacute lesion involved an infarcted area slightly smaller than the posterior half of the body of the corpus callosum (figure 2). Thus, her transient alien hand and mild nondominant limb apraxia were correlated acutely with damage to the middle of the body of the corpus callosum.

Previous reports<sup>6,10,21,22</sup> have emphasized damage to the anterior portion of the corpus callosum and neighboring frontal cortex as the basis for alien hand syndrome. The lesions involved were large, often secondary to anterior communicating or anterior cerebral aneurysmal rupture or stroke, and affected anterior regions primarily. The inclusion of frontal groping and impulsive exploratory behaviors in alien hand cases has biased clinical-anatomic interpretations toward implicating frontal lesions in alien hand's pathogenesis. All but five of the 20 patients reviewed by Feinberg et al<sup>5</sup> had significant involvement of cingulate or frontal cortex. Two of the five, who had damage limited to the callosum, had lesions reportedly confined to the genu, but these cases were not based on MRI data and involved aneurysmal rupture, which likely resulted in an area of damage larger than that seen on CT.<sup>23,24</sup> Two of the remaining cases had documented large lesions involving the genu as well as the body of the callosum,<sup>16</sup> and the patient of Watson and Heilman<sup>8</sup> had a lesion involving the entire body of the callosum.



*Figure 2. Postacute sagittal and coronal MRIs. Scans were done 8 weeks after those shown in figure 1 and reveal the postacute extent of the stroke (T<sub>1</sub>-weighted; sagittal proton-density). The area of damage is several millimeters smaller at the rostral and caudal borders and is confined to the posterior half of the body of the callosum (arrows). The coronal T<sub>2</sub>-weighted images demonstrate that the damage is confined to the callosal white matter and that the medial-to-lateral extent of the lesion has not changed significantly.*

The present case is unique in the circumscribed nature of the lesion documented by acute and postacute MRI and is the only MRI-documented case with a le-

sion confined to the middle and posterior body of the corpus callosum resulting in alien hand syndrome. Case number 4 of Brion and Jedynak<sup>13</sup> had a tran-

sient alien hand, with damage confined to a small portion of the posterior body of the callosum. However, their patient's symptoms were more akin to hemineglect, and the dependence on autopsy for localization (remote from the event) made precise clinical-anatomic correlation difficult. Our patient's concurrent intermanual conflict, alienation from the nondominant hand, and ideomotor apraxia, in the absence of groping, grasping, or frontal system dysfunction, are analogous to those observed in other cases of archetypal callosal alien hand syndrome<sup>5,8,24</sup> and support the distinction between callosal and frontal alien hand syndrome advanced by Feinberg et al.<sup>5</sup> Additionally, the present case, with a limited callosal body infarction, supports the observed association between ideomotor apraxia and callosal alien hand syndrome<sup>5,8</sup> and suggests that the relevant callosal fibers travel in close proximity.

Our case also suggests that, when seen in conjunction with alien hand syndrome, the signs of tactile anomia, aphasic agraphia, and ideational apraxia likely reflect the more widespread damage to adjacent anterior callosal or cortical areas often seen with anterior cerebral artery infarction or aneurysmal rupture.<sup>10,16,21,22</sup> Tactile anomia has been previously associated with splenial damage as well as medial frontal and callosal damage<sup>6,10,13,16,21,22</sup> and is not observed in cases of limited callosal body damage in the acute<sup>15</sup> or postacute<sup>8,11</sup> setting. Aphasic agraphia has similarly shown variable localization, occurring with damage to the anterior callosum or genu as well as to anterior splenium and posterior body.<sup>8,17,21,22</sup> The singular vascular event in our patient suggests that many of these accompanying signs of anterior or posterior callosal disconnection can be dissociated from the alien hand phenomenon.

Anatomic data on the gross topography of interhemispheric connections in the human corpus callosum<sup>25</sup> suggest that the supplementary motor cortex and much of the primary motor (precentral) cortex send interhemispheric connections via a region that overlaps with the anterior portion of our patient's lesion. The work of Pandya et al<sup>26</sup> in nonhuman primates maps the interhemispheric fibers of primary motor, premotor (PMA), and supplementary motor areas (SMA) to the same callosal region. The more anterior extent of our patient's lesion acutely encompasses this area, whereas the more posterior extent overlaps with regions carrying postcentral parietal, insular, and posterior temporal interhemispheric connections.<sup>25,26</sup> The SMA and PMA were not involved, but it is likely that interhemispheric pathways connecting these areas were acutely disturbed.

Thus, we propose that the disruption of volitional motor control and the presence of the alien hand syndrome in the nondominant hand in our patient is due to the interhemispheric disconnection of the motor and supplementary motor areas.<sup>9</sup> The loss of interhemispheric motor integration caused by this disconnection can cause a sense of alienation from the nondominant limb and the resulting intermanual conflict that are the hallmarks of alien hand syndrome.<sup>9,27</sup>

Preliminary data from a study<sup>28</sup> with a large sample of patients seem to support this model. However, why does callosal alien hand syndrome predominantly involve the nondominant hand?

Data from lesion studies in humans suggest that the left hemisphere is dominant for complex or fine motor movements in right-handed individuals.<sup>8,9,17,27,29</sup> Recent data from functional MRI and PET support this proposition by showing a clear asymmetry of motor cortex activation during volitional fine motor movements of the hand.<sup>30,31</sup> Fine motor movements of the nondominant (left) hand in right-handed individuals involve activation of bilateral motor areas, while right hand movements involve primarily the dominant (left) motor areas. Thus, nondominant hand movement requires transfer and coordination of information between the PMA, SMA, and primary motor areas of both hemispheres. Dominant hand movement does not require this transcallosal information transfer. The left hand's dependence during fine motor movements on bilateral primary motor, PMA, and SMA activation explains why the archetypal callosal alien hand syndrome predominantly involves the left hand in left hemisphere-dominant individuals. This is further supported by the absence of alien hand symptoms and ideomotor apraxia in an ambidextrous individual with a callosal lesion similar to that of our patient.<sup>16</sup> Most of the cases of right-handed alien hand syndrome involve damage to left frontal areas, including the SMA, and are more akin to the frontal release phenomenon.<sup>5,7</sup>

Our patient's lesion acutely disrupted interhemispheric motor, PMA, and SMA connections coincident with her alien hand syndrome and ideomotor apraxia. She also was unable to carry out any fine movements with her left hand without unconsciously mirroring them with her right. The observation of mirror movements in the right hand during the acute phase of our patient's lesion further demonstrates the importance of transcallosal SMA-to-SMA communication for independent, purposeful fine movements in the left hand.<sup>22,27,32</sup> When our patient's alien hand complaint subsided, so did her apraxia and right-hand mirror movements, as has been reported by others.<sup>8,9,16,27,32</sup> Parallel evidence supporting a deficit in preparatory motor activity and implicating interhemispheric SMA-to-SMA disconnection is the attenuation of the Bereitschaftspotential coincident with alien hand syndrome.<sup>9,21</sup>

*Other signs of callosal disconnection.* Visuomotor disconnection in our patient is supported by the large CUD favoring the ipsilateral condition in the right hand's RTs to lateralized flashes. In normal subjects, the ITT averages 3 to 4 msec. In our patient's right hand, the ITT was 40 msec, consistent with observations in split-brain patients.<sup>18,19</sup>

Based on the proposal that motor disconnection underlies alien hand syndrome, one might expect difficulty in measuring interhemispheric visuomotor transfer in the left hand, since this would require intact interhemispheric motor integration. Indeed, our patient demonstrated large variance in response

times with the left hand compared with the right, and no positive CUD was demonstrated. A fundamental motor disconnection in our patient led to the disruption of fine motor control of the left hand and confounded the reliable measurement of any concomitant visuomotor disconnection. This suggests that, even months after the disappearance of the alien hand sign, a subclinical deficiency in nondominant hand motor control was evident in a laboratory setting.

Our patient had no deficit in intermanual somesthetic transfer or dichotic listening. This is in contrast to several other published reports<sup>11,14,15</sup> that described profound deficits in interhemispheric somatosensory transfer in patients with lesions affecting the body of the corpus callosum. However, others<sup>3,19,32-34</sup> did not observe such deficits as long as the splenium was spared, suggesting that the splenium provides an additional pathway for the interhemispheric transfer of somatosensory information. These conflicting results may reflect individual differences in callosal organization, sparing of some fibers in the damaged body of the callosum not seen at the resolution of MRI, or multiple crossing of somatosensory fibers. A recent study<sup>35</sup> in patients with multiple sclerosis supports the latter proposition by demonstrating that interhemispheric somatosensory transfer can occur in both the midbody of the callosum and the splenium. In our patient, the splenium was intact, providing an alternate pathway for interhemispheric somatosensory transfer.

## Acknowledgments

We wish to thank the patient and her family for their collaboration and Elicia David for research assistance.

## References

- Goldstein K. Zur Lehre der motorischen Apraxie. *J für Psychologie und Neurologie* 1908;11:169-187.
- Brion S, Jedynak C-P. Troubles du transfert interhémisphérique (callosal disconnection). A propos de trois observations de tumeurs du corps calleux. Le signe de la main étrangère. *Rev Neurol (Paris)* 1972;126:257-266.
- Bogen JE. The callosal syndromes. In: Heilman KM, Valenstein E, eds. *Clinical neuropsychology*. 3rd ed. New York: Oxford University Press, 1993:337-407.
- Doody RS, Jankovic J. The alien hand and related signs. *J Neurol Neurosurg Psychiatry* 1992;55:806-810.
- Feinberg TE, Schindler RJ, Flanagan NG, Haber LD. Two alien hand syndromes. *Neurology* 1992;42:19-24.
- Goldberg G, Mayer NH, Toglia JU. Medial frontal cortex infarction and the alien hand sign. *Arch Neurol* 1981;38:683-686.
- Della Sala S, Marchetti C, Spinnler H. Right-sided anarchic (alien) hand: a longitudinal study. *Neuropsychologia* 1991;29:1113-1127.
- Watson RT, Heilman KM. Callosal apraxia. *Brain* 1983;106:391-403.
- Tanaka Y, Iwasa H, Yoshida M. Diagnostic dyspraxia: case report and movement-related potentials. *Neurology* 1990;40:657-661.
- Banks G, Short P, Martinez J, et al. The alien hand syndrome: clinical and postmortem findings. *Arch Neurol* 1989;46:456-459.
- Dimond SJ, Scammell RE, Brouwers EYM, Weeks R. Functions of the centre section (trunk) of the corpus callosum in man. *Brain* 1977;100:543-562.
- Jeeves MA, Simpson DA, Geffen G. Functional consequences of the transcallosal removal of intraventricular tumors. *J Neurol Neurosurg Psychiatry* 1979;42:134-142.
- Brion S, Jedynak CP. Sémiologie calleuse dans les tumeurs et les malformations vasculaires. In: Michel F, Schott B, eds. *Les syndromes de disconnexion chez l'homme*. Lyon, France: SPCM, 1975:253-264.
- Volpe BT, Sidtis JJ, Holtzman JD, Wilson DH, Gazzaniga MS. Cortical mechanisms involved in praxis: observations following partial and complete section of the corpus callosum in man. *Neurology* 1982;32:645-650.
- Bentin S, Sahar A, Moscovitch M. Intermanual information transfer in patients with lesions in the trunk of the corpus callosum. *Neuropsychologia* 1984;22:601-611.
- Leiguarda R, Starkstein S, Berthier M. Anterior callosal haemorrhage; a partial interhemispheric disconnection syndrome. *Brain* 1989;112:1019-1037.
- Leipman H, Mass O. Fall von linksseitiger Agraphie und Apraxie bei rechtsseitiger Lahmung. *J für Psychologie und Neurologie* 1907;10:214-227.
- Marzi CA, Bisiacchi P, Nicoletti R. Is interhemispheric transfer of visuomotor information asymmetric? Evidence from a meta-analysis. *Neuropsychologia* 1991;29:1163-1177.
- Iacoboni M, Fried I, Zaidel E. Callosal transmission time before and after partial commissurotomy. *Neuroreport* 1994;5:2521-2524.
- Vallar G, Sterzi R, Basso A. Left hemisphere contribution to motor programming of aphasic speech: a reaction time experiment in aphasic patients. *Neuropsychologia* 1988;26:511-519.
- McNabb AW, Carroll WM, Mastaglia FL. "Alien hand" and loss of bimanual coordination after dominant anterior cerebral artery territory infarction. *J Neurol Neurosurg Psychiatry* 1988;51:218-222.
- Chan JL, Ross ED. Left-handed mirror writing following right anterior cerebral artery infarction: evidence for non-mirror transformation of motor programs by right supplementary motor area. *Neurology* 1988;38:59-63.
- Beukelman DR, Flowers CR, Swanson PD. Cerebral disconnection associated with anterior communicating artery aneurysm: implications for evaluation of symptoms. *Arch Phys Med Rehabil* 1980;61:18-23.
- Toshiya F, Endou K, Sugishita M, Tsukakoshi H. A case of callosal damage accompanied with ideomotor apraxia without agraphia, diagnostic apraxia and intermittent initiation difficulty of left hand. *Rinsho Shinkeigaku* 1987;27:1073-1080.
- De Lacoste M, Kirkpatrick JB, Ross ED. Topography of the human corpus callosum. *J Neuropathol Exp Neurol* 1985;44:578-591.
- Pandya DN, Karol EA, Heilbronn D. The topographical distribution of interhemispheric projections in the corpus callosum of the rhesus monkey. *Brain Res* 1971;32:31-43.
- Goldberg G. Supplementary motor area structure and function: review and hypotheses. *Behav Brain Sci* 1985;8:567-616.
- Chan J-L, Liu A-B. The alien hand syndrome (AHS) in anterior cerebral artery (ACA) territory infarction: evidence for the contribution of the corpus callosum (CC) midbody to the development of the AHS [abstract]. *Neurology* 1994;44(suppl 2):A292.
- Geschwind N. Disconnection syndromes in animals and man. *Brain* 1965;88:237-294, 585-644.
- Kawishima R, Yamada K, Kinomura S, et al. Regional cerebral blood flow changes of cortical motor areas and prefrontal areas in humans related to ipsilateral and contralateral hand movement. *Brain Res* 1993;623:33-40.
- Kim SG, Ashe J, Hendrich K, et al. Functional magnetic resonance imaging of motor cortex: hemispheric asymmetry and handedness. *Science* 1993;261:615-616.
- Risse GL, Gates J, Lund G, et al. Interhemispheric transfer in patients with incomplete section of the corpus callosum: anatomic verification with magnetic resonance imaging. *Arch Neurol* 1989;46:437-443.
- Graff-Radford NR, Welsh K, Godersky J. Callosal apraxia. *Neurology* 1987;37:100-105.
- Zaidel D, Sperry RW. Some long-term motor effects of cerebral commissurotomy in man. *Neuropsychologia* 1977;15:193-204.
- Pelletier J, Habib M, Lyon-Caen O, et al. Functional and magnetic imaging correlates of callosal involvement in multiple sclerosis. *Arch Neurol* 1993;50:1077-1087.

# Neurology<sup>®</sup>

## **Alien hand syndrome: Interhemispheric motor disconnection due to a lesion in the midbody of the corpus callosum**

D. H. Geschwind, M. Iacoboni, M. S. Mega, et al.

*Neurology* 1995;45;802-808

DOI 10.1212/WNL.45.4.802

**This information is current as of April 1, 1995**

<b>Updated Information &amp; Services</b>	including high resolution figures, can be found at: <a href="http://www.neurology.org/content/45/4/802.full.html">http://www.neurology.org/content/45/4/802.full.html</a>
<b>References</b>	This article cites 27 articles, 5 of which you can access for free at: <a href="http://www.neurology.org/content/45/4/802.full.html##ref-list-1">http://www.neurology.org/content/45/4/802.full.html##ref-list-1</a>
<b>Citations</b>	This article has been cited by 7 HighWire-hosted articles: <a href="http://www.neurology.org/content/45/4/802.full.html##otherarticles">http://www.neurology.org/content/45/4/802.full.html##otherarticles</a>
<b>Permissions &amp; Licensing</b>	Information about reproducing this article in parts (figures, tables) or in its entirety can be found online at: <a href="http://www.neurology.org/misc/about.xhtml#permissions">http://www.neurology.org/misc/about.xhtml#permissions</a>
<b>Reprints</b>	Information about ordering reprints can be found online: <a href="http://www.neurology.org/misc/addir.xhtml#reprintsus">http://www.neurology.org/misc/addir.xhtml#reprintsus</a>

*Neurology*® is the official journal of the American Academy of Neurology. Published continuously since 1951, it is now a weekly with 48 issues per year. Copyright Copyright 1995 by Modern Medicine Publications, Inc., a subsidiary of Edgell Communications, Inc.. All rights reserved. Print ISSN: 0028-3878. Online ISSN: 1526-632X.

