

- mutations in familial amyotrophic lateral sclerosis. *Am J Hum Genet* 1994;55(suppl):A243
14. Gurney ME, Pu H, Chiu AY, et al. Motor neuron degeneration in mice that express a human Cu, Zn superoxide dismutase mutation. *Science* 1994;264:1772-1775
  15. Bowling AC, Schulz JB, Brown RH, Beal MF. Superoxide dismutase activity, oxidative damage, and mitochondrial energy metabolism in familial and sporadic amyotrophic lateral sclerosis. *J Neurochem* 1993;61:2322-2325
  16. Rainero I, Pinessi L, Tsuda T, et al. SOD1 missense mutation in an Italian family with ALS. *Neurology* 1994;44:347-349

## Intracerebral Involvement in Scleroderma en Coup de Sabre: Report of a Case with Neuropathologic Findings

Marilda H. Chung, MD,\* John Sum, MD,†  
Martha J. Morrell, MD† and Dikran S. Horoupian, MD\*

Linear scleroderma en coup de sabre (LScs) is a rare disorder not infrequently associated with neurologic symptoms, notably epilepsy. However, histopathologic documentation of intracerebral lesions in LScs is very limited and the etiology of the central nervous system symptoms has therefore never been convincingly established. We describe a 27-year-old woman with LScs and a long-standing history of epilepsy. Radiographic studies demonstrated a focal, intraparenchymal lesion in the left frontal lobe directly subjacent to the area of scleroderma on the forehead and scalp. The resected cerebral lesion revealed localized band-like sclerosis of the leptomeninges and associated vessels, as well as intraparenchymal calcifications and anomalous, ectatic vessels. These findings suggest that LScs may represent a neurocutaneous syndrome of vascular dysplasia similar to the Sturge-Weber syndrome, rather than a localized form of collagen vascular disease, as suggested by some.

Chung MH, Sum J, Morrell MJ, Horoupian DS. Intracerebral involvement in scleroderma en coup de sabre: report of a case with neuropathologic findings. *Ann Neurol* 1995;37:679-681

Linear scleroderma en coup de sabre (LScs) is an unusual, nonhereditary disorder characterized by an atro-

From the \*Division of Neuropathology and †Department of Neurology and Neurological Sciences, Stanford Comprehensive Epilepsy Center, Stanford University Medical Center, Stanford, CA.

Received Sep 2, 1994, and in revised form Jan 5, 1995. Accepted for publication Jan 6, 1995.

Address correspondence to Dr Horoupian, Division of Neuropathology, R-241, Stanford University Medical Center, 300 Pasteur Drive, Stanford, CA 94305-5324.

phic, band-like region of induration involving the frontoparietal area of the forehead and scalp. Although generally regarded as part of the spectrum of connective tissue disorders that includes both morphea and progressive systemic sclerosis (PSS), the pathogenesis of LScs is unknown. Overlap syndromes with systemic lupus erythematosus and other collagen vascular diseases have suggested an autoimmune etiology [1]. However, the localized nature, nonprogressive course, and inconsistent presence of autoantibodies in LScs all suggest that processes other than autoimmune mechanisms may be involved [2, 3].

Histologically, the skin lesion in LScs consists of a localized area of dense collagen deposition within the dermis that may extend to involve deeper connective tissues including muscle and even bone. By mechanisms that are unclear, progressive involution of the craniofacial bones may result, culminating in hemifacial atrophy [2]. This extreme expression of LScs appears to be identical to those cases described as the Parry-Romberg (or Romberg) syndrome of idiopathic progressive facial hemiatrophy (PFH).

A variety of neurologic disorders referable to the side of dermatologic involvement have been reported in LScs. Perhaps the most frequent neurologic abnormality in LScs is seizure disorder, usually of the complex partial type [2,4-10]. Radiographic abnormalities including cerebral atrophy, ventricular enlargement, parenchymal calcifications, white matter changes, and meningocortical "dysmorphia" have also been reported [6, 11, 12]. However, surprisingly scant information regarding the histopathology of cerebral lesions in LScs exists.

In this report we describe the neuropathologic findings in a patient with LScs and a seizure disorder who underwent resection of an intracranial lesion that was topographically related to the sclerodermatous lesion of her forehead.

### Case Report

The patient is a 27-year-old woman who was first noted to have a pale lesion of the left forehead at age 1 year. The lesion progressed to a reddish plaque and then to a depressed, linear scar. The diagnosis of LScs was established by biopsy at 4 years of age. At age 3.5 years, the patient developed complex partial seizures, which first became generalized at age 22. The patient has not developed any additional skin lesions or evidence of systemic involvement. There is no family history of either dermatologic or neurologic disease.

Physical examination demonstrated a linear, atrophic area of the left forehead just lateral to the midline. The lesion extended from the left superior orbital ridge into the scalp and was associated with hair loss and a shallow groove in the skull. A mild left facial atrophy with asymmetry of smile was appreciable. The remainder of the examination was unremarkable. Laboratory studies including FANA, anti-SC70, anti-centromere, and ANA titers were negative. Magnetic

resonance imaging (MRI) scans demonstrated a possibly calcified, left frontal lobe lesion underlying the area of scleroderma, involving cortex and white matter (Fig 1). There was associated parenchymal atrophy. An angiogram revealed no abnormalities. Electroencephalographic studies showed nearly constant interictal as well as ictal epileptiform abnormalities consistent with left frontal onset.

During surgical resection of the cerebral lesion, a thickened skull plate under the area of skin abnormality and dense adhesions of the dura to the underlying pia-arachnoid membranes were noted. Postoperatively, the patient is maintained on phenytoin monotherapy and has shown complete resolution of her seizures.

### Neuropathology

The resected left frontal brain tissue measured  $8.8 \times 5.5 \times 2.4$  cm and was notable for a central area of thickened, opaque leptomeninges that were densely adherent to the underlying cortex. The involved area measured  $1.2 \times 1.0$  cm. The adjacent leptomeninges and superficial cortical vessels were unremarkable. Segments of the bone and overlying dura were not available for examination. Microscopically, the thickened area of the leptomeninges consisted of markedly dense collagenous tissue; inflammatory cells were absent. Many of the leptomeningeal vessels were abnormally clustered and had thickened, homogeneously sclerotic walls that blended into the fibrotic meninges (Fig 2A). No fibrinoid

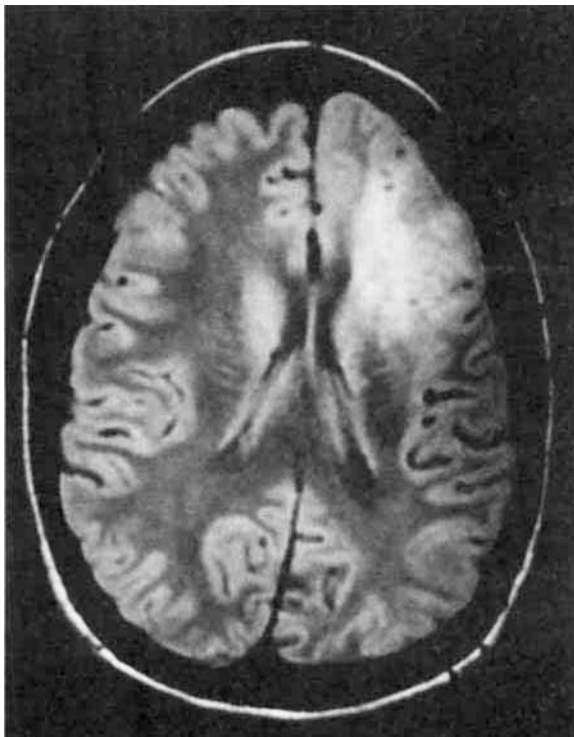
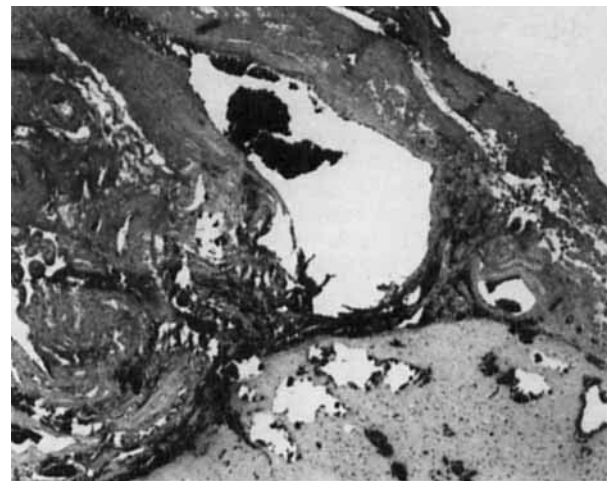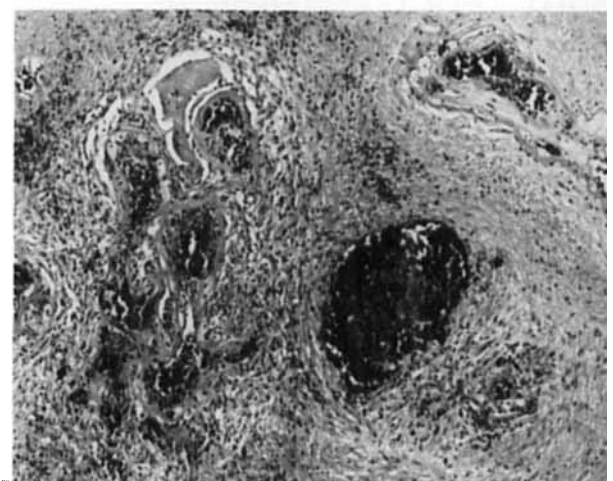


Fig 1. Magnetic resonance imaging scan demonstrates a well-demarcated, nonhomogeneous lesion of the left frontal lobe, involving both cortex and white matter. Topographically, this lesion was directly adjacent to the area of facial/scalp scleroderma.



A



B

Fig 2. (A) Prominent, dense sclerosis of the leptomeninges merged into the walls of similarly thickened leptomeningeal vessels that appeared abnormally clustered. Numerous calcospherites were present in the underlying cortex and white matter (H & E,  $\times 160$  before 33% reduction). (B) Anomalous collection of ectatic, sclerotic vessels in the white matter underlying the area of leptomeningeal sclerosis. The surrounding parenchyma is gliotic (H & E,  $\times 250$  before 34% reduction).

degeneration, amyloid or vascular inflammation was present. At the margins of the involved areas, an abrupt transition to normal leptomeninges indicated the circumscribed nature of the lesion. Within the brain parenchyma, densely sclerotic, thickened blood vessels similar in appearance to the leptomeningeal vessels were noted. Many were markedly dilated and randomly dispersed, sometimes forming small clusters. No inflammatory infiltrates, fibrinoid necrosis, or thrombi were present. The parenchyma surrounding some of the abnormal vessels was mildly to moderately gliotic (Fig. 2B). There were numerous parenchymal calcospherites, predominantly in the cortical strip directly underlying the area of dense leptomeningeal fibrosis. Scattered calcifications, some associated with vessels, were also seen in the deep white matter.

## Discussion

Brain involvement in patients with LScs has long been suspected on both clinical and radiologic grounds. However, histologic information regarding the nature of these lesions is scarce. Ultrastructural examination of skin in PFH, considered by some an extreme expression of LScs, has demonstrated abnormalities of vascular endothelium and basement membranes, suggesting cell-mediated vascular injury analogous to what has been proposed in PSS and morphea [13]. Although an inflammatory process has been thought to underlie the intracerebral lesions in LScs, this hypothesis has never been histologically confirmed [5]. In one case of LScs associated with seizure disorder, extension of inflammatory infiltrates into the periorbital soft tissues was documented but no intracranial findings were described [10].

Although LScs is often likened to PSS, in contrast to LScs virtually all neurologic symptoms occurring in patients with PSS are attributable to complications of systemic disease, concurrent diseases, or steroid therapy. Primary intracerebral involvement in PSS is exceedingly rare, possibly due to the paucity of adventitial fibrous tissue in the cerebral vasculature. It would therefore seem unlikely that the intracerebral lesions seen in LScs are related to the inflammatory mechanisms thought to be involved in the skin lesions of PSS.

We propose the alternative theory that LScs with intracerebral involvement may represent a neurocutaneous syndrome of vascular dysgenesis. This interpretation is consistent with three separate descriptions of central nervous system pathology in LScs/PFH that appeared in German around the turn of the century (cited by Terstegge and co-workers [11]). The findings included meningeal thickening, atrophy of cortical gyri, and vascular "stasis." Wolf and Verity [7] similarly described abnormal vessels in a case of PFH associated with ipsilateral cerebellar atrophy. Based on radiologic studies, Merritt and Faber [12] also concluded that the cerebral calcifications in PFH/LScs were most likely vascular in origin and probably represented a vascular malformation.

Early studies of localized scleroderma (LS) involving the extremities demonstrated a predilection for the skin lesions to occur along dermatomal lines and also showed a consistent association with various congenital anomalies of the neuroaxis, such as spina bifida [6,

14]. These observations further support the theory that both LS and LScs represent developmental disorders rather than localized forms of autoimmune disease. In this respect, one may compare the lesion in LScs to certain craniofacial, vascular dysgenetic neurocutaneous disorders, such as the Sturge-Weber syndrome. It is interesting that hemifacial atrophy has been reported in association with Sturge-Weber syndrome [15]. Although histologically the vascular lesion in the present case does not fit into any of the well-defined categories of vascular malformations, this may in part be due to the variable involutionary changes of its dermal, leptomeningeal, and parenchymal components.

## References

1. Mackel SE, Kozin F, Ryan LM, et al. Concurrent linear scleroderma and systemic lupus erythematosus: a report of two cases. *J Invest Dermatol* 1979;73:368-372
2. Krafchik BR. Localized cutaneous scleroderma. *Semin Dermatol* 1992;11:65-72
3. Falanga V, Medsger TA, Reichlin M, Rodnan G. Linear scleroderma. Clinical spectrum, prognosis and laboratory abnormalities. *Ann Int Med* 1986;104:849-857
4. Chazen EM, Cook CD, Cohen J. Focal scleroderma: report of 19 cases in children. *J Pediatr* 1962;60:385-393
5. Luer W, Jockel D, Henze T, Schipper HI. Progressive inflammatory lesions of the brain parenchyma in localized scleroderma of the head. *J Neurol* 1990;237:379-381
6. Wartenberg R. Progressive facial hemiatrophy. *Arch Neurol Psychiatry* 1945;54:75-96
7. Wolf SM, Verity A. Neurological complications of progressive facial hemiatrophy. *J Neurol Neurosurg Psychiatry* 1974;37:997-1004
8. Dilley JJ, Perry HO. Bilateral linear scleroderma en coup de sabre. *Arch Dermatol* 1968;97:688-689
9. Donley DE. Facial hemiatrophy associated with epilepsy. *J Nerv Ment Dis* 1935;82:33-39
10. David J, Wilson J, Woo P. Scleroderma "en coup de sabre." *Ann Rheum Dis* 1991;50:260-262
11. Terstegge K, Kunath B, Felber S, et al. MR of brain involvement in progressive facial hemiatrophy (Romberg disease): reconsideration of a syndrome. *AJNR* 1994;15:145-150
12. Merritt KK, Faber HK. Progressive facial hemiatrophy: report of two cases with cerebral calcifications. *J Pediatr* 1937;10:374-395
13. Pensler JM, Murphy GF, Mulliken JB. Clinical and ultrastructural studies of Romberg's hemifacial atrophy. *Plast Reconstr Surg* 1990;85:669-674
14. Rubin L. Linear scleroderma: association with abnormalities of the spine and nervous system. *Arch Dermatol Syphilol* 1948;58:1-18
15. Koch G. The phakomatoses. In: Vinken PJ, Bruyn GW, eds. *Handbook of clinical neurology*. New York: American Elsevier, 1972:512