

CASE REPORT

Late onset globoid cell leukodystrophy (Krabbe's disease)— Swedish case with 15 years of follow-up

J Arvidsson¹, B Hagberg², J-E Månsson³ and L Svennerholm³

Department of Pediatrics, County Hospital of Jönköping¹, Department of Pediatrics and Child Psychiatry² and Department of Clinical Neuroscience³, Section of Neurochemistry, University of Göteborg, Göteborg, Sweden

Arvidsson J, Hagberg B, Månsson J-E, Svennerholm L. Late onset globoid cell leukodystrophy (Krabbe's disease)—Swedish case with 15 years of follow-up. *Acta Pædiatr* 1995;84:218–21. Stockholm. ISSN 0803–5253

We describe a male patient with late onset globoid cell leukodystrophy (GLD) (Krabbe's disease) still alive at 24 years of age, with a well preserved intellectual and communicative capacity, in contrast to visual failure and severe central pyramidal and extrapyramidal motor disability with spasticity, dystonia, ataxia and peripheral neuropathy. Visual dysfunction began at 4 years of age, limping and balance problems at 8 years and epilepsy at 14 years of age. Neuroimaging at 15 years of age revealed white matter lesions, and nerve conduction velocity examinations showed a slowly developing polyneuropathy. Galactosylceramidase activity was reduced in leukocytes to 0.07 $\mu\text{kat/kg}$ protein compared with 0.02 (SD 0.01) $\mu\text{kat/kg}$ protein in infantile GLD. □ *Galactosylceramidase deficiency, galactosylceramidoses, Krabbe's disease, late onset globoid cell leukodystrophy*

J Arvidsson, Pediatric Clinic, County Hospital of Jönköping, Ryhov, S-551 85 Jönköping, Sweden

Globoid cell leukodystrophy (GLD), in its classic form, is a rapidly progressive and brain destroying disease in infants. It was first described in Denmark by Krabbe (1) and is known to be most prevalent in Sweden, with more than 100 cases diagnosed between 1960 and 1992. Late onset Krabbe's disease, defined as the form with an onset after 15 months of age, is extremely rare in the Scandinavian ethnic group, but seems to be the predominant form in some Mediterranean populations (2). While infantile GLD has a rather monotonous phenotypic pattern (3), the late onset type shows a wide scatter of variations in expression, as revealed in a European study of 50 cases (4). We present data on the first Swedish case of late onset GLD, a patient still alive at 24 years of age and able to manage a sheltered workshop job.

Case report

This boy, born in 1969, was the third child of healthy non-consanguineous parents, both of Swedish ethnic origin. One sister had died at 6 years of age of acute lymphatic leukemia. One older brother was healthy. The pregnancy and delivery were uneventful: birth weight 3000 g and length 50 cm. The neonatal period and early development were normal. He was able to sit at 7 months of age, walked unsupported at 1 year and was toilet trained at 2 years; he also had normal speech development. He was fully

developmentally assessed at 4-year check-up (a standard Swedish health examination). The first symptom was suspicion of visual dysfunction at 4–5 years of age. At 6 years of age he had a visual acuity of 5/30 but the ERG was normal. At 8 years of age his vision had deteriorated to 0.1 in both eyes and then remained largely unchanged and the macula is still considered normal now at age 24 years of age.

Motor performance had been normal up to early school age, but at 8 years of age he began to limp with his left leg and had a balance problem. A few months later, neurological examination revealed spastic paraparesis with bilateral ankle clonus and extensor Babinski's sign and, in addition, ataxia, cavus feet and atrophic hands. Within the next 6 months he deteriorated rapidly and became wheel-chair dependent. A tetraplegic spastic–atactic condition developed in parallel, as well as a slowly increasing sensory motor polyneuropathy. In later years, dystonic features have appeared, particularly obvious in the plantar-deviated feet. Epilepsy began at 14 years of age with partial seizures. EEG showed paroxysmal activity on the left side. He was given carbamazepine and at 24 years of age is free from seizures. His speech, normal until school age, successively became dysarthric with slow articulation, making him difficult to understand in daily communications, except with his family. His intellectual profile declined slightly when he was 7–8 years of age, but he has always

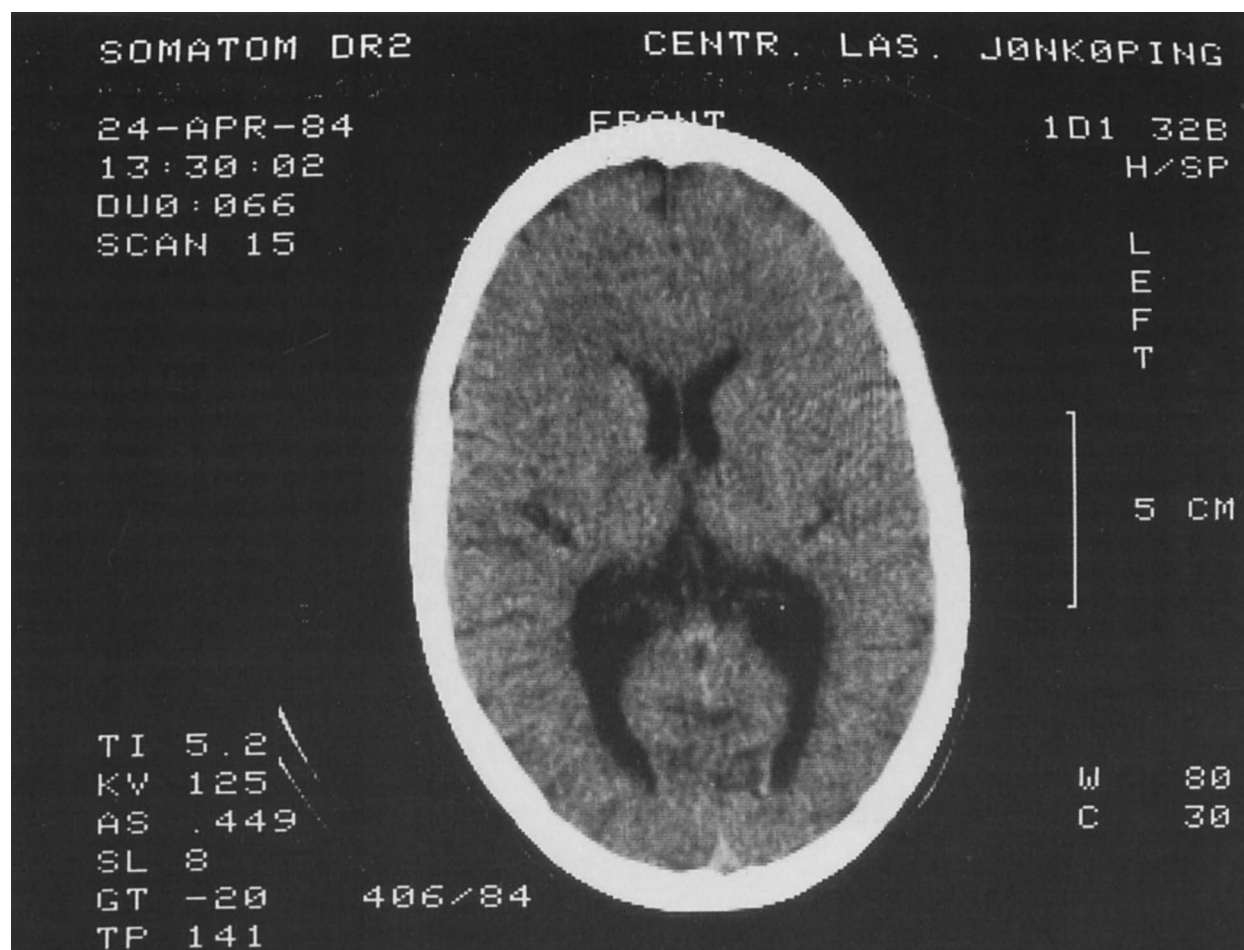


Fig. 1. CT scan of the brain at 15 years of age showing demyelinating disease.

been able to stay in the mainstream educational system. At 24 years of age he has a sheltered occupation with computer work in an office; thus, he has maximum complex motor disability but a surprisingly well preserved intellectual and communicative ability.

Laboratory findings

Galactosylceramidase activity was determined with the specific substrate N-nervonylgalactosylsphingosine (C24:1 galactosylceramide developed in our laboratory), which provides optimum discrimination between affected homozygote patients, obligatory heterozygotes and controls (5). The galactosylceramidase activity of the leukocytes from our patient was $0.07 \mu\text{kat/kg}$ protein compared with 0.02 (SD 0.008) $\mu\text{kat/kg}$ protein in patients with the infantile form of GLD. The corresponding values in leukocytes for the father, mother and brother were 0.61 , 0.52 and $0.33 \mu\text{kat/kg}$

protein (parents of infantile GLD patients 0.55 (SD 0.26) $\mu\text{kat/kg}$ protein). The galactosylceramidase activity in the patient's cultured skin fibroblasts was $0.14 \mu\text{kat/kg}$ protein (reference values 1.08 (SD 0.23) $\mu\text{kat/kg}$ protein). Nevertheless, cultured skin fibroblasts are a less valuable source of material for diagnosis and discrimination of GLD patients. The patient had a slightly elevated albumin concentration determined at 8, 9, 21 and 24 years of age. The values were 309, 260 (reference values 75–150 mg/l at 15 years), 375 and 309 mg/l (100–300 mg/l at 15–45 years), indicating mild brain barrier damage.

Neurophysiology

Nerve conduction velocities (NCV) in the lower limbs at 8 years of age were NCVm 39–42 m/s and NCVs 30–38 m/s (sural nerve); at 21 years of age, NCVm 17 m/s and NCVs 20 m/s.

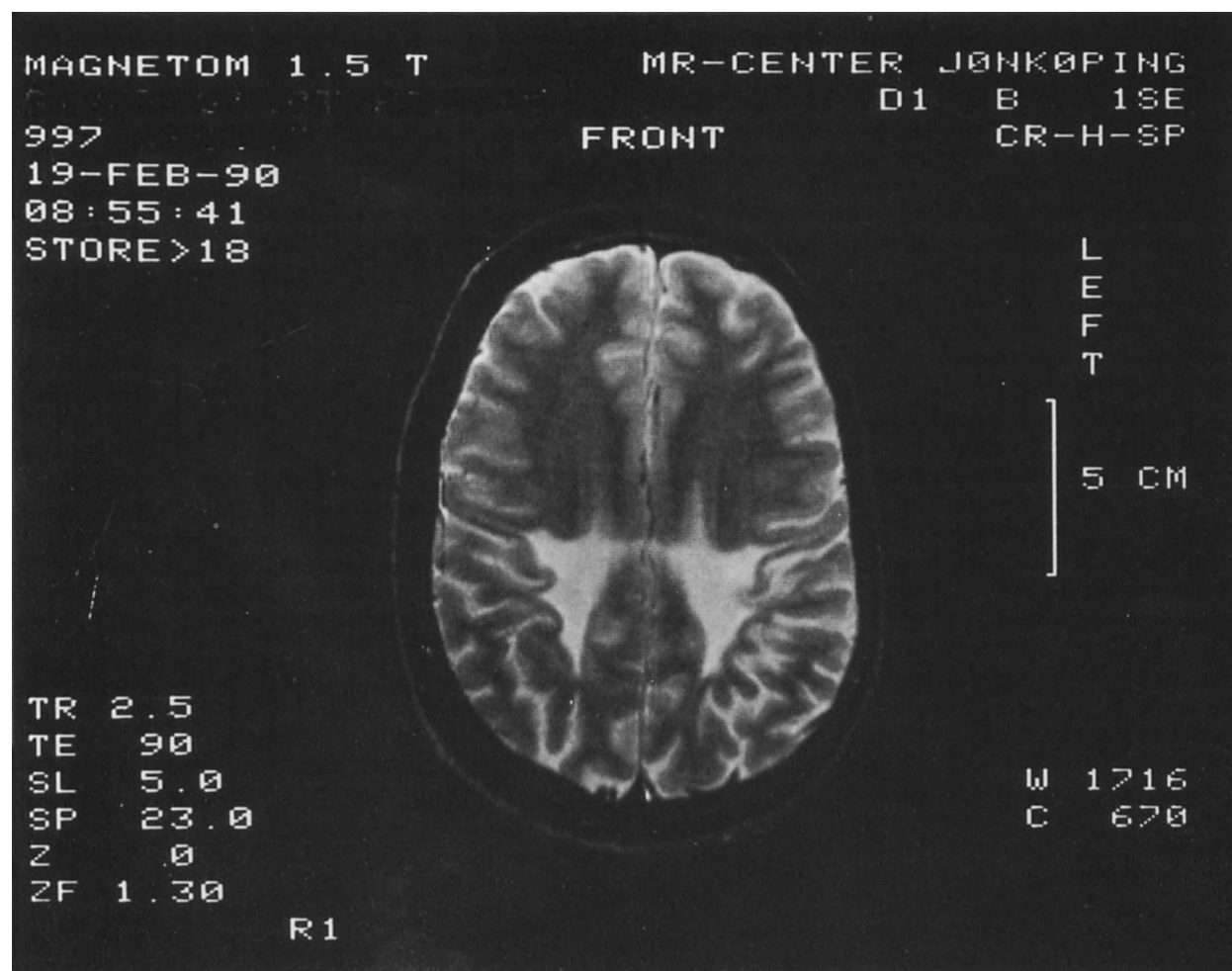


Fig. 2. MRI of the brain at 21 years of age showing marked white matter lesions, particularly in the parietal, but also in the frontal and temporal areas.

Neuroradiology

CT scan at 8 years of age was normal; at 15 years it revealed severe demyelination (Fig. 1). MRI (Fig. 2) was performed at 21 years of age and showed marked white matter lesions. The reduction in white matter was most pronounced in the parietal region, but frontal and temporal areas were also affected. T2-weighted images demonstrated increased signals from the white matter surrounding the lateral aspects of the posterior horn in both hemispheres. The signal intensity from both the right and left globus pallidus was lower than is usually seen in this part of the brain.

Discussion

Combined neurological, neurophysiological and neuroimaging data suggested a progressive encephalopathy with marked white matter lesions. The enzymatic

findings determined the diagnosis of GLD. In a large study of 50 European patients with late onset GLD (4), the authors were unable to find any difference in residual galactosylceramidase activity between their late onset patients and those with the infantile form, although the determinations were performed with specific substrate. It is thus likely that our patient belongs to another genotype than the previously described late infantile European GLD group.

The clinical phenotype and long-term profile of this late onset GLD male completely differ from that of the 100 infantile GLD cases diagnosed over the past 30 years in Sweden. There are, however, reports from other parts of the world of patients with disease of long duration reaching adult age (6–9).

The history and long-term profile of our patient were characterized by peculiarities in clinical course and profile, contrasting to the traditional concept of late onset GLD (4): the uneven, now 20-year clinical profile, beginning with insidious isolated visual failure

from 4–8 years, the rapid general neurological deterioration over a few months, ending with severe motor disability, and finally the now 15-year period with a remarkably stable yet slowly downhill course. Visual failure may be due to destruction of optic radiation tracts, as optic fundi were normal. Our patient, at age 24 years of age, also has a surprisingly well preserved intellectual capacity, in contrast with his pronounced neuromotor and visual impairment. For a long time, late onset GLD cases were considered to be rapidly deteriorating in all capacities, with a profile leading to early death once the downhill process had begun (3). Discrepancies in clinical profiles, such as the ones in our patient, have recently been reported increasingly, particularly in late juvenile and adult onset GLD patients (6–9). Thus Lyon et al. (4), reviewing 50 cases, emphasized that the pace and duration of the disease might be very variable, but they were unable to present concrete data on intellectual profiles. In the series of 15 cases presented by Kolodny et al. (9), there were 8 with intact intellectual capacities in spite of severe progressive motor difficulties. It is now increasingly important to delineate differences of this kind in clinical profiles and long-term prognosis. A correct prognostic evaluation and future therapeutic approaches may soon be influenced by advances in enzyme and molecular biology.

Acknowledgements.—The authors thank Assistant Professor T Hindmarsh and Dr G Åkerskog for their comments on neuro-radiology and neuro-ophthalmology. This study was supported by the Gunnar and Märtha Bergendahl Foundation.

References

1. Krabbe K. A new familial infantile form of diffuse brain-sclerosis. *Brain* 1916;39:74–114
2. Fiumara A, Pavone L, Siciliano L, Tiné A, Parano E, Innico G. Late onset globoid cell leukodystrophy. *Child Nerv Syst* 1990;6:194–7
3. Hagberg B. Krabbe's disease: Clinical presentation of neurological variants. *Neuropediatrics* 1984;15(Suppl):11–15
4. Lyon G, Hagberg B, Evrard PH, Allaire C, Pavone L, Vanier M. Symptomatology of late onset Krabbe's leukodystrophy: The European experience. *Dev. Neurosci* 1991;13:240–4
5. Månsson JE, Svennerholm L. The use of galactosylceramides with uniform fatty acids as substrates in the diagnosis and carrier detection of Krabbe disease. *Clin Chem Acta* 1982;126:127–33
6. Phelps M, Aicardi J, Vanier M-T. Late onset Krabbe's leukodystrophy: a report of four cases. *J Neurol Neurosurg Psychiatry* 1991;54:293–6
7. Verdru P, Lammens M, Dom R, Van Elsen A, Carton H. Globoid cell leukodystrophy: A family with both late-infantile and adult type. *Neurology* 1991;41:1382–4
8. Grewal RP, Petronas N, Baron NW. Late onset globoid cell leukodystrophy. *J Neurol Neurosurg Psychiatry* 1991;54:1011–2
9. Kolodny EH, Raghavan S, Krivit W. Late-onset Krabbe disease (globoid cell leukodystrophy): Clinical and biochemical features of 15 cases. *Dev Neurosci* 1991;13:232–9

Received Jan. 10, 1994. Accepted May 11, 1994