

Cerebral artery stenoses in Williams syndrome cause strokes in childhood

Paige Kaplan, MBBCh, Martin Levinson, MD, and Bernard S. Kaplan, MBBCh

From the Divisions of Genetics and Nephrology, Children's Hospital of Philadelphia and University of Pennsylvania and Sinal Hospital, Detroit, Michigan

Extensive narrowing of lumens of many cerebral arteries caused strokes with brain damage and chronic hemipareses in two children with Williams syndrome. Increased irritability, loss of consciousness, and seizures were initial signs. Arterial stenoses are not limited to the supraaortic and pulmonary arteries in patients with Williams syndrome. (J PEDIATR 1995;126:943-5)

The cardiovascular system is affected in 60% of patients with Williams syndrome; the most common problem is narrowing (stenosis, hypoplasia, coarctation) of the lumens of the

supraaortic and peripheral pulmonary arteries. Stenoses of cerebral arteries have not been considered part of the spectrum of vascular disease in Williams syndrome. We describe two patients with extensive narrowing of cerebral arteries and neurologic sequelae.

Submitted for publication Nov. 4, 1994; accepted Jan. 27, 1995.
Reprint requests: Paige Kaplan, MBBCh, Children's Hospital of Philadelphia, 34th Street and Civic Center Boulevard, Philadelphia, PA 19104-4399.

Copyright © 1995 by Mosby-Year Book, Inc.
0022-3476/95/\$3.00 + 0 9/22/63716

CASE REPORTS

Case 1. A 22-year-old woman was recognized as having Williams syndrome at age 19 years. She had had marked hypertension and congestive heart failure at 10 weeks of age. Cardiac catheterization showed peripheral pulmonic stenosis, a thickened pulmonic

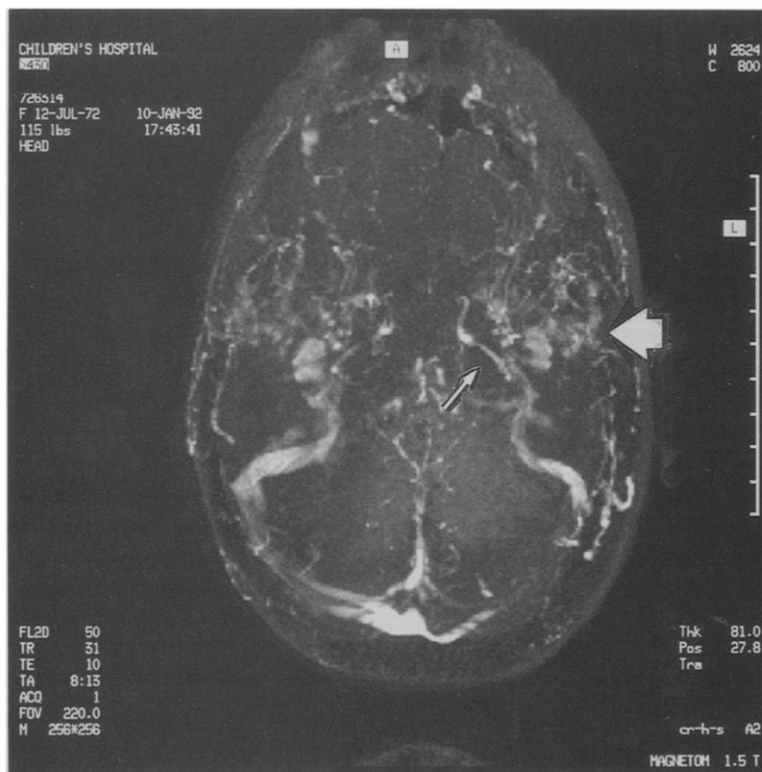

Fig. 1. Case 1. Magnetic resonance angiography of brain at 19½ years showing narrow lumens of internal carotid arteries at bifurcation into anterior and middle cerebral arteries (small arrow) and collateral vessels (wide arrow).

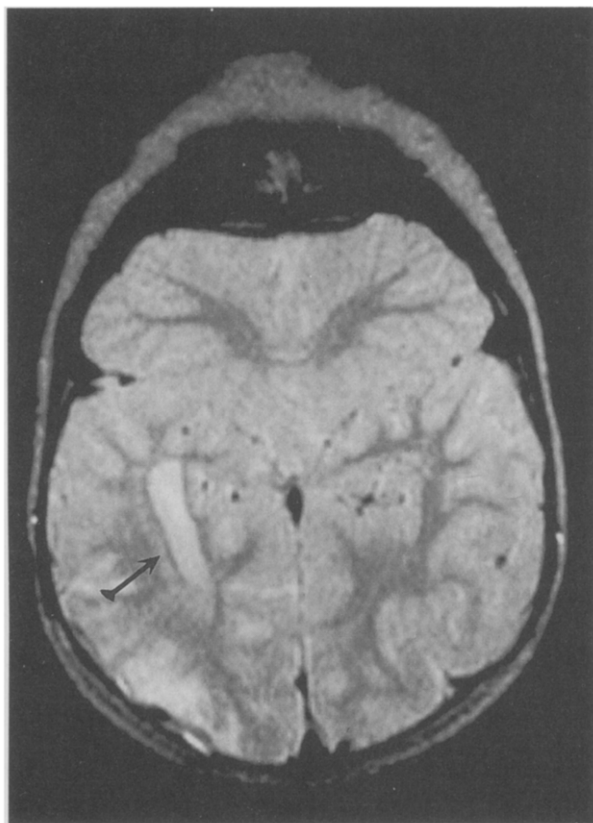


Fig. 2. Case 2. Magnetic resonance imaging of brain at 3 years showing infarction in area of left middle cerebral area (arrow).

See related article, p. 945.

MRI Magnetic resonance imaging

valve, and right-sided ventricular hypertrophy; aortic narrowing was absent. She had three episodes of cerebrovascular insufficiency: at 3 years of age she suddenly became more irritable and lost consciousness, and an acute left hemiparesis developed, with greater involvement of the upper limb than the lower. Blood pressure was 120 to 140/90 mm Hg. Cranial bruits were heard over the parietal and left carotid arteries. Arteriography showed occlusion of the right anterior and middle cerebral arteries with "abnormal blushing" in the diencephalon. Moyamoya was diagnosed. The electroencephalogram showed abnormal asymmetric intermittent interhemispheric activity. The patient was treated with acetylsalicylic acid, 7.5 mg/day. The hemiparesis resolved but recurred a few weeks later on the right side. Focal and generalized seizures developed subsequently. She lost the ability to recite the alphabet and numbers, and to recognize colors. At 6½ years of age she had another episode of hemiparesis and had residual, permanent bilateral spastic hemiparesis. At 12 years of age she had intermittent pain and discoloration in the left arm. Severe narrowing of the left subclavian artery and mod-

erate narrowing of the origin of the left renal artery were seen with arteriography. Magnetic resonance imaging was done when she was 19½ years old because she had severe headaches and chronic hypertension (198/100 mm Hg). Magnetic resonance imaging of the brain showed old watershed infarcts in the areas supplied by the left and right anterior and middle cerebral arteries. Magnetic resonance angiography (Fig. 1) demonstrated that the internal carotid arteries had fairly normal calibers in the cavernous parts but very narrow lumens in the supraclinoid parts at the bifurcation into anterior and middle cerebral arteries. The basilar artery was narrow. Multiple small collateral vessels coursed from the external to internal circulations over the scalp, midface, skull base, and area adjacent to the incisura of the tentorium. The left vertebral artery originated from the aortic arch instead of from the subclavian artery. Magnetic resonance imaging showed normal caliber of the ascending and descending aorta. Mild dilatation of the left coronary and main pulmonary arteries was present. The peripheral pulmonary arteries had normal caliber. She has severe mental handicaps, functions at the level of an 8-year-old child, and has episodes of intense verbal and physical aggression.

Case 2. A 5-year-old boy was found in the neonatal period to have extensive, severe narrowing of the ascending and descending aorta; aortic arch; coronary, subclavian, common carotid, and pulmonary arteries; and to have a ventricular septal defect. At 25 months of age, 5 weeks after graft reconstruction of the aortic arch, he became more irritable and had a prolonged right-sided seizure. He then had right hemiparesis and loss of speech, which eventually improved after several months. Magnetic resonance imaging of the head demonstrated an acute left middle cerebral artery infarct (Fig. 2). At 34 months of age he had recurrent episodes of projectile vomiting together with headaches, irritability, and loss of consciousness, thought to be due to transient ischemia. Angiography when the patient was 40 months of age showed an abnormal, narrow common origin of the left common carotid and innominate arteries. The left middle cerebral artery was narrow, with diminished blood flow to the parietal and temporal areas. The left vertebral artery was very narrow. The entire posterior cerebral circulation was served by the right vertebral artery. Collateral vessels had developed.

DISCUSSION

Only three cases of Williams syndrome with cerebral artery narrowing, cerebrovascular insufficiency, acute decompensation, and strokes have been reported.¹⁻³ A 2-year-old boy, who had a viral infection, became unresponsive within 3 hours¹; magnetic resonance angiography showed stenoses of the left common carotid artery, midcervical areas of the internal carotid arteries bilaterally, and right internal carotid and posterior cerebral arteries. Collateral vessels connected the ophthalmic artery with cerebral arteries. Another 2-year-old boy had prolonged seizures and hemiplegia and was found to have narrow cerebral arteries.² An 18-year-old woman, who had the same diagnoses of Williams syndrome and Moyamoya as in case 1, died suddenly of an intraventricular hemorrhage.³ At autopsy the circle of Willis, inter-

nal carotid arteries, anterior and middle cerebral arteries, and ascending aorta were narrow. In our opinion, the vascular narrowing in this woman and in patient 1 was misclassified as Moyamoya.

The onset of clinical signs of cerebrovascular insufficiency in early childhood is ominous. The presence of collateral arteries in all the patients with cerebrovascular insufficiency suggests that the main cerebral vessels were narrow for long periods before the strokes occurred. No obvious precipitating causes of the acute decompensation were found. It is unlikely that chronic hypertension, acute infection, or thrombi or emboli precipitated the strokes. Cerebral arterial stenoses may be more prevalent in Williams syndrome than previously realized but may not be manifesting with acute cerebral infarction. For example, in the brain of a 31-year-old man who was severely retarded but without strokes or hemiplegia, intracortical patches of cell loss and gliosis were consistent with small vessel ischemia.⁴ Abnormal origin of arteries is another unusual aspect of the vascular anomalies in Williams syndrome.⁵

Narrowing of the carotid, cerebral, or vertebral arteries may cause serious, chronic morbidity in early childhood and

premature death. It may be the first problem demanding medical attention and must be considered in a child with Williams syndrome who suddenly becomes more irritable or has seizures with hemiparesis or severe hypertension. Conversely, the diagnosis of Williams syndrome should be considered in a child having a stroke or the manifestations described in our patients.

REFERENCES

1. Ardinger RH Jr, Goertz KK, Mattioli LF. Cerebrovascular stenoses with cerebral infarction in a child with Williams syndrome [Abstract]. *Am J Med Genet* 1994;51:200-2.
2. Grealley JM, Soper R, Chaloupka JC, et al. Multivessel cerebral arteriopathy causing stroke in Williams syndrome [Abstract]. *Am J Hum Genet* 1994;55:81A.
3. Kawai M, Nishikawa T, Tanaka M, et al. An autopsied case of Williams syndrome complicated by moyamoya disease. *Acta Paediatr Jpn* 1993;35:63-7.
4. Galaburda AM, Wang PP, Bellugi U, Rossen ML. Cytoarchitectonic anomalies in a genetically based disorder: Williams syndrome. *Neuroreport* 1994;5:753-7.
5. Ottesen OE, Antia AU, Rowe RD. Peripheral vascular anomalies associated with the supravalvular aortic stenosis syndrome. *Radiology* 1966;86:430-5.

Ischemic stroke and intracranial multifocal cerebral arteriopathy in Williams syndrome

Robert Soper, MD, John C. Chaloupka, MD, Pierre B. Fayad, MD,
John M. Grealley, MB, BCh, BAO, Bennett A. Shaywitz, MD,
Issam A. Awad, MD, and Barbara R. Pober, MD

From the Departments of Genetics, Diagnostic Radiology and Neurosurgery, Neurology, Pediatric Neurology, and Neurovascular Surgery, Yale University, New Haven, Connecticut

We describe an otherwise healthy 2-year-old patient with Williams syndrome who had a stroke as a result of intracranial multivessel focal and segmental stenotic disease. The diagnosis of Williams syndrome was confirmed by elastin gene deletion testing. Combined magnetic resonance imaging and magnetic resonance angiography, and transcranial Doppler flow studies, were used in diagnosing and monitoring the course of the disease. (J PEDIATR 1995;126:945-8)

Submitted for publication Nov. 7, 1994; accepted Feb. 8, 1995.

Reprint requests: Robert Soper, MD, Department of Genetics, Yale University School of Medicine, P.O. Box 208005, New Haven, CT 06520-8005.

Copyright © 1995 by Mosby-Year Book, Inc.
0022-3476/95/\$3.00 + 0 9/22/64038

Williams syndrome is a genetic disorder with manifestations including vasculopathy, originally described as supravalvular aortic stenosis¹ but now recognized to involve many areas of the arterial circulation.² We describe a 2-year-old boy with WS and ischemic stroke resulting from multifocal intracranial arterial stenoses without discernable premor-