

# The Vasculopathy of Varicella-Zoster Virus Encephalitis

Catherine Amlie-Lefond, MD,\* Bette K. Kleinschmidt-DeMasters, MD,\*† Ravi Mahalingam, PhD,\*  
Larry E. Davis, MD,‡ and Donald H. Gilden, MD\*§

Varicella-zoster virus (VZV) encephalitis has become more prevalent in the era of acquired immunodeficiency syndrome and other immunosuppressive diseases and poses diagnostic and therapeutic challenges for clinicians, radiologists, and pathologists. Six cases studied at our institutions shed light on the patterns and pathogenesis of the disease. VZV encephalitis is predominantly a vasculopathy, involving small and large vessels, that generates seizures, mental changes, and focal deficits. Brain imaging reveals large and small ischemic or hemorrhagic infarcts, often both, of cortex and subcortical gray and white matter. Deep-seated white matter lesions often predominate and are ischemic and/or demyelinative, depending on the size of blood vessels involved and the amount of additional demyelination caused by infection of oligodendrocytes. The demyelinative lesions are smaller and less coalescent than those seen in progressive multifocal leukoencephalopathy.

Amlie-Lefond C, Kleinschmidt-DeMasters BK, Mahalingam R, Davis LE, Gilden DH. The vasculopathy of varicella-zoster virus encephalitis. *Ann Neurol* 1995;37:784-790

Diverse lesions develop after acute virus infection of the central nervous system (CNS) and depend in large part upon the cell type infected by virus. Necrosis follows infection of neurons by poliovirus, rabies, and togaviruses [1]; fatal choriomeningitis develops after infection of choroid plexus, meninges, and ependyma by lymphocytic choriomeningitis virus [2]; demyelination occurs after lytic infection of oligodendrocytes by papovavirus [3]; and a hemorrhagic encephalopathy is produced by parvovirus infection of endothelial cells [4]. In varicella-zoster virus (VZV) encephalitis, the pathologic changes of vasculopathy leading to ischemic/hemorrhagic infarction and demyelination suggest that VZV is capable of infecting multiple cell types. To study the pathogenesis of disease, we combined clinical, radiologic, pathologic, and virologic studies of 6 patients with VZV encephalitis.

## Case Histories

### Subject 1

A 54-year-old man with a 5-month history of Wegener's granulomatosis, *Pneumocystis carinii* infection, and renal insufficiency, taking cyclophosphamide (150 mg/day) and prednisone (80 mg/day), developed progressive leg weakness and numbness, difficulty urinating, and constipation over a month. He had experienced purpuric rash from Henoch-Schönlein disease. There was no history of zoster. Neurologic examination revealed spastic left leg weakness, a T12

sensory level to touch and pain, hyperactive leg reflexes, and bilateral extensor plantar responses. Spinal cord magnetic resonance imaging (MRI) showed increased nonenhancing signal at T10-T11 without mass effect. The CSF contained 18 mononuclear cells/mm<sup>3</sup>, a protein level of 51 mg%, and a glucose level of 62 mg%. Two months later, he had three generalized seizures and was in a nonketotic hyperglycemic state with a serum glucose level of 1,064 mg%. An electroencephalogram showed generalized slowing and left hemisphere sharp waves. Brain MRI revealed multiple hyperintense nonenhancing white matter lesions in both hemispheres (Fig 1). One month later, brain MRI again showed multiple, bilateral white matter hyperintensities, as well as a left thalamic lesion, many of which enhanced. One month later, he developed fever and lethargy. Diffuse infiltrates were seen on chest x-ray. A right frontal lobe brain biopsy revealed ovoid, predominantly demyelinative lesions (Fig 2) with minimal endothelial proliferation and numerous Cowdry A inclusions in glia at the perimeter of the lesions (Fig 3). Indirect immunoperoxidase staining of the biopsy identified VZV but not herpes simplex virus (HSV) antigen. In situ hybridization (ISH) demonstrated VZV DNA but not HSV DNA (Fig 4). The patient died of pneumonia 2 months later. Permission for an autopsy was denied.

### Subject 2

A 30-year-old man with acquired immunodeficiency syndrome (AIDS) and a CD4 count of 4 began falling to the right. A head computed tomographic (CT) scan was normal.

From the Departments of \*Neurology, †Pathology, and §Microbiology, University of Colorado Health Sciences Center, Denver, CO; and ‡Neurology Service, Albuquerque VA Medical Center, and Department of Neurology, University of New Mexico School of Medicine, Albuquerque, NM.

Received Nov 16, 1994, and in revised form Feb 9, 1995. Accepted for publication Feb 9, 1995.

Address correspondence to Dr Amlie-Lefond, Department of Neurology, Box B-182, University of Colorado Health Sciences Center, 4200 East 9th Avenue, Denver, CO 80262.

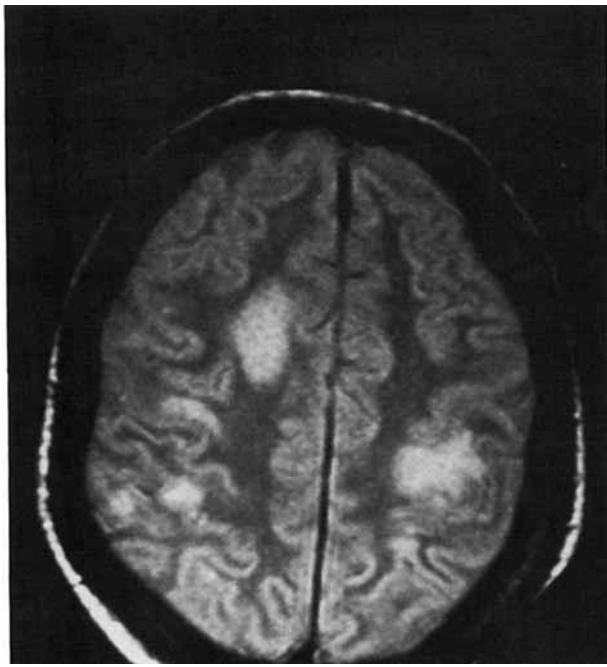


Fig 1. Proton-density head magnetic resonance imaging scan of Subject 1 demonstrates multiple discrete lesions in both hemispheres, primarily involving white matter, and extending to gray-white matter junctions.

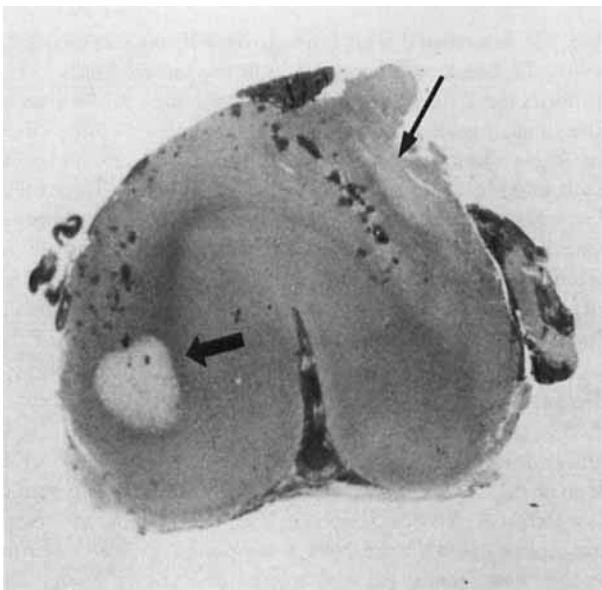


Fig 2. Whole-mount section of cortical biopsy from Subject 1 shows a well-demarcated ovoid demyelinated lesion at the cortical gray-white matter junction (thick arrow). One edge of a larger plaque is seen at the lower left (thin arrow). (Hematoxylin and eosin,  $\times 5$ .)

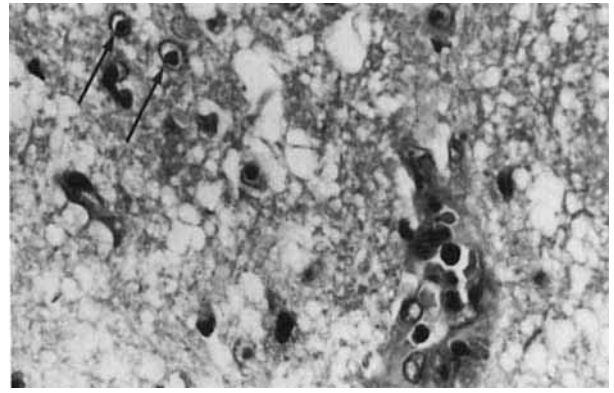


Fig 3. Brain biopsy from Subject 1 reveals multiple Cowdry A inclusion bodies (arrows).

Cerebrospinal fluid (CSF) contained 27 red blood cells (RBCs), 10 white blood cells (WBCs) (52% polymorphonuclear leukocytes and 48% mononuclear), a protein level of 83 mg% and a glucose level of 57 mg%. Herpes zoster was present on the left buttock. He was treated with acyclovir, 800 mg intravenously, every 6 hours for 9 days, followed by 800 mg orally four times daily for 13 days. Four months later, he developed left-sided neglect, progressive left-sided weakness and decreased sensation, and left facial weakness. There was no rash. Neurological examination revealed a left homonymous hemianopsia, mild left central facial weakness, a mild left hemiparesis with normal tone, decreased sensation, and brisk deep-tendon reflexes on the left. The left plantar response was extensor. A head CT scan revealed focal hemorrhage or hemorrhagic infarction and edema in the right posterior temporal and parietal lobes. A head MRI scan demonstrated a large hemorrhagic lesion and multiple small areas of hemorrhage in both hemispheres (Fig 5). Carotid artery duplex ultrasound and MRI angiogram of the head were normal. The CSF contained 428 RBCs, no WBCs, a protein level of 56 mg% and a glucose level of 80 mg%. Cryptococcal antigen and cultures of the CSF were negative. Polymerase chain reaction (PCR) revealed VZV DNA, but not HSV or cytomegalovirus DNA, in both CSF and in blood mononuclear cells (MNCs). Antibody to VZV was present in CSF. He was treated with intravenous acyclovir, 800 mg every 8 hours for 2 weeks, and dexamethasone 6 mg intravenously every 4 hours for 7 days, then 2 mg intravenously every 6 hours for 1 day, then 1 mg intravenously every 6 hours for 1 day, and then an oral prednisone taper over 5 days. At the time of discharge, there was residual cognitive impairment and a left hemiparesis. He was then treated with acyclovir, 800 mg orally three times daily, which has been continued indefinitely. He is currently neurologically stable 5 months later.

### Subject 3

A 29-year-old man with AIDS developed left-sided weakness and intermittent garbled speech. Eight months earlier, he had experienced lumbosacral distribution zoster. A head CT scan revealed enhancing lesions in the posterior limb of the right

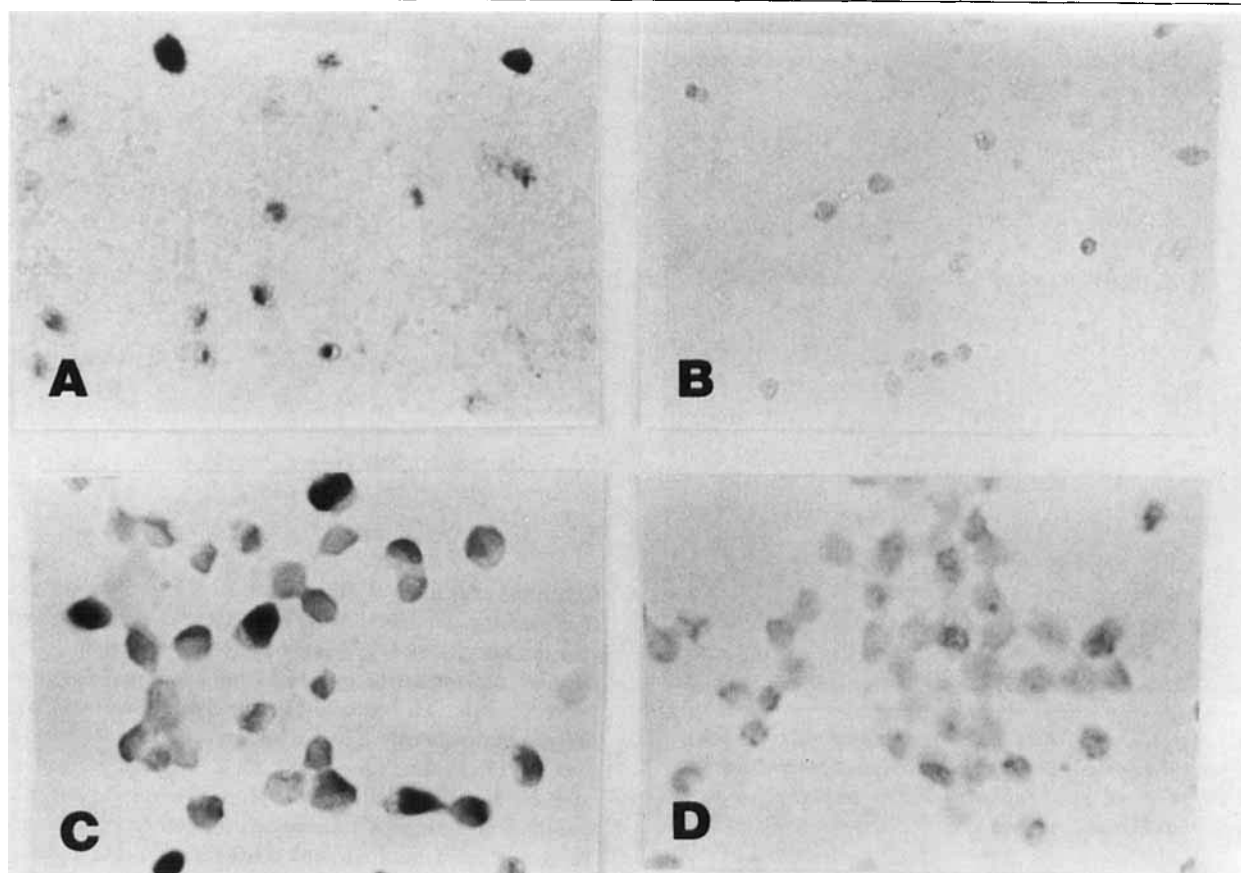


Fig 4. Numerous positive dark cells are seen after *in situ* hybridization of a varicella-zoster virus (VZV)-specific riboprobe to brain biopsy from Subject 1 (A) and to VZV-infected BSC-1 cells (C), but not after hybridization to normal human brain (B) or uninfected BSC-1 cells (D).

internal capsule and both sylvian fissures, and a brain MRI scan revealed large and small areas of infarction in superficial and deep areas of the right hemisphere including the splenium of the corpus callosum (Fig 6). The CSF was acellular and contained a protein level of 85 mg% and a glucose level of 39 mg%. CSF cultures for bacteria, fungi, and acid-fast bacilli (AFB) were negative. A transthoracic echocardiogram and the following laboratory studies were normal: prothrombin time (PTT), protein C and S, anti-thrombin III, anti-cardiolipin antibody, antinuclear antibody (ANA), rheumatoid factor, hepatitis B surface antigen, and serum rapid plasma reagin (RPR). A few weeks later, he developed generalized tonic-clonic status epilepticus. He was febrile. Neurologic examination revealed a postictal state but no focal deficit. A head CT scan revealed low-density nonenhancing lesions in the right internal capsule and parietal lobe, most consistent with infarction. The CSF was acellular and contained a protein level of 70 mg% and a glucose level of 58 mg%. Gram stains and cultures for bacteria, fungus, and AFB were negative. Fever continued, he remained obtunded, and developed left-sided weakness. A brain MRI scan revealed nonenhancing high signal intensity on T1-weighting in the medial right occipital lobe and posterior limb of the right internal capsule. He developed upper gastrointestinal bleed-

ing. He was treated with gancyclovir, 350 mg intravenously every 12 hours, and acyclovir, 700 mg intravenously every 8 hours for 2 days before death. Pathologic examination of the brain revealed acute and subacute arteritis of the circle of Willis vasculature with fibrinoid necrosis, luminal occlusion, and MNC inflammation without herpetic inclusions (Fig 7). Ischemic infarctions of the right basal ganglia, internal capsule, and occipital lobe were seen, with a collar of demyelination and Cowdry A inclusions in glia surrounding the occipital lesion. ISH detected VZV nucleic acid in the mixed ischemic-demyelinative occipital lobe lesion.

#### Subject 4

A 33-year-old man with AIDS and a history of recurrent zoster developed chronic progressive fatal encephalitis. A CT scan of the brain 1 month before death revealed deep-seated low-density enhancing lesions in both basal ganglia and internal capsules, and a brain MRI 1 week later revealed necrosis in the basal ganglia and hydrocephalus. Pathologic examination of the brain revealed necrosis in the basal ganglia bilaterally and periventricular necrosis. Vascular thromboses were present in most necrotic areas, and necrotic and demyelinating lesions were admixed throughout the cortical white matter. Vacuolation and demyelination were seen at the edge of many of the larger necrotic lesions. Cowdry A inclusions were seen in glia and in ependymal cells lining the 4th ventricle and VZV was demonstrated by Southern blot analysis on tissue from basal ganglia, internal capsule, and pons [5].

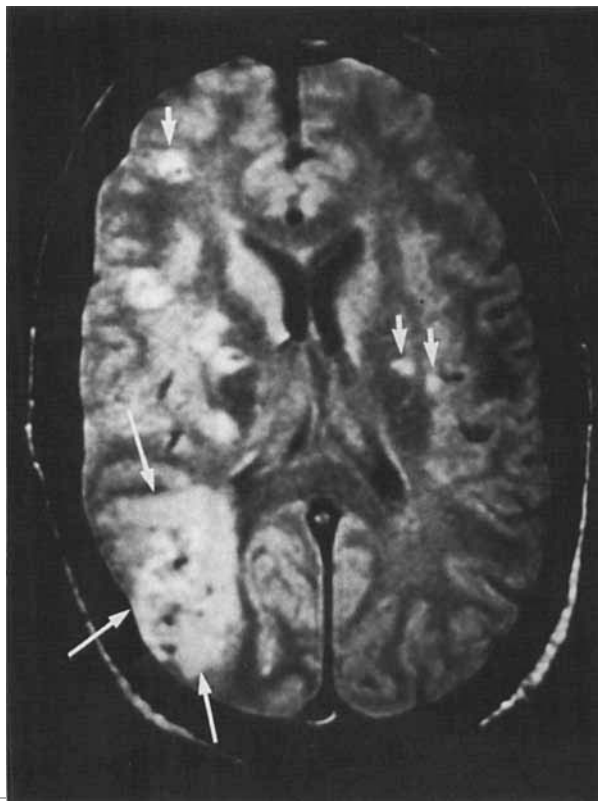


Fig 5. Head magnetic resonance imaging scan of Subject 2 reveals a large hemorrhagic lesion in the right temporoparietal region (long arrows); smaller deep-seated hemorrhagic lesions are seen in both hemispheres (short arrows).

#### Subject 5

A 69-year-old woman with a history of steroid-dependent asthma and hypertension developed a brachial plexitis. Three months later, she developed C8- and T3-distribution zoster, followed 3 days later by an acute encephalitis with seizures and coma. A brain MRI revealed multifocal subcortical lesions in both white and gray matter. She died 4 weeks later. Pathologic examination of the brain, brainstem, and cerebellum revealed large bland and hemorrhagic infarcts coupled with small patchy ovoid predominantly necrotic lesions, scattered throughout white matter, in both motor strips, more so on the left, and predominantly near gray-white matter junctions. Smaller lesions in the brain and cerebellum were noteworthy for their perivascular orientation. Demyelination was minimal, and a paucity of glial Cowdry A inclusions was seen, although indirect immunoperoxidase staining using rabbit anti-VZV serum (courtesy of Dr J. R. Martin) revealed VZV antigen [6].

#### Subject 6

A 37-year-old man with AIDS and a history of recurrent bilateral zoster developed chronic progressive fatal encephalitis. A CT scan of the brain 1 month before death showed an expanding, low-density, nonenhancing lesion in the right cerebellar hemisphere. Pathologic examination revealed no

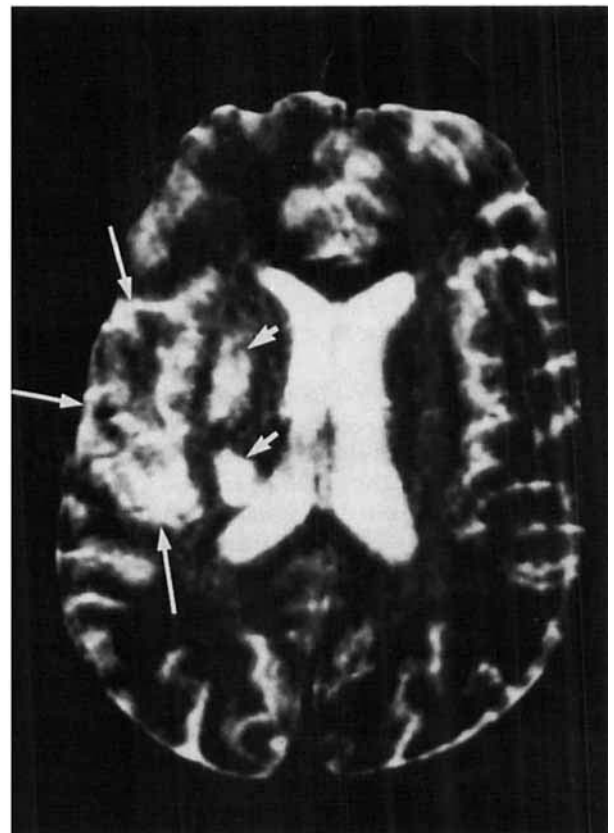


Fig 6. Although movement artifacts make definitive interpretation impossible, a T2-weighted head magnetic resonance imaging scan of Subject 3 shows a distinct large area of hyperintensity in the right inferoposterior temporal region (long arrows) and two deep-seated lesions in the region of the lentiform nucleus (short arrow) and posterior white matter (short arrow).

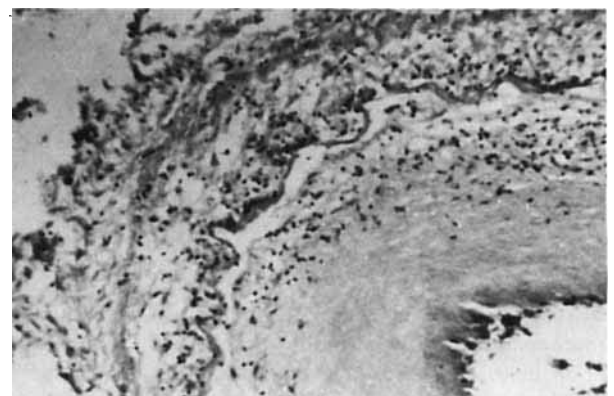


Fig 7. Artery at base of brain from Subject 3 shows subacute arteritis with intimal proliferation, mononuclear cell inflammation, and intact elastic lamina. (Hematoxylin and eosin,  $\times 400$  before 33% reduction.)

cerebral infarctions, but periventriculitis surrounding the left temporal and occipital horns was seen. At the gray-white matter junction of the cortex, particularly at the left motor strip, ovoid demyelinating lesions with central capillary proliferation and macrophage influx were present, surrounded by vacuolation and numerous glia containing Cowdry A inclusions. Peroxidase-antiperoxidase staining with rabbit polyclonal antiserum to VZV (Dr S. Straus) was positive and VZV DNA in brain was confirmed by Southern blot analysis of frozen temporal lobe and cerebellum [7].

## Materials and Methods

### Preparation of Riboprobes

**HSV-1 PROBE.** The HSV-1 *Bam*HI-*Sal*I DNA fragment (2.3 kb), which contains a portion of the HSV glycoprotein B coding region, was subcloned from a 4.0-kb *Bam*HI-*Xho*I fragment into the pGEM transcription vector. The recombinant clone was linearized using *Hind*III and digoxigenin-labeled RNA probes were synthesized using a Genius RNA labeling kit (Boehringer Mannheim, Indianapolis, IN).

**VZV PROBE.** For PCR amplification, oligonucleotide primers specific for VZV gene 40 were selected from the published sequence [8]. The VZV U<sub>L</sub>40 primer A (5'-ACTCATTGTAACGAGGCACTGC-3') is located between nucleotides 72096 and 72117, and primer B (5'-TGAATCGGAGTTGGATTGTGG-3') is located between nucleotides 72626 and 72646 on the VZV genome. Bacteriophage T7 RNA polymerase primer sequences (5'-TGTAATACGACTCACTATAGGGCGA-3') were linked to VZV gene 40 primer A. This primer pair was used to amplify a 550-bp DNA fragment with T7 RNA polymerase promoter at one end. The PCR product was cleaned using a QIAquick PCR purification kit (QIAGEN Inc, Chatsworth, CA). Digoxigenin-labeled RNA probes were synthesized from the PCR product using a Genius RNA labeling kit (Boehringer Mannheim).

**FRAGMENTATION OF PROBES.** An equal volume of 60 mM sodium carbonate and 40 mM sodium bicarbonate, pH 10.2, was added to the digoxigenin-labeled RNA probes. Incubation was at 60°C for 10 minutes, followed by the addition of an equal volume of 200 mM sodium acetate, 1% (vol/vol) acetic acid, pH 6.0.

**PRETREATMENT.** Brain tissue sections were deparaffinized in xylenes twice for 5 minutes each time, rehydrated in graded alcohols, and washed in water followed by phosphate-buffered saline two times for 5 minutes each time. Tissue sections were then treated with proteinase K (20 µg/ml) for 15 minutes at 55°C in 0.02 M Tris-HCl, pH 7.4, and 0.002 M CaCl<sub>2</sub>, washed twice in water, treated for 10 minutes at room temperature with freshly prepared 0.25% acetic anhydride in 0.1 M triethanolamine HCl, pH 8.0, and 0.9% NaCl, and dehydrated in graded alcohols. After delipidation in chloroform for 5 minutes at room temperature, sections were washed in 100% ethanol and in 95% ethanol for 1 to 2 minutes each time, air-dried, and stored at room temperature until use.

**ISH.** ISH using riboprobes was performed as described by Smith and colleagues [9] with the following modifications. Hybridization solution containing 10 ng of riboprobe in 10% dextran sulfate, 50% formamide, 1× Denhardt's solution, 4× saline-sodium citrate (SSC), 10 mM dithiothreitol, 1 mg/ml tRNA, 2 mM EDTA, and 1,000 U/ml RNasin (Promega, Madison, WI) was placed on top of the tissue section, which was covered with a glass coverslip and sealed with grease to prevent evaporation. Each section was denatured at 95°C for 5 minutes, hybridized overnight at 52°C in a humid chamber, washed twice with 4× SSC, once with 2× SSC in 50% formamide at 50°C for 45 minutes, rinsed twice in RNase buffer (20 mM Tris, pH 8.0, 500 mM NaCl, 1 mM EDTA), treated with a mixture of RNase A (40 µg/ml) and RNase T1 (10 U/ml) in RNase buffer, and washed with 2× SSC in 50% formamide at 50°C for 45 minutes. Immunodetection of digoxigenin was performed according to the Genius detection kit (Boehringer Mannheim) using alkaline phosphatase-conjugated antibody and colorimetric development for 1 to 16 hours. Positive and negative controls for each virus probe included normal human brain, uninfected, VZV-infected, and HSV-1-infected BSC-1 (African green monkey kidney) cells.

## Results and Discussion

We describe 6 cases of VZV encephalitis, 4 in AIDS patients and 2 in patients being treated with cyclophosphamide and steroids or only steroids. Pathologic or virologic studies verified that all cases were caused by VZV. Zoster occurred days to months before encephalitis in 5 patients and was recurrent in 2 of these 5 patients. VZV encephalitis developed once without any history of rash. Encephalitis was characterized by fever, seizures, focal deficit, and mental status changes. Brain imaging revealed multifocal lesions, some of which enhanced, in the distribution of large and small arteries, most consistent with infarction. Both ischemic and hemorrhagic lesions were seen. Pathologically, the lesions in all 6 cases were a combination of ischemia and demyelination. Infarction in the distribution of large arteries was accompanied by large vessel arteritis (Subject 3). Deep-seated infarction, often with demyelination, was secondary to small artery vasculopathy, which was characterized by endothelial swelling and scant chronic inflammation. The smaller demyelinating lesions in these patients usually included the presence of Cowdry A inclusions in glia at the periphery of lesions.

Early reports of VZV vasculopathy emphasized large vessel disease, which typically produced stroke weeks to months after trigeminal or cervical distribution zoster. Imaging and pathologic studies of these cases of "herpes zoster ophthalmicus," "granulomatous angiitis," or "vasculitis" revealed infarction in the distribution of the carotid, middle cerebral, anterior cerebral, and basilar arteries [10, 11]. Such large vessel infarctions were seen in Subjects 1 to 3.

While the large infarctions that follow trigeminal or cervical distribution zoster are usually ischemic [12] and only rarely hemorrhagic [13], an even mix of ischemic and hemorrhagic infarction was seen in our patients with VZV encephalitis. In fact, clinical and radiologic evidence of multifocal ischemic and hemorrhagic infarction should suggest the possibility of VZV infection.

In contrast to the abundance of reports of large vessel disease produced by VZV, the small vessel vasculopathy that leads to a leukoencephalopathy and demyelination was not appreciated until Horten and co-workers [14] first described fatal VZV encephalitis in patients with cancer. This was later confirmed by Morgello and associates [15]. Pathologically, these cases are characterized by multifocal small lesions, usually deep-seated, involving white matter more than gray matter, and often concentrated at gray–white matter junctions. Horten and co-workers [14] and Morgello and colleagues [15] emphasized the demyelinating nature of small lesions and relative preservation of axons. Gray and collaborators [16], on the other hand, noted necrotic features. Our cases illustrate that both demyelination and necrosis can be produced by small vessel vasculopathy (“multifocal leukoencephalitis”). Many smaller lesions in our patients had at least a demyelinating component and had Cowdry A inclusions in glia at the periphery of lesions. While the absence of Cowdry A viral inclusions in purely infarctive lesions can pose diagnostic difficulties for the pathologist, the combination of ischemic and demyelinating lesions in the same brain suggests VZV as the cause. The smaller, ovoid, less coalescent demyelinating lesions in VZV contrast with progressive multifocal leukoencephalopathy (PML), in which infarction is not seen, and viral inclusions develop only in oligodendrocytes, fill their nuclei, and usually do not give a Cowdry A halo appearance. PML also displays bizarre pleomorphic astrocytes that are not found in VZV encephalitis.

The presence of multifocal gray–white matter junction lesions suggests that VZV may spread hematogenously. However, the same multifocal gray–white matter junction lesions were also seen in an AIDS patient who developed encephalitis, and in whom pathologic and virologic evidence of VZV was found in the eye, the optic chiasm, the lateral geniculate bodies, and the occipital cortex, strongly indicating anterograde spread of VZV through the visual system [16]. A possible explanation for gray–white matter junction lesions after primary involvement of visual pathways is that transaxonal spread of virus from the eye to the brain may be followed by local virus infection of small blood vessels, ultimately leading to ischemic infarction and necrosis. Our pathologic examination of the spinal cords of Subjects 5 and 6 also suggests that, in some

cases, VZV enters the CNS via axonal spread from dermatomal zoster. Dorsal root ganglionitis develops, followed by dorsal nerve root inflammation and degeneration, and by destruction of dorsal gray and, to a lesser extent, ventral gray matter of the spinal cord. The small blood vessels might be infected focally at the spinal cord level, with the virus spreading hematogenously leading to local and more distant ischemic infarction. Alternatively, and in keeping with the report of Rostad and colleagues [17], transaxonal spread within the CNS might occur. In Subjects 5 and 6, the motor strip in the cerebral cortex showed prominent lesions, raising the possibility of retrograde transaxonal spread via the corticospinal tract from the spinal cord anterior gray matter. In this scenario, spread into small blood vessels at the motor strip might yield the ischemic and ischemic/demyelinating lesions. In Case 3, where the central portion of lesions appeared ischemic and the perimeter demyelinating, an initial vasculopathy and blood vessel infection by VZV followed by later oligodendrocyte infection is possible. Although virus was not demonstrated in endothelial cells in our cases by the presence of inclusions or by ISH, perhaps due to the temporal sequence of disease, the recent demonstration of VZV antigen in walls of small cerebral blood vessels of a patient with VZV brainstem encephalitis [18] supports the notion that small blood vessels can be infected by VZV directly and may serve as the cause for small ischemic lesions in brain.

In summary, VZV encephalitis in immunocompromised individuals usually develops concurrent with rash or weeks to months after acute herpes zoster and is characterized by mental status changes and multifocal neurologic deficits. Radiographic studies reveal a spectrum of lesions, from ischemic/hemorrhagic infarctions of varying size, depending on the caliber of blood vessel involved, to small ovoid lesions with mixed ischemic/demyelinating or predominantly demyelinating pathology. The radiologic detection of both infarctive (ischemic or hemorrhagic) and demyelinating lesions in an immunocompromised patient with or without a history of zoster rash should suggest the diagnosis of VZV encephalitis. These features differ from PML, which has no infarctive component and usually produces more coalescent and larger zones of demyelination than VZV encephalitis. The detection of VZV DNA in CSF by PCR can confirm the diagnosis rapidly. Pathologically, the combination of ischemic and demyelinating features should strongly prompt consideration of VZV encephalopathy. In purely infarctive lesions, characteristic Cowdry A inclusions may be scant or absent, and a search for more demyelinating or mixed lesions should be undertaken. Both transaxonal and vascular spread are likely to be important in producing VZV encephalitis.

This work was supported in part by PHS grants AG 06127 and NS 32623 from the NIH, and the Research Service, Department of Veterans Affairs. Dr Amlie-Lefond is the recipient of NIH Training Grant NS 07321 in Neurovirology-Molecular Biology.

We thank Drs Mario Kornfeld and Anna Phelps for neuropathological assistance, Nancy Hart and Cathy Allen for preparing the manuscript, Bob McCullough for photographic assistance, and Marina Hoffman and Mary Devlin for editorial review.

## References

1. Nathanson N, Cole GA, Weiner LP, et al. Diversity of pathological lesions produced by acute virus infections of the nervous system. In: Proceedings of the VIth international congress of neuropathology. Paris: Masson et Cie, 1970:876-891
2. Gilden DH, Cole GA, Monjan AA, Nathanson N. Immunopathogenesis of acute central nervous system disease produced by lymphocytic choriomeningitis virus. I. Cyclophosphamide-mediated induction of the virus-carrier state in adult mice. *J Exp Med* 1972;135:860-873
3. Padgett BL, Walker DL, ZuRhein GM, Eckroade RJ. Cultivation of papova-like virus from human brain with progressive multifocal leukoencephalopathy. *Lancet* 1971;1:1257-1260
4. Baringer JR, Nathanson N. Parvovirus hemorrhagic encephalopathy of rats: electron microscopic observations of the vascular lesions. *Lab Invest* 1972;27:514-522
5. Gilden DH, Murray RS, Wellish M, et al. Chronic progressive varicella-zoster virus encephalitis in an AIDS patient. *Neurology* 1988;38:1150-1153
6. Gilden DH, Dueland AN, Cohrs R, et al. Preherpetic neuralgia. *Neurology* 1991;41:1215-1218
7. Ryder JW, Croen K, Kleinschmidt-DeMasters BK, et al. Progressive encephalitis three months after resolution of cutaneous zoster in a patient with AIDS. *Ann Neurol* 1986;19:182-188
8. Davison AJ, Scott JE. The complete DNA sequence of VZV. *J Gen Virol* 1986;67:1759-1816
9. Smith RL, Escudero JM, Wilcox CL. Regulation of the HSV latency-associated transcripts during establishment of latency in sensory neurons in vitro. *Virology* 1994;202:49-60
10. Fukumoto S, Kinjo M, Hokamura K, Tanaka K. Subarachnoid hemorrhage and granulomatous angiitis of the basilar artery: demonstration of the varicella-zoster virus in the basilar artery lesions. *Stroke* 1986;17:1024-1028
11. Hilt DC, Buchholz D, Krumholz A, et al. Herpes zoster ophthalmicus and delayed contralateral hemiparesis caused by cerebral angiitis: diagnosis and management approaches. *Ann Neurol* 1983;14:543-553
12. Kuroiwa Y, Furukawa T. Hemispheric infarction after herpes zoster ophthalmicus: computed tomography and angiography. *Neurology* 1981;31:1030-1032
13. Eible RJ. Intracerebral hemorrhage with herpes zoster ophthalmicus. *Ann Neurol* 1983;14:591-592
14. Horten B, Price RW, Jimenez D. Multifocal varicella-zoster virus leukoencephalitis temporally remote from herpes zoster. *Ann Neurol* 1981;9:251-266
15. Morgello S, Block GA, Price RW, Petito CK. Varicella-zoster virus leukoencephalitis and cerebral vasculopathy. *Arch Pathol Lab Med* 1988;112:173-177
16. Gray F, Bélec L, Lescs MC, et al. Varicella-zoster virus infection of the central nervous system in the acquired immune deficiency syndrome. *Brain* 1994;117:987-999
17. Rostad SW, Olson K, McDougall J, et al. Transsynaptic spread of varicella zoster virus through the visual system: a mechanism of viral dissemination in the central nervous system. *Hum Pathol* 1989;20:174-179
18. Schmidbauer M, Budka H, Pilz P, et al. Presence, distribution and spread of productive varicella zoster virus infection in nervous tissues. *Brain* 1992;115:383-398