

CASE REPORT

Seizures and 'disappearing' brain lesions

T. HEMANTH RAO, RICHARD B. LIBMAN & MAHENDRA PATEL*

*Departments of Neurology and *Radiology, Long Island Jewish Medical Center, The Long Island Campus for The Albert Einstein College of Medicine, New Hyde Park, New York, USA.*

Address correspondence to: Richard B. Libman, MD, The Department of Neurology, Long Island Jewish Medical Center, New Hyde Park, NY 11042, USA.

Background—Patients with seizures may have abnormal brain imaging. Lesions demonstrated on computerized tomography or magnetic resonance imaging often suggest the underlying cause of the seizures, and may prompt an invasive investigation for diagnosis and treatment. In an increasingly recognized subset of patients however, the imaged lesions spontaneously resolve. While poorly understood, these 'disappearing' lesions may in fact be the consequence of seizures, rather than the cause. Two patients with 'disappearing' lesions are presented: the first patient had a proven cause, the second a probable one.

Case 1. A patient with new onset seizures had an abnormal MRI. An angiogram confirmed thrombosis of the straight sinus. On follow-up, she was doing well; repeat imaging was normal with resolution of the lesion.

Case 2. A patient with a long seizure history had been well controlled on medications, and had no change in frequency of her seizures. She was found to have a left homonymous hemianopsia. MRI revealed a right parieto-occipital lesion. The patient refused further work-up and was lost to follow-up. She returned almost a year later; repeat imaging was normal.

Conclusion—Patients with seizures and abnormal imaging suggestive of structural lesions may occasionally have lesions that resolve spontaneously. While some diagnoses remain elusive, an important consideration to exclude in these patients is venous thrombosis.

Key words: seizures; epilepsy; cysticercosis; venous thrombosis.

In patients with seizures, focal abnormalities on computerized tomography (CT) or magnetic resonance imaging (MRI) prompt further investigation to determine whether or not these lesions are causative. In most cases, these lesions persist unless specific therapeutic interventions are undertaken. Rarely, lesions disappear spontaneously and are believed to be the consequence of seizures. They may represent metabolic disturbances that occur around a seizure focus^{1–3}. Disappearing lesions may have other aetiologies, however^{4–6}. We report two patients with seizures and lesions on MRI that spontaneously disappeared, but which were apparently not caused by seizures. Recognition of this poorly understood entity may change the approach to some seizure patients with abnormal imaging.

PATIENT 1

A 43-year-old woman without a significant past medical history was referred to our institution after a first generalized seizure. She was reportedly in her usual state of good health the day of admission, when she suddenly lost consciousness. Her family noted that her eyes rolled upward and she developed shaking of all her extremities, which lasted between 1 and 2 minutes. This was associated with urinary incontinence, but there was no tongue biting, faecal incontinence or any other associated features. She denied similar episodes in the past. She was taken to her family doctor who obtained an MRI scan and referred her to our institution. In the emergency room she was without complaints. On general examination

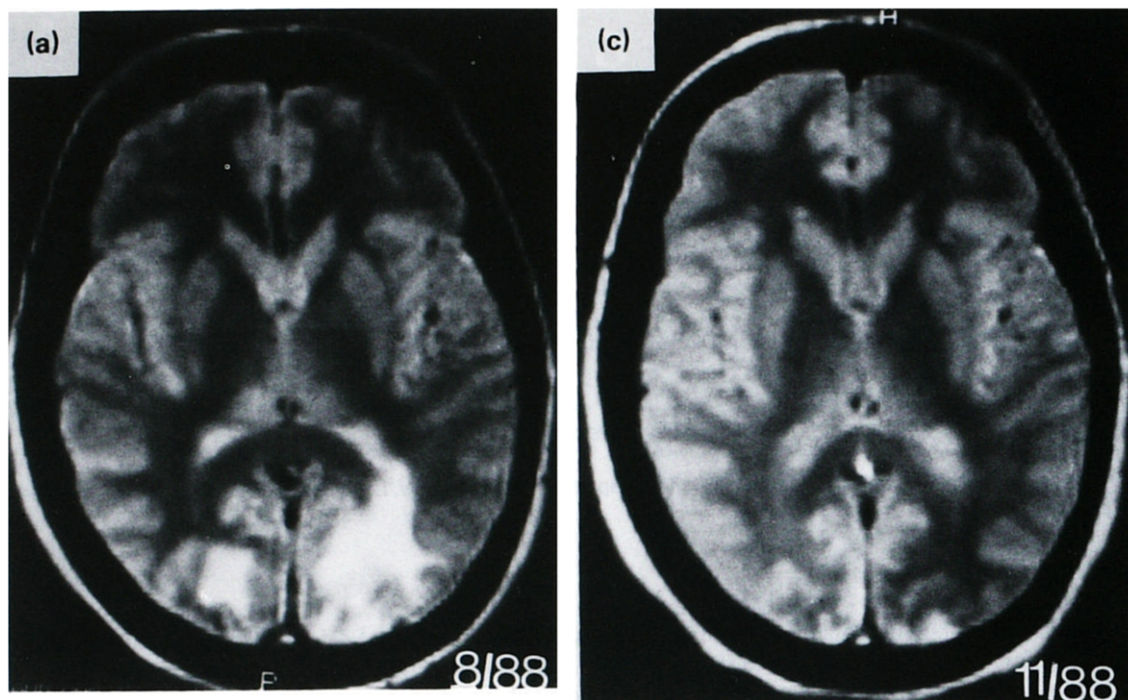


Fig. 1: (a) Initial T2-weighted MRI showing abnormal signal in bilateral occipital regions. (b) Cerebral angiogram showing straight sinus thrombosis (L-enlarged vein of Labbé; small arrows—presumed location of thrombosed straight sinus; large arrow—thrombosis extending to torcular Herophili). (c) MRI 9 weeks later.

she was afebrile, normotensive, and her neck was supple without adenopathy. The rest of her general physical exam was normal. Her neurological examination was normal.

Routine laboratory investigations including a complete blood count, chemistry panel, liver function tests, kidney function tests and coagulation profile were within normal limits. Her

T-2 weighted MRI scan revealed two areas of increased signal in both parieto-occipital areas, confined mostly to white matter (Fig. 1(a)). A cerebral arteriogram was done because of the peculiar distribution of the lesions, which confirmed a straight sinus thrombosis (Fig. 1(b)).

The patient was started on carbamazepine

and her hospital course was uneventful. On follow-up she remained asymptomatic. A repeat MRI scan obtained 8–9 weeks later was normal (Fig. 1(c)).

PATIENT 2

A 54-year-old woman had a long history of post-traumatic seizures, believed secondary to have been beaten with a baseball bat as a teenager. She was seen in clinic for routine follow-up. She reported an average seizure frequency of once or twice per year. Her seizures typically began with right-sided clonic jerks followed by secondary generalization. Her last seizure had been 12 days prior to evaluation, and had been relatively brief according to her family (less than 1 minute). This seizure was atypical because it was generalized from the outset without right-sided clonic movements. There had been no change in seizure type or frequency over the previous few years. She had been compliant with her anticonvulsant medication (phenytoin). There was no history of foreign travel, drug abuse, or recurrent trauma. Imaging studies in the past, including a CT scan done within the previous month were negative for acute structural pathology, showing only an area of encephalomalacia in the left parietal region, consistent with her history of trauma. The EEG showed only left fronto-parietal slowing; no focal spikes had ever been documented.

The general physical examination was normal without adenopathy or meningismus. Neurological examination was normal except for a left homonymous hemianopsia which had not been present on her examination 4 months previously. She underwent an MRI which, in addition to the previously documented area of encephalomalacia, revealed an area of increased signal in the right temporo-occipital region on proton density images, apparently confined to the white matter and without mass effect (Fig. 2(a)). A neoplastic or infectious lesion was suspected, but the patient refused further work-up and was lost to follow-up. One year later, she was re-evaluated. She remained asymptomatic, and the homonymous hemianopsia was no longer present. A repeat MRI showed virtually complete resolution of the abnormal signal (Fig. 2(b)). EEG was unchanged from her previous studies. She denied taking any medication other than her phenytoin or undergoing any diagnostic or

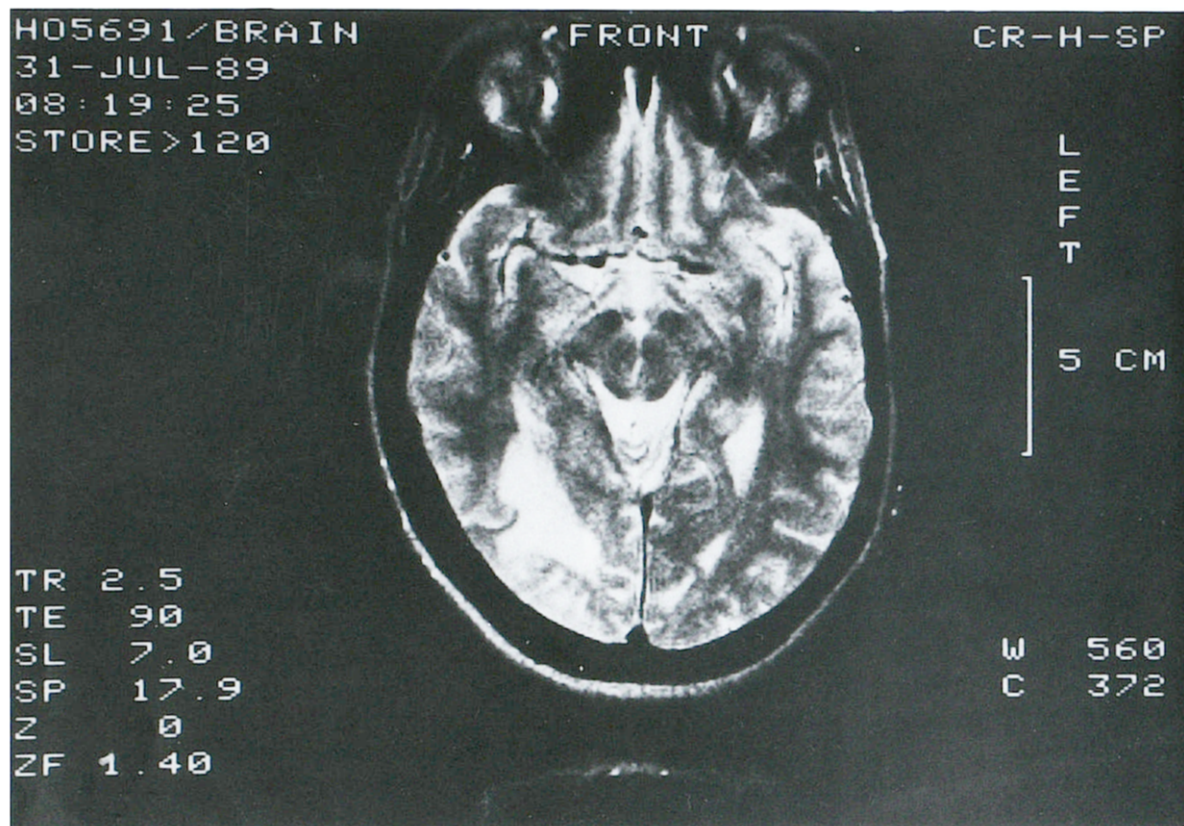
therapeutic procedures during the previous year.

DISCUSSION

Transient CT lesions that correlate with an ictal focus are thought to be secondary to a metabolic disturbance around the focus, resulting in abnormal vascular permeability and cerebral edema^{1–3}. These CT lesions have been reported with either repeated focal seizures^{1,2} or focal status epilepticus³. The location of the imaged lesion generally corresponds to the presumed seizure focus¹, which was not the case in our patients. These lesions disappear when the seizures are controlled with medications. The above mechanism of abnormal vascular permeability is also the most likely explanation for the reversible lesions seen in eclampsia^{5,6}. Our first patient had a documented straight sinus thrombosis as the presumed cause of her seizures and imaged lesions on MRI. These lesions were probably due to venous ischemia which did not progress to infarction because of rapid recanalization. Our second patient had a similar lesion on MRI scan, and she did not have prolonged or repeated focal seizures. Therefore, the postulate that seizures were the cause of our patient's lesion, while possible, seems unlikely. Another possible cause of disappearing lesions is thought to be cryptic angiomas that rupture. The signal characteristics of our patient's lesion were not suggestive of haemorrhage.

Self-limited focal encephalitis is a possible diagnosis in our second patient. Focal encephalitis secondary to a bacterial pathogen such as tuberculosis does not resolve without specific therapy, making that diagnosis highly improbable. The bulk of patients reported with disappearing lesions have been from the Indian subcontinent and Central or South America where cysticercosis is endemic. The reported lesions have typically been without mass effect². A certain percentage of patients with cysticercosis during the acute encephalitic phase do spontaneously resolve⁴ and spontaneous radiographic disappearance of cerebral cysticercosis has also been reported⁷. To attribute our patient's lesion to cysticercosis is difficult because she was not from an endemic area, and was without a history of travel to an endemic area, although sporadic cases of cerebral cysticercosis acquired in the United States have been documented^{8,9}. In our second

(a)



(b)

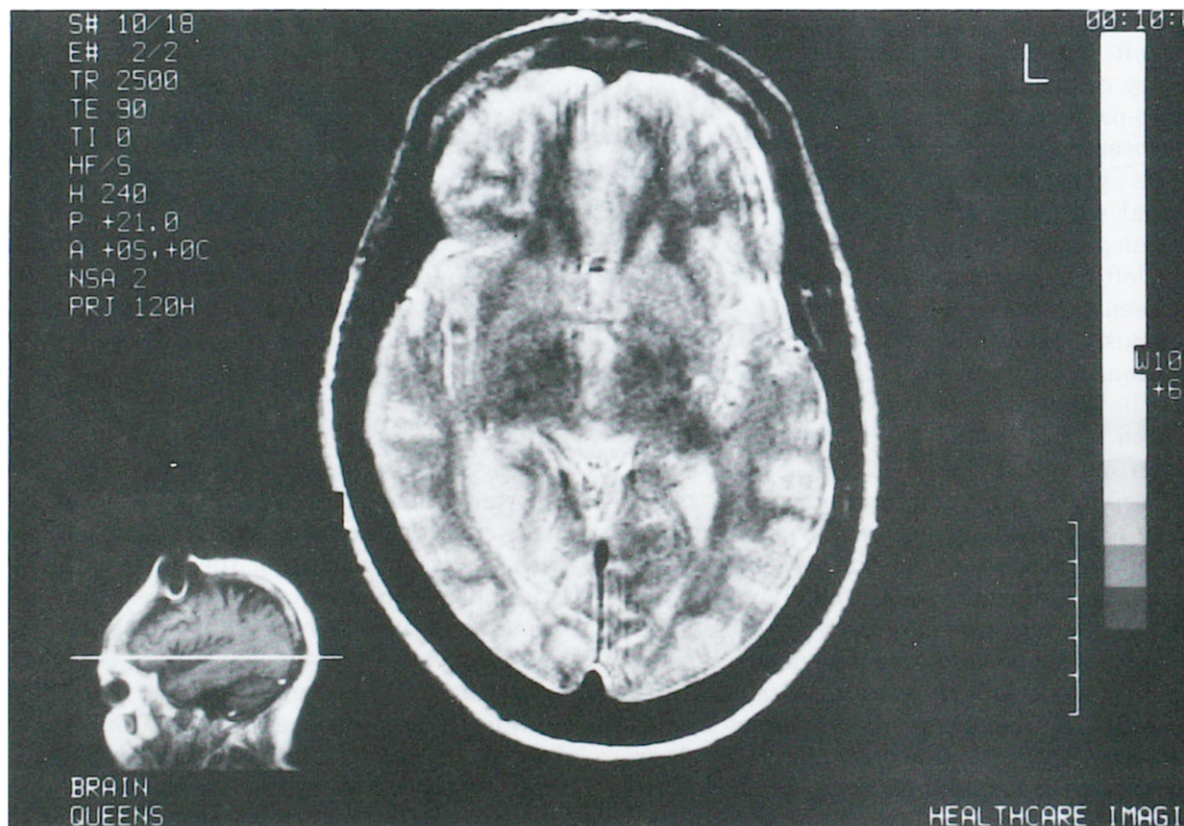


Fig. 2: (a) Initial proton density MRI showing abnormal signal in right parieto-occipital region. (b) MRI 1 year later.

patient the differential diagnosis may include a self-limited focal encephalitis perhaps due to cysticercosis, possibly an unidentified viral infection, but more likely unsuspected (and undocumented) venous ischemia.

In conclusion, patients with seizures may have abnormal imaging suggestive of structural lesions, with presumed vasogenic oedema but without significant mass effect. A subset of these patients will have 'disappearing' lesions. The term 'disappearing' lesions probably encompasses a heterogeneous group of disorders. To our knowledge, this is the first reported association between 'disappearing' lesions and venous thrombosis. Venous thrombosis is an important diagnosis to exclude as specific therapy, i.e. anticoagulation, could be initiated and might prevent clinical deterioration or improve the chances of good recovery¹⁰.

ACKNOWLEDGEMENT

We thank Ronald Kanner, MD, for his helpful review of an earlier version of the manuscript.

REFERENCES

1. Sethi, P.K., Kumar, B.R., Madan, V.S. and Mohan, V. Appearing and disappearing CT scan abnormalities and seizures. *Journal of Neurosurgery and Psychiatry* 1985; **48**: 866–869.
2. Goulatia, R.K., Verma, A., Mishra, N.K. and Ahuja, G.K. Disappearing CT lesions in epilepsy. *Epilepsia* 1987; **28**: 523–527.
3. Kramer, R.E., Haders, H., Lesser, R.P. *et al.* Transient focal abnormalities of neuroimaging studies during focal status epilepticus. *Epilepsia* 1987; **28**: 528–532.
4. De Brutto, O.H. and Sotelo, J. Neurocysticercosis: an update. *Review of Infectious Diseases* 1988; **10**: 1075–1087.
5. Schwaighofer, B.W., Heselink, J.R. and Healy, M.E. MR demonstration of reversible brain abnormalities in eclampsia. *Journal of Computer Assisted Tomography* 1989; **13**: 310–312.
6. Sanders, T.G., Clayman, D.A., Sanchez-Ramos, L., Vines, F.S. and Russo, L. Brain in eclampsia: MR imaging with clinical correlation. *Radiology* 1991; **180**: 475–478.
7. Miller, B., Grinell, V., Goldberg, M.A. and Heiner, D. Spontaneous radiographic disappearance of cerebral cysticercosis: three cases. *Neurology* 1983; **33**: 1377–1379.
8. Keane, JR. Cysticercosis acquired in the United States. *Annals of Neurology* 1980; **8**: 643.
9. Tasker, W.G. and Plotkin, S.A. Cerebral cysticercosis. *Pediatrics* 1979; **63**: 761–763.
10. Boussier, M.-G., Chiras, J., Bories, J. and Castaigne, P. Cerebral venous thrombosis—a review of 38 cases. *Stroke* 1985; **16**: 199–213.