

## Neurosurgery 1992-98

September 1994, Volume 35, Number 3

**515** Language-activated Single-photon Emission Tomography Imaging in the Evaluation of Language Lateralization--Evidence from a Case of Crossed Aphasia: Case Report  
Case Report

**AUTHOR(S):** Gomez-Tortosa, Estrella, M.D.; Martin, Eileen M., Ph.D.; Sychra, Jerry J., Ph.D.; Dujovny, Manuel, M.D.

Departments of Neurosurgery (EG-T, MD), Psychiatry (EMM), and Nuclear Medicine (JJS), University of Illinois at Chicago, Chicago, Illinois

Neurosurgery 35; 515-520, 1994

**ABSTRACT:** WE REPORT A right-handed patient who developed a nonfluent aphasia after surgery for a right parietal arteriovenous malformation. Resting brain single-photon emission tomography displayed decreased regional cerebral blood flow only in the right hemisphere, with spared regional cerebral blood flow in the left hemisphere. Single-photon emission tomography performed after a language activation task (Boston Naming Task) showed a consistent area of increased regional cerebral blood flow in the right inferior and posterior frontal lobe, supporting a right hemisphere dominance for language. These results suggest a potential role for this noninvasive study in the evaluation of language lateralization.

**KEY WORDS:** Activation; Arteriovenous malformation; Crossed aphasia; Single-photon emission tomography

In 1899, Bramwell<sup>(2)</sup> reported a case of aphasia in a right-handed patient after a right hemisphere lesion and coined the term "crossed aphasia" to define the instance when language lateralization and handedness are not linked. Since then, several cases of aphasia due to lesions of the right hemisphere in right-handed subjects have been reported<sup>(5,11,28)</sup>. Even though these circumstances are uncommon (less than 2% of right-handed patients with right hemisphere lesions develop aphasia)<sup>(8,27)</sup>, pinpointing language lateralization is essential for neurosurgical patients who undergo procedures involving potentially eloquent cortex.

Currently, only invasive methods such as the intracarotid sodium amytal test or subdural electrostimulation are available for the study of language lateralization. However, the recent development of activated positron emission tomography (PET) and single-photon emission tomography (SPECT) have helped establish a better relationship between clinical functioning and anatomy. In an activated scan procedure, the patient performs a behavioral task during the injection of radiolabeled tracer before scanning. It is assumed that cerebral perfusion, and therefore tracer uptake, will be maximal in those brain regions most active during task performance. For example, PET scanning

performed during the reading and speaking of single words shows increased activity in the language areas located in the dominant hemisphere<sup>(14,19,20)</sup>. This study has been suggested as a reliable and noninvasive preoperative technique for the assessment of language dominance<sup>(17)</sup>. Nevertheless, this technique is restricted to research settings and is not accessible for the clinicians on a regular basis. There have only been sporadic reports of SPECT activation studies, and these have used different methodology, making comparison across studies difficult. However, activation procedures using available SPECT technology show promising results. Wallesch and colleagues<sup>(26)</sup>, using xenon-133, have shown that language production in healthy right-handed people increases regional cerebral blood flow (rCBF) consistently in the dominant (left) frontal area, with a slightly smaller rCBF increase in bilateral subcortical and retrorolandic areas.

## PATIENTS AND METHODS

Our patient is a 38-year-old African-American, monolingual, strongly right-handed woman (laterality quotient of 100 on the Edinburgh-Oldfield Inventory)<sup>(16)</sup> with a 10th-grade education. Both parents, all nine brothers and sisters, and four of her five children are right handed. She was seen with generalized seizures and was diagnosed in 1986 with an arteriovenous malformation (AVM) in the right parietal lobe (*Fig. 1A*). It had multiple arterial feeders from both the internal and external carotid systems, with draining vessels to the superior sagittal sinus.

In 1988, she underwent an embolization and, at the end of the procedure, became hemiplegic on the left side. Angiography revealed that some of the emboli had lodged in the right middle cerebral artery occluding the M-1 segment, and a right frontotemporal craniotomy with an embolectomy was performed. However, the patient had residual left hemiparesis (4/5 in lower extremity, 1/5 in upper extremity with mild facial weakness) and slight hemisensory loss on the left side. No language deficit, neglect, or apraxia was noted at that time. Computed tomographic (CT) and magnetic resonance imaging studies showed a subcortical infarction involving the lenticulostriate branches of the right middle cerebral artery (*Fig. 1B*).

In June 1993, she had a presurgical evaluation that included neuropsychological testing. She was administered the Wechsler Adult Intelligence Scale-Revised, Wechsler Memory Scale-Revised, Benton Visual Naming Test, Controlled Oral Word Association, Judgment of Line Orientation, Visual Form Discrimination, and Trail Making tests (further information about these tests is provided in the *Neuropsychological Assessment* by Lezak<sup>(15)</sup>). The patient showed decreased short-term attention and concentration. Immediate and delay memory for verbal and visual information was impaired, but remarkably more so for visual (1st to 4th percentile) than for verbal (18th to 22nd percentile). Her recall of visual material was noteworthy for evidence of spatial distortion. Visual perception was impaired, as evidenced by poor performance on tests involving

angle matching and pattern discrimination. There was no evidence of neglect in a line cancellation task. Her spontaneous language was fluent, with intact comprehension and repetition. Confrontation naming was in the borderline range, and her responses were indicative of a poor vocabulary, probably associated with her 10th-grade education rather than with word-finding deficits. Verbal fluency (retrieval from semantic memory) was in the defective range.

In July 1993, the patient underwent successful surgery for the removal of her AVM. The resected piece containing the AVM involved the right inferior somatosensory gyrus and the supramarginal gyrus. After surgery, her left hemiparesis remained unchanged, her sensory loss slightly worsened on her left side, and she showed a left hemianopsia. Surprisingly, she also developed a nonfluent aphasia. Her spontaneous speech was poorly fluent, although well articulated, with painstaking production of phrases and single-word responses to questions. The ability to name common items was preserved but was defective with less familiar items. Similarly, she was able to perform the first 30 items of the Boston Naming Task but had trouble with later items, which consist of words less commonly used and, therefore, more difficult to name. Repetition was the most severely affected. She was hardly able to repeat single words and was incapable of repeating two-word sentences. Comprehension of spoken language was normal. Writing showed some spelling errors and, although impaired, was not as severely affected as oral output. There was no evidence of apraxia or anosognosia. She showed inconsistent evidence of extinction to double simultaneous tactile stimulation but showed mild spatial inattention to the left visual field on a cancellation task, missing seven items on the left compared with four on the right. Her performance on visual-spatial tasks with and without a drawing component was severely impaired. Her approach when drawing was fragmented, placing individual details without regard to the overall configuration.

Postoperative CT scans showed a small parietal hematoma and mild edema in the right hemisphere. Brain SPECT studies confirmed a large, well-defined area of marked hypoperfusion confined to the right hemisphere.

### **SPECT METHODS AND DATA ANALYSIS**

The patient underwent two resting brain SPECT scans as part of a routine treatment protocol for AVMs. The first was before her operation, and the second was 2 days after surgery. For both of them, the patient was lying down during tracer injection and was instructed just to relax and avoid movement or talking. One week after surgery, she underwent another set of SPECT studies separated by 24 hours--a baseline scan and one performed during language activation. In the baseline scan, the patient was seated comfortably in a sound-insulated isolation booth and was asked to maintain active visual fixation on a series of white cards. For the activation study, the patient was administered the Boston Naming Task while seated again in the sound-insulated booth. The

Boston Naming Task is a standardized picture-naming task that requires subjects to give the names of 60 line drawings presented one at a time in a specified order. The test was initiated 3 minutes before tracer injection and continued for 5 minutes postinjection.

Brain SPECT scans were conducted with the radiopharmaceutical [<sup>99m</sup>Tc] hexamethylpropyleneamine oxime (Ceretek; Amersham-MediPhysics, Arlington Heights, IL). The patient was injected with 20 mCi for each of the studies, about 30 to 45 minutes before scanning. Scans were obtained by a single, rectangular-head, rotating gamma camera (SOPHA DSX; Sopher Medical Systems, Columbia, MD) using 128 steps (2.81 degrees). The patient's head was positioned in the SPECT scanner by use of a transversal plane laser beam through the canthomeatal line, with a sagittal laser beam coinciding with the left-right symmetry plane of the face. The acquired three-dimensional image blocks were 64 × 64 × 64 voxel each, and the voxel size was 5.3 mm.

Images obtained from the resting studies were processed on SOPHA's computer. For the activation studies, two blocks of images were obtained: a first block for the baseline study and a second block during which time the patient was given the Boston Naming Task. Both blocks were routinely processed on SOPHA's clinical computer by the system's default low-pass Hann-Hamming filter, and the reconstructed image blocks were then transferred to our computer for the subtraction image processing. To correct for different concentrations of the radiopharmaceutical in the blood, the voxel intensities of the baseline and activation images were first normalized by requesting the sum of voxel intensities over the brain in the activation image block to be equal to that in the baseline image block. Furthermore, images were aligned with an accuracy at least one-quarter pixel and 2 degrees<sup>(22)</sup>. Finally, subtracted images between baseline and activation three-dimensional images were generated in axial and coronal planes.

These images were displayed by use of a color coding to depict quantitatively the regions with positive changes in rCBF from baseline to activation. A single color band represents a 2.5% change of the average counts per voxel. As a conservative strategy, only increases of 10% or more from baseline levels were considered significant (preliminary results indicate that the noise-induced changes in the SPECT scan can reach 7.5 to 10% of values).

### **SPECT RESULTS**

The preoperative resting brain SPECT scan showed a well-defined area of markedly decreased rCBF in the right parietal lobe in the region of the AVM. Two days after surgery, the resting SPECT scan showed a larger area of right hemisphere hypoperfusion, including the temporal and frontal as well as the parietal lobes. The rCBF in the left hemisphere showed no change from preoperative to postoperative studies.

The baseline study performed 1 week after surgery showed a slight improvement in rCBF in the right

frontal and temporal lobes. The SPECT image obtained during the Boston Naming Task showed an area of significantly increased rCBF in the posterior and inferior right frontal lobe. Computerized subtraction images confirmed this local increase in rCBF as more than 20% compared with the baseline condition and therefore well above noise-induced artifacts (*Fig. 2*). It was also compact and fairly large and did not overlap with the surgical edge (see coronal slices), a finding inconsistent with noise-induced artifact. Edge artifacts in the shape of thin rim segments sometimes occur in the areas of high pixel intensity gradients (high blood flow gradients). We exclude these areas from the activation image analysis. Well-identified activation effects either are located in the regions of low gradient (distant from the "edges") or are of a distinctively "two-dimensional" nature, extending inward away from the edge. The area of increased rCBF in the right frontal lobe discussed in this study fulfills these criteria.

Other areas showing a notable but less marked increase in rCBF (10 to 15%) were areas corresponding to the left basal ganglia and the left angular gyrus. These analogous areas in the right hemisphere could not be evaluated because they were involved in the area of decreased rCBF surrounding the surgical excision.

## DISCUSSION

This patient fulfills the clinical criteria for crossed aphasia<sup>(11)</sup>: she is monolingual and strongly right-handed, with a strong right-handed tradition in her family and without a history of childhood brain damage to the left hemisphere. In addition, her case is an exception to most of the reported cases of crossed aphasia in that the majority are stroke related, whereas her aphasia developed after surgical manipulation over the right parietal and temporal lobes for the removal of her AVM. There was no evidence of left hemisphere damage in the brain CT and SPECT studies.

The clinical pattern of her aphasia fits the profile most commonly reported in cases of crossed aphasia. This profile has been characterized regardless of lesion localization within the right hemisphere as nonfluent<sup>(11)</sup>, with relative spared comprehension and frequently a better writing performance compared with oral output<sup>(5,28)</sup>. On the basis of these clinical findings, it has been argued that linguistic functions are diffusely rather than focally represented when the right hemisphere is language dominant and that lesions at any site within a diffusely organized language area cause nonfluent aphasia<sup>(3,24)</sup>. However, clinical features of fluent aphasia have also been reported in right hemisphere lesions similar to those appearing after correlative left hemisphere lesions<sup>(5,11)</sup>. These latter observations suggest that linguistic functions within a dominant right hemisphere are organized like those of the left hemisphere for normal, right-handed adults.

This patient's clinical course is consistent with the observation that nonfluent aphasia is more common when the right hemisphere is dominant for language because a surgical lesion involving the inferior

parietal lobe and supramarginal gyrus would more predictably result in a fluent conduction-type aphasia<sup>(1,6)</sup>. Nevertheless, not all right hemisphere aphasias are the same. In our patient, the most strikingly impaired aspect of her language was repetition as compared with fluency. It is also noteworthy that the patient did not develop aphasia after her right subcortical infarction. Similar deep lesions, sparing cortical language areas, have caused aphasia not only in left but also in right structures<sup>(4,9)</sup>. Her language skills after the stroke were not subjectively impaired, nor was impairment noted during a normal conversation. Nevertheless, in the neuropsychological study performed before surgery, there was already evidence of a moderate naming deficit.

During further postoperative cognitive function tests, she showed impairment in visual-spatial tasks and a mild neglect syndrome, supporting the contention of Geschwind and Galaburda<sup>(7)</sup> that crossed aphasia is likely to be accompanied by spatial and emotional alterations common in nondominant hemisphere lesions. The CT scan and resting SPECT scan performed after surgery argued against a left hemisphere dysfunction, indicating right hemisphere damage and clinical aphasia. Other cases of crossed aphasia in both acute and chronic stages support the idea that the decreased rCBF or hypometabolism involves only the right hemisphere<sup>(18,21,25)</sup>. However, one recent report of two cases of crossed aphasia studied with fluorodeoxyglucose (18F) and PET scans have shown functional depression extending to the structurally unaffected left hemisphere in the acute stage<sup>(4)</sup>. The authors suggest that the extent of functional transcallosal diaschisis may be related to the development of crossed aphasia. Even when left hemisphere dysfunction is present to a lesser extent, right hemisphere damage is predominant and clearly responsible for the clinical deficit in cases of crossed aphasia. With brain SPECT, a close parallel has been described between the clinical recovery of crossed aphasia and the normalization of cerebral perfusion in the right hemisphere<sup>(18)</sup>. Furthermore, right dominance for language in crossed aphasia has been conclusively demonstrated during the intracarotid sodium amyltal test<sup>(28)</sup>.

The SPECT study during language activation, showing increased rCBF in the posteroinferior right frontal lobe, strongly supports clinical evidence that this patient is right hemisphere dominant for language. Previous functional studies during language activation show enhancement of the frontal and temporal structures in the dominant hemisphere and also of the subcortical and temporal regions in the nondominant hemisphere. Wallesch and associates<sup>(26)</sup> studied rCBF in normal, right-handed subjects using inhaled xenon-133 during different language activation tasks including counting, producing random syllables, and retelling a previously read story. They used three separate control conditions, including nonarticulatory oral movements, a silent memory task, and rest. They reported a consistent increase in the left frontal region corresponding to Broca's area during speech and most

markedly during language production; this result replicates prior studies using intra-arterial xenon-133<sup>(12,13)</sup>. They also found increased rCBF in the left temporal and anterior thalamic/pallidal regions and bilaterally in the head of the caudate and (cortical or subcortical) retrorolandic areas.

More recently, Hellman and colleagues<sup>(10)</sup> studied normal subjects during the performance of the Boston Naming Task using [<sup>123</sup>I]iodoamphetamine and found significant differences between resting and language conditions for the left posterior parietal regions. Tikofsky and coworkers<sup>(23)</sup> administered the same task to both normal, right-handed subjects and aphasic patients and reported decreased uptake in the left perisylvian region for aphasic patients compared with control subjects.

In a series of studies, Petersen and coworkers<sup>(19, 20)</sup> have reported on language activation using PET with labeled water and multiple activation tasks, isolating different cognitive components of language behavior. Reading aloud compared with resting resulted in increased rCBF bilaterally in the frontal lobes. However, the generation of words (e.g., generating a use for a given noun) compared with reading aloud showed a strong lateralized activation of the left anterior frontal cortex. Pardo and Fox<sup>(17)</sup> used the same series of behavioral tasks in a group of epileptic patients undergoing a preoperative work-up. They replicated the finding of a very consistent activation in the dominant anterior frontal cortex in the generative naming condition and suggest that activated PET studies may be a useful noninvasive preoperative study of language dominance, as reliable as the Wada test. Leblanc and colleagues<sup>(14)</sup> also reported on an activated PET scan performed during the reading and speaking of simple words in a right-handed patient. They found increased activity in the left parastriate and the temporal and frontal cortex and also in the right first temporal gyrus.

Therefore, even though several cortical and subcortical areas are activated bilaterally during language production, the greatest increase in rCBF appears in the perisylvian regions of the dominant hemisphere. The finding of greatest activity in the right frontal region argues that our patient is right hemisphere dominant for language. It is unlikely that this lateralized area of hyperperfusion can be accounted for by motor activity because prior studies indicate that motor activity results in bilaterally increased rCBF. In addition, the patient's prior cerebrovascular accidents would be expected to result in right frontal hypoperfusion rather than hyperperfusion.

The finding of bilateral increases in perfusion in the subtraction image is not surprising when the response requirements of the activation and control tasks are considered. Our choice of control procedure (visual fixation on a series of white cards) was designed to increase the subject's arousal to a level comparable with the activation condition. However, the activation task did require additional nonlinguistic cognitive function by the subject (visual scanning, facial movement, object recognition), which clearly contributed to the

increases in perfusion detected in the left hemisphere and in the extraperisylvian regions. We are currently modifying our control task in order to match the response requirements of the activation condition more closely.

## CONCLUSION

A prerolandic increase in rCBF during language production in normal people involves consistently the posteroinferior frontal lobe in the dominant hemisphere. Our SPECT findings strongly suggest that our right-handed patient is right hemisphere dominant for language. Further studies are needed for analyzing and quantitating the data generated by SPECT scans, and also, more appropriate behavioral control conditions should be considered. However, even though these results should be considered preliminary, this case illustrates the potential utility of this technique. It is possible that future language activation studies with SPECT could provide a noninvasive way to obtain information about language lateralization.

## ACKNOWLEDGMENTS

Dr. E. Gomez-Tortosa was supported by a grant from DuPont Pharma (Spain). We thank Dan G. Pavel, M.D., Moises Gaviria, M.D., and James I. Ausman, M.D., Ph.D. for their help in the preparation of the manuscript.

**Received**, November 17, 1993.

**Accepted**, March 31, 1994.

**Reprint requests:** Manuel Dujovny, M.D., The University of Illinois (Chicago), Department of Neurosurgery (M/C 799), 912 South Wood Street, Chicago, IL 60612-7329.

## REFERENCES: <sup>(1-28)</sup>

1. Benson DF, Sheremata WA, Bouchard R, Segarra JM, Price D, Geschwind N: Conduction aphasia. A clinicopathological study. *Arch Neurol* 28:339-346, 1973.
2. Bramwell B: On "crossed" aphasia and the factors which go to determine whether the "leading" or "driving" speech centres shall be located in the left or in the right hemisphere of the brain, with notes of a case of "crossed" aphasia (aphasia with right-sided hemiplegia) in a left handed man. *Lancet* 1:1473-1479, 1899.
3. Brown JW, Hécaen H: Lateralization and language representation. Observation on aphasia in children, left-handers, and "anomalous" dextrals. *Neurology* 26:183-189, 1976.
4. Cappa SF, Perani D, Bressi S, Paulesu E, Franceschi M, Fazio F: Crossed aphasia: A PET follow-up study of two cases. *J Neurol Neurosurg Psychiatry* 56:665-671, 1993.
5. Carr MS, Jacobson T, Boller F: Crossed aphasia: Analysis of four cases. *Brain Lang* 14:190-202, 1981.
6. Damasio H: Cerebral localization in aphasias,

- in Sarno MT (ed): *Acquired Aphasia*. New York, Academic Press, 1981, pp 27-50.
7. Geschwind N, Galaburda AM: Cerebral lateralization. Biological mechanisms, associations, and pathology. I. A hypothesis and a program for research. **Arch Neurol** 42:428-450, 1983.
  8. Gloning I, Gloning K, Haub G, Quatember R: Comparison of verbal behaviour in right-handed and non-right-handed patients with anatomically verified lesions of one hemisphere. **Cortex** 5:43-52, 1969.
  9. Habib M, Joanette Y, Ali-Cherif A, Poncet M: Crossed aphasia in dextrals: A case report with special reference to site of lesion. **Neuropsychologia** 21:413-418, 1983.
  10. Hellman RS, Tikofsky RS, Collier BD, Palmer DW, Hoffmann RG, Isitman AT, Krohn L: Quantitation of regional cerebral I-123 iodoamphetamine (IMP) distribution in normal subjects undergoing cognitive challenge. **J Nucl Med** 28:592, 1987 (abstr).
  11. Henderson VW: Speech fluency in crossed aphasia. **Brain** 106:837-857, 1983.
  12. Ingvar DH, Schwartz MS: Blood flow patterns induced in the dominant hemisphere by speech and reading. **Brain** 97:273-288, 1974.
  13. Larsen B, Skinhøj E, Soh K, Endo H, Lassen NA: The pattern of cortical activity provoked by listening and speech, in Ingvar DH, Lassen NA (eds): *Cerebral Function, Metabolism and Circulation*. Copenhagen, Munkgaard, 1977.
  14. Leblanc R, Meyer E, Bub D, Zatorre RJ, Evans AC: Language localization with activation positron emission tomography scanning. **Neurosurgery** 31:369-372, 1992.
  15. Lezak M: *Neuropsychological Assessment*. New York, Oxford, 1983, ed 2.
  16. Oldfield RC: The assessment and analysis of handedness. **Neuropsychologia** 9:97-113, 1971.
  17. Pardo JV, Fox PT: Preoperative assessment of the cerebral hemispheric dominance for language with CBF PET. **Hum Brain Mapping** 1:57-68, 1993.
  18. Perani D, Papagno C, Cappa S, Gerundini P, Fazio F: Crossed aphasia: Functional studies with single photon emission computerized tomography. **Cortex** 24:171-178, 1988.
  19. Petersen SE, Fox PT, Posner MI, Mintun MA, Raichle ME: Positron emission tomographic studies of the cortical anatomy of single-word processing. **Nature** 331:585-589, 1988.
  20. Petersen SE, Fox PT, Posner MI, Mintun MA, Raichle ME: Positron emission tomographic studies of the processing of single words. **J Cogn Neurosci** 1:153-170, 1989.
  21. Schweiger A, Wechsler AF, Mazziota JC: Metabolic correlates of linguistic functions in a patient with crossed aphasia: a case study. **Aphasiology** 1:415-421, 1985.
  22. Sychra JJ, Pavel DG, Trepashko DW, Chen Y: The accuracy of brain SPECT images. Part 1: Propagation of registration errors. **J Med Physics** (in press).
  23. Tikofsky RS, Hellman RS, Collier BD, Palmer DW, Hoffmann RG, Krohn L, Gresch A: Influence of a naming task on SPECT I-123 iodoamphetamine (SPECT/IMP) brain imaging. Chronic aphasics vs normals. **J Nucl Med** 28:559-560, 1987 (abstr).
  24. Urbain E, Seron X, Remits A, Lobben A, Van Der Linden M, Mouchette R: Aphasie croisée chez une droitnière. A propos d'une observation. **Rev Neurol** 134:751-759, 1978.
  25. Walker-Batson D, Wendt JS, Devous MD Sr, Barton MM, Bonte FJ: A long-term follow-up case study of crossed aphasia assessed by single photon emission tomography (SPECT), language and neuropsychological testing. **Brain Lang** 33:311-322, 1988.
  26. Wallesch CW, Heriksen L, Kornhuber HH, Paulson OB: Observations on regional cerebral blood flow in cortical and subcortical structures during language production in normal man. **Brain Lang** 25:224-233, 1985.
  27. Zangwill OL: Speech and the minor hemisphere. **Acta Neurol Psychiatr Belg** 67:1013-1020, 1967.
  28. Zangwill OL: Two cases of crossed aphasia in dextrals. **Neuropsychologia** 17:167-172, 1979.

#### COMMENTS

This article points out the potential utility of single-photon emission tomography (SPECT) imaging for functional cortical localization. SPECT, as well as functional magnetic resonance imaging techniques, are at the forefront of neuroimaging and will play an increasingly important role in the future of clinical neuroscience, especially in areas dealing with functional neurosurgery, and epilepsy surgery in particular. The implications of this report are important enough that it is worthwhile to address some of the weaknesses of the article and suggest some improvements for future studies.

The SPECT imaging in this case was created by having the patient first perform a silent attention task and subsequently an overt naming task. The authors acknowledge the difference between the baseline and activation studies. The language task is complex, because motor output of speech is required in addition to the cognitive processing involved in the naming task. This creates a potential problem for misidentifying the language area on the basis of motor cortex activation, rather than language cortex activation, particularly in a patient with a contralateral cerebrovascular accident. In this case, the greatest increase in regional cerebral blood flow was in the right posterior and inferior frontal lobe, although activation also occurred in the left basal ganglia and left angular gyrus. As the authors point out, there may be artifacts related to the edge of a surgical lesion, and attempts were made to exclude these areas from the activation image analysis. Although, in this case, the language cortex location

appeared to be the right frontal lobe, the data were equivocal and were not corroborated by independent testing. For example, there was no confirmation of the hemispheric dominance for language by Wada testing. This would have been a preferable adjunct to the information but would have required an additional invasive postoperative test on the patient. This obviously could not be justified on clinical grounds. Nevertheless, this type of corroboration could be considered for future studies.

It is disturbing that the large, right-sided cerebrovascular accident produced left hemiplegia without aphasia. This finding may have been because the patient's original cerebrovascular accident was subcortical, involving the basal ganglia and external capsule, sparing the perisylvian cortex. However, the absence of aphasia from the original right-sided stroke does not necessarily support the authors' contention of right hemispheric dominance for language.

In the SPECT Results section, the authors discuss potential problems with imaging in an area of surgical defect. Apparently, edge artifacts can occur along the borders of a surgical resection because of the high blood flow gradient. These edge effects will have to be expected and accounted for in future studies with SPECT imaging in patients with intracranial lesions and/or after resective surgery.

In summary, this article has significant implications for cortical localization in neurosurgical patients. This technique and others are already being added to the neurosurgical armamentarium and should become widely available within the next several years. These methodologies will greatly affect the practice of neurosurgery and will likely enhance and improve the care of our patients.

**Kim J. Burchiel**  
*Portland, Oregon*

The authors present a blood flow study in a case of crossed aphasia. Single-photon emission tomography (SPECT) is used during a standard language activation task. Consistent with deficits in repetition and other cognitive tasks seen in this patient after a right-sided cerebrovascular accident, right-sided blood flow changes are seen during a language task. More readily available than positron emission tomography, SPECT is suggested as a tool to localize language lateralization by the use of a readily available paradigm. Presenting a case of crossed aphasia underscores the importance of determining lateralization because handedness alone is not a flawless indicator.

This study is not, however, tailored to isolate language function. The patient had preoperative language deficits (poor function on the Boston Naming Test) and did not perform well on the task used during the activation SPECT. As the authors point out, the activation is not controlled for nonlanguage phenomenon. Blood flow changes during language tasks can be small compared with those from motor tasks, repetition tasks, word retrieval, picture analysis, and especially,

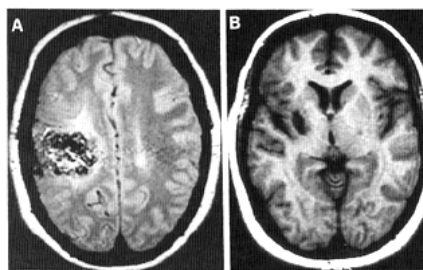


Figure 1. *A*, axial proton-density magnetic resonance image (MRI) of the AVM in the right parietal lobe. *B*, axial T1-weighted MRI of subcortical infarction involving the lenticulostriate branches of the right middle cerebral artery.

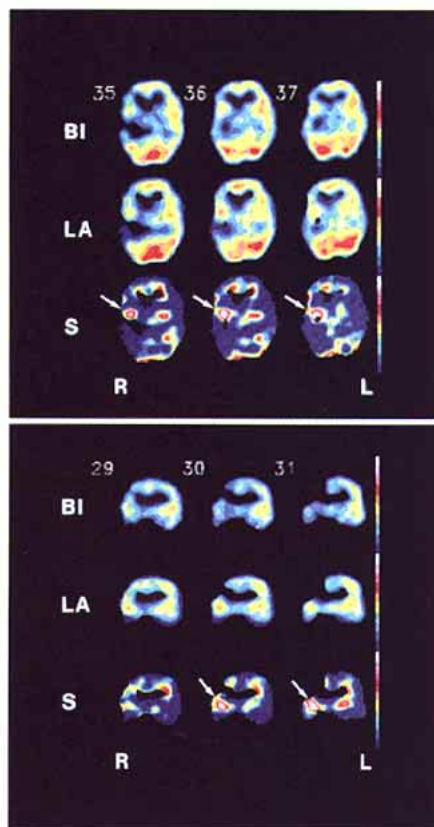


Figure 2. Brain SPECT, transverse (*upper panel*) and coronal (*lower panel*) slices. The upper row displays baseline images (*BI*), the middle row shows language activation images (*LA*), and the lower row displays results of the subtraction of both (*S*). Note the increase of CBF of up to 25% or more in the posterior and inferior aspects of the right frontal lobe (*arrow*). Each color shade corresponds to a 2.5% variation of rCBF.