

VISUAL AGNOSIA AND OPTIC APHASIA: ARE THEY ANATOMICALLY DISTINCT?

Armin Schnider, D. Frank Benson and Douglas W. Scharre

(Neurobehavior Program, Department of Neurology, UCLA School of Medicine, Los Angeles, California)

INTRODUCTION

Agnosia has been defined as a failure to recognize despite preserved primary sensory capabilities, succinctly characterized by Teuber (1968) as a “percept stripped of its meaning”. Two types of visual agnosia have been distinguished, apperceptive and associative (Lissauer, 1880; Farah, 1990; Grüsser and Landis, 1991). *Apperceptive agnosia* indicates failure of object recognition due to perceptual impairment even though elementary visual functions are relatively preserved (Benson and Greenberg, 1969; Farah, 1990). Some authors included the failure to recognize objects presented under perceptually difficult conditions, such as overlapping drawings (De Renzi and Spinnler, 1966; De Renzi, Scotti and Spinnler, 1969) or unusual views (Warrington and Taylor, 1978; Warrington, 1985). The latter disorders occurred in patients with right brain damage. *Associative agnosia* denotes the failure to recognize objects despite adequate perception, demonstrated by correct matching-to-sample and copying (Rubens and Benson, 1971; Bauer and Rubens, 1985; Farah, 1990). It is based on bilateral or unilateral left posterior lesions. Associative agnosia has often been contrasted with *optic aphasia*, the inability to name visually presented items or to point to named items which are recognized, as demonstrated by non-verbal means (pantomiming the use or semantic classification of objects) (Freund, 1889; Beauvois, 1982; Poeck, 1984). Optic aphasia is seen with unilateral left-posterior lesions.

The distinction between associative agnosia and optic aphasia is problematic because it is difficult to prove or exclude *recognition* of objects that cannot be named. Some authors ruled out agnosia if the patient could classify stimuli by semantic category or match objects with pantomimes, even if demonstration of object use was impaired (Assal and Regli, 1980; Larrabee, Levin, Huff et al., 1985; Coslett and Saffran, 1989; Riddoch and Humphreys, 1987; Peña-Casanova, Roig-Rovira, Bermudez et al., 1985). No single function unequivocally proves intact recognition, however. A patient may name or point to tools, yet fail to use them (Ochipa, Rothi and Heilman, 1989); use of a visually presented object may be pantomimed without knowledge of function (Sirigu, Duhamel and Poncet, 1991); semantic categorizations may be achieved despite impaired recognition (Jankowiak, Kinsbourne, Shalev et al., 1992); object use in every day life is, at best, a crude measure of recognition. On the other hand, impairment in any

of these functions suggests deficient recognition.

Several models have been proposed for agnosia and optic aphasia. Geschwind (1965) did not distinguish between the two disorders, explaining both in term of the disconnection theory, as suggested by Freund (1889). This theory holds that the language areas of the left hemisphere are separated from visual input by one or more lesions involving the left occipital lobe (right hemianopia) plus the corpus callosum or fibres passing through it. Other authors suggested visuo-verbal disconnection only for optic aphasia (Lhermitte and Beauvois, 1973; Ratcliff and Newcombe, 1982; Poeck, 1984; Coslett and Saffran, 1989). Others suggested that visual agnosia reflected damage to a meaning system located in the left posterior brain (Warrington, 1985; McCarthy and Warrington, 1990) or disturbed access of visual information to this system (Riddoch and Humphreys, 1987; Riddoch, Humphreys, Coltheart et al., 1988). The anatomic basis of these models is weak.

In a group of patients with left posterior infarction, De Renzi, Zambolin and Crisi (1987) found a continuum of visual recognition defects, suggesting that optic aphasia and visual agnosia may not be separate disorders. Based on a case study and analysis of previous reports we propose that optic aphasia and visual agnosia are anatomically distinct with the difference indicating varying right hemisphere participation in visual processing.

CASE REPORT

A 71-year-old right handed man left high school in the twelfth grade without graduating. He had been treated for long-standing hypertension and had a fifty pack-year history of smoking. Nine years earlier he had undergone left nephrectomy and right renal artery endarterectomy to treat renal artery stenosis.

Arterial coronarography demonstrated diffuse coronary artery disease and a four-vessel coronary bypass graft procedure was performed. On the day following surgery he was arousable but confused and agitated and displayed difficulty with every day activities. He confused toothpaste with shaving cream, mistook his razor for a toothbrush, confused cutlery when eating and did not know which food items to start with. A right hemianopia was demonstrated. Motor and sensory exams were normal. Computed tomography (CT) showed a left posterior cerebral artery area infarct involving the occipital and posterior temporal lobes (Figure 1).

Six days after surgery he was alert, oriented to name and place but not date. Digit span was 7 forward and 4 backward. Spontaneous speech was fluent, well-articulated, without paraphasia but empty. Comprehension of 3-step pointing commands, yes/no questions, and passive and possessive sentence constructions, language repetition, and verbal fluency were intact. Confrontation naming was severely defective; he named only a few body parts and no real objects or line drawings of objects. He occasionally read a single letter but no combination of letters or numbers nor any words. He was unable to name letters written on the fingertips of either hand but he could outline the correct letter in the air with the opposite hand. He correctly identified words spelled for him (e.g., book, telephone) and could spell words aloud but made spelling errors when writing sentences. He could perform only one digit calculations. He had no finger agnosia nor right/left confusion and he correctly performed transitive and intransitive movements to verbal command. Verbal memory was severely impaired: in 4 trials he learned only the last 4 of a list of 8 words and recalled none after 10 minutes.

He could copy drawings of objects reasonably well (Figure 2) but was unable to name them. He had a complete right hemianopia but in a test of visual neglect with geometric forms (circles, squares, triangles, crosses) scattered on a sheet of paper, he found all the circles and made no wrong marks. He could match colours and follow the numbers on the

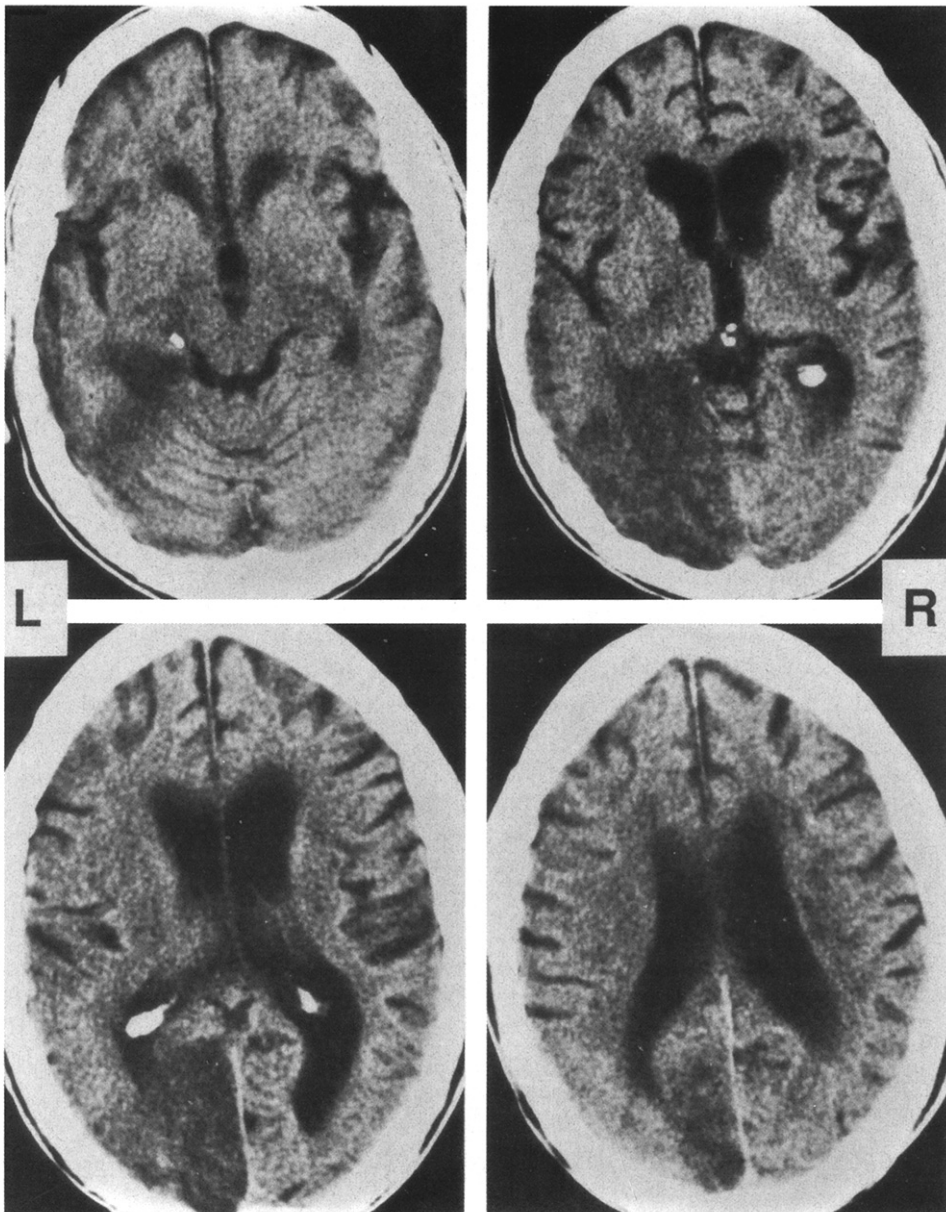


Fig. 1 – CT scan of the head, 7 days post onset, shows an infarct of the infero-medial portions of the left occipital and temporal lobe. The lingual, fusiform and posterior parahippocampal gyri appear mostly destroyed, the lower-most part of the cuneus is partially damaged.

Ishihara colour plates with his fingers but could not name the numbers. He was unable to name colours, point to them on verbal request, give the colour of common objects or select appropriate colours for line drawings. He consistently recognized the examiner by face alone during multiple visits and recognized famous persons from their photographs.

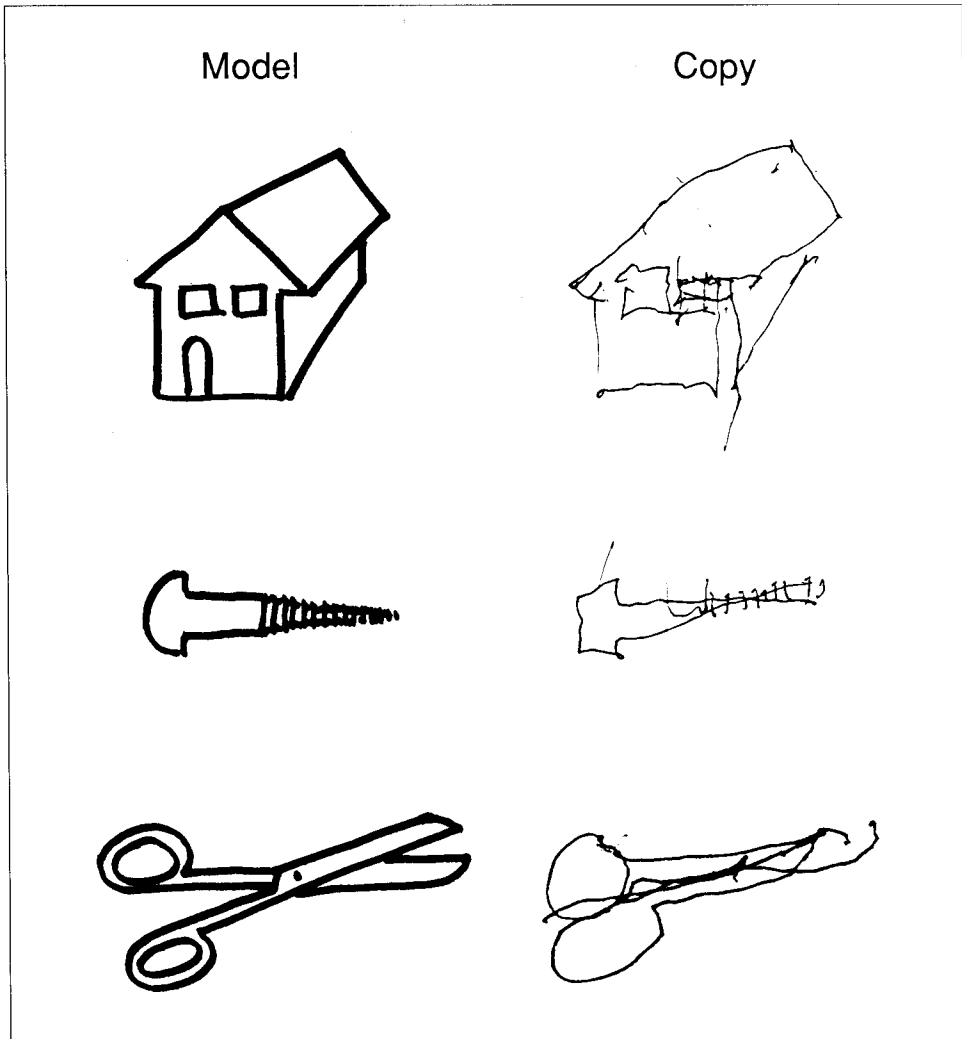


Fig. 2 – Examples of the patient's copies of line drawings demonstrating preserved perception of the items. He could not name and did not recognize any of these items.

Naming and Recognition

The results of the naming and recognition tests are summarized in Table I. The patient named *body parts* (14 items) on himself and on the examiner much better than on line drawings of the body. When the examiner pointed to one of his own body parts, the patient could point to the respective body part on himself but if the body parts were shown in line drawings he could not point to his own corresponding body parts.

He named only 1 picture in an abbreviated version of the *Boston Naming Test* (BNT [Goodglass, Kaplan and Weintraub, 1985]) using 15 pictures (tree, bed, whistle, flower, house, canoe, toothbrush, volcano, tongs, harmonica,

TABLE I
Percentages of Correct Answers in Different Naming and Recognition Tests Performed on Day 9

	Naming	Pointing
Body parts		
On himself	79%	
On examiner	71%	100% ¹
On photographs	17%	
On drawings	14%	10% ¹
Boston Naming Test (abbr.)	7%	
Colours	14%	50%

¹ The examiner pointed the body parts on himself and on line drawings and asked the patient to point to his own corresponding body parts.

dominos, funnel, mask, camel, hammock). Most errors were perseverative. One error was semantically related to the picture ("bush" instead of flower) and in 2 additional instances, the patient indicated some recognition (e.g., "It goes into the water" when shown a canoe).

He correctly named 8 of 10 *environmental sounds* (e.g., telephone ringing, car engine).

He named none of 10 common distinct *smells* (e.g., coffee, vinegar) but distinguished them (e.g., garlic: "smells bad", perfume: "smells fine").

TOOL RECOGNITION (EXPERIMENT 1)

Materials and Methods

Tools were selected for a detailed recognition test because they can be presented visually, tactilely and as a pantomime and because recognition can be indicated by pantomimes. The patient was asked to name stationary tools, tools used by the examiner, and pantomimes of tool use performed by the examiner. To test whether motion influenced tool recognition the tools were also presented while moving them nonspecifically and with a gesture typical for another tool, e.g., a toothbrush was used like a key. Tool naming by touch and from a functional description was tested and he was requested to demonstrate the use of the visually presented stationary tools. Task modality and item were continuously changed. In addition, a forced choice test was performed in which the patient was asked to point to a named tool among 7 tools. In all test modalities the same 12 tools were used (hammer, pliers, screwdriver, scissors, key, fork, knife, spoon, pencil, rubber eraser, comb, toothbrush). Eleven control subjects easily recognized and named all tools both upon visual and tactile presentation.

Results

Table II summarizes the results. Tools were flawlessly named from functional definition. In visual presentation, tools were better named when the examiner demonstrated the actual use of the tool or pantomimed the tool use (without holding the tool) than when the stationary tool was presented. When looking at an item, the patient consistently drew a correct outline of it in the air but this did not improve naming. When the examiner nonspecifically moved the tool naming did not improve. Demonstrating tools in wrong usage impaired naming. Tactile naming improved faster than visual naming.

TABLE II
Tests of Tool Naming and Recognition (Day 15)

Task	Correct	
Naming		
Visual:		
Real tool	6/12	50%
Real tool, non-specifically moved by the examiner	6/12	50%
Real tool use demonstrated by the examiner	12/12	100%
Pantomime of tool use by the examiner	10/12	83%
Real tool, inappropriate gesture	3/12	25%
Tactile presentation of real tool	9/12	75%
Verbal description of the tool's function	12/12	100%
Pointing to designated tool	8/12	67%
Demonstration of use		
Visual		
Pantomime when actual tool shown	7/12	58%
Imitation of pantomimes	12/12	100%
Experiment 2: Tool name provided by the examiner		
Congruent condition (correct name)	12/12	100%
Incongruent condition (incorrect name)	12/12	100%
Visual and tactile: actual use	11/12	92%
Verbal: Pantomime to verbal command	12/12	100%

Pointing to tools named by the examiner was deficient. When shown real tools the patient correctly pantomimed their use if he could name them but only rarely if he could not name them. Even though encouraged to pantomime the tools' use before naming them he often first misnamed them (e.g., "key" when shown a toothbrush) and then made a pantomime based on the name he had given. Misnaming was often perseverative and unrelated to the presented tool. The same behaviour — wrong pantomime after erroneous naming — was also observed with tactile presentation of the tools but he sometimes performed correctly despite being unable to name the tool. Demonstration of the tools' use with eyes open while holding a tool in his hands was correct but only after a long latency before movement was started. This contrasted to the immediate, smooth execution of the pantomime of tool use to verbal command and to imitation of the examiner's pantomimes.

SUPPRESSION OF CONFABULATIONS (EXPERIMENT 2)

Materials and Method

When asked to pantomime the use of a visually presented tool the patient usually hesitated, then misnamed the tool (confabulated) and then pantomimed the use of the tool he named. To avoid confabulations, he was asked to pantomime the use of visually presented tools after the examiner provided a tool name. The patient was informed that the name given to the tool could be right or wrong but that he should pantomime the use of the tool being shown. Test items irregularly switched from congruent ("This is a hammer. How would you use it?" when showing a hammer) to incongruent ("This is a comb. How would you use it?" when showing a toothbrush).

Results

The procedure successfully suppressed confabulations: in no instance did the patient spontaneously produce a tool name — confabulated or correct — before performing the pantomime. He even repeatedly rejected correct tool names. Thus, if the examiner named a tool correctly, the patient might deny that the name was correct (“It’s no scissors” when shown scissors named correctly by the examiner); only once did he correct a wrong tool name before he pantomimed its use. He initiated pantomimes repeatedly with the statement “I don’t know what it is but I would use it like this...”. But in all instances — both after correct and false tool names provided by the examiner —, he performed all pantomimes correctly (Table II), usually after long latencies (up to 20 seconds). When he was asked thereafter, what tool’s use he had pantomimed (“So then, what tool was it?”), he always correctly named it, often with obvious surprise (e.g., “So, then it’s a hammer!” after performing the correct pantomime).

These results augment information from the 2 previous tasks: pantomimes to verbal command were executed immediately and 100% correctly, pantomimes on visual presentation of the tool were executed with a latency of up to 10 seconds and only 58% correct (Table II).

Course

A follow-up examination was performed 5 months after the stroke. The patient continued to confuse the cutlery (e.g., trying to cut meat with the spoon), and needed help to distinguish toothpaste from shaving cream. The right hemianopia was slightly improved with some movement perception in the lower quadrant. Reading of single letters had improved (80% correct) but reading of words remained impossible even though he copied correctly. Writing had improved; he could write recognizable sentences but could not make corrections. Performance in the abbreviated Boston Naming Test remained severely deficient (2/15, 13%). Naming of tools (Real tools visually, 9/12, 75%; tactilely, 11/12, 92%; pantomimes 11/12, 92%) and of colours (8/13, 62%) was moderately improved. Pantomimes to visual presentation of the real tool and tool usage with tactile presentation were correct. When the tools were shown as line drawings, he correctly named 7/12 (58%) and pantomimed the use of 9/12 (75%) tools. Experiment 2 with visual presentation of the tool with a correct or wrong name was repeated using line drawings instead of real tools. Performance improved to 11/12 (92%) correct pantomimes.

The patient remained severely handicapped by visual recognition disturbances and died 3 months later of renal insufficiency subsequent to congestive heart failure.

DISCUSSION

Following infarction of the infero-medial portions of the left occipital and posterior temporal lobes but with spared corpus callosum, a patient suffered

disturbed recognition of visually presented material. That the items were adequately perceived was clearly demonstrated; he could match forms, draw the outlines of real objects in the air and copy line drawings of objects. When given a verbal definition he could name objects. He could not, however, name, point to, or demonstrate the use of visually presented material. These findings fulfil the definition of associative visual agnosia, a "percept stripped of its meaning" (Teuber, 1968). As in other reported cases (Assal and Regli, 1980; Morin et al., 1984; Larrabee et al., 1985; Feinberg et al., 1986; Sirigu et al., 1991; Yamadori et al., 1992), the agnosia initially also concerned non-visual modalities (tactile, olfactory) but never to a degree comparable to the visual modality. Eventually the visual agnosia was the patient's only handicap.

That naming was dependent on the visual properties of the stimulus was demonstrated with different presentation modes. Tools shown in correct usage and pantomimes of tool use were much better named than stationary tools. This was not due to increased visual attention by motion, as experienced by healthy subjects (e.g., McLeod, Driver and Crisp, 1988); moving the tools nonspecifically did not improve naming and showing tools in *wrong* usage produced even worse naming. Gestures appeared to evoke more kinesthetic associations than stationary or nonspecifically moved tools.

When asked to demonstrate the use of a visually presented tool in a test condition, the patient often misnamed (confabulated) the tool and performed a gesture based on the false name. In an experimental condition confabulations were suppressed by requesting demonstration of the use of visually presented tools for which a name that could be correct or false was provided (experiment 2). Under this condition, the patient did not produce confabulated tool names any more. But even though he did also not provide the correct tool names and did not even recognize correct tool names provided by the examiner, he correctly pantomimed each tool's use. Thus, this simple manoeuvre temporarily changed the disorder from visual agnosia to optic aphasia. Only after demonstrating a tool's use did he name it correctly, often to his own surprise (naming presumably was based on kinesthetic feedback from performing the pantomime, a mechanism of recognition which has previously been demonstrated in patients with apperceptive agnosia [Goldstein and Gelb, 1918; Landis et al., 1982]). Our experiment indicates that visual agnosia and optic aphasia are functionally related conditions, representing different degrees of disturbed visual recognition, an idea supported by the variability of agnosic symptoms in a given patient (Critchley, 1964; Bauer and Rubens, 1985) and the wide spectrum of agnosic signs across patient groups (De Renzi, Zambolin and Crisi, 1987).

What anatomical substrate allows transition of visual agnosia to optic aphasia? Comparison of cases with fairly stable visual agnosia or optic aphasia due to a unilateral left-sided lesion provides some insight (optic aphasia following bilateral temporo-occipital lesions has never been described). Unfortunately, only a few reports provide pertinent anatomic information, and among these, pure optic aphasia is rare: McCormick and Levine's (1983) and Michel, Schott, Boucher et al.'s (1979) patient could always demonstrate the use of objects they could not name; Coslett and Saffran's (1992) patient had naming difficulties in multiple modalities including naming in response to a verbal definition. Coslett

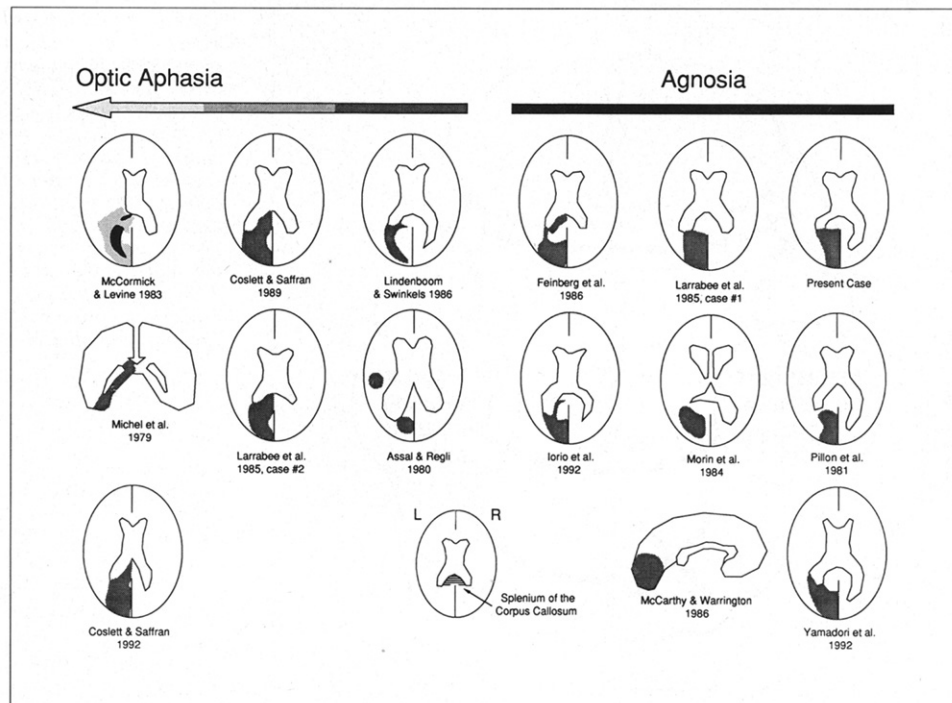


Fig. 3 – CT scans (all horizontal slices) and MRI scan (sagittal cut) of patients with unequivocal visual agnosia (3 right columns), and patients with less pervasive recognition disturbances; the further to the left a scan is placed, the better recognition was preserved and the more the syndrome resembled optic aphasia. In McCormick and Levine's case [1983], the dark area indicates contrast-enhanced tumour parts, the pale area indicates perifocal edema. All other patients had vascular lesions. The template in the middle of the bottom shows the position of the splenium of the corpus callosum.

and Saffran's (1989) and Larrabee, Levin, Huff et al.'s (1985) case 2 often failed to demonstrate the use of objects; Lindenboom and Swinkels's (1986) patient could not demonstrate the use of tools he could not name and Assal and Regli's (1980) patient, in addition, had occasional problems with object use. Figure 3 shows sketches of lesions derived from illustrations included in reports of these patients with "optic aphasia" and of patients with unequivocal visual agnosia due to unilateral left-sided lesions (Pillon, Signoret and Lhermitte, 1981; Morin, Rivrain, Eustache et al., 1984; Larrabee et al., 1985; Feinberg, Rothi and Heilman, 1986; McCarthy and Warrington, 1986; Iorio, Falanga, Fragassi et al., 1992; Yamadori et al., 1992). Both groups show inferior temporoparietal lesions. The splenium, however, is involved only in patients who could always or almost always demonstrate the use of visually presented objects and who had no difficulty using objects, i.e., optic aphasics. Lindenboom and Swinkels's (1986) and Assal and Regli's (1980) patients, who could not pantomime the use of visually presented tools, had lesions similar to the visual agnosics; their lesions spared the splenium of the corpus callosum. A possible exception is Feinberg et al.'s (1986) patient with multi-modal agnosia whose lesion appears to involve, but not completely destroy the splenium. Other cases

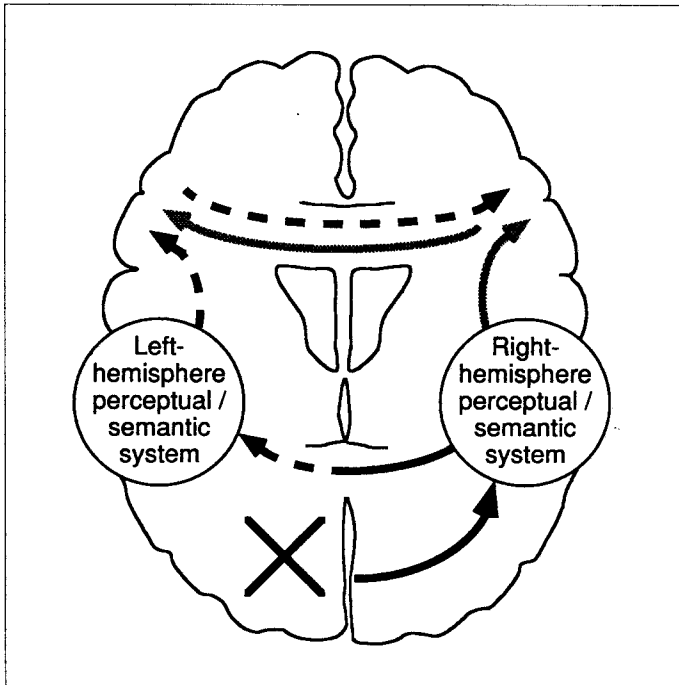


Fig. 4 – Proposed model of object recognition in patients with unilateral left-posterior lesions. Black arrows indicate the pathways normally used. Dashed black arrows indicate the pathways used in visual agnosia. The gray arrows show the alternative route with right-hemisphere processing, presumably used in optic aphasia.

with unilateral lesions were not included because no anatomical details were described (Lhermitte and Beauvois, 1973; Hécaen, Goldblum, Masure et al., 1974; Riddoch and Humphreys, 1987; Gil, Pluchon, Toullat et al., 1985), the CT scans did not include the level of the splenium (Ferro and Santos, 1984; Peña-Casanova, Roig-Rovira, Bermudez et al., 1985; Benke, 1988), optic aphasia resolved within a week after intracerebral hemorrhage (Rapcsak, Rothi and Heilman, 1987), or naming was the only reported test of recognition (Nissl von Mayendorf 1935; Levin and Rose, 1979).

The behaviour of patients with optic aphasia resembles the right-hemisphere performance of split-brain patients who often demonstrate (with the left hand) the use of objects tachistoscopically presented to the left visual field although they cannot name them (Sperry, Gazzaniga and Bogen, 1969). Based on findings in our patient and review of reported cases we posit that optic aphasia and visual agnosia differ in the degree of callosal disconnection and subsequent semantic identification by the non-dominant hemisphere. If the damaged left inferior temporo-occipital area is disconnected from the right hemisphere's visual input, the right hemisphere may process stimuli in the manner of split-brain patients; the syndrome then resembles optic aphasia. If some visual information gains access to the damaged left inferior temporo-occipital area, less visual processing occurs in the right hemisphere and more in the damaged left hemisphere producing associative visual agnosia. The severity of the agnosia depends on the extent of the inferotemporal lesion, an area critical for visual recognition (Dean, 1982). The presence of optic aphasia is dependent upon

additional damage of the corpus callosum. Theoretically, optic aphasia might also result from a lesion outside the splenium. But a forceps major lesion would have to be huge in order to completely destroy the interhemispheric visual fibers and would probably be associated with aphasia; only a lesion of the splenium, where the interhemispheric fibers are tightly bundled, is likely to interrupt these fibers without damaging the left hemisphere language structures.

This model assumes that semantic classification of visually presented objects is performed preferably by the left hemisphere (Figure 4). If there is sufficient callosal disconnection or strong discouragement by the examiner to process stimuli by naming them first (experiment 2) the right hemisphere will process stimuli beyond the perceptual level. With bilateral temporo-occipital lesions, a combination of perceptual and semantic disturbances (De Renzi, Scotti and Spinnler, 1969; Warrington and Taylor, 1978), without the possibility of right-hemisphere compensation for impaired left-hemisphere processing has to be expected; optic aphasia is unlikely with bilateral lesions. Inherent in this model is a cognitive flexibility, rarely acknowledged by cognitive models of object recognition but often observed in clinical settings (Critchley, 1964; Bauer and Rubens, 1985).

ABSTRACT

A patient with left infero-medial occipital-temporal infarct suffered a visual agnosia that, by a minor change of the task, could be manipulated to optic aphasia. Tools in actual use and pantomimes of tool use were better named than stationary tools, a dissociation that suggests differences in the ability of stimuli to evoke associations over multiple modalities. Based on this case and analysis of previous reports we suggest that optic aphasia differs from visual agnosia primarily in the degree of callosal disconnection and that the preserved demonstration of tools use and semantic classification of optic aphasia reflect right hemisphere contribution to visual processing.

Acknowledgement. Study supported by a grant from the Swiss National Science Foundation to Dr. Schnider.

REFERENCES

- ASSAL, G., and REGLI, F. Syndrome de disconnexion visuo-verbale et visuo-gestuelle. *Revue Neurologique*, 136: 365-376, 1980.
- BAUER, R.M., and RUBENS, A.B. Agnosia. In K.M. Heilman and E. Valenstein (Eds.), *Clinical Neuropsychology*. 2nd ed. New York: Oxford University Press, 1985, pp. 187-241.
- BEAUVOIS, M.F. Optic aphasia: a process of interaction between vision and language. *Philosophical Transactions of the Royal Society of London*, 298: 35-47, 1982.
- BENKE, T. Visual agnosia and amnesia from a left unilateral lesion. *European Neurology*, 28: 236-239, 1988.
- BENSON, D.F., and GREENBERG, J.P. Visual form agnosia. *Archives of Neurology*, 20: 82-89, 1969.
- COSLETT, H.B., and SAFFRAN, E.M. Preserved object recognition and reading comprehension in optic aphasia. *Brain*, 112: 1091-1110, 1989.
- COSLETT, H.B., and SAFFRAN, E.M. Optic aphasia and the right hemisphere: a replication and extensions. *Brain and Language*, 43: 148-161, 1992.
- CRITCHLEY, M. The problem of visual agnosia. *Journal of the Neurological Sciences*, 1: 274-290, 1964.
- DE RENZI, E., SCOTTI, G., and SPINNLER, H. Perceptual and associative disorders of visual recognition. *Neurology*, 19: 634-642, 1969.
- DE RENZI, E., and SPINNLER, H. Visual recognition in patients with unilateral cerebral disease. *Journal of Nervous and Mental Diseases*, 142: 515-525, 1966.
- DE RENZI, E., ZAMBOLIN, A., and CRISI, G. The pattern of neuropsychological impairment associated with left posterior cerebral artery infarcts. *Brain*, 110: 1099-1116, 1987.

- DEAN, P. Visual behavior in monkeys with inferotemporal lesions. In D.J. Ingle, M.A. Goodale and R.J.W. Mansfield (Eds.), *Analysis of Visual Behavior*. Cambridge: The MIT Press, 1982, pp. 587-628.
- FARAH, M.J. *Visual Agnosia. Disorders of Object Recognition and What They Tell Us about Normal Vision*. Cambridge: The MIT Press, 1990.
- FEINBERG, T.E., ROTH, L.J.G., and HEILMAN, K.M. Multimodal agnosia after unilateral left hemisphere lesion. *Neurology*, 36: 864-867, 1986.
- FERRO, J.M., and SANTOS, M.E. Associative visual agnosia: A case study. *Cortex*, 20: 121-134, 1984.
- FREUND, C.S. Über optische Aphasie und Seelenblindheit. *Archiv für Psychiatrie und Nervenkrankheiten*, 20: 276-297, 371-416, 1889.
- GOLDSTEIN, K., and GELB, A. Psychologische Analysen hirnpathologischer Fälle auf Grund von Untersuchungen Hirnverletzter. *Zeitschrift für die gesamte Neurologie und Psychiatrie*, 41: 1-142, 1918.
- GESCHWIND, N. Disconnexion syndromes in animals and man. Part II. *Brain*, 88: 585-644, 1965.
- GIL, R., PLUCHON, C., TOULLAT, G., MICHENEAU, D., ROGEZ, R., and LEFEVRE, J.P. Disconnexion visuo-verbale (aphasie optique) pour les objets, les images, les couleurs et les visages avec alexie "abstractive". *Neuropsychologia*, 23: 333-349, 1985.
- GOODGLASS, H., KAPLAN, E., and WEINTRAUB, S. *Boston Naming Test*. Philadelphia: Lea and Febiger, 1985.
- GRÜSSER, O.J., and LANDIS, T. Visual agnosias and other disturbances of visual perception and cognition. In J. Cronly-Dillon (Ed.), *Vision and Visual Dysfunction*, vol. 12. London: MacMillan, 1991.
- HÉCAEN, H., GOLDBLUM, M.C., MASURE, M.C., and RAMIER, A.M. Une nouvelle observation d'agnosie d'objet. Déficit de l'association ou de la catégorisation, spécifique de la modalité visuelle? *Neuropsychologia*, 12: 447-464, 1974.
- IORIO, L., FALANGA, A., FRAGASSI, N.A., and GROSSI, D. Visual associative agnosia and optic aphasia. A single case study and review of the syndromes. *Cortex*, 28: 23-37, 1992.
- JANKOWIAK, J., KINSBOURNE, M., SHALEV, R.S., and BACHMAN, D.L. Preserved visual imagery and categorization in a case of associative visual agnosia. *Journal of Cognitive Neuroscience*, 4: 119-131, 1992.
- LANDIS, T., GRAVES, R., BENSON, D.F., and HEBBEN, N. Visual recognition through kinaesthetic mediation. *Psychological Medicine*, 12: 515-531, 1982.
- LARRABEE, G.J., LEVIN, H.S., HUFF, F.J., KAY, M.C., and GUINTO, F.C. Visual agnosia contrasted with visual-verbal disconnection. *Neuropsychologia*, 23: 1-12, 1985.
- LEVIN, H.S., and ROSE, J.E. Alexia without agraphia in a musician after transcalsal removal of a left intraventricular meningioma. *Neurosurgery*, 4: 168-174, 1979.
- LHERMITTE, F., and BEAUVOIS, M.F. A visual-speech disconnection syndrome. *Brain*, 96: 695-714, 1973.
- LINDENBOOM, J., and SWINKELS, J.A. Interhemispheric communication in a case of total visuo-verbal disconnection. *Neuropsychologia*, 24: 781-792, 1986.
- LISSAUER, H. Ein Fall von Seelenblindheit nebst einem Beitrag zur Theorie derselben. *Archiv für Psychiatrie und Nervenkrankheiten*, 21: 222-270, 1890.
- MCCARTHY, R.A., and WARRINGTON, E.K. Visual associative agnosia: a clinico-anatomical study of a single case. *Journal of Neurology, Neurosurgery and Psychiatry*, 49: 1233-1240, 1986.
- MCCARTHY, R.A., and WARRINGTON, E.K. *Cognitive Neuropsychology. A Clinical Introduction*. San Diego: Academic Press, 1990.
- MCCORMICK, G.F., and LEVINE, D.A. Visual anomia: a unidirectional disconnection. *Neurology*, 33: 664-666, 1983.
- MCLEOD, P., DRIVER, J., and CRISP, J. Visual search for a conjunction of movement and form is parallel. *Nature*, 332: 154-155, 1988.
- MICHEL, F., SCHOTT, B., BOUCHER, M., and KOPP, N. Alexie sans agraphie chez un malade ayant un hémisphère gauche déafférenté. *Revue Neurologique*, 135: 347-364, 1979.
- MORIN, P., RIVRAIN, Y., EUSTACHE, F., LAMBERT, J., and COURTHEOUX, P. Agnosie visuelle et agnosie tactile. *Revue Neurologique*, 140: 271-277, 1984.
- NISSL VON MAYENDORF. Zur Lehre von der Seelenblindheit. *Zeitschrift für die gesamte Neurologie und Psychiatrie*, 152: 342-382, 1935.
- OCHIPA, C., ROTH, L.J.G., and HEILMAN, K.M. Ideational apraxia: a deficit in tool selection and use. *Annals of Neurology*, 25: 190-193, 1989.
- PEÑA-CASANOVA, J., ROIG-ROVIRA, T., BERMUDEZ, A., and TOLOSA-SARRO, E. Optic aphasia, optic ataxia, and loss of dreaming. *Brain and Language*, 26: 63-71, 1985.
- PILLON, B., SIGNORET, J.L., and LHERMITTE, F. Agnosie visuelle associative. Rôle de l'hémisphère gauche dans la perception visuelle. *Revue Neurologique*, 137: 831-842, 1981.
- POECK, K. Neuropsychological demonstration of splenial interhemispheric disconnection in a case of "optic anomia". *Neuropsychologia*, 22: 707-713, 1984.
- RAPCSAK, S.Z., ROTH, L.J.G., and HEILMAN, K.M. Phonological alexia with optic and tactile anomia: a neuropsychological and anatomical study. *Brain and Language*, 31: 109-121, 1987.
- RATCLIFF, G., and NEWCOMBE, F. Object recognition: some deductions from the clinical evidence. In A.W.

- Ellis (Ed.), *Normality and Pathology in Cognitive Functions*. London: Academic Press, 1982, pp. 147-171.
- RIDDOCH, M.J., and HUMPHREYS, G.W. Visual object processing in optic aphasia: A case of semantic access agnosia. *Cognitive Neuropsychology*, 4: 131-185, 1987.
- RIDDOCH, M.J., HUMPHREYS, G.W., COLTHEART, M., and FUNNEL, E. Semantic systems or system? Neuropsychological evidence re-examined. *Cognitive Neuropsychology*, 5: 3-25, 1988.
- RUBENS, A.B., and BENSON, D.F. Associative visual agnosia. *Archives of Neurology*, 24: 305-316, 1971.
- SIRIGU, A., DUHAMEL, J.R., and PONCET, M. The role of sensorimotor experience in object recognition. A case of multimodal agnosia. *Brain*, 114: 2555-2573, 1991.
- SPERRY, R.W., GAZZANIGA, M.S., and BOGEN, J.E. Interhemispheric relationships: the neocortical commissures; syndromes of hemisphere disconnection. In P.J. Vinken, G.W. Bruyn, M. Critchley and J.A.M. Frederiks (Eds.), *Handbook of Clinical Neurology*, vol. 4: *Disorders of Speech, Perception, and Symbolic Behaviour*. Amsterdam: North-Holland Publishing Company, 1969, pp. 273-290.
- TEUBER, H.L. Alteration of perception and memory in man. In L. Weiskrantz (Ed.), *Analysis of Behavioral Change*. New York: Harper and Row, 1968.
- WARRINGTON, E.K. Agnosia: the impairment of object recognition. In P.J. Vinken, G.W. Bruyn, H.L. Klawans and J.A.M. Frederiks (Eds.), *Handbook of Clinical Neurology*, vol. 45: *Clinical Neuropsychology*. Amsterdam: Elsevier Science, 1985, pp. 333-349.
- WARRINGTON, E.K., and TAYLOR, A.M. Two categorical stages of object recognition. *Perception*, 7: 695-705, 1978.
- YAMADORI, A., YONEDA, Y., YAMASHITA, H., and SUGIURA, K. A patient with difficulty of object recognition: semantic amnesia for manipulable objects. *Behavioural Neurology*, 5: 183-187, 1992.