

## Neurosurgery 1992-98

October 1994, Volume 35, Number 4

**751** Endoscopic Resection of a Subthalamic Cavernous Angioma: Technical Case Report  
Technical Case Report

**AUTHOR(S):** Otsuki, Taisuke, M.D., Ph.D.;  
Yoshimoto, Takashi, M.D., Ph.D.

Department of Neurosurgery, National Miyagi Hospital and Division of Neurosurgery, Institute of Brain Diseases, Tohoku University School of Medicine, Sendai, Japan

Neurosurgery 35; 751-754, 1994

**ABSTRACT:** ENDOSCOPIC RESECTION OF a cavernous angioma at the subthalamic region was performed in a 33-year-old woman who presented with diplopia and progressive hemiparesis caused by recurrent hemorrhages. The entire surgical procedure was done through an 8-mm guiding tube inserted stereotactically from a frontal burr hole via an approach that traversed the anterior limb of the internal capsule. The patient's symptoms improved after surgery. This is believed to be the first report describing successful resection of a cavernous angioma located at the subthalamic region.

**KEY WORDS:** Cavernous angioma; Diencephalon; Endoscopy; Stereotactic surgery; Surgical technique

Cavernous angioma of the diencephalon is uncommon. In a review of 164 cases of cerebral cavernous angioma in 1976, Voigt and Yasargil<sup>(25)</sup> described two cases of cavernous angioma in the diencephalon, one in the hypothalamus with Morgagni's syndrome, i.e., a syndrome of endocrine dysfunction associated with hyperostosis of the frontal bone, and one in the dorsal part of the thalamus. In a more recent review by Simard, et al.<sup>(21)</sup> in 1986, the lesion occurred in the diencephalon in two of 138 cases, namely, one in the thalamus<sup>(2)</sup> and one in the hypothalamus<sup>(11)</sup>, but none in the subthalamus. Recently, surgical explorations of thalamic and hypothalamic cavernous angiomas have been reported<sup>(3,5,17,19,23)</sup>. Surgical exploration of cavernous angiomas at the subthalamic region, however, has remained unmentioned.

### CASE REPORT

This 33-year-old woman developed slight ptosis of her right eyelid. She experienced headache, nausea, and vomiting on the next day and noticed diplopia on the following days. She was admitted to a nearby hospital 7 days after the onset of symptoms. Progressive left hemiparesis developed thereafter. She was referred to our institution 3 weeks later.

### Examination

On neurological examination, she exhibited upward and downward gaze palsy with slight skew deviation of the eyes and moderate left hemiparesis, including her face, arm, and leg. Computed

tomographic (CT) scans and magnetic resonance (MR) images demonstrated a moderate enlargement of the lateral ventricles with a right subthalamic lesion of about 3.0 cm in maximal diameter extending to the cerebral peduncle, suggesting a small cavernous angioma associated with a hematoma caused by recent hemorrhage (*Fig. 1*). Cerebral angiography showed no vascular abnormalities such as vascular stains and draining vessels.

### Operation

One month after initial presentation the patient underwent stereotactic endoscopic resection of the subthalamic lesion. This was performed under general anesthesia using a frontal burr hole to approach the anterior limb of the internal capsule.

Most of the details of the devices and techniques used for this surgical procedure have been reported previously<sup>(13-15)</sup>. Briefly, multiplanar MR imaging (4-mm slices) was performed for planning the trajectory of the guiding tube after a standard Leksell stereotactic frame was fixed to the patient's head under local anesthesia. The *x*, *y*, and *z* coordinates for the center of the lesion, angle of the trajectory, and depth of the lesion were calculated on MR images, and the patient was transferred to the operating room and anesthetized. After a burr hole had been made in the right frontal bone, a small corticotomy was performed, and a fine needle was inserted to confirm the accuracy of the trajectory by aspirating the liquified clot at the target site. Then, an 8-mm-diameter guide tube with an inner stylet was carefully inserted to the target. The guiding device was fixed to one of the needle holders of a standard Leksell stereotactic frame with an adapter.

After removing the inner stylet, a rigid endoscope, 1.7 mm in diameter, having an outer sheath 2.2 mm in diameter, was inserted to visualize the operating field. The eye piece of the endoscope was attached to the proximal needle holder of the Leksell apparatus eccentrically, so that the tip of the endoscope could be introduced along the wall of the guiding tube (*Fig. 2*). The outer sheath was used to irrigate both the tip of the endoscope and the operating field. The lesion was partially encapsulated and adhered to a structure near the wall of the third ventricle. It was resected piecemeal using flexible tumor forceps. Total resection of the angioma was achieved, although a thin layer of fibrous capsule at the lateral aspect of the wall of the third ventricle was not removed but carefully coagulated by Nd:Yag laser. A small piece of Gelfoam with dimensions of 5 × 5 × 10 mm was placed in the cavity after removal of the angioma.

### Postoperative course

The patient recovered from the anesthesia with significant improvement in her gaze palsies and no additional deficits. Her double vision and left hemiparesis also resolved in the following days. Histological diagnosis was cavernous angioma. Postoperative CT and MR scans (*Fig. 3*) showed that the angioma had been totally resected without additional trauma to the brain, except for the fine line

of trajectory of the guide tube with a diameter of 8 mm. Ventricular dilatation disappeared without drainage or shunting operation. She complained of only a slight clumsiness in her left hand 1 month after surgery, although no objective sensorimotor deficits, including ataxia or motor weakness, were revealed. Standard neuropsychological evaluation performed at this point, including the Wechsler Adult Intelligence Scale, was unremarkable.

## DISCUSSION

Cavernous angiomas may cause hemorrhage, seizures, and progressive neurological deficits<sup>(4,9,12,16,24,25)</sup>. Although the natural history of cavernous angiomas is not fully understood, resection of cavernous angiomas is recommended for symptomatic patients if the lesions are accessible<sup>(6,7,9,12,19,24,28)</sup>. Surgical management of cavernous angiomas, however, is not always simple, because these lesions tend to be small and located deep in the brain, so that location of the lesions by conventional techniques may be difficult. Stereotactic radiographic surgery, as an alternative to resective surgery, has so far met with limited success in the case of cavernous angiomas<sup>(8,27)</sup>, and stereotactic needle biopsy of cavernous angiomas for diagnostic evaluation sometimes may cause massive and fatal hemorrhage.

The treatment of such malformations in the diencephalon has been controversial<sup>(17)</sup>. The recent literature on brain stem cavernous angiomas, however, suggests that surgical exploration should be considered when the patient shows progressive and repetitive neurological deficits caused by hemorrhages<sup>(6,7,19,28)</sup>. In our case, the malformation was located in the subthalamic region, i.e., Forel's field and the zona incerta<sup>(18)</sup>. The patient's symptoms of diplopia and hemiparesis progressed, and MR imaging suggested recurrent hemorrhage. Because the angioma was considered inaccessible by conventional surgical techniques, we applied the endoscopic approach to resect this small malformation<sup>(13)</sup>. This subthalamic cavernous angioma with a liquified clot 30 mm in the maximal diameter was removed endoscopically through an 8-mm-diameter guide tube using a frontal approach through the anterior limb of the internal capsule between the caudate and the globus pallidus.

The surgical approach adopted in our report is unique but not totally new. In 1942, Meyers<sup>(10)</sup> reported a transventricular approach to lesion the ansa lenticularis for the treatment of parkinsonian tremor and rigidity. This open procedure was followed, in the 1950s and the 1960s, by stereotactic approaches using various instruments and thermocoagulation electrodes to injure the basal structures, including the globus pallidus, ansa lenticularis, Forel's field, and the ventrolateral part of the thalamus<sup>(22,26)</sup>.

Although the stereotactic endoscopic approach has been considered an ideal method for resecting small intracranial lesions with minimal invasiveness<sup>(1,20)</sup>, endoscopic excision of intraparenchymal lesions has remained difficult. The authors have developed, in this context, a new surgical approach using a

stereotactic guide tube and fine endoscopes<sup>(13-15)</sup>. This approach allows the surgeons to use various surgical instruments, including lasers, and makes endoscopic resection of solid intraaxial lesions possible. In the present case, an outer sheath of the endoscope was used to irrigate both the tip of the endoscope and the operating field to obtain better visualization. Postoperatively, the patient's symptoms improved dramatically without additional deficits. We conclude that endoscopic resection should be considered as an alternative in the treatment of patients with small symptomatic cavernous angiomas, especially if the angiomas are located at inaccessible sites such as the deep diencephalons.

## ACKNOWLEDGMENTS

We thank Dr. Masaharu Amagasa for referral of the patient described in this report. We also appreciate Dr. Toshikatsu Fujii's neuropsychological evaluation of the patient.

**Received,** November 19, 1993.

**Accepted,** April 20, 1994.

**Reprint requests:** Taisuke Otsuki, M.D., Ph.D., Department of Neurosurgery, National Miyagi Hospital, 100 Kassenhara, Takase, Yamamoto, Watari, Miyagi 989-22, Japan.

## REFERENCES:

<sup>(1-28)</sup>

1. Auer LM, Holzer P, Asher PW, Heppner F: Endoscopic neurosurgery. **Acta Neurochir (Wien)** 90:1-14, 1988.
2. Becker DM, Townsent JJ, Kramer RA, Newton TH: Occult cerebrovascular malformations: A series of 18 histologically verified cases with negative angiography. **Brain** 102:249-287, 1979.
3. Bertalanffy H, Gilsbach JM, Eggert HR, Seeger W: Microsurgery of deep-seated cavernous angiomas: Report of 26 cases. **Acta Neurochir (Wien)** 108:91-99, 1991.
4. Curling OD, Kelly DL, Elster AD, Craven TE: An analysis of the natural history of cavernous angiomas. **J Neurosurg** 75:702-708, 1991.
5. Davis DH, Kelly PJ: Stereotactic resection of occult vascular malformations. **J Neurosurg** 72:698-702, 1990.
6. Fahlbusch R, Strauss C, Huk W, Rockelein G, Kompf D, Ruprecht KW: Surgical removal of pontomesencephalic cavernous hemangiomas. **Neurosurgery** 26:449-457, 1990.
7. Kashiwagi S, van Loveren HR, Tew JM, Wiot JG, Weil SM, Lukin RA: Diagnosis and management of vascular brain-stem malformations. **J Neurosurg** 72:27-34, 1990.
8. Kondziolka D, Lunsford LD, Coffey RJ, Bissonette DJ, Flickinger JC: Stereotactic radiosurgery of angiographically occult vascular malformations: Indications and preliminary experience. **Neurosurgery** 27:892-900, 1990.

9. Lobato RD, Perez C, Rivas JJ, Cordobes F: Clinical, radiological, and pathological spectrum of angiographically occult intracranial vascular malformations, analysis of 21 cases and review of the literature. **J Neurosurg** 68:518-531, 1988.
10. Meyers R: The modification of altering tremor, rigidity and festration by surgery of the basal ganglia. **Res Publ Assoc Res Nerv Ment Dis** 21:602-665, 1942.
11. Mizutani T, Goldberg, HI, Kerson LA, Murtagh F: Cavernous hemangioma in the diencephalon. **Arch Neurol** 38:379-382, 1981.
12. Ogilvy CS, Heros RC, Ojemann RG, New PF: Angiographically occult vascular malformations. **J Neurosurg** 69:350-355, 1988.
13. Otsuki T, Jokura H, Yoshimoto T: Stereotactic guiding tube for open-system endoscopy: A new approach for the stereotactic endoscopic resection of intra-axial brain tumors. **Neurosurgery** 27:326-330, 1990.
14. Otsuki T, Yoshimoto T, Jokura H, Katakura R: Stereotactic laser surgery for deep-seated brain tumors by open-system endoscopy. **Stereotact Funct Neurosurg** 54-55:404-408, 1990.
15. Otsuki T, Yoshimoto T: A new approach for the endoscopic stereotactic brain surgery using high-power laser. **Optical Fibers Med VI SPIE** 1420:220-224, 1991.
16. Robinson JR, Awad IA, Little JR: Natural history of the cavernous angioma. **J Neurosurg** 75:709-714, 1991.
17. Roda JM, Alvarez F, Isla A, Blazquez MG: Thalamic cavernous malformation: Case report. **J Neurosurg** 72:647-649, 1990.
18. Schaltenbrand G, Wahren W: Atlas for *Stereotaxy of the Human Brain*. Stuttgart, Georg Thieme, 1977.
19. Scott RM, Barnes P, Kupsy W, Adelman LS: Cavernous angioma of the central nervous system in children. **J Neurosurg** 76:38-46, 1992.
20. Shelden CH, Jacques S, Lutes HR: Neurologic endoscopy, in Schmidek HH, Sweet WH (eds): *Operative Neurosurgical Techniques*. Orlando, Grune & Stratton Inc., 1988, pp 423-430.
21. Simard JM, Garcia-Bengochea F, Ballinger WE, Mickle P, Quisling RG: Cavernous angioma: A review of 126 collected and 12 new clinical cases. **Neurosurgery** 18:162-172, 1986.
22. Spiegel EA, Wycis HT, Szekely EG, Adams J, Flanagan M, Baird HW: Campotomy in various extrapyramidal disorders. **J Neurosurg** 20:871-884, 1963.
23. Suzuki J, Katakura R, Mori T: Interhemispheric approach through the lamina terminalis to tumors of the anterior part of the third ventricle. **Surg Neurol** 22:157-163, 1984.
24. Tagle P, Huete I, Mendez J, del Villar S: Intracranial cavernous angioma: Presentation and management. **J Neurosurg** 64:720-723, 1986.
25. Voigt K, Yasargil MG: Cerebral cavernous haemangiomas or cavernomas. **Neurochirurgie** 19:59-68, 1976.
26. Walker AE: Stereotactic surgery for tremor, in Schaltenbrand G, Walker AE (eds): *Stereotaxy of the Human Brain*. Stuttgart, Georg Thieme, 1982, pp 515-521.
27. Weil S, Tew JM, Steiner L: Comparison of radiosurgery and microsurgery for treatment of cavernous malformations of the brain stem. **J Neurosurg** 72:336A, 1990 (abstr).
28. Yoshimoto T, Suzuki J: Radical surgery on cavernous angioma of the brain stem. **Surg Neurol** 26:72-78, 1986.

### COMMENTS

This is a concise, well-written report about the use of a stereotactic guide tube and fine rigid endoscope to carry out resection of a cavernous malformation of the diencephalon. Drs. Otsuki and Yoshimoto have presented an excellent illustration of what can be achieved by combining the precision of stereotaxy with the optics of endoscopy to approach deep lesions in eloquent brain.

Endoscopes have been used to access almost every air- or fluid-filled cavity in the human body. Recent interest in endoscopic neurosurgery has focused primarily on disorders occurring within the clear fluid-filled cerebral ventricles. Otsuki and Yoshimoto have shown that endoscopes also may offer an alternative to the conventional management of lesions located deep in the cerebral parenchyma. Essentially, they have substituted a small rigid guide tube for brain retractors and a small rigid endoscope for the operating microscope, using miniaturized instruments and a fiber-optic laser to perform the surgical resection.

It can be difficult to establish a clear field of vision when working endoscopically within the substance of the brain. Visibility is somewhat improved when exploring cysts or evacuated hematoma cavities. The authors' method of irrigating through the endoscope's outer sheath was reportedly effective in maintaining visibility of the target. Another potentially limiting factor is endoscopic hemostasis, which sometimes can be difficult to achieve. The very factors that make endoscopic neurosurgery a minimally invasive procedure also make it difficult for the surgeon to handle significant bleeding should this occur. I would not recommend this approach for highly vascular lesions.

The authors have presented a very nice example of the use of stereotactic neuroendoscopy to remove a deep lesion in eloquent brain with minimal invasiveness. They have reported this technique of "open-system endoscopy" previously for removal of cavernous malformations and malignant parenchymal tumors <sup>(1)</sup>. Other neurosurgical applications include "closed-system endoscopy" to perform therapeutic procedures within the cerebral ventricles through burr

hole exposures and "endoscope-assisted craniotomy" to look around corners and limit the need for excessively large bony exposures at the cranial base.

**Alan R. Cohen**  
*Cleveland, Ohio*

**REFERENCES:** <sup>(1)</sup>

1. Otsuki T, Jokura H, Yoshimoto T: Stereotactic guiding tube for open-system endoscopy: A new approach for the stereotactic endoscopic resection of intra-axial brain tumors. **Neurosurgery** 27:326-330, 1990.

The paper of Otsuki and Yoshimoto presents the very skillful management of a patient with a deep-seated thalamic cavernoma with subthalamic hemorrhage. The indication for active treatment was given because of the symptomatic lesion. The authors show how important the combination of stereotactic guidance of the endoscope is. The special technique of Otsuki and Yoshimoto is to use an open 8-mm working tube, in which the thin 1.7-mm lens scope is placed, and the remaining diameter is free for the working instruments. With this equipment, it is possible to remove larger pieces of tissue and to have a larger action radius for the instruments under optic control. The technique described offers another example of how to combine microsurgical manipulation with endoscopic visual control for the surgery of deep-seated lesions, using the same philosophy as in surgery of deep-seated aneurysms to avoid retraction of important structures.

**Axel Perneczky**  
*Mainz, Germany*

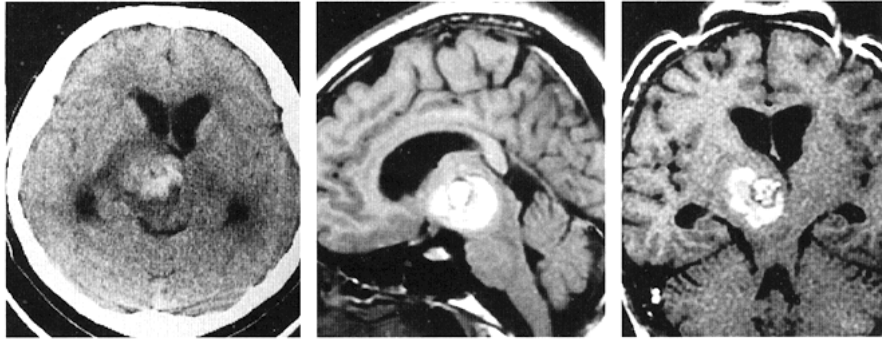


Figure 1. Preoperative CT scan and magnetic resonance (MR) T1-weighted images. *Left*, CT scan demonstrating a mixed-density lesion at the right subthalamic region and dilatation of the lateral ventricles. *Middle*, MR sagittal image showing a heterogeneous signal intensity lesion located at the subthalamic region extending to the cerebral peduncle. *Right*, MR oblique image, 45 degrees from the AC-PC line, obtained for surgical planning, demonstrating that the lesion is accessible from the frontal cortex through the anterior limb of the internal capsule.

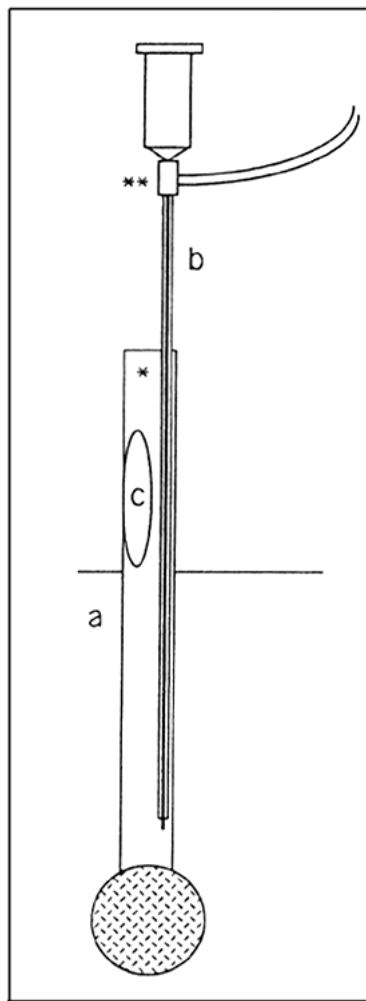


Figure 2. Diagram illustrating the equipment for open-system endoscopic surgery. *a*, Guide tube, 8 mm in diameter, fixed to one of the needle holders of a standard Leksell stereotactic frame at the proximal end (\*). *b*, Rigid endoscope, 1.7 mm in diameter, having an outer irrigation sheath, 2.2 mm in diameter, attached to the proximal needle holder of the Leksell apparatus (\*\*). *c*, Window to insert such microsurgical instruments as aspirators, flexible forceps, and laser fibers to resect an intraaxial lesion.

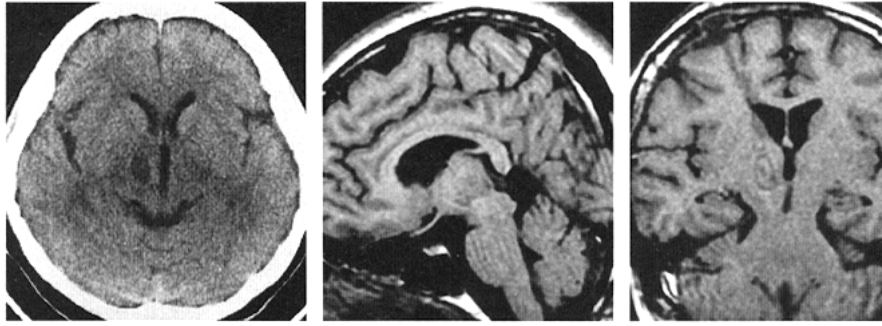


Figure 3. Postoperative CT scan and T1-weighted MR images. *Left*, CT scan performed 14 days after surgery showing total resection of the angioma and improvement in the ventricular dilatation. *Middle*, MR sagittal image obtained during the fourth postoperative week showing total resection of the angioma and the normalization of the configuration of the midbrain and the diencephalon. *Right*, MR oblique image, 45 degrees from the AC-PC line, obtained during the fourth postoperative week, demonstrating the fine line of the trajectory used to resect the angioma from the frontal burr hole through the anterior limb of the internal capsule.