

# Use of a Calcium Channel Blocker (Nicardipine HCl) in the Treatment of Childhood Moyamoya Disease

Syed A. Hosain, MD; John T. Hughes, MD; Sandra L. Forem, MD; Jeffrey Wisoff, MD; Irving Fish, MD

---

---

## ABSTRACT

Moyamoya disease is a cerebrovascular disease characterized radiologically by progressive narrowing and occlusion of the arteries contributing to the circle of Willis and its branches. There is formation of an exuberant collateral network of blood vessels at the base of the brain, which is thought to arise in response to chronic ischemia. Clinically, the course is variable, with patients having repeated transient ischemic attacks, strokes, migraine, and seizures. Effective treatment is not available. The etiology and pathophysiology of moyamoya disease are largely unknown. Two patients with arteriographically proven moyamoya disease were identified. Both patients were symptomatic before age 5 years. Despite successful encephaloduroarteriosynangiosis revascularization procedures, they continued to experience an inexorable downhill course. A calcium channel blocker (nicardipine HCl) was introduced in order to prevent further symptoms. After the introduction of nicardipine, no further strokes occurred in either patient. There were no further episodes of transient ischemic attacks, seizures, or headache in one patient and decreased frequency in the other. In patients with moyamoya disease, nicardipine may have a beneficial effect on cerebral hemodynamics and may prevent ischemic sequelae by optimizing existing collateral circulation. (*J Child Neurol* 1994;9:378-380).

---

---

Moyamoya disease is a peculiar progressive cerebrovascular disease first described by Shimzu and Takeuchi in 1966.<sup>1-5</sup> The Japanese term *moyamoya* describes the typical angiographic appearance, which consists of bilateral stenosis of the internal carotid arteries and basal telangiectasias, which are dilated collateral lenticulostriate and thalamoperforating arteries.<sup>2,6-9</sup> Children typically present with repeated transient ischemic attacks, strokes, seizures, involuntary movements, and migrainelike headaches. Adults, on the other hand, commonly present with subarachnoid hemorrhages due to rupture of aneurysms that form on the enlarged moyamoya vessels.<sup>10-12</sup> Aspirin, steroids, and low molecular weight dextran have not been effective in preventing the progression of the disease.<sup>13-15</sup> Surgical therapy may be helpful on occasion but is not entirely satisfactory. The most commonly employed treatment in children at present is a surgical revascularization procedure, encephaloduroarteriosynangiosis.<sup>16-20</sup> Prognosis in children is directly related to age of onset of symptoms: the earlier the onset of symptoms, the worse the outcome.<sup>10,21</sup>

Two patients with symptomatic moyamoya disease underwent encephaloduroarteriosynangiosis surgery but continued to have symptoms and signs of progressive deterioration despite angiographic evidence of revascularization. Both patients were given nicardipine hydrochloride, a calcium channel blocker known to dilate central nervous system vessels, in an attempt to alleviate their progressive symptomatology.

## CASE 1

T.D. is an 8½-year-old right-handed boy of Korean descent who was adopted at the age of 4½ months. Growth and development was normal until 3 years, when he developed sudden right-sided weakness. He was admitted to New York University Medical Center for evaluation. General physical examination was normal. Neurologic examination revealed a moderate right hemiparesis. Extensive blood workup and cardiac workup were normal. A computed tomographic (CT) scan of the brain showed a deep white-matter infarct in the left parietal region, and a cerebral angiogram showed moyamoya disease.

Thirty-six hours after the angiogram, T.D. developed another sudden episode of right-sided weakness, which improved partially over 5 days. Encephaloduroarteriosynangiosis revascularization was successfully performed on the left side on March 9, 1987, and on the right side on August 13, 1987. At the age of 3 years 10 months, T.D. developed sudden left-sided weakness and dysarthric speech. CT scan of the brain demonstrated old bilateral ischemic infarcts and a new infarct in the region supplied by the right middle cerebral artery. The weakness partially improved, and at the time of discharge, he was able to walk with

---

Received May 20, 1993. Received revised Dec 21, 1993. Accepted for publication Dec 22, 1993.

From the Departments of Pediatric Neurology and Pediatric Neurosurgery, New York University Medical Center, New York, NY.

This work was presented in part at the 21st Annual Meeting of the Child Neurology Society, New Orleans, October 22-24, 1992.

Address correspondence to Dr Irving Fish, New York University Medical Center, 550 First Avenue, New York, NY 10016.

assistance. Due to the continued clinical deterioration after surgery, a calcium channel blocker (nicardipine HCl) was started in November 1987 on a compassionate use basis. He was prescribed nicardipine 10 mg three times a day.

## CASE 2

T.M. is an 8½-year-old right-handed white girl. She was well until 4½ years of age, when she developed several episodes of sudden numbness in the left upper extremity, which resolved over minutes to hours. She also developed migrainelike headaches and was treated with aspirin and acetaminophen as needed, with some relief. Five months later, she had sudden onset of left-sided weakness and incoherent speech. This episode lasted for about 5 to 10 minutes and subsided without any residual deficits. Cardiac, blood, and urine workups were normal. A magnetic resonance imaging (MRI) scan of the brain at the time showed an abnormal vascular pattern at the base of the brain, and a cerebral angiogram revealed a vascular pattern consistent with the diagnosis of moyamoya disease (Figures 1 and 2). Because of this, bilateral revascularization procedures—encephaloduroarteriosynangioses—were performed.

One month after the second surgical procedure, the patient developed right arm and leg numbness, which rapidly resolved. She had a right focal motor seizure for which she was worked-up and placed on carbamazepine. An MRI of the brain performed at that time showed a new ischemic infarct in the white matter of the left parietal lobe (Figure 3).

Several months later, T.M. had another stroke, and she continued to have transient ischemic attacks, most frequently consisting of numbness or weakness of a limb.

In August 1989, in order to prevent further symptoms, a calcium channel blocker (nicardipine HCl) was introduced. She has been maintained on a dose of 10 mg three times a day without any adverse effects.

## RESULTS

In the 4½ years after the initiation of nicardipine HCl therapy in patient 1, no further signs or symptoms have occurred. MRI of the brain has not shown any new infarcts. Magnetic resonance angiography showed adequate revascularization and no further progression of moyamoya disease. In the 3½-year follow-up of patient 2, no strokes or transient ischemic attacks have occurred, but she continues to have migrainelike headaches and has had seizures despite therapeutic levels of carbamazepine.

## DISCUSSION

Moyamoya disease, especially when symptoms arise before age 5 years, is very often a progressive disease that ends either in death or severe permanent neurologic deficits. The ultimate course of the disease depends on the rapidity of the occlusive process and the patient's ability to develop adequate collaterals.<sup>22,23</sup> Since the original description of moyamoya disease by Shimzu and Takeuchi, studies on moyamoya disease have failed to satisfactorily elucidate the pathogenesis. Effective treatment is still not available. Surgical revascularization procedures are occasionally of benefit, but many of these patients continue to deteriorate neurologically. Pharmacotherapeutic agents, such as aspirin, steroids, and vasodilators have been tried in the past without success.

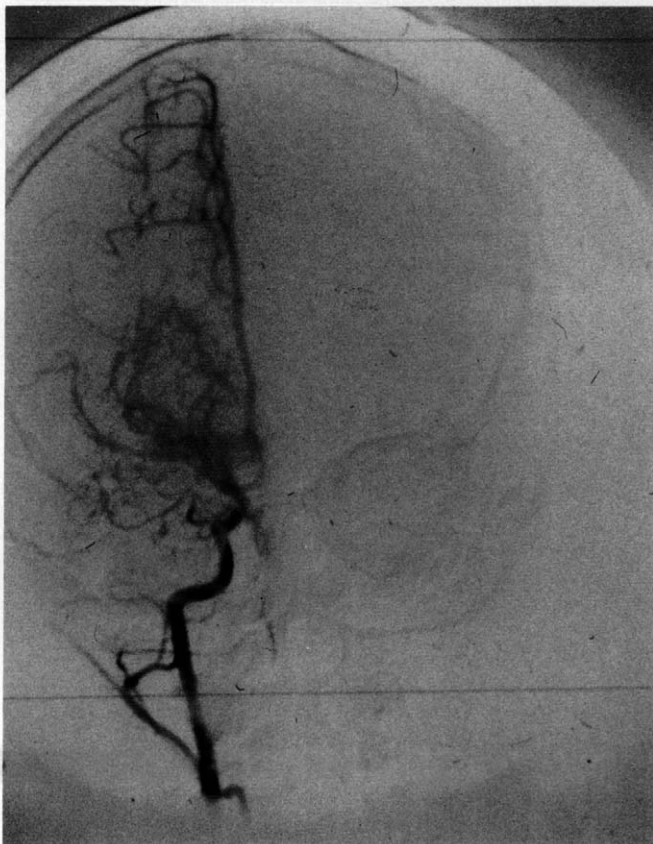

Figure 1. Right carotid angiogram of patient 2 (anteroposterior projection) showing narrowing of the internal carotid artery and prominent moyamoya vessels.

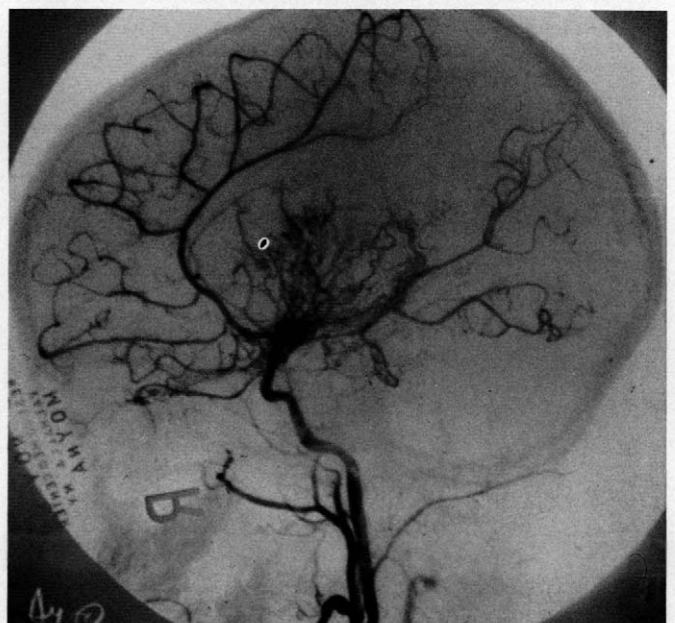


Figure 2. Right carotid angiogram of patient 2 (lateral projection) showing stenosis of the terminal internal carotid artery and its major branches with lush basal anastomosis.

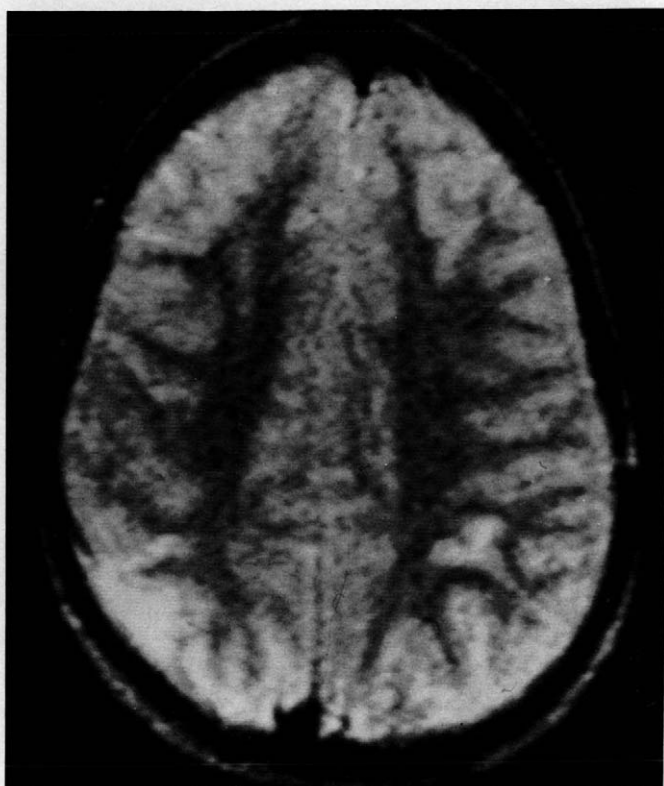

Figure 3. MRI showing a fresh ischemic infarct in white matter of left parietal lobe and an old infarct in the right posterior temporoparietal lobe. This MRI was obtained after the revascularization procedure.

McLean et al<sup>24</sup> reported a case of moyamoya disease in which intravenous verapamil, a calcium channel blocker, was thought to be effective during acute deterioration.

There have been no reports of the long-term use of an oral calcium blocker in childhood moyamoya disease. Nicardipine HCl proved successful in our two cases, both of whom had undergone encephaloduroarteriosynangiosis surgery and had shown adequate revascularization but continued to have symptoms. Calcium channel blockers perhaps optimize the dilation of the preexisting collateral vessels. Because of the vasodilating effect on cerebral arteries and the lack of adverse side effects, it is justifiable to use such a drug in moyamoya disease. We used 10 mg of nicardipine orally three times a day, and no side effects, such as dizziness, lowering of blood pressure, nausea, or palpitations, were reported.

## CONCLUSION

Two patients with documented moyamoya disease whose symptoms continued after successful encephaloduroarteriosynangiosis revascularization surgery were given nicardipine 10 mg three times a day orally on a chronic basis. After the introduction of nicardipine, their symptoms abated.

Further studies, both physiologic and controlled clinical trials, will have to be done to determine the place for calcium channel blockers in the treatment of this condition.

## Acknowledgments

We wish to acknowledge Vivian Catenaccio for her secretarial assistance. We wish to thank Syntex Corporation for providing the nicardipine hydrochloride.

## References

1. Suzuki J, Kodoma N: Moyamoya disease—a review. *Stroke* 1983;14:104–109.
2. Suzuki J, Takaku A: Cerebrovascular “moyamoya” disease. *Arch Neurol* 1969;20:288–299.
3. Suzuki J: *Moyamoya Disease*. Berlin, Springer Verlag, 1986.
4. Gordon N, Isler W: Childhood moyamoya disease. *Dev Med Child Neurol* 1989;31:103–106.
5. Maki Y, Enomoto T: Moyamoya disease. *Childs Nerv Syst* 1988;4:204–212.
6. Suzuki J, Takaku A, Asahi M: The disease showing the abnormal network at the base of the brain, particularly found in Japan. II. A follow-up study, in Japanese. *Brain Nerve* 1966;18:897–908.
7. Suzuki J, Kowada M, Asahi M, Takaku A: A study on disease showing singular cerebral angiographic findings which seem to be new collateral circulation. Proceedings of the 22nd Annual Meeting of the Japan Neurological Society, 1963.
8. Fukuyama Y, Umerzu R: Clinical and cerebral angiographic evolutions of idiopathic progressive angioocclusive disease of circle of Willis (“moyamoya” disease) in children. *Brain Dev* 1985;7:21–37.
9. Taveras JM: Multiple progressive intracranial arterial occlusion: A syndrome of children and young adults. *AJR Am J Roentgenol* 1969;106:235–268.
10. Matsushima Y, Aoyagi M, Niimi Y, et al: Symptoms and their pattern of progression in childhood moyamoya disease. *Brain Dev* 1990;6:784–789.
11. Adam HP, Kassell NF, Wisoff HS, Drake CG: Intracranial saccular aneurysm and moyamoya disease. *Stroke* 1979;10:174–179.
12. Kowada M, Momma F, Kikuchi K: Intracranial aneurysm associated with cerebrovascular moyamoya disease: Report of a case and review of 13 cases. *Br J Radiol* 1979;52:236–237.
13. Fukuyama Y, Kuriya Y, Imezu R: An experience of neurocorticosteroid hormone in childhood occlusion of circle of Willis, in Japanese, in *Annual Report of Special Working Group of Welfare Ministry of Moyamoya Disease in Fiscal Year 1980*. 1981, pp 45–51.
14. Suzuki J, Takaku A, Kodama N, Sato S: An attempt to treat cerebrovascular “moyamoya disease” in children. *Childs Brain* 1975;1:193–206.
15. Spittler JF, Smehtala K: Pharmacotherapy in moyamoya disease. *Hokkaido J Med Sci* 1990;2:235–240.
16. Matsushima T, Fiyiwara S, Nagata S: Surgical treatment for pediatric patients with moyamoya disease by indirect revascularization procedures (EDAS, EMS, EMAS). *Acta Neurochem* 1989;3–4:135–140.
17. Ou MV, Griebel RN, Hoffman HJ: The surgical treatment of childhood moyamoya disease. *J Neurosurg* 1987;66:675–680.
18. Matsushima Y, Iwaba Y: Moyamoya disease in children and its surgical treatment. Introduction of a new surgical procedure and its follow-up angiograms. *Childs Brain* 1984;11:155–170.
19. Miyamoto S, Kikuchi H, Karasawa J, et al: Pitfalls in the surgical treatment of moyamoya disease. *J Neurosurg* 1988;68:537–543.
20. Cahan LD: Failure of encephaloduro-arterio-synangiosis procedure in moyamoya disease. *Pediatr Neurosci* 1985–1988;12:58–62.
21. Kurokawa T, Tomita S, Ueda K, et al: Prognosis of occlusive disease of circle of Willis (moyamoya disease). *Pediatr Neurol* 1985;5:274–277.
22. Yoshihara M, Yutaka I: The specificity of the collaterals to the brain through the study of surgical treatment of moyamoya disease. *Stroke* 1986;17:117–122.
23. Eller W, Pasternak JF: Revascularization of moyamoya disease. Five year follow-up. *Surg Neurol* 1987;28:463–467.
24. McLean MJ, Gebarski SS, Van der Spek AF, Goldstein GW: Treatment of acute deficits of moyamoya disease with verapamil. *Ann Acad Med Singapore* 1985;1:65–70.