

# Functional Segregation of Color and Motion Processing in the Human Visual Cortex: Clinical Evidence

Lucia M. Vaina

Intelligent Systems Laboratory, Departments of Biomedical Engineering and Neurology, Boston University, Boston, Massachusetts 02215, Center for Biological and Computational Learning, Massachusetts Institute of Technology, Boston, Massachusetts, and Departments of Neurology and Surgery, Brigham and Women's Hospital, Harvard Medical School, Boston, Massachusetts 02115

Anatomical and physiological investigations indicate two major distinct functional streams within the extrastriate visual cortex of the macaque monkey, and behavioral observations suggest that the ventral (occipitotemporal) pathway is the cornerstone for object recognition whereas the dorsal (occipitoparietal) pathway is primarily involved in visuospatial perception and visuomotor performance. In the context of this dichotomy we conducted a psychophysical and neuropsychological study of visual perceptual abilities in two stroke patients, each with lesions involving several extrastriate areas. Magnetic resonance imaging demonstrated bilateral lesions; in one patient (E.W.) the lesion involves the ventral medial portions of the occipital and temporal lobes, and in the other (A.F.) the lesion involves dorsally the occipital-parietal area, including the region of the temporal-parietal-occipital junction. E.W. suffers from achromatopsia of central origin, prosopagnosia, visual agnosia, and alexia without agraphia. His depth and motion perception, including recognition of moving objects, are normal. He has superior visual field loss bilaterally, and slightly impaired acuity, and complains that the world appears in a deep twilight even on a sunny day. In contrast, A.F. shows specific deficits of stereopsis, spatial localization, and several aspects of motion perception. He is also impaired at recognizing objects presented from unconventional views, but recognition of prototypical views of objects, and color and form discrimination are normal, as is his ability to recognize faces.

The anatomical characteristics of the lesions of these two patients permit a direct experimental comparison of the effects of lesions confined to the parietal or temporal pathways. E.W.'s and A.F.'s performance on the psychophysical and neuropsychological tasks discussed here supports the functional distinction between a dorsal and a ventral extrastriate system but additionally suggests the existence of a pathway involved in identification-from-motion that is separate from *both* the dorsal early motion/spatial analysis pathway and the ventral color/static-form pathway.

Studies of the visual system of the macaque monkey provide the best structural and physiological model of the human visual system. Both they and we are Old World primates, and the physiology and anatomy of the macaque visual system are well studied. At subcortical levels, the anatomy of the macaque brain is very similar to our own. At the cortical level, a great deal is now known about the macaque but relatively little is known about the human visual system.

A wealth of anatomical and physiological studies concerned with the characterization of visual properties in the extrastriate regions of the macaque have led to the hypothesis that each of these areas is specialized in a particular aspect of vision. In one of the most influential schemes for the functional parcellation of extrastriate visual cortex, Ungerleider and Mishkin (1982) propose two major "parallel" streams of processing, both originating in V1. One stream progresses toward the temporal lobe via V4, and is involved in the analysis of visual information relevant to object recognition. The other stream courses toward the parietal lobe via MT, and is indispensable for the perception of visual information relevant to spatial position and visuomotor coordination. Recently, this sharp separation in the visual system has been challenged (for a critical review, see Merigan and Maunsell, 1993) partly due to the discovery of abundant interconnections among the extrastriate areas (for review, see Felleman and Van Essen, 1991). However, abundant cross-connections at various stages between extrastriate visual areas in functionally different pathways are still consistent with anatomical segregation over substantial portions of the parietal and temporal pathways (Merigan and Maunsell, 1993). For example, interconnections may evoke one pathway to suppress another in the mechanism of selective visual attention. Most of the direct comparisons that have been made between the parietal and temporal pathways emphasize primarily the contributions to visual analysis of areas MT and V4. The major distinctive properties of these areas appear to be strong selectivity to motion in MT, accompanied by indifference to color and form, and conversely conspicuous selectivity for color and orientation in V4 along with insensitivity to changes in motion. The selectivity for color persists along the occipital-temporal pathway (Gross et al., 1972), whereas the selectivity for motion-related information persists along the occipital-parietal pathway (Bruce et al.,

1981; Van Essen and Maunsell, 1983; Cowey and Marcar, 1993; Marcar and Cowey, 1993).

Functional segregation between the properties of the parietal and temporal pathways in humans has also been demonstrated in PET studies of normal subjects. Most notably, Watson et al. (1993) and Zeki et al. (1991) have shown substantial spatial segregation in cortical activation when subjects view color or moving stimuli, and Haxby et al. (1991) showed similarly separate patterns of activation when subjects perform a spatial task underlying either judgements of face recognition or spatial relationships. Consistent with neurophysiological data, these neuroanatomy studies support the model of a major segregation of the extrastriate visual cortex into at least two functional streams.

This segregation is reinforced by studies of lesions in restricted regions of the human visual cortex, which often lead to specific deficits in visual perception. Vaina (1989) showed that patients with occipital-temporal lesions are impaired at discriminating form whether it is defined by orientation differences (texture), stereopsis, or motion, yet their performance is normal on a large class of motion discrimination tasks. The converse holds for patients with occipital-parietal lesions, whose perceptions of motion and stereopsis are impaired, although their form discrimination ability is generally unaffected. [There is, however, evidence that large parietal lobe lesions do not impair global stereopsis in monkeys (Cowey, personal communication), while temporal lobe lesions do (Schiller et al., 1993).] Vaina et al. (1989) and Rizzo et al. (1992) presented evidence for the dissociation of color and motion perception in patients with central achromatopsia. Although in humans such well-circumscribed lesions are even more rarely exactly where one would want them to be, it is important to study their effects psychophysically for a number of reasons. First, it helps to map areas in human visual cortex that are homologous and/or analogous to areas in monkeys where we can learn much more about the cell physiology and connective anatomy. Second, verbal reports by human subjects of damaged visual percepts are incomparably more detailed and informative than purely psychophysical data from animals with specific lesions. When the link between human and monkey visual cortical areas can be made with greater confidence, it will be much clearer how to interpret properties of cells in a given functional/anatomical area.

In this study we report the results of detailed psychophysical and neuropsychological tests from two patients (E.W. and A.F.) who have bilateral lesions in conjunction with particularly selective visual deficits. Patient E.W. showed deficits in color discrimination in the total absence of deficits in motion perception. Patient A.F. showed the opposite pattern of deficits; that is, he was impaired on motion but not color. A.F.'s visual motion deficits have been discussed before (Vaina et al., 1990a,b). Although other perceptual deficits were found concurrently, the present results provide further support for the idea that different visual cortical streams process color and motion aspects of vi-

sual stimuli. Furthermore, the location of these human cortical areas is consonant with the general scheme of parietal and temporal pathways of information processing proposed in the monkey visual cortex (Ungerleider and Mishkin, 1982; Ungerleider and Desimone, 1986; Maunsell and Newsome, 1987) and dealing respectively with the position or the identity of objects.

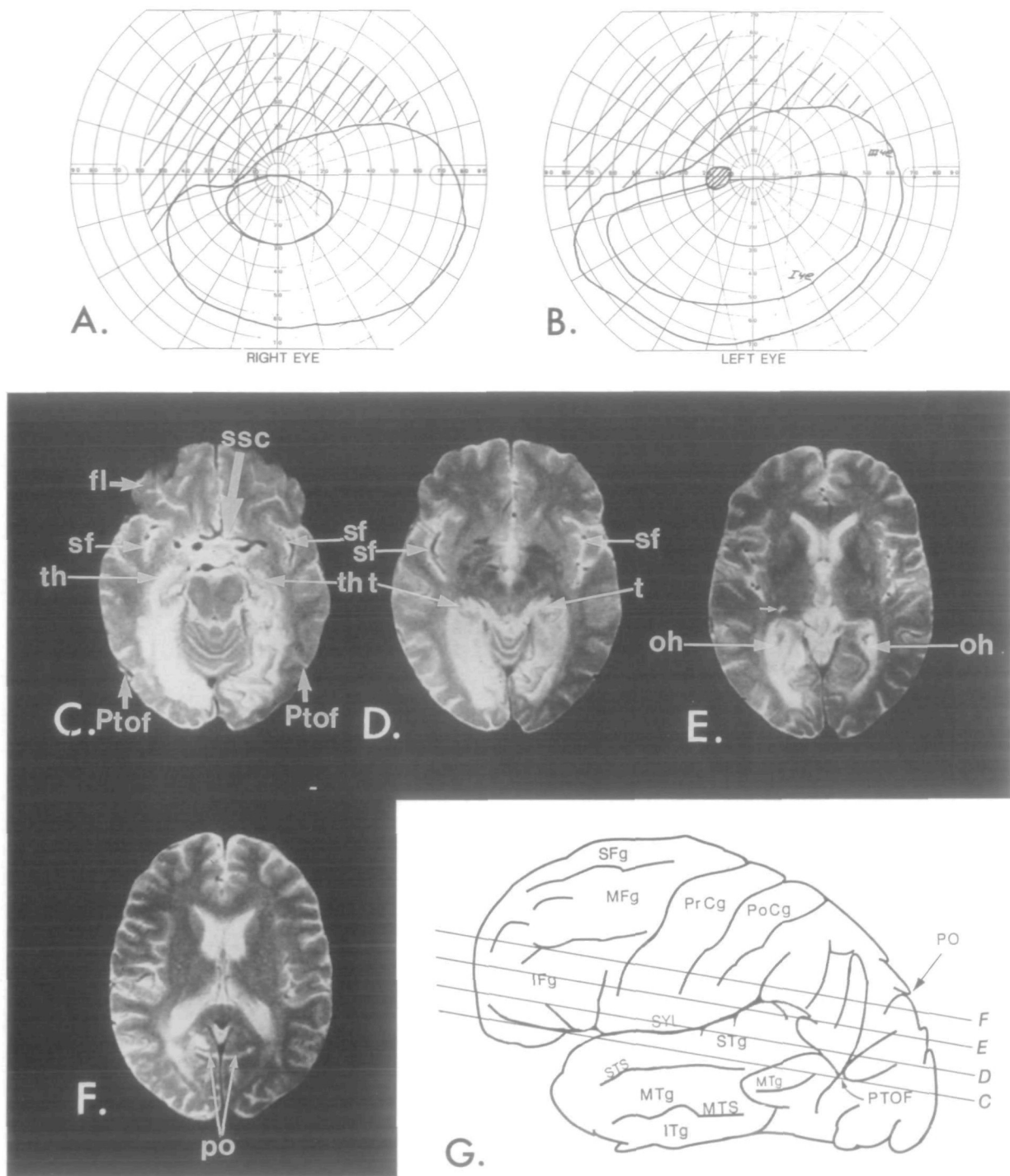
### The Patients

The localization of the lesion in both patients was done by magnetic resonance imaging (MRI), and acuity, visual fields, and eye movements were measured formally in neuro-ophthalmological examinations. Both patients underwent a detailed evaluation of their perceptual abilities concerning form, color, motion, binocular stereopsis, and their abilities to recognize objects and actions. Normal subjects naive as to the purpose of the tasks used in this study were used as control subjects. The two patients and the control subjects gave written consent to all the procedures after they had been explained.

#### Case 1: E.W.

E.W. is a 63-year-old right-handed man, a retired high-school science teacher who was referred to us for the clinical evaluation of perceptual and cognitive deficits. His neurological problems date from March 1988, when he suffered a right occipitotemporal infarction. He was then maintained on anticoagulation therapy with Coumadin, which was stopped in July 1988 when he underwent surgery for the removal of a colonic polyp. A few days later he developed headache, nausea, vomiting, gait instability, and global visual changes. The patient's clinical condition was consistent with a new left occipitotemporal cerebrovascular accident (CVA) that was revealed by MRI studies.

The neuro-ophthalmological investigation revealed normal fundus in both eyes, normal pupils, and normal optokinetic nystagmus. Acuity was 20/40 in both eyes without correction. Visual fields on Goldmann perimetry (Fig. 1A,B) demonstrated a superior latitudinal defect in both eyes that is characteristic, although not diagnostic, of patients with cortical achromatopsia (Meadows, 1974). The MRI obtained at the time of our study (Fig. 1C-F) showed bilateral occipital lobe lesions, more extensive in the right hemisphere than the left. The lesions extend ventrally into the medial temporal area, involving the hippocampus and parahippocampal gyrus, and slightly into the parietal lobe, medial and posterior to the trigone of the lateral ventricle. The neurological examination did not reveal any paresis, ataxia, akinesia, or apraxia and there were no somatosensory deficits, including stereognosis. On neuropsychological evaluation, the results on subtests of the Wechsler Adult Intelligence Scale Revised (WAIS-R) showed that his score on the verbal scale (VIQ = 136) was above average, whereas on the performance scale he showed a severe deterioration from the premorbid level (PIQ = 76). Memory, especially visual and topographic, was severely impaired. Problem-solving ability and reasoning were remarkably



**Figure 1.** Visual fields and MRI of patient E.W.'s brain 3 months following a hemorrhagic stroke and the localization of the axial scans on the lateral view of a human brain. *A* and *B* show E.W.'s visual fields by Goldmann perimetry. The *crosshatched area* shows E.W.'s bilateral upper visual field loss. Isopters for targets *I4e* and *III4e* are indicated. *C-F* show axial slices of E.W.'s T2-weighted MRI studies (Tr, 2000 msec; Te, 80 msec) revealing large lesions, consistent with infarcts, along the medial margins of both temporal lobes (*C*), into the medial portions of the occipital lobes. The posterior portion of the lesion in the left hemisphere does not extend quite as far medially as in the right hemisphere. Some small slight patchy hyperintense areas are seen at the cortical margin of the right posterior temporal-parietal-occipital region of the right hemisphere (*C, D*), suggesting some tissue loss as well, but the margins of the area are not well-enough defined to be certain of discrete tissue loss. *E* extends through the frontal and occipital horns of the lateral ventricles. The lesion in the right hemisphere extends about the margins of the occipital horn of the lateral ventricle, extends up higher than on the left, and is still seen behind and slightly lateral to the body of the right lateral ventricle (*A*). It also extends up medially to the occipital horn, in front and behind the parietal-occipital sulcus. Numerous bright foci are also seen scattered in the basal ganglia; the most prominent one (*small white arrow*) lies at the lateral posterior margin of the right thalamus. For *C-F* (Figs. 1 and 2): *bl*, body of the lateral ventricle; *fl*, frontal lobe; *h*, hemosiderin; *oh*, occipital horn of the lateral ventricle; *po*, parietal-occipital sulcus; *ptof*, parietotemporo-occipital fossa; *ssc*, suprasellar cistern; *t*, trigone of the lateral ventricles. For *G* (Figs. 1 and 2): *IFg*, inferior frontal gyrus; *ITg*, inferior temporal gyrus; *MFg*, middle frontal gyrus; *MTg*, middle temporal gyrus; *MTS*, middle temporal sulcus; *PO*, parietal occipital sulcus; *PoCg*, postcentral gyrus; *PrCg*, precentral gyrus; *Sfg*, superior frontal gyrus; *STg*, superior temporal gyrus; *STS*, superior temporal sulcus; *SYL*, Sylvian fissure; *PTOF* is the parietal-temporal-occipital fossa from Polyak (1957, Fig. 271), which several authors have suggested corresponds to the human homolog of the macaque MT. The *horizontal lines* denote the levels of the axial slices corresponding to *C-F*.

good. There was no discernable aphasia or agraphia. Calculations were normal. Copying was excellent. In contrast, drawing from memory was very impaired. Thus, when asked to draw a banana, which he could copy very well, he drew a large L-shaped form with the corner well emphasized.

E.W. had persistent significant visual deficits consistent with central achromatopsia, prosopagnosia, loss of topographic memory, alexia without agraphia, and visual object agnosia. He reported that the world looked as if in a continuous "twilight and drained of color." His prosopagnosia was extremely severe, he was not able to recognize any of the members of his family or to identify himself in a recent photograph, and he could not identify any particular objects beyond their general category. He could, however, recognize people by their voice, posture, and gait. At the hospital he could recognize familiar nurses as soon as they moved, but when they were seated in front of him he failed to identify any of them. E.W. could see letters and words, but could not identify them. He could write well, and legibly, but was not able to read his own writing (alexia without agraphia). In occupational therapy and at home he went through many sessions of retraining his reading of letters and words, but he did not make any progress by the time of this study (2 months after the second stroke).

He had severe deficits in recognizing familiar objects, photographs, and drawings (visual object agnosia), and was unable to find his way even in the most familiar surroundings (topographic agnosia). Even when he recognized objects, such as shoes or clothing items, for example, he could not distinguish between those that were his own and those that belong to someone else, such as his son or son-in-law, for example.

#### **Case 2: A.F.**

Details of patient A.F. have been reported in detail in Vaina et al. (1990a) and are summarized here. A.F. is a 60-year-old left-handed man, retired from a white-collar job, who suffered an acute hypertensive hemorrhage that required emergency hospitalization and subsequently the evacuation of a large hematoma. The neurological examination did not reveal any paresis, ataxia, akinesia, or apraxia. An MRI study (Fig. 2C-F) showed bilateral lesions involving the temporal-parietal-occipital junction. The right hemisphere lesion was larger than the left but both extended dorsally into the posterior parietal lobes. The left hemisphere lesion shows tissue loss from an old infarct extending along the lateral margin of the lateral ventricle and around the margins of the occipital horn, going upward posterior to the body of the lateral ventricle and into the medial portion of the parietal lobe.

Visual field charted by Goldmann perimetry revealed a dense congruous loss of the left inferior visual field bilaterally (Fig. 2A,B). There was a minimal loss in the upper visual field. Letter acuity with appropriate correction glasses was 20/30. On the examination of ocular motility there was no strabismus, and saccadic eye movements were normal both to the

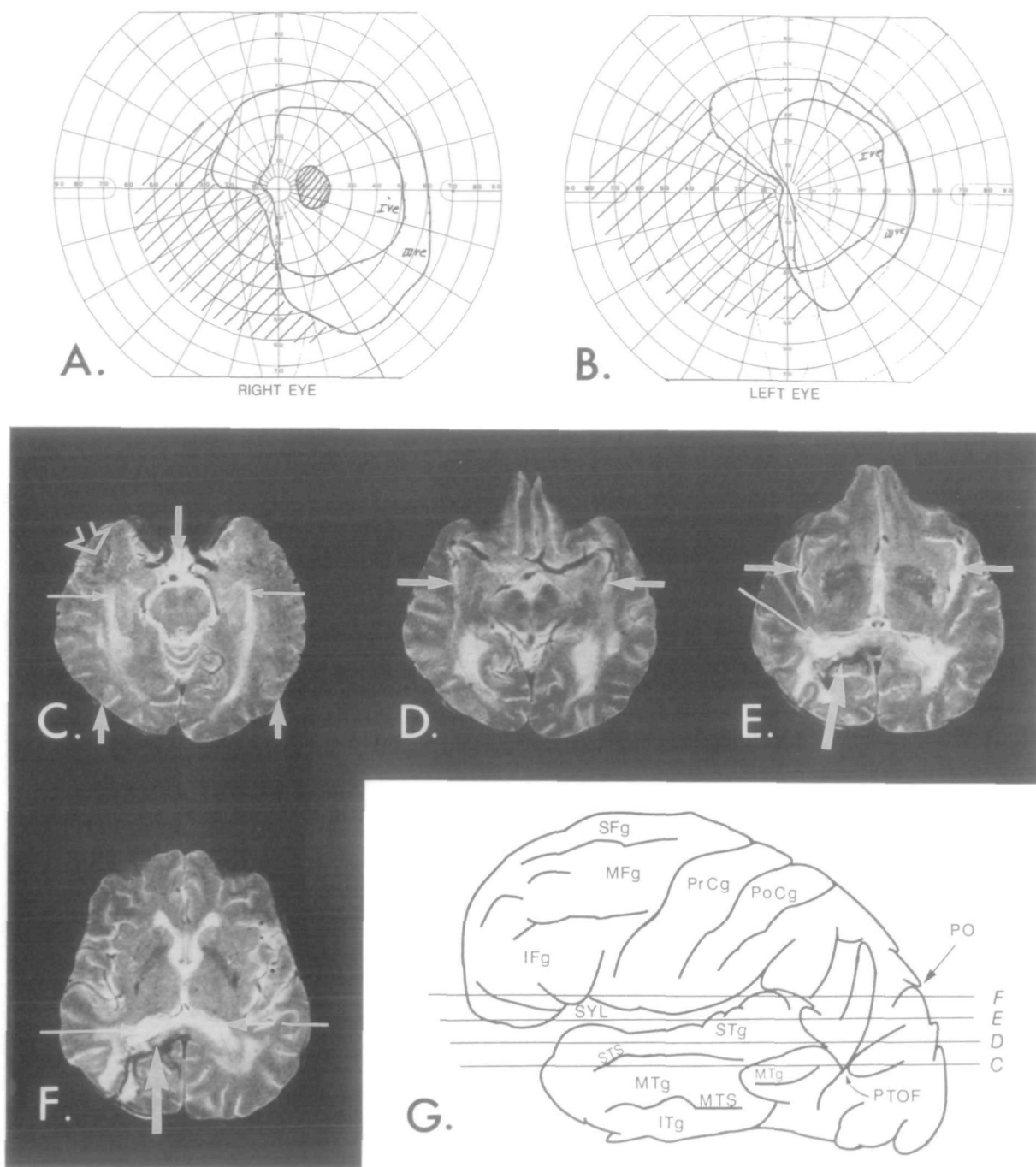
right and to the left. He substituted saccades for smooth pursuit when following a smoothly moving target. This occurred both to the right and to the left. He was unable to maintain fixation of left lateral gaze and tended to drift back toward the central fixation.

Though arm movements were intact and he could clearly perceive objects in the visual field, he was somewhat inaccurate in touching objects placed in his reach (more in the left visual field than in the right). He complained of difficulties with reading and written calculations, but he showed no deficits in oral calculations. Copying and drawing were poor and lacked perspective. Printing in uppercase letters was very disorganized when he wrote looking at the page, but when blindfolded or when writing cursive he was not impaired. The difficulties of reading and writing in print were entirely derived from his inability to locate letters and numbers on the page under visual control. As expected, writing cursive with lowercase letters was good, since this does not require specifically visual positioning of each individual letter. On basic neuropsychological evaluation with the WAIS-R, A.F. obtained an average VIQ of 104 and a severely depressed PIQ of 68.

#### **General Methods and Results**

The psychophysical tasks for assessing the patients' contrast sensitivity and perceptual abilities for form, motion, and spatial location were generated and presented by an Apple Macintosh IIx computer on standard Apple monitors (the Pelli attenuator was used in the contrast sensitivity tests for displaying low-contrast stimuli). The monitor was 13 inches along the diagonal with a frequency of the vertical retrace interrupt of 67 Hz. Viewed from 60 cm from the screen, a pixel subtended  $2 \times 2$  arcmin. In most tests, stimuli were displayed by the constant stimuli method to compute the percentage of correct responses to stimuli with graded level of difficulty. In the contrast sensitivity and motion coherence tests stimuli were presented by a staircase procedure. In all the motion tasks random dots were used to minimize familiar position cues and to isolate the detection of motion per se, because in such displays it is impossible to track the individual elements across frames by a shift in attention (Nakayama and Tyler, 1981). All the computer-presented tasks were conducted at photopic light levels. Every new test was introduced by examples to assure that the subject understood the task. During the example session feedback was given. For the computer-presented tasks, each trial was initiated by the subject by pressing a specially designated key and observers were asked to maintain fixation on a small black mark in the center of the display. An exception to this was the motion coherence task, in which the stimuli were presented separately in each visual field and the subjects fixated on a mark placed  $2^\circ$  to the left or to the right of the border of the stimulus aperture.

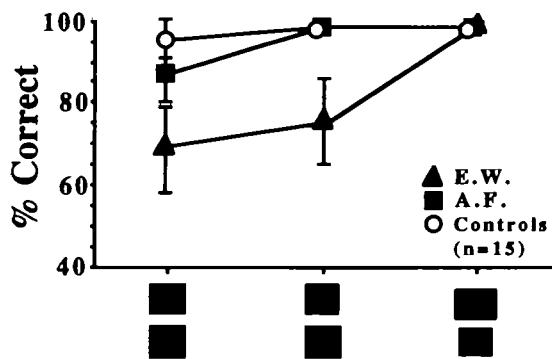
Binocular stereopsis was measured with the clinical Randot test (Randot Stereotests, Stereo Optical Co., Chicago, IL) and with a set of stereograms from the



**Figure 2.** Visual fields and MRI of patient A.F.'s brain 3 months following a hemorrhagic stroke and the localization of the axial scans on the lateral view of a human brain. Perimetry results obtained on the Goldmann perimeter are shown in A and B. Isopters for targets 14e and III4e are given, as well as the dimensions of A.F.'s bilateral congruous loss of the left inferior visual field and a small loss in the upper visual field (crosshatched area). C-F are the relevant slices in axial view of T2-weighted MRI studies (Tr, 2000 msec; Te, 80 msec; see G). In C the picture shows the temporal horns of the lateral ventricles and some patchy hyperintensities at their margins, more on the right. In D the picture shows local tissue loss in the right hemisphere at the sites of the hemorrhagic stroke in the parietal lobe just medial to the occipital horn of the lateral ventricle and anterior to the parietal occipital sulcus. There is also some patchy hyperintensity in the temporal lobe along the lateral margin of the right occipital horn. Localized hyperintense areas are seen in the left temporal lobe adjacent to the lateral proximal margin of the occipital horn and in the margins of the occipital horn. E and F show bilaterally larger patchy areas of hyperintensity posterior, medial, lateral, and above of the trigones and at the margins of the bodies of the lateral ventricles. Tortuous narrow bands of hemosiderin (labeled h) are seen in both images at the site of the recent hemorrhage. G, A schematic drawing of adult human brain showing the major gyri and sulci in lateral view.

series generated by Julesz (1971). For evaluating color vision, both patients were given the Farnsworth-Munsell 100 Hue Test (Farnsworth, 1943). Two additional color tasks were given to E.W. since he was clinically diagnosed as having central achromatopsia: a classical

wavelength discrimination task and flicker photometry to measure the photopic spectral sensitivity. These tests were done by the method of adjustment. Neuropsychological tasks of perceptual categorization (silhouette matching, Gollin pictures, unusual views) and



**Figure 3.** Shape discrimination task: percentage correct performance of five normal controls and of E.W. and A.F. on shape discrimination for three ratios plotted as decreasing difficulty.

of object and face recognition were presented as drawings or as photographs.

### Contrast Sensitivity

The patients' contrast sensitivity for 1D gratings was measured with the Vistech chart<sup>1</sup> (Vistech Cons. Inc., Dayton, OH) and with computer-displayed sinusoidal gratings. In the computer-based test, both static and moving stimuli were used, with spatial frequency ranging from 0.4 to 5 cycles/degree. E.W. and A.F. scored within the normal range for both the detection and discrimination of static and moving stimuli (direction).

### Static Form Perception

#### Shape Detection

This is a task of figure-ground discrimination closely adapted from Warrington and Taylor (1973). The stimulus consists of a fragmented background on which was superimposed a fragmented letter, either an X or an O. The degree of difficulty of the detection was manipulated by varying the ratio of black to white in the figure in relation to the black/white ratio in the background. This was a yes/no task in which the subject had to report whether the letter was present in the display. Both A.F. and E.W. obtained perfect, 100% correct scores.

#### Shape Discrimination

This task is a close replication of Efron's "square" test (Efron, 1968; Warrington and James, 1988). The target stimulus was a square  $5^\circ \times 5^\circ$  and the distractors were oblongs with one areal dimension of  $5.25^\circ \times 4.77^\circ$ ,  $4.6^\circ \times 5.5^\circ$ , or  $6.5^\circ \times 4^\circ$  (Fig. 3; shapes under the plot represent each particular shape pair). For each of these dimensions 10 squares and 10 oblongs were presented for 0.5 sec, singly in pseudorandom order. Subjects were asked to judge whether the shape was a square or an oblong.

A.F.'s performance on this task was normal. E.W.'s performance was in the impaired range as compared with age-matched normal control subjects and with A.F., except for stimuli that differed by the largest ratio of the lengths of the sides of one of the components

## Perceptual Categorization Tasks

### Matching Silhouettes to Objects

In this test, the subject is asked to first pick out the photograph that correctly matched a silhouette of an animate object (kangaroo, giraffe, dog, cow, horse) or an inanimate one (roller skates, truck, doll, train, car), and then to name or describe the objects. The silhouettes and the target objects were photographed from prototypical, front view. All 10 silhouettes and the 10 colored photographs of the corresponding objects were shown side by side. A.F. scored 100% correct on this task. E.W. also was able to match correctly all silhouettes to photographs of objects even if he could not identify the object (e.g., roller skates were identified as "an animal, a cat?").

### Unusual Views

This test, adapted from Warrington and Taylor (1973), consists of black-and-white photographs of common objects shown from an unconventional angle but still in a relatively familiar view. Visual difficulty is manipulated by changing the angle from which the object is photographed. The observer is asked to recognize the objects presented in an unusual view. The patients who fail this task are subsequently asked to identify the same objects presented from a front view (the conventional view). Since, as discussed in detail in the next section, E.W. could not recognize objects presented even in the prototypical, front view, we did not give him this test. The test is very sensitive to right posterior parietal lobe damage (Warrington and Taylor, 1973), and as expected, A.F. was severely impaired on it. He could recognize all these objects when presented as photographs taken from the usual, canonical view. When presented with pictures of noncanonical views of a bucket or a basket, for example, A.F. described them as "a slice taken from the trunk of a tree," a glove he described as an "overshoe or a boot," and a frying pan as a "magnifying glass."

### Gollin Pictures

This test consists of a graded series of incomplete outline drawings of objects (Gollin, 1960). There were in total five drawings for each item. An error score was obtained by summing the number of additional drawings of the stimulus required for correct identification. A.F. was given 14 total stimuli. E.W. was so severely impaired on visual recognition of objects that tasks that manipulate visual complexity of objects were inappropriate. We did, however, administer a short exploratory test using only seven stimuli.

A.F. scored 29 of 52, which is worse than the 5% cutoff score in the normal population. For E.W. it was meaningless to apply the usual scoring procedure, since he was unable to recognize the objects. Nonetheless, his responses were interesting. Similar to the recognition of photographs or of full drawings of objects, when an incomplete drawing contained a relevant feature of an animate object, such as the legs, he could correctly assign the drawing to the correct category. Thus, for example, a cow was in the first at-

tempt described as "a four-legged animal," and even when the full drawing was shown, he could not provide a more specific description. The only item that he could identify correctly when presented as a complete drawing was the pig: "the cute curly tail, must be a pig." However, when he was shown any drawing of an inanimate object, he often could not identify it even when the full drawing was presented.

### **Recognition: Faces, Objects, and Actions**

In addition to his inability to discriminate colors of objects, E.W. failed to recognize even the most familiar faces and was severely impaired on object recognition. These deficits were noted by the patient himself and by his family and people surrounding him. In contrast, A.F. had no problems in this area and since his results on the neuropsychological tests in this section were totally unremarkable, they will not be discussed further.

#### **Face Recognition**

Facial recognition ability was tested informally. E.W. always knew when he was looking at a face and he quickly and accurately noted missing parts in incomplete drawings of faces. However, he consistently failed to identify whose face it was, and could not even recognize himself in a photograph. Family photographs were meaningless to him; he described them as "a bunch of people together." He was unable to judge correctly the age or the mood of photographs of faces, and could not interpret accurately the emotional content of photographs or drawings of faces. This failure to recognize facial expression (i.e., sadness, happiness, surprise, anger, or fear) was more pronounced with static expressions, as shown in drawings or photographs. However, when a facial expression was pantomimed in front of him, he carefully observed the movement and could recognize quite accurately, although hesitantly, the specific face expression. When asked to mimic sadness, anger, surprise, or happiness, his facial expressions were always accurate.

#### **Recognition of Objects and Actions**

E.W. failed to recognize real objects and colored pictures, although by making use of specific details he was usually able to identify the general category (e.g., a four-legged animal) but not the subordinate category of the object (a dog). It did not matter whether the objects were shown as 3D reproductions of the real object or as colored or black-and-white photographs. Although he almost always failed to recognize the stimulus as a whole, often he quickly identified a salient part of the stimulus and used it as a basis for reasoning about the possible identity of the object. For example, when shown (without being allowed to touch it) a gray toy elephant that was a veridical reproduction of an elephant, at first he said that he had no idea what it was, but then continued, "long nose, big ear, busy ears, prehensile nose, the only animal with prehensile nose is . . .hmm, elephants have big noses, they are gray or brown, but this is not an ele-

phant, elephants have a trunk, this is not a trunk, is a hell of a nose. This is a wild, ferocious animal." When he took it in his hand, he passed the fingers around it, slowly, and said "still I don't know, some strange beast! with four legs." However, when he looked at an excerpt of a videotape showing an elephant walking in the field, he immediately recognized it—"an elephant!" He described the picture of a cow as "an animal in disguise, the ears do not give a clue, skinny legs, big body, could be a dog," a horse as "a dog, its gait is common to dogs and horses," a seal as "it has whiskers, so may be it is meant to be a cat. No tail, very unrealistic," and a fly as "a four-legged animal with wings. That's strange, no flying animal has legs." Recognition of inanimate objects was even more impaired. He described a little blue toy car as a "four-legged animal," and he still continued to describe it as a four-legged animal when he held it in his hand. When shown a picture of a telephone he described the telephone cord in detail, but failed to put together the object "for the foot, that goes around the ankle, to secure it," the picture of an ice-cream bar as "a torch, a lantern," and a camera as "a clock, some man-made thing."

In contrast, his recognition of drawings of actions (i.e., dancing, fighting, exercising, riding a bicycle, hammering, sawing) and of pantomimed actions was perfect. When he watched television he could correctly identify actions with no difficulty. He was able to characterize gaits accurately (e.g., sporty, tired, limping) and without failure could recognize people by how they moved. He loved watching sports on television and he could anticipate accurately the moves of the players.

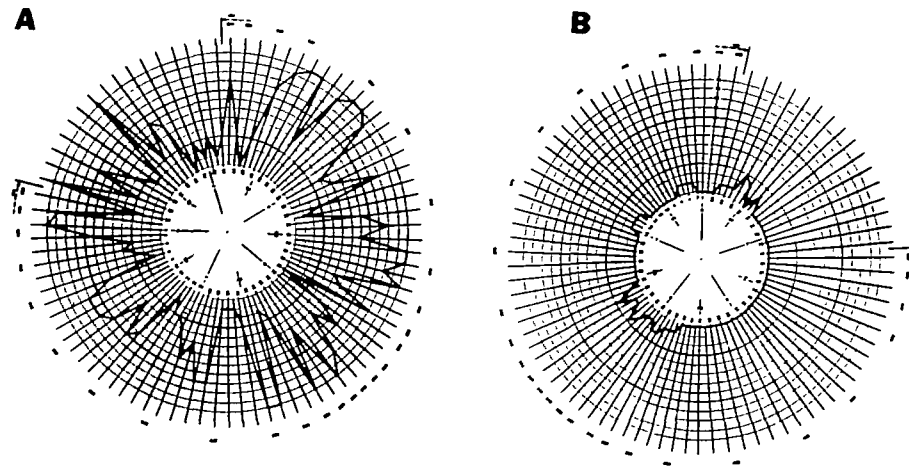
#### **Color Perception**

##### **The Farnsworth-Munsell 100 Hue Test**

This is a test of color discrimination, consisting of 85 chips of different hues, in four groups. The patient is given all chips in one group and is asked to arrange them in a line according to hue. The first and last chip are fixed at the ends of the group and serve as a frame of reference. Figure 4, A and B, shows that while E.W. was severely impaired on this task, A.F.'s score was normal.

##### **Wavelength Discrimination**

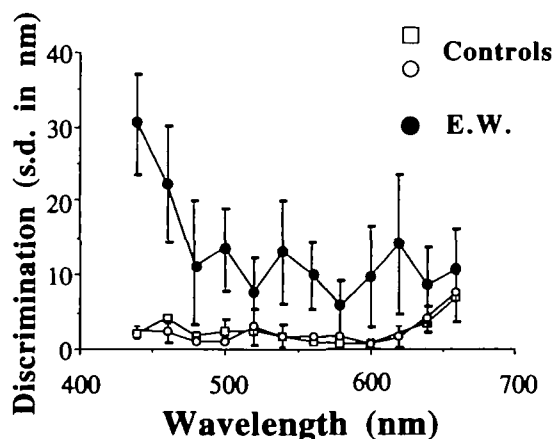
In order to look at the wavelength discrimination deficits of E.W. in more detail, he was tested additionally as follows (since no color deficits were obvious in A.F., his color vision was not tested further). The output of two slit monochromators (slit bandwidth = 10 nm) was projected, side by side, onto a plain white screen. The relative luminance of the two monochromators was systematically varied by interposing neutral density filters into the light path, out of sight of the subject. The reference monochromator was set at a fixed wavelength (440–640 nm, in 20 nm steps). E.W. was asked to match, as closely as possible, the color of the reference monochromator by adjusting the second monochromator until the colors appeared equal. Four



**Figure 4.** Results of the Farnsworth-Munsell 100 Hue Test from E.W. (A) and A.F. (B). Errors are plotted radially, and position on the circumference represents points along a continuum of hue.

values were taken for each reference wavelength. The standard deviation of these values from the reference was calculated for E.W. and two normal controls, as a measurement of wavelength discrimination abilities (Fig. 5).

The shape and the values of the wavelength discrimination curves for the two normal control subjects are typical of normal observers described in earlier studies (e.g., Wright, 1947). Relative to the controls, discrimination values for E.W. are clearly elevated, as one would expect from an "achromatopic" subject. However, the figure shows that discrimination values were clearly better than random, and apparently better on long-than short-wavelength settings. Though E.W. complained initially that he could not discriminate colors at all, he could in fact discriminate one end of the spectrum from the other, and never matched a red with a blue, or vice versa. However, the subject did take an extremely long time (>1 min) to make each match, and expressed little confidence in the final values. This is in contrast to his quick, confident, and good performance on the motion tasks.

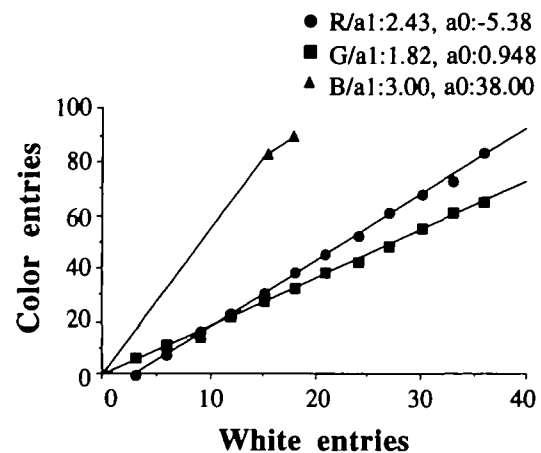


**Figure 5.** Results from E.W. and two normal control subjects on the wavelength discrimination test.

#### Photopic Spectral Sensitivity

Like the previous task, this task was used solely with E.W. Flicker photometry at 15 Hz was done on a CRT screen, in which E.W. was asked to match the luminance of white to either the blue, green, or red gun over a range of luminance values (1–21 cd/m<sup>2</sup>). The results of the test are shown in Figure 6, which shows luminance values of the red, green, and blue guns of the stimulus CRT, at values matched by E.W. to the luminance of a white patch with which it was alternating. For each of the three colors, the function relating white luminance to color luminance is essentially linear, indicating that the spectral sensitivity does not change in shape over this range in luminances; that is, there is no Purkinje shift. Second, the values of the color/white ratios given by E.W. were entirely within the normal range; that is, the photopic spectral sensitivity curve was normal.

We also tested the equiluminance point somewhat informally. The subject viewed either a red-green



**Figure 6.** Results from E.W. on the flicker photometry test. The figure shows luminance values of the red, green, and blue guns of the stimulus on the CRT, at values matched by E.W. to the luminance of a white patch against which the stimulus was flickering. For each of the three colors, the function relating white luminance to color luminance is essentially linear.



square wave or a sine wave grating, in which the intensities of the red and green could be independently and continuously varied. There was no point, in either type of stimulus, at which the grating appeared as a uniform field to E.W., although the stripes appeared much more faint at intensity values corresponding to expected normal equiluminance values.

#### *Color Ordering and Naming*

The stimuli consisted of colored Munsell papers differing in saturation and hue. All the hues were represented by  $3 \times 5$  cm rectangular patches that were presented binocularly in a random arrangement on a neutral gray flat surface. There were 15 papers in each of three widely separated parts of the spectrum, namely, reds, yellow/greens, and blues. The first task was to put the color patches of similar hues into a smooth order of color. The second task was to name the colors. A.F. showed no deficits on the color ordering and naming task. E.W. could name and choose colored patches of paper at levels somewhat above chance, but often used brightness cues to make the choices. He could not distinguish blues, greens, and grays, and had difficulties with reds and yellows. Thus, similar to his performance on the wavelength discrimination task, E.W. was better at discriminating and naming long wavelengths than short wavelengths. He could correctly, but effortfully and slowly, name yellows (578 nm) and reds (630 nm) but not blues (480 nm), which he described variously as blue, green, or yellow. Apparently this ability to identify long-wavelength hues prevented him from making widely discrepant matches on the wavelength discrimination task.

#### *Binocular Stereopsis*

Static binocular stereopsis was first measured with the Randot Stereotest (Stereo Optical Co., Chicago, IL) and with red-green stereopatterns from the series generated by Julesz (1971). In both tests, in 75% of the trials with binocular fusion a central figure (e.g., letter E or T, a square, a circle, a triangle, or a star) stands out in front of the surround. In the remaining 25% of the trials the display contained only random dots.

The Randot test uses random dot stereograms printed on polarized cards. With appropriate polarized glasses each eye views a different image. The test measures stereoacuity in a series of stereograms of different disparities. In Julesz's random-dot stereograms, when viewed monocularly, each target appears as a random array of small light and dark squares in which no form or depth is apparent. The two random-dot patterns are identical except that in one pattern a contiguous cluster of dots in the central region has been displaced laterally with respect to the same region in the other pattern. The patterns were printed in pale red and green ink. When viewed with a green filter over one eye and a red filter over the other, the central figure is seen in front of the surround. We used 16 random-dot stereograms with the disparity ranging between 120 and 300 arcmin. In both stereotests, the subjects' task was to say whether they saw a central figure standing away from the surround and then to

identify the shape of the figure (e.g., a square, a triangle in different orientations, a star, or a circle). E.W.'s performance on binocular stereopsis was intriguing. In both tests, he reported correctly that he perceived a figure and he correctly identified the random-dot patterns in which there was actually no figure present. Asked to draw what he saw in the random-dot patterns, he reproduced the forms perfectly and then (often without looking at it) he could correctly identify it. In contrast, A.F. lacked binocular stereopsis; in all the displays he reported seeing in the random-dot stereograms "just dots, no pattern or form at all." Surprised by his failure on these tests, A.F. commented that in the past he enjoyed resolving anaglyphs of Julesz's type like the ones he was looking at now, and that years ago he used to watch 3D movies and had never had any problems with depth vision.

#### *Spatial Perception*

##### *Point Discrimination*

The task consisted of two adjacent squares (each subtending  $6^\circ \times 6^\circ$ ), one with a black dot (subtending 4 arcmin<sup>2</sup>) printed in the center and the other with a black dot printed off center (the task is similar to that described by Warrington and James, 1988). From trial to trial the deviation of the dot from the center varied from 2 arcmin to  $2^\circ$ . For each trial the assignment of the dot to the center of the square or off center was random, but so that in 50% of the trials the left-hand square contained the dot in the center. In a two-alternative forced-choice task and constant stimuli, the observers were asked to choose the point that was in the center of the square. E.W.'s score was perfect on this task. A.F. scored 60% correct when the off-center dot was off by  $1^\circ$  or less. For larger offsets his performance was perfect, thus indicating that he did not have any difficulties in understanding the task per se.

##### *Discrimination of Line Orientation*

Line orientation discrimination was evaluated with a task developed by Benton (Benton et al., 1977) that is widely used in clinical neuropsychology for the assessment of spatial perception abilities. The stimulus consists of two lines oriented at an angle between  $0^\circ$  and  $180^\circ$  (the target), and 11 line segments arranged in a semicircle radiating outward from the center. The subject must decide which two lines among the 11 lines exactly match the orientation of the two target lines. All the lines have equal length. E.W.'s score was almost perfect (59 of 60). On the other hand, A.F.'s score of 31 of 60 suggests a severe deficit of spatial perception.

##### *Spatial Discrimination*

A basic task of spatial discrimination is that of line bisection. The patient is presented with a line and asked to mark the central point. Thirty lines of different lengths and orientations were used. A.F. was severely impaired on this task (2 of 30). He was not able to mark accurately the center of lines, even if the examiner placed them carefully within his intact visual

field. (At close examination, A.F.'s errors did not reveal a specific pattern.) In contrast, E.W. indicated correctly the center of the all the lines presented (30 of 30).

#### *Spatial Location*

The stimuli consist of two outline squares, one containing 14 randomly placed symbols (single digit numbers and letters) and the other containing a small black square subtending  $5.6 \text{ arcmin}^2$  (MacQuarrie, 1953). The subject's task is to identify the symbol in the top square corresponding to the position of the black mark in the bottom square. A.F. scored 50% correct (10 of 20), which was at a severely impaired level (his scores were below the 5% scores obtained in an age-matched control group; Warrington and James, 1988). E.W.'s performance was normal.

#### *Motion Perception*

We tested several aspects of motion perception. The tests and A.F.'s performance are described in detail in Vaina et al. (1990a,b). In the first three tasks we wanted to learn whether E.W. and A.F. could see form or boundary from differences in motion in neighboring spatial regions. These tasks use highly coherent dense motion fields to address the problem of perceptual segregation by different motion cues. The next three tests evaluate the patients' ability to discriminate speed in randomly moving dots, to detect coherent motion defined by a small number of dots embedded in noise, and to perceive 3D structure solely from motion cues. Finally, we addressed E.W.'s and A.F.'s ability to identify different patterns of biological motion only from the trajectory of a small set of moving points.

#### *2D Form from Motion*

The sensation of two moving textured planar surfaces was elicited by two patches of contiguous random dots uniformly displaced from one frame to the next in horizontal translational motion across the random-dot display that formed the stationary background (Fig. 7A). The subjects are asked to determine whether the two translating forms have the same shape (square, circle, triangle, cross, or oblong). Both subjects performed normally on this task (Fig. 7B).

#### *Boundary from Differences in Motion Direction*

This test (adapted from Hildreth, 1984) is described in detail in Vaina et al. (1990a) and Vaina and Grzywacz (1992). In summary, the display (subtending  $10^\circ \times 10^\circ$ ) contains two adjacent regions translating coherently, but in different directions, thus producing a discontinuity in the velocity field (Fig. 7C). The discontinuity appears as an imaginary vertical line with a notch. The notch (subtending  $1.4^\circ \times 1.4^\circ$ ) was always presented within  $2^\circ$  above or below the center of the imaginary boundary. Five angular differences between the two areas are used:  $18.4^\circ$ ,  $37.1^\circ$ ,  $45^\circ$ ,  $90^\circ$ , and  $180^\circ$ . In a two-alternative forced-choice procedure the observers are requested to determine whether the notch was above or below the center of the display. E.W.'s score was perfect on this task. A.F. also scored

well, except for the smallest angle ( $18.4^\circ$ ), for which his performance was impaired (Fig. 7D).

#### *2D Form from Relative Motion*

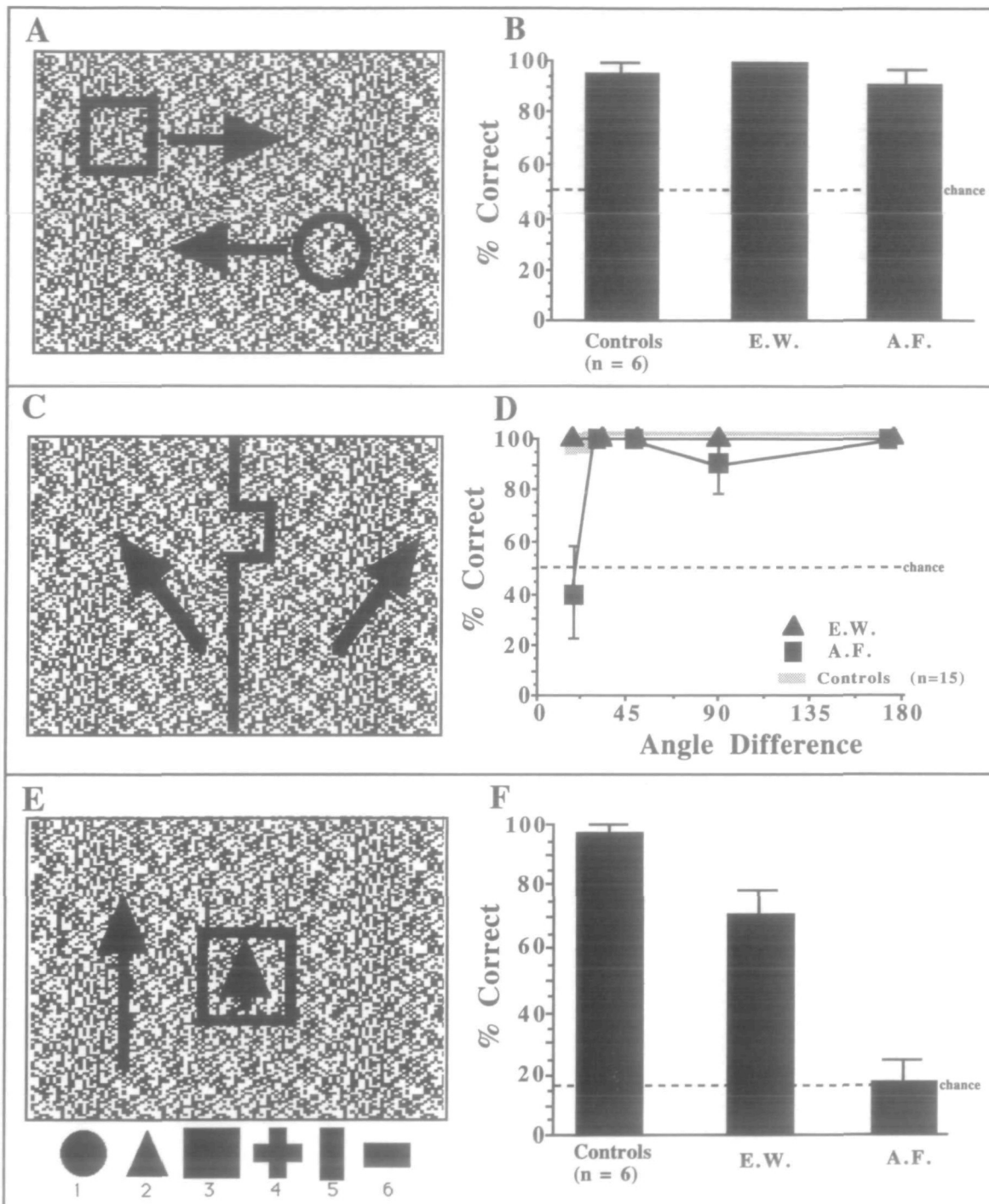
This task (described in Vaina et al., 1990a) involves comparison of velocity magnitude without any difference in direction. An example of the display is portrayed in Figure 7E. In summary, the figure (subtending roughly  $2^\circ \times 2^\circ$ ) is presented roughly in the middle of a  $6^\circ \times 3.75^\circ$  aperture consisting of a dense random-dot pattern. Both the figure and the background are displaced in the same direction but with different speeds. In 60% of the trials the background speed was slower than the figure and in 40% of the trials the background was faster than the figure. The speed ratios between the figure and the background using as a reference the speed of the background ( $3^\circ/\text{sec}$ ) had the following values:  $3/2$ ,  $2$ ,  $3$ ,  $2/3$ , and  $1/2$ . Observers were asked to make a six-alternatives forced-choice judgment indicating which of the six figures displayed at the bottom of the screen constituted the correct match for the moving shape. There were 60 trials and each one of the six shapes was the correct answer 10 times.

The results for this experiment are shown in Figure 7F. The normal control group had near perfect performance, approximately 95% correct, whereas A.F.'s was strikingly impaired. His score of 17% correct responses was at chance level. E.W.'s score was below that of the normal controls but still significantly above chance (70% correct).

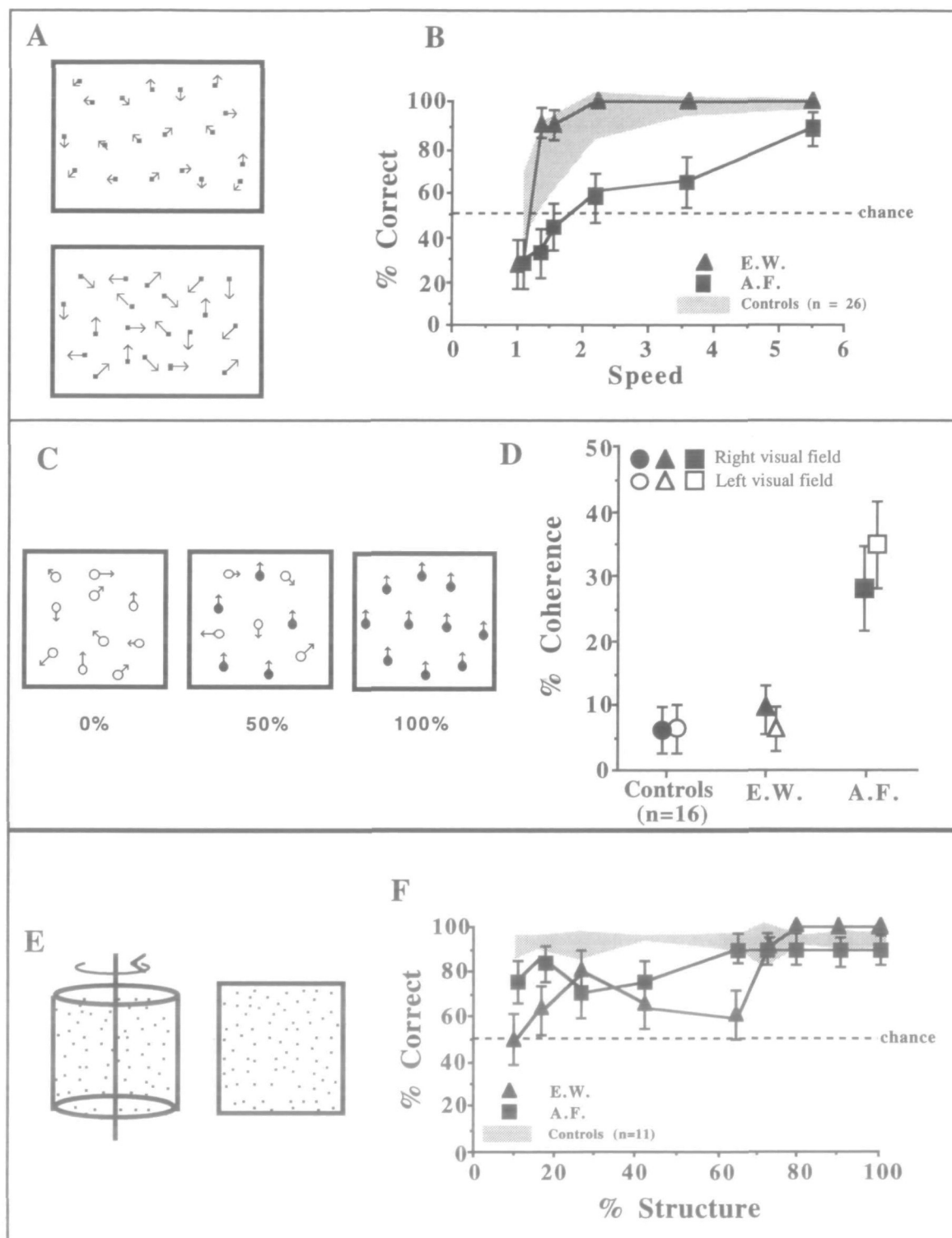
#### *Local Speed Discrimination*

The stimuli consist of two sparse dynamic random-dot kinematograms each comprising 20 computer-generated dots. The kinematograms were displayed in two rectangular apertures arranged one above the other, each subtending an area of  $4^\circ \times 2.5^\circ$ , thus giving a dot density of 2 dots/degree<sup>2</sup> (Fig. 8A). The distance between the centers of the apertures was  $2.75^\circ$ . In any single trial each dot took an independent, 2D "random-walk" of constant step size defined by the speed. The direction in which any dot moved was independent of its previous direction and also of the displacements of the other dots. The speeds of the dots, defined as a function of the distance a dot was displaced between successive frames, was uniform within an aperture and was assigned independently for each aperture. A base speed of  $3^\circ/\text{sec}$  was always compared to five other speeds, giving five speed ratios of 1.1, 1.47, 2.2, 3.6, and 5.5. The assignment of the highest speed to the top or bottom aperture was pseudorandomly selected.

Subjects were asked to determine which of the two apertures contained the faster moving dots. A two-alternative forced-choice procedure was used for measuring the subject's ability to detect difference in speed. In comparison to the age-matched control group, and E.W., who was performing almost perfectly for 2:1 speed differences, A.F. had a severe deficit on this task (Fig. 8B). He failed to discriminate reliably speed ratios smaller than 5.5 and was performing near



**Figure 7.** Motion tasks. *A*, 2D form from motion in a static background. The display consisted of a fine-grained (pixel size = 1.72 arcmin) random-dot pattern containing 50% black and 50% white dots. Two patches of contiguous dots were coherently translated across the static background and with equal speeds. The observer's task was to determine whether the two translating 2D shapes were the same or different. *B*, Percentage correct responses as a function of correct matches of the moving shapes. The graph shows the mean percentage correct responses and error bars for E.W. and A.F. and mean percentage of correct responses and standard deviations for the normal control group. *C*, Boundary localization test. The differential movement of the two adjacent areas of the pattern reveals a boundary with a rectangular notch defined solely by the difference in the directions of motion of the two areas. The position of the notch and of the invisible dividing line between the two areas in relative motion vary randomly within 1° on the x-axis. The *heavy square* indicates the fixation mark. *D*, Percentage correct responses for correctly identifying the location of the notch (above or below the fixation mark) for the following angular differences of directions of motion between the two areas: 18.4°, 37.1°, 90°, and 180°. The *shaded area* indicates the percentage of correct responses of the control group  $\pm 1$  SD obtained under identical conditions. *E*, 2D form from differences of velocity magnitudes: illustration of the stimulus. The background scrolls vertically and a central patch of contiguous dots subtending  $2^\circ \times 2^\circ$  moves in the same direction as the background with different speed. The shape of the central patch is randomly assigned to one of the six shapes illustrated on the bottom of the display. *F*, The bar graphs plot percentage correct responses of the total number of trials for E.W. and A.F. and for the normal controls together with the standard deviation for the normal group and the SE of the patients.



**Figure 8.** Motion tasks. *A*, Local speed discrimination: a schematic representation of the stimuli employed. The display consisted of two sparse random-dot fields each displayed in a rectangular aperture subtending  $4^\circ \times 25^\circ$ . Within each aperture the dots, plotted here as vectors, move in random distributed directions with constant speed. The observer's task is to decide in which of the two apertures the dots move faster. *B*, Results for E.W., A.F., and normal controls. The graphs plot the percentage of correct answers as a function of the speed ratios between the two apertures. *C*, Motion coherence: schematic representation of the dynamic random-dot stimuli employed. Each stimulus presented dots in rapid succession and each dot survived for a brief period of time before being replaced. In the 0% correlation case (*left*) the replacement dots were plotted at random locations within the aperture so that the dot field appeared as twinkling visual noise without motion in any single direction. In the 100% correlation case (*right*) each dot was replaced by a partner with a constant offset in space and time, so that the dot field appeared to move in a single coherent direction. For intermediate states, such as that for 50% correlation displayed in the *middle*, a prespecified percentage of the dots carried the correlated motion signal while the remaining dots provided a dynamic masking noise. The stimulus is presented  $2^\circ$  to the left or to the right of a fixation mark. A four-alternative forced-choice procedure was used to determine the threshold correlation for which observers could successfully discriminate the direction of motion. *D*, The graph plots the threshold correlation for normal controls and E.W. and A.F. *E*, Structure from motion, schematic representation of the two dynamic random-dot fields employed. On the *left* is portrayed the structured stimulus generated by the

chance when normal observers and E.W. were performing better than 90% correct.

### *Motion Coherence*

This task is adapted from Newsome and Paré (1988) and the specific test used here is described in detail in Vaina et al. (1990a). In summary, the stimuli were dynamic random-dot kinematograms with a correlated motion signal of variable strength embedded in motion noise. The strength of the motion signal, that is, the percentage of the correlated dots moving in the same direction, varied from 0% to 100%. For strengths less than 100%, the dots carrying the motion signal were embedded in a field of dots moving in random directions. The direction of signal flow could not be determined by following a single dot because the signal and the noise dots were spatially intermingled, and between frames varied in assignment between the signal and the noise group. Thus, to do the task, the subject was required to detect the global direction of flow, which involved integrating the motion signal over the whole display. The percentage of signal intensity for which a subject could reliably discriminate the direction of motion, up, down, left, or right, constituted the threshold (Fig. 8C). The stimulus consisted of a dynamic random-dot display presented in a square  $10^\circ \times 10^\circ$  aperture situated at  $2^\circ$  left or right of a white fixation mark. The subject is instructed to maintain fixation on the fixation mark for the entire testing period. Dot density used in this test was 2 dots/degree<sup>2</sup>. [Other densities were explored but the range of densities used did not have an effect on performance. This is consistent with the findings of Downing and Movshon (1989) in the similar displays.] The speed of motion, defined as a function of the distance a dot is displaced between successive frames, was  $3^\circ$ /sec.

E.W.'s score was normal for presentation in either visual field. A.F., on the other hand, had elevated thresholds for motion coherence for stimuli presented in either visual field (Fig. 8D). It is possible that this deficit demonstrates a deficit of spatial integration of motion signal, or an inability to filter out motion noise (Baker et al., 1990; Pasternak et al., 1991; Pasternak and Merigan, 1994).

### *3D Structure from Motion: The Rotating Cylinder*

This experiment examined the patients' ability to recover 3D information from the relative motions of elements in the changing 2D image. [A similar task has been used by Siegel and Andersen (1988) in monkeys with MT lesions.] The display (Fig. 8E) consisted of two dynamic random-dot kinematograms presented simultaneously, each subtending an area of  $3^\circ \times 3^\circ$ . Each kinematogram was composed of 128 dots with an average point density of 14 dots/degree<sup>2</sup>, which ap-

peared to be optimal for the normal control group. At the end of its lifetime the point disappeared and was replotted at a new random location on the screen (within the boundary of each display) and it began a new trajectory. One kinematogram (structured display) portrayed the dots painted at random location on the orthographic projection of a transparent rotating imaginary cylinder, and the other (unstructured) showed a pattern of scrambled velocities. The angular velocity of the cylinder rotating around its vertical axis was  $30^\circ$ /sec. The maximum distance traveled by a dot between two consecutive frames was 4.3 arc-min. The dots had limited point-lifetime (400 msec). The percentage of structure, that is, percentage of dots actually projected on the imaginary surface of the rotating hollow cylinder, varied as follows: 100%, 90%, 80%, 70%, 65%, 42%, 27%, 11%. The spatial positions (left vs right) of the structured field and the unstructured field were randomly assigned. There were 20 trials for each condition (in total 160 trials).

For high percentage of structure in the cylinder both patients scored very well on this task (Fig. 8F). Both patients scored close to the normal control group for fractions of structure in the cylinder above 42%. As the proportion of noise increased, the patients' performance dropped significantly. Since for A.F. this was similar to the level of noise that he could tolerate in the motion-coherence task, it is possible that his structure-from-motion recognition was limited by his ability to cope with noise in the stimulus.

### *Biological Motion Recognition*

Johansson (1973) demonstrated the sufficiency of biological motion for form perception by placing lights on the points of articulation of a human actor in darkness. The form of such an actor remains obscure while the person is static or even while the light points translate without any articulation. But as they articulate, the shape becomes immediately obvious. The only information available in the display is provided from the dynamic source alone. The display shows only the pattern of lights attached to the joints of the human actor during the performance of some prototypical actions: walking, stair climbing, riding a bicycle, push-ups, two men walking, shaking hands, and hugging. The stimulus was presented to E.W. and A.F. on a videotape using scenes from the original Johansson movie. Both E.W. and A.F. had perfect scores on this test. They quickly recognized that the movement of the lights portrayed a man and correctly identified all the actions.

### *Topographic Disorientation*

E.W.'s topographic memory was very poor. His family described that when going for a walk in the neighborhood, E.W. could not remember how to get back

---

←  
orthographic projection of a square-shaped random-dot velocity field onto a transparent cylinder that is rotated. On the *right* is portrayed a velocity field representing the unstructured stimulus. The dot survival time and the percentage of structure in the structured stimulus were independently varied in the display. F, Comparison of E.W.'s and A.F.'s results with normal controls where percentage of structure was varied in the cylinder (point lifetime was constant at 400 msec).

**Table 1**

A qualitative summary of E.W.'s and A.F.'s results on the static psychophysical tasks

Test results	E.W.	A.F.
Contrast sensitivity	Normal	Normal
Shape detection	Normal	Normal
Shape discrimination	Impaired	Normal
Farnsworth-Munsell test	Impaired	Normal
Wavelength discrimination	Impaired	N/A
Photopic spectral sensitivity	Impaired	N/A
Color naming	Impaired	Normal
Binocular stereopsis	Normal	Impaired
Line orientation	Normal	Impaired
Point location	Normal	Impaired
Spatial location	Normal	Impaired

"N/A," task was not administered to the subject; "Normal," patient's results are not statistically different from the results of the normal controls; "Impaired," patient's scores are significantly below those of the age-matched normal controls ( $p < 0.05$ )

home or which street to turn on, and that when they returned to their street he did not recognize it as familiar. He thought that the neighbor's house, a few doors down the street, was theirs. In general he failed to use familiar landmarks to find his way around. In contrast, A.F. had no deficits in this area.

### Discussion

The focus of this study was the comparison of results on visual-cognitive and psychophysical tasks in two patients with focal bilateral brain lesions. The patients' results on the psychophysical tasks are summarized in Tables 1-3.

The results show that these patients present a clear-cut dissociation of deficits at the earlier stages of visual processing. E.W. was impaired on color and form discrimination, but not on motion or stereopsis. He was also impaired on perceptual categorization and recognition of objects and faces, but he could recognize correctly actions, even in degraded stimuli (biological motion task). A.F. was impaired on spatial relations, binocular stereopsis, and motion, but not on form and color discrimination. He was also impaired on aspects of perceptual categorization, but faces and object recognition were normal, as was his ability to recognize biological motion.

In both patients localization of lesions by MRI

**Table 2**

A qualitative summary of E.W.'s and A.F.'s results on the motion tasks

Test results	E.W.	A.F.
2D form from motion	Normal	Normal
Boundary by direction difference	Normal	Good
2D form from speed difference	Good	Impaired
Speed discrimination	Normal	Impaired
Motion coherence	Normal	Impaired
3D structure from motion	Normal	Normal
Biological motion	Normal	Normal

"Good," patient's results are below those of the normal controls, with a statistical significance of the difference in the range of  $0.05 < p < 0.2$ .

**Table 3**

A qualitative summary of E.W.'s and A.F.'s results on the visual recognition tasks

Test results	E.W.	A.F.
Face recognition	Impaired	Normal
Matching silhouettes to objects	Normal	Normal
Gollin pictures	Impaired	Impaired
Unusual views	N/A	Impaired
Object recognition (drawings)	Impaired	Normal
Object recognition (objects)	Impaired	Normal
Memory for objects	Impaired	Normal
Topographic memory	Impaired	Normal

showed involvement of the visual association cortex. A.F.'s lesions were relatively dorsal, involving the parietal-occipital-temporal junction bilaterally. He has severe motion deficits. PET scan studies done by Zeki and his collaborators (Zeki, 1991; Watson et al., 1993) suggest that the region activated during the perception of movement in humans coincides with the heavily myelinated region labeled by Flechsig (1920) as area 16. This region probably includes the homolog of the macaque MT complex and higher motion-responsive areas (e.g., MST, FST). Several studies suggested that the human homolog of area MT corresponds to the occipital-parietal-temporal fossa (area PTOF of Polyak, 1957), or in Brodmann terms to the junction of the area 19 and the inferior portion of area 37 (Miezin et al., 1987; Tusa and Ungerleider, 1988; Vaina et al., 1989; Clarke and Miklossy, 1990). The location of A.F.'s lesion is consistent with his symptoms, which illustrate misperception of spatial position of visual stimuli and the ensuing inability to relate positions of objects in visually represented space. This deficit was manifested both visually and by reaching under visual guidance. Taken together these deficits are components of the syndrome of visual disorientation found in patients with bilateral posterior parietal lobe damage (Holmes, 1918a,b). Although visual motion mechanisms are severely impaired in A.F., color and form perception and object and facial recognition are normal.

E.W.'s lesions were also bilateral and symmetric, affecting the occipital and ventral medial temporal structures. The location of his lesions is consistent with lesion locations leading to achromatopsia and associated prosopagnosia in other human patients. Recent PET studies confirmed that the ventromedial surface, particularly the occipitotemporal junction, is implicated in face recognition (Damasio et al., 1982; Sergent et al., 1992). Specifically, the authors suggest a crucial role for the right parahippocampal gyrus in linking perceptual and memory information about faces.

Thus, on both anatomical and behavioral grounds it is likely that E.W.'s and A.F.'s lesions involved different streams of processing in the extrastriate cortex: E.W.'s lesion can be associated with the ventral visual system, while A.F.'s lesion may be associated with the dorsal system.

***Achromatopsia and Impaired Shape  
Discrimination: A Deficit in the  
Ventral Pathway?***

One might perhaps argue that E.W.'s complaint that the "world looks as if it was in deep twilight, even on a sunny day" and was "devoid of color" can be explained by preferential sparing of magnocellular-stream cortical areas, which might lead to such a perception, since there is evidence that the rod signals are directed preferentially to the magnocellular LGN layers (e.g., Purpura et al., 1988), and magnocellular cells are poor at color discriminations (e.g., Derrington et al., 1984). However, E.W.'s photopic spectral sensitivity curve showed no hint of rod intrusion. E.W.'s wavelength discrimination was significantly impaired, particularly on the short-wavelength end of the spectrum, but he could discriminate one end of the spectrum from the other. He correctly reported red, but was unable to identify blue, gray, or greens. This partial sparing of color vision has been previously reported in achromatopsia (Meadows, 1974; Victor et al., 1989).

In a series of studies Zeki (summarized in his recent monograph, Zeki, 1993) argued that total (bilateral) achromatopsia is a result of bilateral damage to area V4 of the human brain. MRI studies (Kölmel, 1988) and brain autopsy in achromatopsic patients (Meadows, 1974; Damasio et al., 1982) implicate the ventral occipital cortex in the deficit, which was indeed involved in E.W.'s lesion. Moreover E.W.'s loss of upper visual field perception (Meadows, 1974) and his mild deficit on the shape discrimination task are consistent with an involvement of V4 in the lesion. However, if the human homolog of V4 is anything like the macaque V4, E.W.'s color deficits cannot be accounted for only on the basis of such a lesion. There is strong evidence that lesions of macaque area V4 produce only mild deficits on form discrimination and wavelength discrimination tasks and it has been suggested (Dean, 1976; Cowey, 1982; Heywood and Cowey, 1987; Schiller et al., 1990; Heywood et al., 1991; Schiller and Lee, 1991; Schiller, 1993) that perhaps V4 is concerned with color constancy rather than wavelength discrimination, with form, and with perceptual context.

E.W.'s impaired fine discrimination of shapes (Fig. 3) suggests a selective partial deficit of visual analysis, prior to the perceptual categorization level. His performance on the two smaller ratios of the shape discrimination test was similar to that of Mr. S reported by Efron (1968). Mr. S is considered one of the classical cases of apperceptive agnosia. Interestingly, Efron commented that "the various tasks that Mr. S. cannot perform are the identification of objects, geometrical figures, letters, numbers, and people. Is there one attribute of these various existents which must be perceived for the identification? The answer is inescapable: they are all identified by the attribute of shape." Efron concluded that the ability to discriminate between shapes is necessary for recognition and identification.

E.W. also failed to recognize letters, drawings, and pictures of objects presented from prototypical, front

views. His descriptions of objects presented as photographs or drawings were always guided by the identification of a part (the ears or the legs of an animal) and then by trying to associate them by inference to an object from a small repertoire of objects that he could remember (e.g., he identified most animals as dogs). This is similar to Mr. S, who "knowing the entire repertoire. . . could deduce which object was before him from the attributes he could identify," and to the patient described by Landis et al. (1982). It is possible that, at least in part, E.W.'s deficits of face and visual object recognition and his inability to read can be explained by an apperceptive disorder of static shape discrimination. His partial achromatopsia but normal motion perception and normal binocular stereopsis strongly indicate that his lesion selectively involved the ventral, occipital-temporal pathway. Moreover, E.W.'s slight deficit on form from speed differences is consistent with the recent results of a study by Britten et al. (1992), which showed that in monkeys with inferotemporal lesions the discrimination of familiar forms (learned prior to the lesion) defined by motion cues was somewhat impaired.

It is thus probable that E.W. suffered from visual apperceptive agnosia, defined as impaired recognition due to a deficit of perceptual categorization and percept formation despite intact early sensory processing (Lissauer, 1890), or as "a disturbance of the synthesis or fusion of impressions in a single modality" (Liepmann, 1908). Numerous cases of apperceptive visual agnosia have been described in the literature (see Grüsser and Landis, 1991, for a review), and most agree that it is a syndrome with devastating consequences for the patient, leaving him in a condition of severe perceptual handicap. E.W. described suggestively how he perceived the world: "The impression I have is that if you only turn the light on I would see," referring to his inability to "see" objects and faces so that he recognizes them.

***Impaired Binocular Stereopsis, Motion and  
Spatial Perception: A Deficit in the  
Dorsal Pathway?***

A.F. and E.W. were tested on six motion tasks: 2D form from motion, 2D form by relative motion, speed discrimination, motion coherence, 3D structure from motion, and biological motion recognition. Table 1 shows that E.W. performed very well on these tasks while A.F. was very impaired on four of the six motion tasks. On the speed discrimination task A.F. could not discriminate speed ratios smaller than 3, which is within the range of the performance of patients with right occipital-parietal lesions reported in Vaina et al. (1989). On the 2D-form-by-relative-motion task he scored at chance level, which is well below the range of the right-occipital parietal group, who were themselves impaired on this task. He was also severely impaired on the motion coherence task, and showed a mild impairment on the 2D-form-from-motion task. In a striking departure from these findings, he had no problems on the *structure-from-motion* task. His good performance on this task was surprising since A.F. had

impaired several early motion mechanisms, such as speed discrimination and motion coherence, which according to current theoretical models may underlie the computation of structure from motion (Longuet-Higgins and Prazdny, 1980; Koenderink and van Doorn, 1986; Treue et al., 1991, 1994). In our reports (Vaina et al., 1990a,b) on A.F.'s motion perception, we suggested that either these cues are not necessary and A.F. might have used different cues (e.g., position), or that structure-from-motion tasks may not require the precision of motion signals implied by the many computational theories relying on velocity difference. Even more surprising was A.F.'s normal performance on the biological motion test. We suggested (Vaina et al., 1990a,b) that A.F.'s perfect performance may be explained by the existence of a separate motion pathway specialized for object recognition and perception of action. There is evidence from physiological studies in the monkey that this type of motion may be perceived in the rostral portion of the superior temporal sulcus (STS) (Bruce et al., 1981; Perrett et al., 1985). Our own data from patients with anterior temporal lesions are consistent with this physiological hypothesis (Vaina and LeMay, 1992; Vaina, unpublished observations). The MRI study suggests that A.F.'s lesion involves the putative human homolog of MT, but that it does not directly involve higher-order areas such as MST or STP (superior temporal polysensory area). This is consistent with his deficits on speed discrimination (Pasternak and Merigan, 1994), motion coherence (Newsome and Paré, 1988), and impaired smooth pursuit (Wurtz et al., 1990). Indeed, A.F.'s configuration of deficits selective to aspects of motion perception is similar to the deficits previously reported in patients with lesions selectively involving the dorsal (occipital-parietal) pathway (Vaina, 1989; Vaina et al., 1991; Regan et al., 1992).

A.F. was severely impaired on spatial perception tasks and, despite his normal object recognition, was severely impaired at identifying degraded structural descriptions of familiar objects (as shown by his poor performance on the unusual-views test and on the Gollin pictures). In contrast, E.W.'s spatial perception abilities were normal. His failure on the Gollin pictures test can be accounted for by his impaired object recognition discussed above.

In conclusion, A.F. was selectively impaired on aspects of visual motion analysis, discrimination of spatial relations, and binocular stereopsis, which are tasks engaging visual processes along the dorsal pathway. Asked what disturbed him most, A.F. said, "I never know exactly where things are, and when I walk I often wonder whether all the drivers in [his town] are drunk or high, and whether on top of the stroke I'll have now someone crashing into me. It always seems that they are going faster than they actually do."

#### ***A System for Identification from Motion?***

The anatomical segregation of the patients' lesions is clear-cut and shows good evidence of two complementary classes of visual defects, one associated with lesions along the ventral system and the other asso-

ciated with lesions corresponding to the dorsal system. E.W. could not recognize objects or faces, but he never failed to identify correctly objects in motion or even to recognize facial expression from pantomime. Recognition of biological motion and structure from motion were normal. A.F. was severely impaired on a large class of motion and spatial tasks, but his performance was normal on the recognition of biological motion and on the 3D-structure-from-motion task. The spared recognition and identification from motion in both patients are surprising. It suggests the existence of a higher-level visual motion system involved in motion recognition that does not require the motion pathway to area MT. Indeed, cells sensitive to particular "biological" types of motion have been found within the STS in STP (Bruce et al., 1981; Perrett et al., 1985). It is possible that in addition to supplying motion information useful to the posterior parietal cortex for visuomotor tasks and for navigation, the dorsal stream also supplies to the anterior temporal lobe motion information useful for recognition of objects and actions. Our previous findings in patients with right hemisphere lesions of a dissociation between motion analysis and motion recognition (Vaina and LeMay, 1992) support this hypothesis. In an elegant recent study, Boussaoud and Ungerleider (1990) showed that, in the macaque, areas specialized for various stages of motion analysis, such as MT, MST, and FST, not only send inputs to the ventral and dorsal system, but also supply strong input to the STS. Thus, this area may constitute a further stage in the system underlying motion, and specifically it may be involved in recognition. MT was clearly spared in E.W.'s lesion, and thus information could arrive at the STS by and large avoiding the ventral system. MT appeared to be involved in A.F.'s lesion, but probably not MST or FST, and motion information could reach the STS by an alternate route, via PO or V3A, for example. Another possibility is that motion information necessary for recognition is routed to STS through V4 and the inferior temporal cortex (IT)

#### **Notes**

1. The Vision Contrast Test System (VCTS) consists of six rows of 1-cm-diameter patches of gratings obtained from photographing computer-generated sine wave gratings, each row having patches of different spatial frequency: 1.5, 3, 6, 12, and 18 cycles/degree. Each row contains, from left to right, one sample patch and eight test patches. The contrast of these patches ranges from 0 contrast to contrast above and below normal threshold in roughly 0.1 log unit steps. The gratings are tilted in one of the three orientations:  $-15^\circ$ ,  $0^\circ$ ,  $+15^\circ$ . The contrast and orientation of test patches are randomized for each row to control for guessing. The observer holds the chart at 56 cm distance positioned vertically at eye level and contrast sensitivity is assessed for each eye separately. The observer is shown a high-contrast sample grating at the three possible orientations. The task is to determine whether each sequential grating patch on a specific row was blank or at a particular orientation. The procedure is repeated for the remaining rows of grating patches. The test method is a four-alternative forced-choice procedure. Contrast sensitivity threshold is determined from an answer key provided by VCTS on the basis of an extensive data base of results from a large number of observers.

This research was supported by NIH Grant EY-RO1-07861



and McDonnell-Pew Foundation Grant T89-01245-017. Thanks are due to Drs. Roger Tootell and Nikos Logothetis for the help with the evaluation of color vision of patient E.W., to Dr. Marjorie LeMay for help with the interpretation of the MRI scans of the patients, and to Dr. Don Bienfang for sharing the interpretation of the neuro-ophthalmological findings. I thank Hillary Rodman, Charles Gross, and Alan Cowey for critical comments on an early version of the manuscript. Jeremy Lambert and Ivans Chou helped with the manuscript preparation.

Correspondence should be addressed to Dr. Lucia M. Vaina, Intelligent Systems Laboratory - Vision Research, ERB-331, Department of Biomedical Engineering, Boston University, 44 Cummington Street, Boston, MA 02215.

## References

- Baker CLJ, Hess RF, Zihl J (1990) The motion-blind patient: perception of random dot limited-lifetime motion. *Invest Ophthalmol Vis Sci* 31:239.
- Benton AL, Varney NR, Hamsher KD (1977) Judgment of line orientation. Iowa City, IA: Department of Neurology, University Hospitals.
- Boussaoud D, Ungerleider LG (1990) Pathways for motion analysis: cortical connections of the medial superior temporal and fundus of the superior temporal visual areas in the macaque. *J Comp Neurol* 296:462-495.
- Britten KH, Newsome WT, Saunders RC (1992) Effects of inferotemporal cortex lesions on form-from-motion discrimination in monkeys. *Exp Brain Res* 88:292-302.
- Bruce C, Desimone R, Gross CG (1981) Visual properties of neurons in a polysensory area in superior temporal sulcus of the macaque. *J Neurophysiol* 46:369-384.
- Clarke S, Miklosy J (1990) Occipital cortex in man organization of callosal connections, related myelo- and cytoarchitecture, and putative boundaries of functional visual areas. *J Comp Neurol* 28:188-215.
- Cowey A (1982) Sensory and non-sensory visual disorders in man and monkey *Philos Trans R Soc Lond [Biol]* 238:3-13.
- Cowey A, Marcar V (1992) The effect on motion perception of removing cortical visual area MT in the macaque monkey: I. Motion discrimination using simple dots. *Eur J Neurosci* 4:1219-1227.
- Damasio AR, Damasio H, Van Hoesen GW (1982) Prosopagnosia: anatomic basis and behavioral mechanisms. *Neurology (NY)* 32:331-341.
- De Renzi E (1989) Prosopagnosia: a multistage, specific disorder? In: *Handbook of research on face processing* (Young A, Ellis HD, eds), pp 27-35. Amsterdam: North-Holland.
- De Renzi E, Faglioni P, Spinnler H (1966) Facial Recognition on brain damaged patients. *Neurology (NY)* 16:143-152.
- Dean P (1976) Effects of inferotemporal lesions on the behavior of monkeys. *Psychol Bull* 83:41-71.
- Derrington AM, Krauskopf J, Lennie P (1984) Chromatic mechanics in the lateral geniculate nucleus of macaque. *J Physiol (Lond)* 357:241-265.
- Downing CJ, Movshon AJ (1989) Spatial and temporal summation in the direction of motion in stochastic random dot patterns. *Invest Ophthalmol Vis Sci [Suppl]* 30:72.
- Efron R (1968) What is perception? In: *Boston studies in the philosophy of science* (Cohen MWW, Cohen RS, eds), pp 137-173. Dordrecht: Reidel.
- Farnsworth D (1943) The Farnsworth-Munsell 100-hue and dichotomous task for color vision. *J Ophthalmol Soc Am* 33:568-578.
- Felleman DJ, Van Essen DC (1991) Distributed hierarchical processing in the primate cerebral cortex. *Cereb Cortex* 1:1-47.
- Flechsig P (1920) *Anatomie des Menschlichen Gehirns und Rückenmarks auf Myelogenetischer Grundlage*. Leipzig: Thieme.
- Gollin ES (1960) Developmental studies of visual recognition of incomplete objects. *Percept Mot Skills* 11:289-298.
- Gross CG, Rocha-Miranda CE, Bender DB (1972) Visual properties of neurons in inferotemporal cortex of the macaque. *J Neurophysiol* 35:96-111.
- Grüsser OJ, Landis T (1991) Visual agnosias and other disturbances of visual perception and cognition. In: *Vision and visual dysfunction*, Vol 12 (Cronly-Dillon JR, ed). Boca Raton, FL: CRC.
- Haxby JV, Grady CL, Horwitz B, Ungerleider LG, Mishkin M, Carson RE, Herscovitch P, Schapiro MB, Rapoport SI (1991) Dissociation of object and spatial visual processing pathways in human extrastriate cortex. *Proc Natl Acad Sci USA* 88:1621-1625.
- Heywood CA, Cowey A (1987) On the role of cortical area V4 in the discrimination of hue and pattern in macaque monkeys. *J Neurosci* 7:2601-2617.
- Heywood CA, Cowey A, Newcombe F (1991) Chromatic discrimination in a cortically colour blind observer. *Eur J Neurosci* 3:802-812.
- Hildreth EC (1984) *The measurement of visual motion*. Cambridge, MA: MIT Press.
- Holmes G (1918a) Disturbances of vision by cerebral lesions. *Br J Ophthalmol* 2:353-392.
- Holmes G (1918b) Disturbances of visual orientation. *Br J Ophthalmol* 2:449-468.
- Johansson G (1973) Visual perception of biological motion and a model for its analysis. *Percept Psychophys* 14:201-211.
- Julesz B (1971) *Foundation of cyclopean perception*. Chicago: University of Chicago.
- Koenderink JJ, van Doorn AJ (1986) Depth and shape from differential perspective in the presence of bending deformations. *J Opt Soc Am [A]* 3:242-249.
- Kölmel HW (1988) Pure homonymous hemiachromatopsia: findings with neuro-ophthalmologic examination and imaging procedures. *Eur Arch Psychiatry Neurol Sci* 237:237-243.
- Landis T, Graves R, Benson F, Hebben N (1982) Visual recognition through kinaesthetic mediation. *Psychol Med* 12:515-531.
- Liepmann H (1908) Über die agnostischen Störungen. *Neurol Zbl Lpz* 27:1-41, 609-617, 664-675.
- Lissauer H (1890) Ein Fall von Seelenblindheit nebst einem Beitrage zur Theorie derselben. *Arch Psychiatr Nervenkr* 21:221-270.
- Longuet-Higgins HC, Prazdny K (1980) The interpretation of a moving retinal image. *Proc R Soc Lond [Biol]* ??:385-397.
- MacQuarrie TW (1953) *MacQuarrie's test for mechanical ability*. Monterey, CA: California Test Bureau.
- Marcar VL, Cowey A (1992) The effect of removing superior temporal cortical motion areas in the macaque monkey: II. Motion discrimination using random dot displays. *Eur J Neurosci* 4:1228-1238.
- Maunsell JHR, Newsome WT (1987) Visual processing in monkey extrastriate cortex. *Ann Rev Neurosci* 10:363-401.
- Meadows JC (1974) Disturbed perception of colours associated with localized cerebral lesions. *Brain* 9:615-632.
- Merigan WH, Maunsell JHR (1993) How parallel are the primate visual pathways? *Annu Rev Neurosci* 16:369-402.
- Miezian FM, Fox PT, Raichle ME, Allman JM (1987) Localized responses to low contrast moving random dot patterns in human visual cortex monitored with positron emission tomography. *Soc Neurosci Abstr* 13:631.
- Nakayama K, Tyler CW (1981) Psychophysical isolation of movement sensitivity by removal of familiar position cues. *Vision Res* 21:427-433.
- Newsome WT, Paré EB (1988) A selective impairment of motion perception following lesions of the middle temporal visual area (MT). *J Neurosci* 8:2201-2211.
- Pasternak T, Merigan WH (1994) Motion perception following lesions of the superior temporal sulcus in the monkey. *Cereb Cortex*, 4:247-260.
- Pasternak T, Maunsell JH, Polashenski W, Merigan WH (1991)

- Deficits in global motion perception after MT/MST lesions in a macaque. *Invest Ophthalmol Vis Sci* 32:824
- Perrett DI, Smith P, Chitty AJ, Mistlin AJ (1985) Visual analysis of body movements by neurones in the temporal cortex of the macaque monkey: a preliminary report. *Behav Brain Res* 16:153-170.
- Polyak S (1957) *The vertebrate visual system*. Chicago: University of Chicago.
- Purpura K, Kaplan E, Shapley RM (1988) Background light and the contrast gain of primate p and m retinal ganglion cells. *Proc Natl Acad Sci USA* 85:4534-4537.
- Regan D, Giaschi D, Sharpe JA, Hong XH (1992) Visual processing of motion-defined form: selective failure in patients with parietotemporal lesions. *J Neurosci* 12:2198-2210.
- Rizzo M, Nawrot M, Blake R, Damasio A (1992) A human visual disorder resembling area V4 dysfunction in the monkey. *Neurology* 42:1175-1180
- Schiller PH (1993) The effects of V4 and middle temporal (MT) area lesions on visual performance on the rhesus monkey. *Vis Neurosci* 10:717-746.
- Schiller PH, Lee K (1991) The role of primate extrastriate area v4 in vision. *Science* 251:1251-1253.
- Schiller PH, Logothetis NK, Charles ER (1990) Role of the color-opponent and broad-band channels in vision. *Vis Neurosci* 5:321-346.
- Sergent J, Ohta S, MacDonald B (1992) Functional neuroanatomy of face and object processing. *Brain* 115:15-36.
- Siegel RM, Andersen RA (1988) Perception of three-dimensional structure from motion in monkey and man. *Nature* 331:259-261.
- Treue S, Husain M, Andersen R (1991) Human perception of structure from motion. *Vision Res* 31:59-75.
- Treue S, Snowden RJ, Andersen RA (1994) The effect of transiency on perceived velocity of visual patterns. *Vision Res* 33:791-798.
- Tusa RJ, Ungerleider LG (1988) Fiber pathways of cortical areas mediating smooth pursuit eye movements in monkeys. *Ann Neurol* 23:174-182.
- Ungerleider LG, Desimone R (1986) Cortical projections of visual area MT in the macaque. *J Comp Neurol* 248:190-222
- Ungerleider LG, Mishkin M (1982) Two cortical visual systems. In: *Analysis of visual behavior*, Chap 18 (Ingle MAG, Ingle DJ, Mansfield RJW, eds), pp 549-586 Cambridge, MA: MIT Press.
- Vaina LM (1989) Selective impairment of visual motion interpretation following lesions of the right occipito-parietal area in humans. *Biol Cybern* 61:347-359.
- Vaina LM, Grzywacz NM (1992) Testing computational theories of motion discontinuities: a psychophysical study. In: *Lecture notes in computer science (Computer vision-ECCV '92 (Sandini G, ed), 588:212-216*. New York: Springer.
- Vaina LM, LeMay M (1992) Functional streams for motion analysis: psychophysical evidence from patients with focal brain lesions. *Invest Ophthalmol Vis Sci [Suppl]* 33:954.
- Vaina LM, LeMay M, Choi A, Kemper T, Bienfang D (1989) Visual motion analysis with impaired speed perception: psychophysical and anatomical studies in humans. *Soc Neurosci Abstr* 15:1256
- Vaina LM, LeMay M, Bienfang DC, Choi AY, Nakayama K (1990a) Intact biological motion and structure from motion perception in a patient with impaired motion mechanisms: a case study. *Vis Neurosci* 5:353-369.
- Vaina LM, Grzywacz NM, LeMay M (1990b) Structure from motion with impaired local-speed and global motion-field computations. *Neural Comput* 2:420-435.
- Vaina LM, Grzywacz NM, Choi A, LeMay M, Bienfang DC (1990c) Selective deficits of measurement and integration of motion in patients with lesions involving the visual cortex. *Invest Ophthalmol Vis Sci [Suppl]* 31:523.
- Van Essen DC, Maunsell JHR (1983) Hierarchical organization and functional streams in the visual cortex. *Trends Neurosci* 6:370-375.
- Victor JD, Maiese K, Shapley R, Sidtis J, Gazzaniga MS (1989) Acquired central dyschromatopsia: analysis of a case with preservation of color discrimination. *Clin Vision Sci* 4:183-196.
- Warrington EK, James M (1988) Visual apperceptive agnosia: a clinico-anatomical study of three cases. *Cortex* 24:13-32.
- Warrington EK, Taylor AM (1973) The contribution of the right parietal lobe to object recognition. *Cortex* 9:152-164.
- Watson JDG, Meyers R, Frackowiak RSJ, Hajnal JV, Woods RP, Mazziotta JC, Shipp S, Zeki S (1993) Area V5 of the human brain: evidence from a combined study using positron emission tomography and magnetic resonance imaging. *Cereb Cortex* 3:79-94.
- Wurtz R, Komatsu H, Yamasaki D, Dursteler M (1990) Cortical visual motion processing for oculomotor control. In: *Vision and the brain (Cohen B, Bodis-Wollner I, eds)*, pp 211-231. New York: Raven.
- Wright WD (1947) *The rays are not colored*. London: Hilger.
- Zeki S (1991) Cerebral akinetopsia (visual motion blindness). *Brain* 114:811-824.
- Zeki S (1993) *A vision of the brain*. London: Blackwell.
- Zeki S, Watson JDG, Lueck CJ, Friston KJ, Kennard C, Frackowiak RSJ (1991) A direct demonstration of functional specialization in human visual cortex. *J Neurosci* 11:641-649