

Arachnoid cyst with traumatic intracystic hemorrhage unassociated with subdural hematoma

Faruk İldan, Erdal Cetinalp, Hüeyin Bağdatoğlu, Bülent Boyar, and Ziya Uzuneyüoğlu

Cukurova University, School of Medicine, Department of Neurosurgery, Balcali, Adana, Turkey

Abstract

Arachnoid cysts of the middle cranial fossa may manifest themselves in several different ways. Most often they remain asymptomatic and are only diagnosed incidentally on computed tomography or at autopsy. When they are symptomatic, headache, nausea, vomiting and seizures are most common in the patients with increased intracranial pressure. Increased intracranial pressure is caused by the ball-valve mechanism of the cyst's membrane which is in communication with the general subarachnoid space or arachnoid cells which contain specialized membranes and enzymes which have secretory activity. A significant number of middle cranial fossa arachnoid cysts are associated with subdural hematoma which may, in turn, be associated with intracystic hemorrhage. We report an unusual case with posttraumatic, isolated intracystic hemorrhage of the arachnoid cyst in the sylvian area without subdural hematoma.

Keywords: Arachnoid cyst, intracystic hemorrhage, middle fossa, subdural hematoma.

1 Introduction

Arachnoid cysts are intra-arachnoid collections of cerebrospinal fluid (CSF). They can be found intracranially at any location adjacent to, and frequently communicating with, the subarachnoid space that commonly occurs in the middle fossa [20]. They can cause neurological deficit by expanding and compressing the surrounding normal tissue. They can also obstruct CSF flow and produce such symptoms as developmental delay, craniomegaly, seizures, and headache [1, 10, 21]. Other specific symptoms and signs vary depend-

ing upon the location. These cysts are frequently discovered incidentally during radiographic evaluation for an unrelated complaint. Arachnoid cysts located in the middle fossa have been well described in the literature. They are often considered to be a separate clinical entity [23]. Many of the cysts in the middle cranial fossa are asymptomatic and require no immediate treatment. However, reports have drawn attention to the predisposition of the cyst to develop an associated subdural hematoma [13, 18], which may, in turn, be associated with intracystic hemorrhage [3, 17]. The occurrence of intracystic hematoma may be more frequent than has been suggested [18]. Due to its venous nature hematoma is nearly always at a chronic stage when clinically manifested. We report a patient who present 10 days after head injury who manifested isolated intracystic hematoma of the middle fossa arachnoid cyst without subdural hematoma. According to our findings a case of isolated intracystic hemorrhage into the arachnoid cyst of the middle cranial fossa without subdural hematoma has not been reported in the literature previously.

2 Case report

This 32-year-old man was admitted with a one week history of right parietal headache, six days vomiting, and increasing hemiparesia involving the left side. Ten days previously, he had sustained a mild head injury. On clinical examination, bilateral papilledema and left hemiparesis

were found. Computerized tomography (CT) demonstrated a right middle fossa arachnoid cyst with intracystic hematoma and mild compression on the right frontal horn (Figure 1). Hemorrhage was not noted anywhere in the subdural space. A craniotomy was carried out immediately. A subdural membrane was found covering the floor of the middle fossa and extending up over the convexity under greatly increased pressure. The outer wall of this lining was removed totally after evacuation of the intracystic hematoma. The insula was exposed with absence of the anterior portion of the right temporal lobe. There was an inner membrane in the depths of the cavity. The inner wall could not be separated from the arachnoid membrane covering the sylvian fissure. The exact source of hemorrhage within the cyst could not be seen. Postoperatively, the headache and vomiting were relieved. Clinical recovery was satisfactory and no residual neurological deficit resulted. The membrane of the middle fossa cyst consisted of slightly thickened arachnoid. Unfortunately there were no specific histological findings which can explain the cause of the bleeding.

3 Discussion

The subject of the origin and natural history of intracranial arachnoid cysts is still controversial. Hypothesis offered to explain the development of arachnoid cysts include congenital malformation

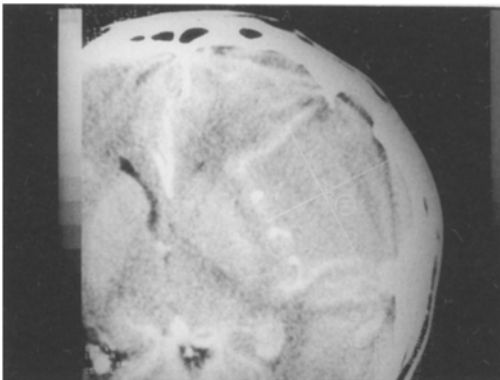


Figure 1. CT scan after contrast enhancement showing an intracystic hemorrhage of the arachnoid cyst in the sylvian area without subdural hematoma.

[21, 23], infection [4, 22], and increased intracranial pressure [14]. The relative prevalence of these cysts in the pediatric population and the absence of signs of trauma or inflammation in the majority of the cases [2, 16, 22] suggest a congenital lesions which differ from traumatic or inflammatory leptomenigeal cysts. Many histopathological studies with light and electron microscopes have definitely revealed that the outer and inner walls of the arachnoid cysts consist of layers of arachnoid cells which unite with the normal arachnoid at the margins of the cyst [8, 10]. Arachnoid cysts seem to increase in size by collection of CSF secreted through arachnoid cells which contain specialized membranes and enzymes which have secretory activity rather than unidirectional CSF flow (ball-valve trapping) [10, 23].

Arachnoid cysts of the middle fossa are considered to be the most common group. They occur most commonly in males under the age of 20, however, may also occur at any age. The various clinical manifestations of arachnoid cysts of the middle fossa have been well described; the most common is headache. Much less commonly, seizures occur. Cysts in this location may deform the surrounding bone by erosion or expansion. When the cyst is large, the sphenoid ridge is elevated, and the greater wing remodels and displaces forward. However, such cysts can remain asymptomatic throughout life [22].

Prior to the advent of CT, the diagnosis of arachnoid cysts were generally made by plain radiography or angiography of the skull. X-rays showed thinning and bulging of the temporal squama, enlargement of the middle cranial fossa, elevation of the lesser sphenoid wing. Angiography showed an avascular space with the signs of displaced vessels.

CT scans yield definite diagnosis of arachnoid cysts. Arachnoid cysts in the sylvian area may have a rectangular shape, probably as a result of shortening of the temporal lobe and flattening of the adjacent insula, as in our case [5].

Many reports have noted an inclination to develop an associated subdural hematoma and intracystic hemorrhage in patients with arachnoid cyst of the middle fossa [3, 13, 17]. This was first recognized by ROBINSON [22] and substantiated

by SMITH and SMITH [23]. The event of intracystic hemorrhage may be more common than previously suggested. There has been no satisfactory explanation for the susceptibility of patients with an arachnoid cyst in the sylvian fissure to develop subdural or intracystic hematoma. The postulated explanations included: 1) after a minor trauma flow changes within the CSF could be magnified by the arachnoid cyst causing the rupture of the bridging veins or vessels in the cyst wall, or 2) since the arachnoid cyst is less compliant than normal brain, reduced intra-calvarial cushioning is present [18].

CT usually delineates the well-circumscribed, low density arachnoid cyst, but the hemorrhage into the cyst can always increase its density. For this reason intracystic hematomas are usually easy to identify in the early period. Subacutely, the clot may contract, increasing further in its density, but the period is short-lived. Then proteolysis begins and hematoma protein is degraded and absorbed [7]. After the state of isodensity has been reached the detection becomes difficult [12, 15]. Injection of intravenous contrast material may allow description of the subdural membrane between the cyst and the subdural hematoma.

Arachnoid cysts of the middle fossa may disappear spontaneously [6], even in the presence of

intracystic hemorrhage [11, 12]. Asymptomatic arachnoid cysts without signs of increased intracranial pressure and focal neurological signs should be treated non-surgically. A surgical approach can only be suggested for cases with considerable space occupation along with midline shift or focal neurological signs [9, 19]. Although drainage of the fluid of the cyst without excision of its membrane has been considered to be effective in the majority of the cases, excision of the cyst rather than simple drainage or shunting procedure as proposed by AUER et al. [3] has been considered as the most effective treatment.

We report an unusual case with isolated intracystic hemorrhage of the arachnoid cyst of the middle cranial fossa without subdural hematoma ten days after trauma. Although the situation in which there is both subdural and intracystic hematoma has been reported frequently a case of isolated intracystic hemorrhage has not been reported so far, according to our knowledge.

We believe that arachnoid cyst of the middle cranial fossa without subdural hematoma following trauma is a specific pathological entity. Clinicians should always be alert to the possibility of isolated intracystic bleeding in patients with middle fossa arachnoid cysts.

References

- [1] AICARDI J, F BAUMAN: Supratentorial extracerebral cysts in infants and children. *J Neurol Neurosurg Psychiatry* 38 (1975) 57–68
- [2] ANDERSON FM, HD SEGALL, WL CATON: Use of computerized tomography scanning in supratentorial arachnoid cysts. A report on 20 children and four adults. *J Neurosurg* 50 (1979) 333–338
- [3] AUER LM, B GALLHOFER, G LADURNER, WD SAGER, F HEPPNER, H LECHER: Diagnosis and treatment of middle fossa arachnoid cysts and subdural hematomas. *J Neurosurg* 54 (1981) 366–369
- [4] BANNA M: Arachnoid cyst in the hypophyseal area. *Clin Radiol* 25 (1974) 323–326
- [5] BANNA M: Arachnoid cysts on computed tomography. *AJR* 127 (1976) 979–982
- [6] BELTRAMELLO A, C MAZZA: Spontaneous disappearance of a large middle fossa arachnoid cyst. *Surg. Neurol* 24 (1985) 181–183
- [7] BERGSTROM M, K ERICSON, B LEVANDE, P SVENDSEN: Computed tomography of cranial subdural and epidural hematomas. Variation of attenuation related to time and clinical events such as rebleeding. *J Comput Assist Tomogr* 1 (1977) 449–455
- [8] DI ROCCO C, M CALDARELLI, G DI TRAPANI: Intratentorial arachnoid cysts in children. *Childs Brain* 8 (1981) 119–133
- [9] GALASSI E, G GAIST, G GIULIANI, E POZATTI: Arachnoid cysts of the middle cranial fossa experience with 77 cases treated surgically. *Acta Neurochir (Suppl)* 42 (1988) 201–204
- [10] GO KG, HJ HOUTHOF, EH BLAAUW, P HAVINGA, J HARTSUIKER: Arachnoid cysts of the sylvian fissure. Evidence of fluid secretion. *J Neurosurg* 60 (1984) 803–813
- [11] HARA H, T INOVE, K MATSUO, S KOBAYASHI, K SUGITA: Unusual computed tomographic findings in a case of arachnoid cyst in the middle cranial fossa. *Surg Neurol* 22 (1984) 79–82
- [12] INOVE T, T MATSUSHIMA, S TASHIMA, M FUKUI, K HASUA: Spontaneous disappearance of a middle

- fossa arachnoid cyst associated with subdural hematoma. *Surg Neurol* 28 (1987) 447–450
- [13] LACOUR, R TREVOR, M CREY: Arachnoid cyst and associated subdural hematoma. Observations on conventional roentgenographic and computerized tomographic diagnosis. *Arch Neurol* 35 (1978) 84–89
- [14] LITTLE JR, MR GOMEZ, CS MAC CARTY: Infratentorial arachnoid cysts. *J Neurosurg* 39 (1973) 380–386
- [15] LUND E, M BUHL, T MILLETIC, V KNUDSEN: Iso-dense middle fossa arachnoid cyst and subdural hematoma: a diagnostic problem on CT. *J Neuro-radiol* 14 (1987) 89–93
- [16] MENEZES AH, WE BELL, GE PERRET: Arachnoid cysts in children. *Arch Neurol* 37 (1980) 168–172
- [17] OLSEN NK, HHT MADSEN: Arachnoid cyst with complicating intracystic and subdural hemorrhage. *Röntgen Bl* 43 (1990) 166–168
- [18] PAGE A, RM PAXTON, D MOHAN: A reappraisal of the relationship between arachnoid cysts of the middle fossa and chronic subdural hematoma. *J Neurol Neurosurg Psychiatry* 50 (1987) 1001–1007
- [19] RAFFEL C, JG MCCOMB: To shunt or to fenestrate: which is the best surgical treatment for arachnoid cysts in pediatric patients? *Neurosurgery* 23 (1988) 338–342
- [20] RENGACHARY SS, WATANABE I: Ultrastructure and pathogenesis of intracranial arachnoid cysts. *J Neuropathol Exp Neurol* 40 (1981) 61–83
- [21] RENGACHARY SS, I WATANABE, CE BRACKETT: Pathogenesis of intracranial arachnoid cysts. *Surg Neurol* 9 (1978) 139–144
- [22] ROBINSON RG: Congenital cysts of the brain: arachnoid malformations. *Progr Neurol Surg* 4 (1971) 133–174
- [23] SMITH RA, SMITH VA: Arachnoid cysts of the middle cranial fossa. *Surg Neurol* 5 (1976) 246–252.

Submitted January 15, 1993. Accepted March 31, 1993.

Faruk İldan, M.D.
Cukurova University
School of Medicine
Department of Neursurgery
Balcali, Adana
Turkey