



0028-3932(94)E0056-T

## TRANSCORTICAL ALEXIA WITH AGRAPHIA FOLLOWING A RIGHT TEMPORO-OCCIPITAL HEMATOMA IN A RIGHT-HANDED PATIENT

P. DAVOUS\* and F. BOLLER

Department of Neurology, Hôpital Victor Dupouy, Argenteuil and the Research Unit "Neuropsychology of Cerebral Aging", Inserm U 324, Paris, France

(Received 7 September 1993; accepted 29 March 1994)

**Abstract**—We describe the case of a 51-year-old right-handed man who was affected by a transcortical alexia with agraphia and aphasia. Transcortical alexia produces errors in both reading and writing while copying is preserved. The patient had a severe alexia and was unable to read letters, words or sentences. Language examination showed mild aphasia with reduced fluency, intermittent paraphasia but a good comprehension and a normal repetition. Spontaneously and from dictation, writing was impaired by an agraphic jargon, but copying was excellent even though the patient was unable to read his own written production. There was no visual agnosia nor hemianopia. CT scan and MRI of the brain showed that there was a single right temporo-occipital hemorrhage but no lesion in the left hemisphere. Following surgical evacuation of the hematoma, the patient improved. One month after onset, his language was quite intact and reading was possible. We hypothesize that this particular syndrome was the result of a double disconnection: alexia would result from a disconnection of the right angular gyrus and the occipital associative areas by a subangular lesion; agraphia would result from a disconnection of the right angular gyrus and the semantic store, probably located in the right hemisphere.

**Key Words:** alexia; agraphia; disconnection.

### INTRODUCTION

In 1883, Charcot [5] devoted two of his famous lectures to word blindness "une espèce particulière d'aphasie" and referred to Kussmaul as the author of the first description of this symptom-complex he had called "Wortblindheit". In 1892, Déjerine [7] distinguished two varieties of word blindness. The first variety, "word blindness with agraphia", had been described by him in 1891 and was considered similar to Wernicke's "cortical" sensory aphasia and related to a lesion of the left angular gyrus. The second variety, "word blindness" (without agraphia) was attributed, after a detailed neuropathological study, to a lesion isolating the visual region from the angular gyrus. Wernicke had previously postulated such a lesion to explain his cases of subcortical alexia. Benson and Geschwind [4] in their extensive review of alexia, introduced the term "transcortical alexia" suggested by Wernicke to describe cases which produce errors in both reading and writing while copying is preserved. We describe a case of transcortical alexia with agraphia in a right-handed man with a right temporo-occipital hematoma.

---

\*Address for correspondence: Service de Neurologie, Centre Hospitalier, 95107 Argenteuil Cedex, France.

## CASE REPORT

A 51-year-old right-handed automobile factory technician with grade school education was referred to Argenteuil Hospital on 3 March 1991 because of a sudden onset of aphasia followed by a major motor seizure. He had taken Dicoumarin for 3 years because of atrial fibrillation and he had been operated on 6 months previously for a left bronchial carcinoma. On admission to the emergency room, his vital signs showed an elevated blood pressure (210/110 mm Hg) and a regular pulse. On neurological examination, the patient was alert. He was obviously aphasic, but performed verbal commands easily. There was a mild left motor deficit involving the arm and the lower face and a doubtful left hemianopia. The EKG showed a sinus rhythm. CT scan of the head demonstrated a large right temporo-occipital hematoma. Twenty-four hours later, the patient was alert and free of motor deficit. There was no evidence of hemianopia or spatial neglect. Language examination showed anomia, paraphasias and a mild comprehension impairment. Repetition of words and sentences was normal. He was unable to read words and letters. Reading comprehension and reading aloud were equally impaired. Spontaneous writing as well as writing from dictation showed a jargonaphasic agraphia. Though copying was near perfect and fluent, the patient could not read what he had written. An MRI of the brain was performed 8 days after the onset of hemorrhage to verify the absence of any other lesion in the left hemisphere. It confirmed a single right temporo-occipital hematoma (Fig. 1). A cerebral angiogram showed no vascular malformation. The patient was operated on the 12th day for evacuation of the hematoma. A meningeal biopsy revealed no amyloid. There was a rapid improvement of the alexic and aphasic symptoms during the weeks following surgery.

### *Neuropsychological data*

The patient was spontaneously right-handed in all his activities and scored 100% right dominance for hand, foot and eye activities on a standard questionnaire derived from the Edinburgh inventory [25]. He had no left-handed parents or siblings. Two neuropsychological examinations were performed at 1 month interval. At first examination (days 5–12 after admission), the patient was alert and oriented for place and time. He had no hemianopia or optic ataxia in his left visual field. Spontaneous language revealed a non-fluent aphasia without articulatory deficit but with a low prosody. He had a markedly reduced fluency, anomia and rare paraphasias. Auditory comprehension was good for words and sentences. There was no error in the repetition of words. Repetition of sentences revealed mild paraphasic and amnesic features. Alexia was global, verbal and literal. There was severe alexia for letters (1/24), words (2/10) and numbers (1/10). When asked to read printed cards, the patient failed to give any response on most of the items. He said: "I can't read . . . I don't know". He could not read letter by letter. There was no word length effect. In two instances, he tried to guess the word and produced pseudo-morphological errors [ARTISTE (artist) → ARTÈRE (artery), ECHARPE (scarf) → EPAISSE (thick)] unrelated semantically to the stimulus. He was unable to grasp the meaning of proper nouns with special configuration (newspaper, advertisements . . .). Matching written words to pictures was impossible. Graphesthesia was moderately impaired. Spontaneous writing and writing from dictation showed agraphia with a paragraphic jargon. When asked to copy the same sentence, the patient wrote it quite well and easily but he could not read it aloud (Fig. 2). He used to copy script to script and print to print with equal facility. Delayed copying was not tested. The spatial placement of what he wrote was normal. Calculation was impaired orally

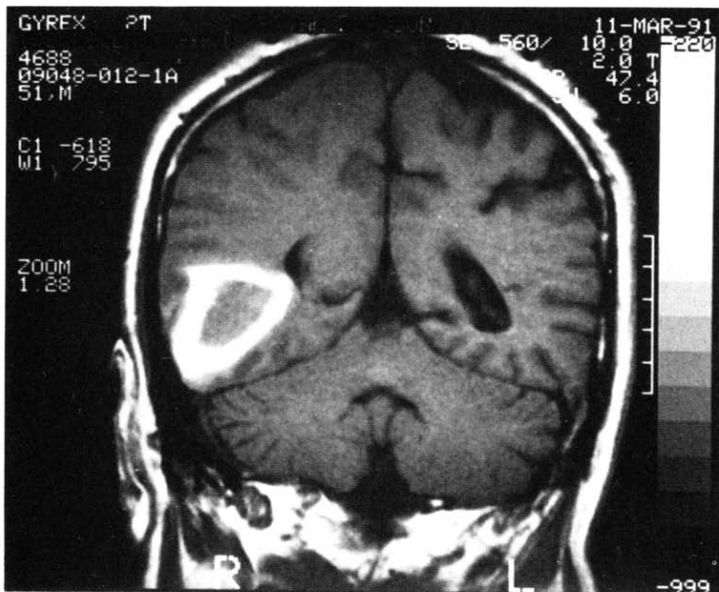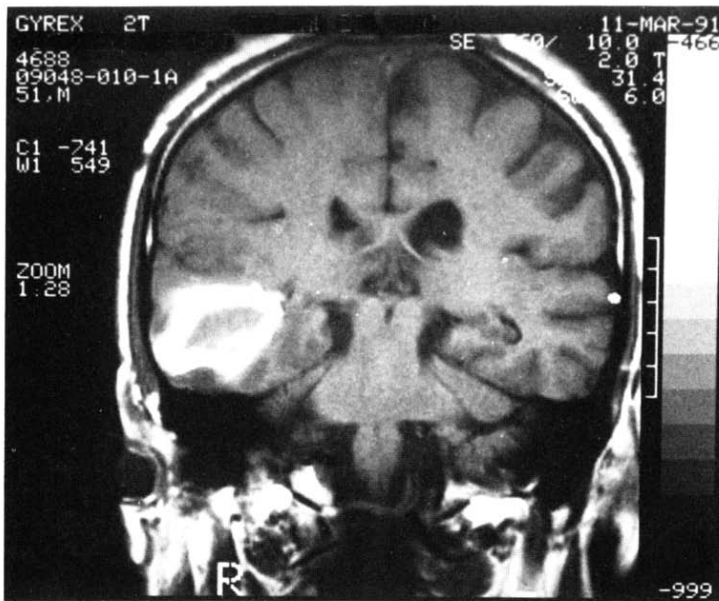


Fig. 1. Two tesla MRI of the brain. Coronal T1 weighted images (TR = 560 msec, TE = 10 msec) showing a ring-like right hypersignal in the inferior temporal (up) and at the temporo-occipital junction (down).



and impossible in writing. He had no impairment of body knowledge, no right-left confusion, no finger agnosia. There was no apraxia. Drawing a daisy or a house was normal, on command and on copy. The perception of forms, images and colors was normal. The patient showed anomia for pictures and colors but made no recognition errors on a multiple choice task. He could identify only 7/10 famous faces.

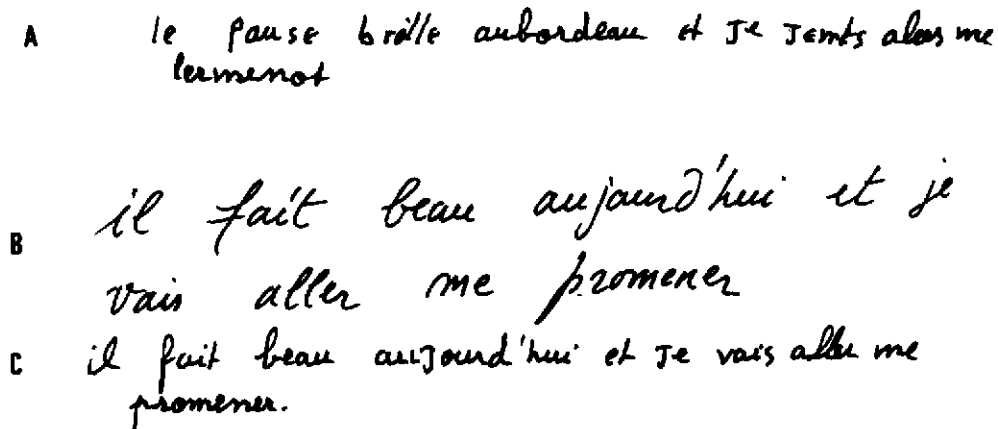


Fig. 2. Examples of patient's writing to dictation showing jargonagraphia (A) and of normal copying (C) of the same sentence (B).

The second neuropsychological examination was performed 30 days after admission. He was oriented for place and time. His memory was normal for verbal and non-verbal material. He had mild verbal difficulties with the associated pairs of the Wechsler memory scale. His MQ was 92. His spontaneous language was fluent. Naming and comprehension were normal. There was mild impairment with complex forms of language, paraphasias were found in rare occasions. Reading had significantly improved for letters (2 errors out of 24) and words. He made no error when reading disyllabic words. Polysyllabic words were read with morphologic paralexia or failed, even if the patient tried to spell the letters or syllables phonetically (formalité→f.or.m.a.si...rise..., charcuterie→c.h.a....cha.r.c.a....char.vo.ru...). Spelling was abnormal for long words. Reading was still difficult for sentences. Numbers were identified slowly with some errors. Calculation was slow. Spontaneous writing showed paraphasias but most of the sentences he wrote were intelligible. Copying was perfect. For example, in a sentence of 16 words there were 4 spontaneous paraphasia with dysorthographia but none in copy. Dictation of 8 polysyllabic words showed 5 morphologic paraphasia but only one error on one letter on copy. Topographical orientation tested on a map of France showed no disorder. There were 3/14 errors on a famous faces test but no errors on the Poppelreuter test. When tested 1 year later for a comparative evaluation, language, writing and reading were within normal limits, except for a rare paraphasic tendency. Calculation was slow but relatively normal.

#### *Anatomical and physiological data*

Two MRI of the brain were performed at 1 year intervals. The lesion could be reconstructed in the coronal, sagittal and axial planes as shown in Fig. 3. It appears that it involved mainly the temporal lobe, the T2 and T3 temporal gyri and the temporo-occipital

junction in its cortical external part. The comparison of both MRI showed that the lesion had a higher volume with oedema at onset, compared with the sequellar hypo-intense lesion seen in the infero-temporal lobe 1 year later. On both examinations, the lingual lobe, the callosal splenium, the calcarine fissure and the angular gyrus were unaffected. Morphometric analysis of the CT and MRI were compatible with those of right-handed subjects with a left hemispheric dominance. Cerebral blood flow was studied using  $^{133}\text{Xe}$  inhalation. There was no asymmetry between the hemispheres ( $52 \text{ ml}/100\text{g}/\text{mn} \pm 11$ ) but a verbal task produced an activation of the right frontal and temporal areas.

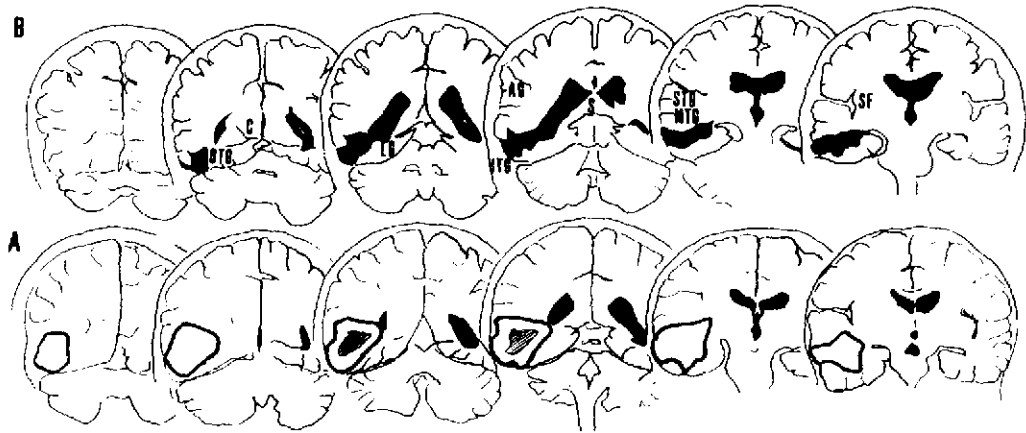


Fig. 3. Anatomical reconstruction of the topography of the hematoma according to MRI coronal templates 8 days (A) and 1 year (B) after the hemorrhage. AG: angular gyrus. C: calcarine cortex. ITG: inferior temporal gyrus. LG: lingual gyrus. MTG: middle temporal gyrus. OTG: occipito-temporal (fusiform) gyrus. S: splenium of the corpus callosum. SF: sylvian fissure. STG: superior temporal gyrus.

## DISCUSSION

In the present case, alexia was severe and global, verbal and literal, and therefore quite different from aphasic alexia which preserves some "global" reading ability [2] and from other alexic syndromes (phonologic, surface or deep dyslexia). Alexia restricted to word visual anomia, without color agnosia or hemianopia has been called subangular alexia [13] and has been interpreted as the result of an intra-hemispheric disconnection between the associative visual areas and the language areas [26]. However, subangular alexia is not recognized as a definite neuropsychological syndrome and variants have been observed including global alexia [26, 32], phonological alexia [9, 30] and other forms [13, 16, 21, 29]. Our patient's agraphia was also different from classical alexia with agraphia where copying is slavish. Writing spontaneously and from dictation showed an agraphia similar to that observed in sensory aphasia with a semantic-orthographic jargon. Conversely, this patient made no error in copying, suggesting that he could transfer visual symbols in written signs without converting them in a semantic store. Pillon *et al.* [27] have reported two similar cases of severe spontaneous jargonagraphia in crossed aphasia but copying was not tested. According to Coslett *et al.* [6], the orthographic jargon might result from the disruption of a

lexical system producing paraphasia and neologisms. Normal copying might be mediated by a non-lexical mechanism. This kind of agraphia can be called “transcortical” in view of its analogy with the concept of transcortical aphasia. A similar pattern is seen in some patients with Wernicke’s aphasia who can read aloud but who cannot comprehend what they are reading [22]. There is evidence that these two behaviours, writing comprehension and writing by copying, are mediated by independent and dissociable information-processing modules. This suggests the existence of an associated bundle from the center of visual symbols to the motor programme area for writing, as was formerly postulated by Dejerine and Thomas [8].

Our patient’s aphasia had features of mixed transcortical aphasia with paucity of spontaneous speech, word finding pauses, moderate semantic-auditory comprehension difficulty and excellent repetition. A similar aphasia has been described by Pirozzolo *et al.* [29] in a case of subangular alexia. Our patient had no deficit for recognition of pictures presented by multiple choice and it was clear that the naming deficit was not agnosic or perceptive in nature such as in the Pillon *et al.* case [28]. The reduction of oral spontaneous speech associated with a mild comprehension impairment could be considered as a feature of crossed aphasia [19] in this right-handed man. A similar case of alexia and agraphia has been described and discussed by Albert *et al.* [3]. Perception of written words was virtually intact and their semantic understanding was relatively well preserved. The authors suggest that their patient had a functional disconnection between visual auditory and motor systems involved in the understanding of written language. According to cognitive models of reading and writing [23], it is likely that the alexia with agraphia syndrome of our patient was the result of a double disconnection syndrome. Reading was probably impaired by a disconnection (A) between orthographic and phonologic lexicon or visual-word images and sound-letter conversion areas (Fig. 4). The absence of abnormality in repetition of spoken

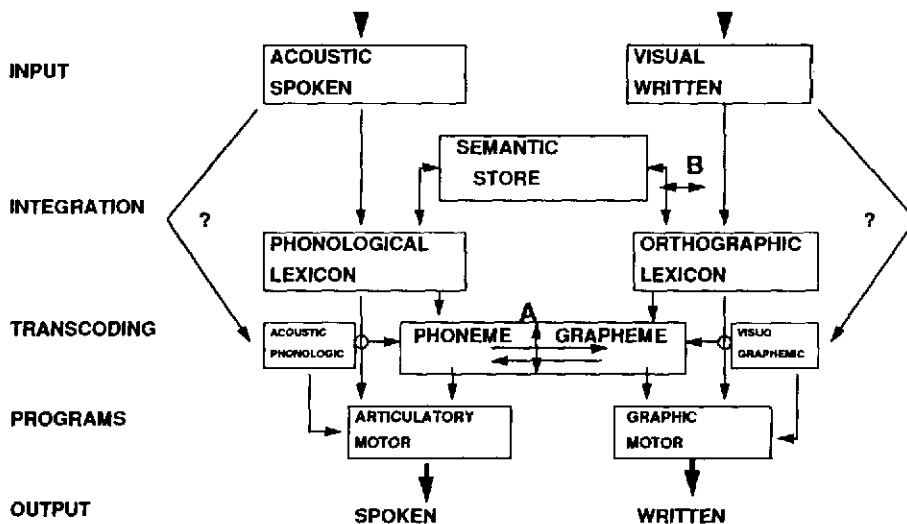


Fig. 4. Schematic diagram of brain mechanisms for spoken and written language processing.

input suggests that the route from phonologic lexicon to articulatory program and verbal output was not involved by the lesion. The abnormal, jargonagraphic written output resulting from dictation or spontaneous evocation of words suggests an involvement of phonologic to orthographic transformation. The high quality of copying can be explained by a second disconnection (B) where a normal visual input to an intact orthographic lexicon can be transferred directly to graphic motor program without access to the semantic store. Besides the double disconnection of the orthographic lexicon from the semantic system and the phonological lexicon ("direct" lexical route) an impairment of graphemic-phonemic conversion is required to explain this global alexia. The reversibility of alexia and agraphia following surgery suggests that these disconnections resulted from a compressive rather than destructive lesion of associative pathways in the temporo-occipital region.

According to Greenblatt [14], the anatomical mechanism of alexia may be simply subangular if the white matter is involved [9, 13, 29] but in other cases, alexia is probably caused by the cortical lesion [16, 32]. In our case, the lingual cortex seems unaffected and it is likely that the lesion disrupted the transverse fasciculus or the inferior longitudinal fasciculus, as in the case of hematoma described by Henderson *et al.* [16]. In contrast with Dejerine's theory [7], this case demonstrates that the syndrome of alexia with agraphia is not always related to the involvement of the angular gyrus. Dejerine and Thomas [8] had been confronted with this paradox. Their patient had alexia, agraphia and normal spelling. He died after a right cerebral hemorrhage but the lesion responsible for his symptoms was in the left hemisphere, involving the posterior cerebral artery territory, the T3 and T2 gyri and the temporo-parietal subcortical white matter. The angular gyrus was spared. Déjerine and Thomas concluded "we must admit that the left angular gyrus was no longer anatomically connected to the center of movement for the left hand which is located in the middle part of the right rolandic convolutions". The role of the infero-temporal cortex in subangular alexia has been emphasized by Japanese authors following the observations of Iwata [18] showing that the posterior inferior temporal lobe plays an important role in semantic processing of kanji reading and writing.

Most cases of alexia, with or without agraphia, have been associated with left hemisphere lesions. When alexia resulted from a unique lesion in the right hemisphere, it was generally observed in left-handed patients. Erkulyravatr [10] described a case of alexia with left hemianopia in a left-handed man. The CT scan showed a right occipital lobe infarction in the territory of the cerebral posterior artery. The patient wrote with his left hand. He had alexia in 50% of long words and 60-80% of short words. Letters were correctly read. Writing was poor but correct. The patient misspelled unfamiliar words. A Wada test was consistent with a left hemispheric dominance. The author suggests that his patient had some functions underlying reading which were represented in the right hemisphere while other aspects of language could be on the left. A similar analysis had been suggested in other cases of right lesions observed in right-handed patients [1, 11, 24] and in a mixed left-handed case [33]. According to this hypothesis, visually perceived written words from the left occipital cortex would be transmitted via the splenium of the corpus callosum to the right occipital cortex, then to the right angular gyrus via associational pathways, then would recross again via the corpus callosum to the left angular gyrus. Such a pathway has been suggested by Geschwind [12] and reinforced by Greenblatt's observations [14].

Pillon *et al.* [28] favoured the hypothesis of perceptive factors, interpreting the alexia of their patient as a visual agnosia limited to the recognition by the sight of semantic value of language-graphic symbols. Reviewing the other cases of the literature, they found only two



left-handed cases similar to their own. They supposed a right hemisphere dominance for their left-handed patient. The clinical picture of a patient described by Henderson *et al.* [15] resembled the pure alexia syndrome following dominant hemisphere damage. This particular case of alexia has been related to combined damage of the right thalamus and right occipital lobe which impaired visuo-spatial perception and caused a profound neglect syndrome. Following this hypothesis, anomalous right hemisphere dominance for language would not be necessary to account for the alexia. Other cases of the typical form of alexia with agraphia have been described in the Japanese literature [20]. There were eight left hemispheric lesions and three cases with right side lesions. Among these three, there was one right-hander. It has been suggested [31] that normal Japanese subjects had a left visual field (right hemisphere processing) superiority for kanji characters and a right visual field (left hemisphere processing) superiority for kana.

This unique observation tends to challenge our understanding of the anatomical pathways and neuropsychological cognitive networks involved in alexia with agraphia. The first question is directed towards hemispheric dominance for language. It is likely that if the patient had had a complete left hemisphere dominance for spoken and written language, he would not have shown alexia and agraphia following a right hemisphere lesion. Since the examination and the questionnaire showed that he was a right-hander, it is also improbable that he had a complete right hemisphere dominance for language, but this cannot be ruled out in consideration of his aphasic symptoms which were not significantly different from those observed in left hemisphere lesions and from phonological and graphemic aspects seen in cases of crossed aphasia or alexia. Alternatively, we have to consider the hypothesis of a partial imbalance between spoken and written language and their representation in the right and left hemispheres. We can suggest the following remarks to fit our observation with the main theories of networks for reading developed previously [7, 12, 14, 17]:

(1) Transcortical alexia resulted from a disconnection of the right angular gyrus and the occipital associative areas by a cortico-subcortical subangular lesion. The visual-word image (lexical) center was probably located in the right hemisphere. (2) Transcortical agraphia resulted from a disconnection of the right angular gyrus and the semantic store, located either in the left or right hemisphere. Normal copying is probably explained by a normal access of visual graphemes to written motor programs via a left angular gyrus which works in a strict ideographic way. The absence of phonological transcoding is compatible with a location of semantic store in the right hemisphere. This suggests that the hypothetic pathway from the right to the left angular gyrus via the dorsal callosum does not work in a reciprocal way. (3) The transcortical aphasic symptoms are compatible with a right hemisphere dominance for language.

This observation demonstrates that reading is not a single capacity but a complex system balanced between both hemispheres according to dominance for spoken and written languages. The alexia with agraphia syndrome may result from a disconnection of the inputs to and outputs from an intact angular gyrus.

*Acknowledgement*—We are grateful to Dr V. W. Henderson for comments on neuroanatomic formulations about cerebral dominance.

## REFERENCES

1. Aboo-Baker, F. et Labauge, R. Alexie et agraphie par lésion de l'hémisphère droit chez un droitier non aphasique. *Rev. Neurol. (Paris)* **143**, 294–297, 1987.
2. Alajouanine, T., Lhermitte, F. et Ribaucourt-Ducarne, B. de. Les alexies agnosiques et aphasiques. In *Les Grandes Activités du Lobe Occipital*, T. Alajouanine (Editor), pp. 235–260. Masson, Paris, 1960.

3. Albert, M. L., Yamadori, A., Gardner, H. and Howes, D. Comprehension in alexia. *Brain* **96**, 317-328, 1973.
4. Benson, D. F. and Geschwind, N. The alexias. In *Handbook of Clinical Neurology*, P. J. Vinken and G. W. Bruyn (Editors). Vol. 4, pp. 112-140. North-Holland, Amsterdam, 1969.
5. Charcot, J. M. Sur un cas de cécité verbale. In *Oeuvres-Complètes, Tome III, Système Nerveux*, pp. 154-177. Delahaye et Lecrosnier, Paris, 1890.
6. Coslett, H. B., Roeltgen, D. P., Rothi, L. G. and Heilman, K. M. Transcortical sensory aphasia: Evidence for subtypes. *Brain Lang.* **32**, 362-378, 1987.
7. Dejerine, J. Contribution à l'étude anatomo-pathologique et clinique des différentes variétés de cécité verbale. *C.r. Mem. Soc. Biol. (Paris)* **4**, 61-90, 1892.
8. Dejerine, J. et Thomas, A. Un cas de cécité verbale avec agraphie suivi d'autopsie. *Rev. Neurol. (Paris)* 655-664, 1904.
9. Ducarne, B., Bergego, C. et Gardeur, D. Alexie "sous-angulaire" et signes neuropsychologiques associés: Étude clinique et tomodensitométrique. *Cortex* **19**, 115-123, 1983.
10. Erkulvawatr, S. Alexia and left homonymous hemianopia in a non-right hander. *Ann. Neurol.* **3**, 549-552, 1978.
11. Fournet, F., Virat-Brassaud, M. E., Guard, O., Dumas, R., Auplat, Ph. et Marchal, G. Alexie-agraphie croisée chez un droitier. *Rev. Neurol. (Paris)* **143**, 214-219, 1987.
12. Geschwind, N. Disconnection syndromes in animals and man. *Brain* **88**, 237-294, 585-644, 1965.
13. Greenblatt, S. H. Subangular alexia without agraphia or hemianopsia. *Brain Lang.* **3**, 229-245, 1976.
14. Greenblatt, S. H. Left occipital lobectomy and the preangular anatomy of reading. *Brain Lang.* **38**, 576-595, 1990.
15. Henderson, V. W., Alexander, M. P. and Naeser, M. A. Right thalamic injury, impaired visuospatial perception and alexia. *Neurology* **32**, 235-240, 1982.
16. Henderson, V. W., Friedman, R. B., Teng, E. L. and Weiner, J. M. Left hemisphere pathways in reading: Inferences from pure alexia without hemianopia. *Neurology* **35**, 962-968, 1985.
17. Henderson, V. W. Anatomy of posterior pathways in reading: A reassessment. *Brain Lang.* **29**, 119-133, 1986.
18. Iwata, M. Kanji vs kana: Neuropsychological correlations of the Japanese writing system. *Trends Neurosci.* **7**, 290-293, 1984.
19. Joannette, Y., Puel, M., Nespoulous, J. L., Rascol, A. et Roch-Lecours, A. Aphasie croisée chez les droitiers. I. Revue de la littérature. *Rev. Neurol. (Paris)* **138**, 575-586, 1982.
20. Kawahata, N., Nagata, K. and Shishido, F. Alexia with agraphia due to the left posterior inferior temporal lobe lesion. Neuropsychological analysis and its pathogenetic mechanisms. *Brain Lang.* **33**, 296-310, 1988.
21. Kawamura, M., Hirayama, K., Hasegawa, K., Takahashi, N. and Yamaura, A. Alexia with agraphia of kanji (Japanese morphograms). *J. Neurol. Neurosurg. Psychiat.* **50**, 1125-1129, 1987.
22. Lytton, W. W. and Brust, J. C. M. Direct dyslexia. Preserved oral reading of real words in Wernicke's aphasia. *Brain* **112**, 583-594, 1989.
23. Margolin, D. I. Cognitive neuropsychology. Resolving enigmas about Wernicke's aphasia and other higher cortical disorders. *Arch. Neurol.* **48**, 751-765, 1991.
24. Ogden, J. A. Dyslexia in a right-handed patient with a posterior lesion of the right cerebral hemisphere. *Neuropsychologia* **22**, 265-280, 1984.
25. Oldfield, R. C. The assessment and analysis of handedness: The Edinburgh inventory. *Neuropsychologia* **9**, 97-113, 1971.
26. Orgogozo, J. M. et Pere, J. J. L'alexie sans agraphie. *Congrès de Psychiatrie et de Neurologie de Langue Française. Rapport de neurologie*. Tome II. Masson, Paris, 1991.
27. Pillon, B., Desi, M. et Lhermitte, F. Deux cas d'aphasie croisée avec jargonographie chez des droitiers. *Rev. Neurol. (Paris)* **135**, 15-30, 1979.
28. Pillon, B., Bachevalier, S. and Lhermitte, F. Alexia without agraphia in a left-handed patient with a right occipital lesion. *Arch. Neurol.* **44**, 1257-1262, 1987.
29. Pirozzolo, F. J., Kerr, K. L., Obrzut, J. E., Morley, G. K., Haxby, J. V. and Lundgren, S. Neurolinguistic analysis of the language abilities of a patient with a "double disconnection syndrome": A case of subangular alexia in the presence of mixed transcortical aphasia. *J. Neurol. Neurosurg. Psychiat.* **44**, 152-155, 1981.
30. Rapcsak, S. Z., Gonzalez-Rothi, L. J. and Heilman, K. M. Phonological alexia with optic and tactile anomia: A neuropsychological and anatomical study. *Brain Lang.* **31**, 109-121, 1987.
31. Sasanuma, S., Motonobu, I., Mori, K. and Kobayashi, Y. Tachiscopic recognition of kana and kanji words. *Neuropsychologia* **15**, 547-553, 1977.
32. Vincent, F. M., Sadowsky, C. H., Saunders, R. L. and Reeves, A. G. Alexia without agraphia, hemianopia or color-naming defect: A disconnection syndrome. *Neurology* **27**, 689-691, 1977.
33. Winkelman, M. D. and Glasson, C. C. Unilateral right cerebral representation of reading in a familial left-hander. *Neuropsychologia* **22**, 621-626, 1984.