

CASE REPORT

Cardiac and Neurologic Complications in Malignant Hypertension due to Oral Contraceptive Use

LUIZ APARECIDO BORTOLOTTI, HELIO BERNARDES SILVA and FULVIO PILEGGI

From the Hypertension Unit Heart Institute, São Paulo, Brazil

Bortolotto LA, Silva HB, Pileggi F. Cardiac and Neurologic Complications in Malignant Hypertension due to Oral Contraceptive Use. *Blood Pressure* 1994; 3: 319-321.

Malignant hypertension is a rare consequence of contraceptive use. We report here on two young women with malignant hypertension secondary to contraceptive use whose main symptomatology was neurological. Both patients had renal failure, severe left ventricle hypertrophy, and hemorrhagic stroke, all reversible after control of blood pressure and discontinuation of the contraceptive pill. *Key words: malignant hypertension, oral contraceptive, left ventricle hypertrophy, stroke.*

INTRODUCTION

Arterial hypertension has been described in association with oral contraceptives since these were introduced in the 1960s [1-5]. Malignant hypertension (MH) is a rare complication occurring among pill users [6-10], and terminal renal failure has been reported in a few cases [7-10]. Left ventricular hypertrophy in patients with MH without a previous history of arterial hypertension has been described as a rare feature [11]. Neurological abnormalities such as stroke have been described in oral contraceptive users due to the thrombogenic effect of such contraceptives [12]. However, these complications have not been described in pill users as a first manifestation of MH. We report here on 2 patients who had taken modern low-dose combined contraceptive pills presenting with neurological complications as the first manifestation of MH, both of them with significant left ventricle hypertrophy and renal failure.

Case report 1

A 23-year-old white woman was admitted to hospital with a 3-day history of headache, mental confusion and aggressiveness. She had been well and normotensive until 6 months before when she started to have daily headaches, and severe arterial hypertension (180 × 140 mmHg) had been diagnosed. Antihypertensive therapy was started, and she was instructed to discontinue oral contraceptives (ethynylestradiol 30 µg, plus levonorgestrel 150 µg) which she had been taking for one year. However, she complained about the antihypertensive drugs and continued to take the pill. She remained well until one day before admission when she presented with headache and behavioral changes, becoming aggressive and confused. On admission her blood pressure was

270/180 mmHg, and an eyes fundus examination showed papilloedema, exudates and mild hypertensive vessel changes. There were no localized neurological signs, only behavioral alterations. Blood urea was 39.6 mmol/l and serum creatinine 309 µmol/l. Intensive therapy with sodium nitroprusside was started, and 24 h later, after furosemide, propranolol and captopril had been started, her blood pressure was 140/90 mmHg. Since she remained aggressive despite control of blood pressure, a cranial computed tomography scan was performed which revealed a right temporoparietal intraparenchymal haematoma (Fig. 1). She then received intravenous dexamethasone, and after one week her conscious level returned to normal, with blood pressure under control. Serum creatinine first increased to 353.6 µmol/l and decreased to 132.6 µmol/l after 15 days. An electrocardiogram showed sinus rhythm, left atrial enlargement and left ventricle hypertrophy, and an echocardiogram demonstrated severe concentric left ventricular hypertrophy (SWT = 17 mm, LVEDD = 40 mm, EF = 66%, MI = 280 g/m²).

Further investigation showed no evidence of secondary hypertension: urinary vanilmandelic acid was normal as was isotopic renal scintigraphy, and renal arteriography demonstrated renal arteries of normal caliber. A cerebral arteriogram did not show any aneurysms or other vascular malformations. A renal biopsy performed after clinical stabilization revealed malignant nephrosclerosis. At the time of discharge from hospital, blood pressure was 130/80 mmHg, and she was prescribed furosemide, propranolol and captopril, and the contraceptive agent was discontinued. Now 4 years later, the patient maintains normotension by 3-drug antihypertensive treatment, without any neurological abnormalities and with normal renal function (serum creatinine = 106 µmol/l). Regression of

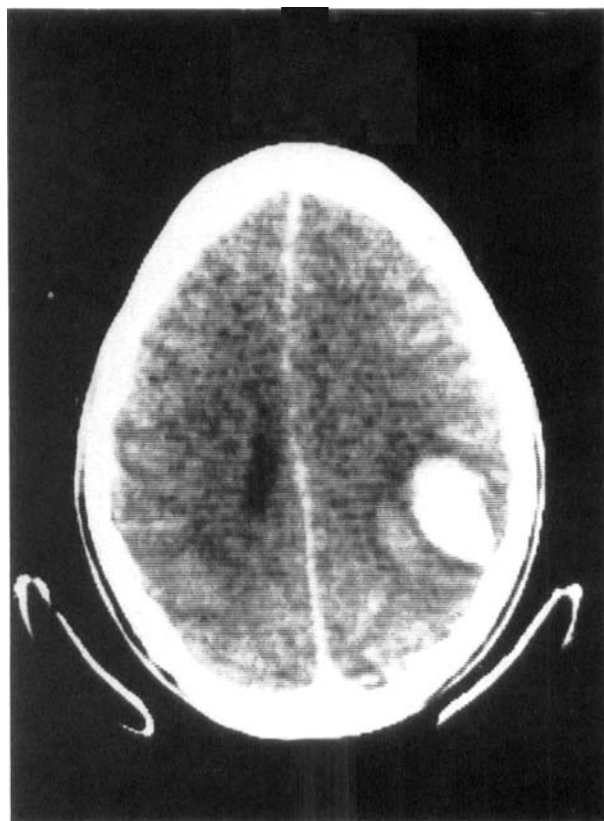


Fig. 1. A cranial ct scan revealing a right temporoparietal intraparenchymal hematoma (white area).

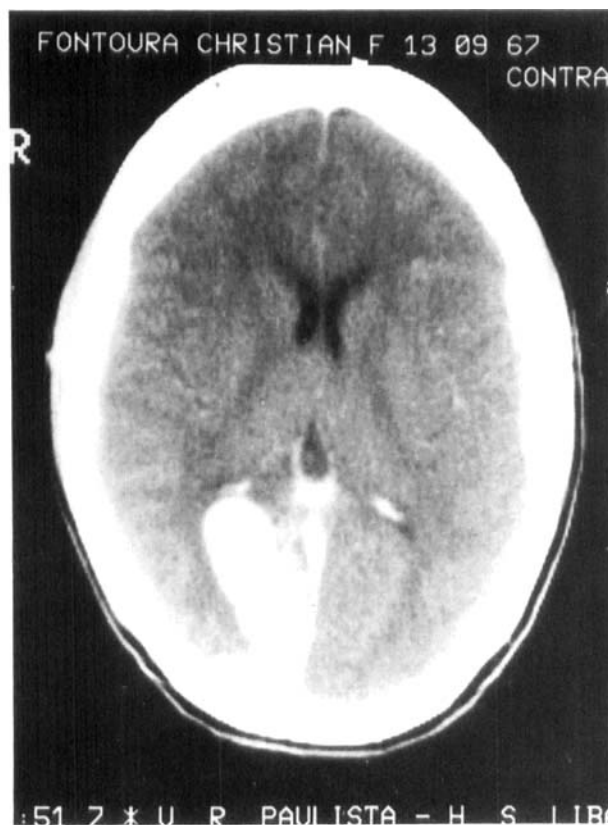

Fig. 2. Computerized cranial tomography scan showing a right occipital intraparenchymal hematoma (white area).

left ventricular hypertrophy (SWT = 11 mm, LDD = 40 mm, MI = 120 g/m²) was observed.

Case report 2

A 21-year-old woman was admitted to hospital with accelerating hypertension. Seven months before she was submitted to a cesarean section after a normal pregnancy during which the blood pressure was normal. One month after the delivery she began taking oral contraceptives (ethinylestradiol 30 µg and levonorgestrel 150 µg). Three months later she developed headache and fatigue, and on the day of admission she had intense headache and vomiting followed by generalized seizures. She was admitted to an intensive care unit in coma; her blood pressure was 250/180 mmHg and serum creatinine was 238.7 mmol/l. The fundi showed exudates and mild arteriolar narrowing. No focal neurological signs were observed. She remained comatose for 5 days and her conscious level returned to normal after control of blood pressure with four antihypertensive drugs, with no further fits. Ten days later blood pressure was 160/100 mmHg, blood urea

was 53.5 mmol/l, serum creatinine 247.5 µmol/l, creatinine clearance 54 ml/min, urinary sediment was normal and 24 h proteinuria was negative. Both electrocardiogram and echocardiogram revealed left ventricular hypertrophy (SWT = 13 mm; LEDD = 49 mm; EF = 72%; MI = 190 g/m²). Investigation for a secondary cause of hypertension was negative.

Neurological examination disclosed left temporal and right nasal hemianopsia and a disordered gait. Electroencephalographic examination revealed diffuse sharp-wave activity predominantly in the temporal area. A computed tomographic scan showed a right occipital intraparenchymal hematoma (Fig. 2), and cerebral arteriography showed a mild medial rightward shift of the right posterior cerebral artery but no further vascular malformations. At the time of discharge from hospital her blood pressure was 140/95 mmHg, she was prescribed furosemide, propranolol and captopril, and the contraceptive agent was discontinued. Three years later, the patient is now normotensive on a single antihypertensive drug, with improvement of renal function and neurological alterations and regression of left ventricle hypertrophy (SWT = 10 mm; LEDD = 40 mm; MI = 100 g/m²).

DISCUSSION

The association between oral contraceptives and arterial hypertension was first suggested in 1962 by Brownrigg et al. [1], but it was well defined only later by Woods [2] and Weir [3]. Over the following years, many studies have described a variable incidence of arterial hypertension. In the RCGP-OC Study [4] the prevalence of hypertension in 1,000 women-years ranged from 8.19 to 13.88% depending on higher doses of progesterone and fixed doses of estrogens. In another study, Spellacy & Birk [5] reported an incidence of 0% to 7% according to the doses of progesterone and estrogen used. In most of these studies, arterial hypertension was mild to moderate and they demonstrated reversal to normal levels after 3 months of withdrawal of the pill. However, severe and malignant hypertension has been described in a few reports, the first of them published in 1969 by Harris [6]. The mechanism whereby the contraceptive pill causes malignant hypertension remains unknown but some hypotheses have been put forward such as an extreme example of the varied increase by pressor effects of estrogens or progestagens or thrombosis of either the main or intrarenal arteries.

Although the association between malignant hypertension and oral contraceptive is well recognized, the number of reported cases is small and the clinical features and prognoses are uncertain. The most recent study published in 1987 by Lim et al. [10] reported that 11 of 34 malignant hypertensive women studied were taking oral contraceptives. Renal impairment was infrequent in this group, probably explaining the excellent prognosis obtained by these investigators (90% of the subjects surveyed over 10 years). Among the most common complications of malignant hypertension, terminal renal failure was the only one reported in the above studies, whereas left ventricular hypertrophy was not reported. In the present study, both patients had severe left ventricular hypertrophy due to malignization of hypertension, and regression occurred during the follow-up in parallel with blood pressure control. Neurological complications such as stroke have been reported [12] in users of the contraceptive pill, but in most cases the event is associated with coagulation disturbances more than with hypertensive complications. These neurological complications have not been described as a first manifestation of MH in pill users, although they are well recognized in MH due to other causes. Both women reported here had a hemorrhagic cerebral accident as a complication of malignant hypertension and the clinical manifestations were similar to those reported by others. Cerebral tomography

was an important complementary examination for a definitive diagnosis.

In conclusion, despite its low incidence, malignant hypertension due to oral contraceptive use can be prevented by effective control of the blood pressure. Neurological, renal and cardiovascular complications, although infrequent, do occur but are reversible after long term treatment.

REFERENCES

1. Brownrigg GM. Arterial hypertension related to oral contraceptive use. *Can Med Assoc J* 1962; 87: 408.
2. Woods JM. Oral contraceptives and hypertension. *Lancet* 1967; 2: 653-4.
3. Weir RJ, Briggs E, Mack A, Naismith L, Taylor L, Wilson E. Blood pressure in women taking oral contraceptives. *BMJ* 1974; 1: 533-5.
4. Royal College of General Practitioner's oral contraception study: further analysis of mortality in oral contraceptive users. *J Roy Coll Gen Pract* 1981; 1: 541-6.
5. Spellacy WN, Birk SA. The effect of intrauterine devices, oral contraceptives, estrogens, and progestagens on blood pressure. *Am J Obstet Gynecol* 1972; 112: 912-6.
6. Harris PWR. Malignant hypertension associated with oral contraceptives. *Lancet* 1969; 2: 466-7.
7. Zacherle RJ, Richardson JA. Irreversible renal failure secondary to hypertension induced by oral contraceptives. *Ann Intern Med* 1972; 77: 83-5.
8. Dunn FG, Jones JV, Fife R. Malignant hypertension associated with use of oral contraceptives. *Br Heart J* 1975; 37: 336-8.
9. Zech P, Riffle G, Lindner A, Sassard J, Blanc-Brunat N, Traeger J. Malignant hypertension with irreversible renal failure due to oral contraceptives. *BMJ* 1975; 4: 326-7.
10. Lim G, Isle CG, Hodsman GP, Lever AF, Robertson JWK. Malignant hypertension in women of childbearing age and its relation to the contraceptive pill. *BMJ* 1987; 294: 1057-9.
11. Shapiro LM, Mackinnon J, Beevers DG. Echocardiographic features of malignant hypertension. *Br Heart J* 1981; 46: 374-9.
12. Collaborative Group for the Study of Stroke in Young Women. Oral contraception and increased risk of cerebral ischemia or thrombosis. *N Engl J Med* 1973; 288: 871-8.
13. Woods JW. Oral contraceptives and hypertension. *Hypertension* 1988; 2 (Suppl 2): II-11-15.
14. Beaumont V, Beaumont JL. The vascular risk of oral contraceptives. Reality and mechanism. *Presse Med* 1989; 18: 1249-53.

Submitted August 16, 1993; accepted October 20, 1993

Address for correspondence:

Luiz A Bortolotto
 Unidade de Hipertensao Instituto do Coracao
 Av. Dr. Eneas de Carvalho Aguiar 44
 São Paulo
 Brazil CEP 05403-000
 Fax: +55 11 8815048