

Violent Sleep-Related Behavior Leading to Subdural Hemorrhage

Mark E. Dyken, MD; Deborah C. Lin-Dyken, MD;
Peter Seaba, MSEE; Thoru Yamada, MD

Objective: To polysomnographically determine, using split-screen electroencephalographic-video analysis, the cause of violent sleep-related activity in a patient whose differential diagnosis includes sleep walking (somnambulism), pavor incubus (adult night terrors), nocturnal seizures, psychogenic wandering, and rapid eye movement sleep behavior disorder.

Setting: The patient was referred to the University of Iowa, Department of Neurology Sleep Disorders Center, Iowa City, from the local community to

evaluate a history of violent dreams associated with injury. The subject presented with a subdural hemorrhage that was discovered with magnetic resonance imaging.

Outcome: The diagnosis of rapid eye movement sleep behavior disorder was confirmed after a characteristic spell of violent behavior, with an associated dream, was captured polysomnographically.

(*Arch Neurol.* 1995;52:318-321)

THE RAPID eye movement (REM) sleep behavior disorder (RBD) was first described in humans in 1985.¹ It is associated with violent behavior arising from REM sleep, normally a state of essential paralysis. The diagnosis requires a history of potentially harmful sleep-related body movements associated with REM dreams.²⁻⁵ These behaviors are rarely captured by polysomnography, as most patients experience a major episode only once every 2 to 3 weeks,⁶ and, as yet, there exists no specific diagnostic criteria based on polysomnographic findings.^{5,7}

After reviewing data from several different groups, only seven (8.0%) of 87 patients with possible RBD reported dreams immediately following characteristic REM-related behaviors captured polysomnographically.^{1,2,4,5,8-19} Schenck et al²⁰ performed sleep studies on 85 adult patients with sleep-related injury. Although all RBD patients were reported to be diagnosed polysomnographically, the primary criterion for diagnosis was loss of REM atonia and emergence of vigorous behaviors during REM sleep. No patients were reported to have typical, complex behaviors associated with dream mentation captured in the laboratory.

Although clinically RBD appears to

be primarily associated with REM sleep, frequent movements (periodic and non-periodic) have been noted in non-REM sleep.⁶ Therefore, polysomnographic support for this disorder is usually based primarily on the observance of elevated muscle tone in REM sleep with nonviolent movements occurring in both REM and non-REM sleep. Subsequently, many other phenomena associated with elevated muscle tone during REM (narcolepsy,²¹ drug use,^{19,22-24} Parkinson's disease,²⁵ and the posttraumatic stress disorder²⁶) or excessive movements during sleep (seizure,²⁷ paroxysmal nocturnal dystonia,²⁷⁻²⁹ somnambulism and night terrors³⁰), psychiatric conditions (such as dissociative states,²⁸ malingering,³¹ Munchausen syndrome by proxy,³¹ posttraumatic stress disorder,⁵ and nocturnal panic attacks⁶), and sleep drunkenness^{27,32} (behavioral responses to arousals induced by disorders such as sleep apnea and/or periodic limb movements) may be misdiagnosed and inappropriate therapy can occur.

REPORT OF A CASE

We describe a 73-year-old man with a history of tobacco abuse (discontinued after a myocardial infarction suffered in 1976). His only medication was ranitidine hy-

From the Departments of Neurology Sleep Disorders Center (Drs Dyken and Yamada and Mr Seaba) and the Department of Pediatrics, Division of Developmental Disabilities (Dr Lin-Dyken), University of Iowa College of Medicine, Iowa City.

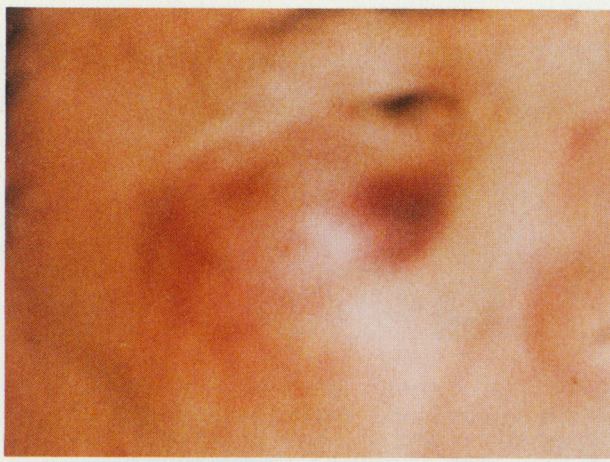

Figure 1. Superficial injury sustained to the right maxillary region during a violent sleep behavior.

drochloride, 150 mg/d, taken for a remote history of peptic ulcer disease. He presented with a 10-year history of violent dreams. He stated: "I act them out, sometimes I hurt myself, I go through the motions of what I'm dreaming about." His dreams occurred "almost every night." On occasion, he unintentionally struck his wife. Recently, he dreamed of working on a loading dock and he had seen a man running. He reported: "Someone yelled, 'stop him.' I tried." His wife reported that he jumped off the end of the bed and awoke on the floor with "a bloody lip, head, and knee."

During another episode, the patient leaped from his bed, fell, and struck the right side of his face on a corner of a chest (**Figure 1**). He immediately awoke and complained of a headache and nausea and vomited. He appeared confused for a 3-hour period, after which he was alert and had no complaints.

Results of the neurologic examination were normal, and RBD was suspected clinically. A magnetic resonance imaging scan of the brain revealed a left-sided subdural hemorrhage, which had completely resolved by the time of a second study 9 months later (**Figure 2**).

A standard polygraph (Nicolet [Madison, Wis] 1A97) was used to record the electroencephalogram, electrooculogram, electromyogram (chin, bilateral anterior tibialis, and intercostal muscles), electrocardiogram, and respiratory air flow and effort parameters. The study was recorded and sleep was scored according to the criterion of Rechtschaffen and Kales.³³ The analog outputs of the 1A97 were input to a reformatter (W/TV-16B, Telefactor Corp, Conshohocken, Pa) that converted the analog inputs to a video signal, simulating the paper recording. This simulation was then mixed with a video image of the patient. The combined video image (patient and data) was displayed on a video monitor while being recorded on the video track of a standard videocassette recorder. Audio from the patient's room was recorded on the audio track of the tape. The video image of the patient was obtained using a low-level black-and-white video camera and infrared light.

The overnight polysomnogram was remarkable for significant periodic limb movements (with a move-

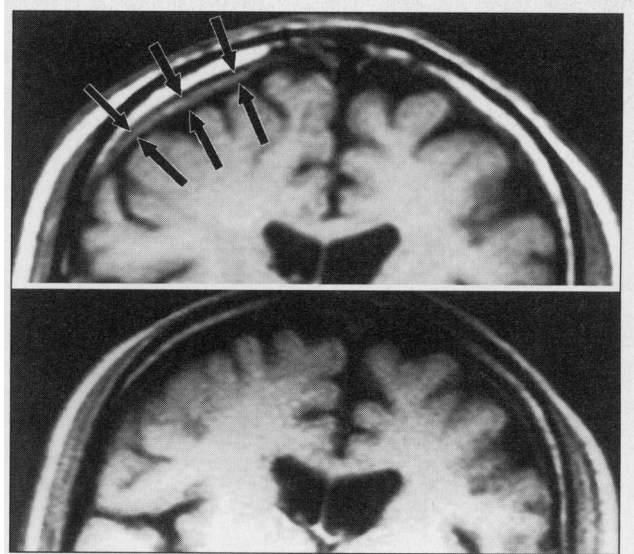


Figure 2. Top, A brain magnetic resonance image of the patient revealed a subdural hemorrhage outlined by the black arrows. Bottom, A 6-month follow-up study demonstrates resolution of the hematoma.

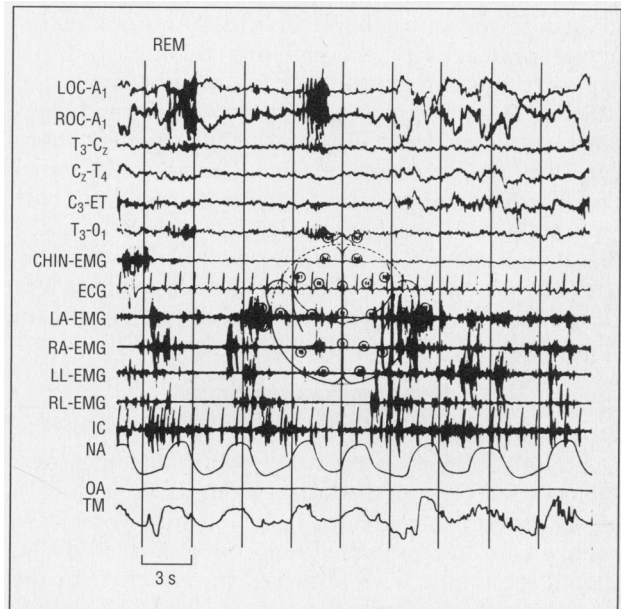


Figure 3. Polysomnographic tracing generally revealed the classic electromyographic augmentation that is associated with rapid eye movement (REM) sleep in the REM sleep behavior disorder. LOC indicates left outer canthus; ROC, right outer canthus; T, temporal; C, central; ET, ears tied; O, occipital; LA, left arm; RA, right arm; LL, left leg; RL, right leg; IC, intercostal electromyogram; NA, nasal airflow; OA, oral airflow; and TM, thoracic movement.

ment index of 52.0 events per hour and a movement-arousal index of 3.0 events per hour) and an increase in phasic limb movements throughout most REM sleep periods (**Figure 3**). There was no evidence of sleep apnea or epileptiform activity. Over a 5-month period, a trial of oral clonazepam, 0.5 mg taken orally every evening before sleep, was instituted. The patient reported marked improvement, without complete resolution of his violent nocturnal behavior.

Subsequently, clonazepam was discontinued for a 3-day period, after which three consecutive nights of

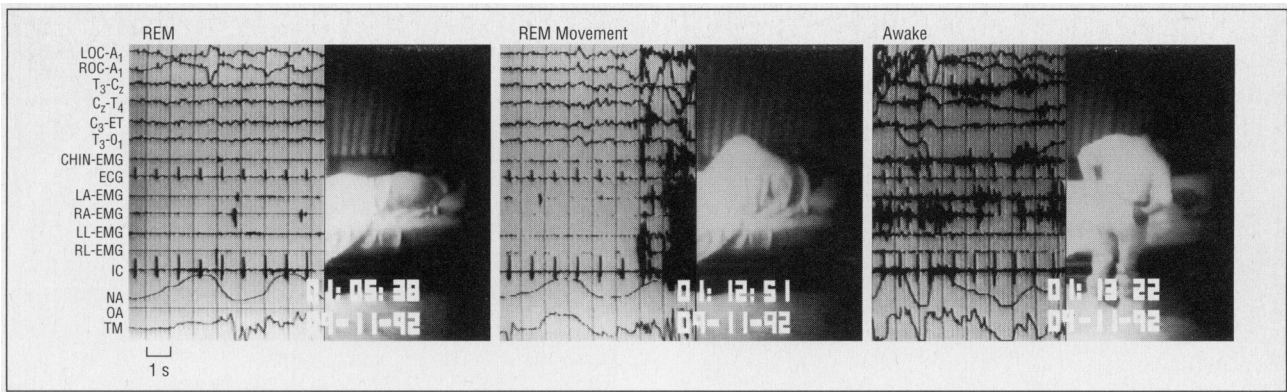


Figure 4. These split-screen polysomnographic tracings of our patient (left, center, and right) temporally document the course (before, during, and after, respectively) of a typical violent rapid eye movement (REM) behavior followed by a spontaneous dream report. LOC indicates left outer canthus; ROC, right outer canthus; T, temporal; C, central; ET, ears tied; O, occipital; LA, left arm; RA, right arm; LL, left leg; RL, right leg; IC, intercostal electromyogram; NA, nasal airflow; OA, oral airflow; and TM, thoracic movement.

polysomnography were performed. Each study revealed significant periodic limb movements and a general loss of atonia during REM sleep. In the third night study, during one REM episode, after a prolonged period of uncharacteristically quiet electromyographic activity, the patient suddenly exhibited explosive running movements, followed by an arousal (**Figure 4**). Subsequently, he was coherent and demonstrated no evidence of confusion. The patient spontaneously reported "one of them dreams. As it started out, I was chasing cattle," after which the animals reportedly turned and pursued him. It should be noted that the patient is a cattle farmer. He was subsequently treated with 1.0 mg of oral clonazepam taken before sleep, with complete resolution of all violent dream activity over the following year.

COMMENT

Our case is important because we have documented a typical spell of RBD that arises from REM sleep with associated violent, directed behavior, followed by the spontaneous, nonprompted report of a detailed dream that corresponds with observed movements. In the sleep laboratory, videotaped actions, felt to be characteristic for RBD, are rarely followed by full arousals.^{4,6,16} Therefore, few of these patients have polysomnographically documented violent behavior associated with the report of dreaming, and, to our knowledge, no published studies provide split-screen, videotaped evidence of such a spell, where temporally related behavior and electroencephalographic activity can be appreciated simultaneously.

Dreamlike mentation can occur from stages of sleep other than REM.^{2,4,26,34,35} In addition, violent behaviors associated with dreams have been reported not only in RBD but in nightmares associated with the posttraumatic stress disorder,^{26,35} somnambulism, night terrors, and sleep apnea.²⁷ Schenck et al²⁸ point out that the diagnosis of sleep-related injury cannot be determined only from clinical characteristics of the behavior, the time of night the behavior occurs, or the degree of event or dream recall, as these features can

appear similar in dream interruption insomnia,^{36,37} somnambulism/night terrors,^{27,38,39} seizures, and RBD.

Subsequently, RBD has frequently been misdiagnosed as nocturnal seizure, psychiatric disorder,²⁷ and sleep apnea.^{2,6} In addition, there has been a recent proposal for the existence of "overlapping syndromes" that exhibit characteristics suggestive of both RBD and sleepwalking/night terrors. In the two cases presented by Hurwitz et al,⁴⁰ complex violent behavior with reported dream imagery was not captured polysomnographically.

Up to 77.1% of patients with RBD present with mild-to-moderate sleep-related injuries, including bruises, lacerations, dislocations, and fractures.⁶ Rarely is the RBD reported to be associated with serious injury, but, owing to the limited use of appropriate monitoring techniques, the true magnitude of these problems may be underestimated.^{7,27,28}

There has been only one other documented case of RBD causing subdural hematoma.⁸ A 73-year-old man, with a 2-year history of almost nightly violent movements in sleep, reportedly hit his head on a table "in a dream." A computed tomogram of the head revealed bilateral subdural hematomas, while polysomnography demonstrated violent movements during REM sleep. The nature of the violent movements was not described, and none were reported to be associated with dream mentation.

Using advanced split-screen video-imaging techniques, we were able to capture a classic REM episode of violent behavior followed by a dream report. These technical capabilities allowed us to confidently diagnose and successfully treat RBD in a patient with an associated subdural hemorrhage.

Accepted for publication November 1, 1993.

We acknowledge the comments and technical assistance given by Harold Adams, MD, and Christine Glenn, REEGT, RPSGT, of the Department of Neurology, University of Iowa College of Medicine, Iowa City, in the preparation of this article.

Reprint requests to Department of Neurology, University of Iowa College of Medicine, Iowa City, IA 52242 (Dr Dyken).

1. Schenck CH, Bundlie SR, Mahowald MW. Human REM sleep chronic behavior disorders: a new category of parasomnia. *Sleep Res.* 1985;14:208. Abstract.
2. Schenck CH, Bundlie SR, Ettinger MG, Mahowald MW. Chronic behavioral disorders of human REM sleep: a new category of parasomnia. *Sleep.* 1986;9:293-308.
3. Thorpy MJ and the Diagnostic Classification Steering Committee. REM sleep behavior disorder. In: *The International Classification of Sleep Disorders: Diagnostic and Coding Manual.* Rochester, Minn: American Sleep Disorders Association; 1990:177-180.
4. Mahowald MW, Schenck CH. REM sleep behavior disorder. In: Kryger MH, Roth T, Dement WC. *Principles and Practice of Sleep Medicine.* Philadelphia, Pa: WB Saunders Co; 1989:389-401.
5. Lapiere O, Montplaisir J. Polysomnographic features of REM sleep behavior disorder: development of a scoring method. *Neurology.* 1992;42:1371-1374.
6. Schenck CH, Mahowald MW. Polysomnographic, neurologic, psychiatric and clinical outcome report on 70 consecutive cases with REM sleep behavior disorder (RBD): sustained clonazepam efficacy in 89.5% of 57 treated patients. *Cleve Clin J Med.* 1990;57(suppl):9-23.
7. Assessment: techniques associated with the diagnosis and management of sleep disorders: report of the therapeutics and technology assessment subcommittee of the American Academy of Neurology. *Neurology.* 1992;42:269-275.
8. Gross PT. REM sleep behavior disorder causing bilateral subdural hematomas. *Sleep Res.* 1992;21:204. Abstract.
9. Storza E, Zucconi M, Petronelli R, Lugaresi E, Cirignotta F. REM sleep behavioral disorders. *Eur Neurol.* 1988;28:295-300.
10. Salva MAQ, Guilleminault C. Olivopontocerebellar degeneration, abnormal sleep, and REM sleep without atonia. *Neurology.* 1986;36:576-577.
11. Herman JH, Blaw ME, Steinberg JB. REM behavior disorder in a 2-year-old male with evidence of brainstem pathology. *Sleep Res.* 1989;18:242. Abstract.
12. Doghramji K, Connell TA, Gaddy JR. Loss of REM sleep atonia: three case reports. *Sleep Res.* 1987;16:327. Abstract.
13. Culebras A, Moore JT. Magnetic resonance findings in REM sleep behavior disorder. *Neurology.* 1989;39:1519-1523.
14. Shimizu T, Inami Y, Sugita Y, et al. REM sleep without muscle atonia (stage 1-REM) and its relation to delirious behavior during sleep in patients with degenerative disease involving the brain stem. *Jpn J Psychiatry Neurol.* 1990;44:681-692.
15. Schenck CH, Bundlie SR, Patterson AL, Mahowald MW. Rapid eye movement sleep behavior disorder: a treatable parasomnia affecting older adults. *JAMA.* 1987;257:1786-1789.
16. Schenck CH, Mahowald MW. Motor dyscontrol in narcolepsy: rapid-eye-movement (REM) sleep without atonia and REM sleep behavior disorder. *Ann Neurol.* 1992;1:3-10.
17. Bamford CR. Carbamazepine in REM sleep behavior disorder. *Sleep.* 1993;16:33-34.
18. Schenck CH, Mahowald MW. Injurious sleep behavior disorders (parasomnias) affecting patients on intensive care units. *Intensive Care Med.* 1991;17:219-224.
19. Schenck CH, Mahowald MW, Kim SW, O'Connor KA, Hurwitz TD. Prominent eye movements during NREM sleep and REM sleep behavior disorder associated with fluoxetine treatment of depression and obsessive-compulsive disorder. *Sleep.* 1992;15:226-235.
20. Schenck C, Milner D, Hurwitz T, Bundlie S, Mahowald M. Sleep-related injury in 85 adult patients: a polysomnographic study. *Sleep Res.* 1988;17:247. Abstract.
21. Montplaisir J. Disturbed nocturnal sleep. In: Guilleminault C, Dement WC, Pasouant P, eds. *Advances in Sleep Research: Narcolepsy.* New York, NY: Spectrum; 1976:43-56.
22. Akindele MO, Evans JI, Oswald I. Mono-amine oxidase inhibitors, sleep and mood. *Electroencephalogr Clin Neurophysiol.* 1970;29:47-56.
23. Dunleavy DLF, Brezina V, Oswald I, Maclean AW, Tinker M. Changes during weeks in effects of tricyclic drugs on the human sleeping brain. *Br J Psychiatry.* 1972;120:663-672.
24. Lacey JH, Crisp AH, Crutchfield M, Hawkins C, Hartmann M. Clomipramine and sleep: a preliminary communication. *Postgrad Med J.* 1977;53(suppl 4):35-40.
25. Moutret J. Differences in sleep in patients with Parkinson's disease. *Electroencephalogr Clin Neurophysiol.* 1975;38:653-657.
26. Schlosberg A, Benjamin M. Sleep patterns in three acute combat fatigue cases. *J Clin Psychiatry.* 1978;39:546-548.
27. Schenck CH, Milner DM, Hurwitz TD, Bundlie SR, Mahowald MW. A polysomnographic and clinical report on sleep-related injury in 100 adult patients. *Am J Psychiatry.* 1989;146:1166-1172.
28. Schenck CH, Milner DM, Hurwitz TD, Bundlie SR, Mahowald MW. Dissociative disorders presenting as somnambulism: polysomnographic, video and clinical documentation (8 cases). *Dissociation.* 1989;2:194-203.
29. Lugaresi E, Cirignotta F. Hypnogenic paroxysmal dystonia: epileptic seizure or a new syndrome? *Sleep.* 1981;4:129-138.
30. Guilleminault C. Sleepwalking and night terrors. In: Kryger MH, Roth T, Dement WC. *Principles and Practice of Sleep Medicine.* Philadelphia, Pa: WB Saunders Co; 1989:379-384.
31. Mahowald MW, Schenck CH, Rosen GM, Hurwitz TD. The role of a sleep disorder center in evaluating sleep violence. *Arch Neurol.* 1992;49:604-607.
32. Mahowald MW, Bundlie SR, Hurwitz TD, Schenck CH. Sleep violence-forensic science implications: polygraphic and video documentation. *J Forensic Sci.* 1990;35:413-432.
33. Rechtschaffen A, Kales A. *A Manual of Standardized Terminology, Techniques and Scoring System for Sleep Stages of Human Subjects.* Bethesda, Md: National Institutes of Health; 1968:204.
34. Dement W, Kleitman N. Cyclical variations in EEG during sleep and their relation to eye movements, body motility, and dreaming. *Electroencephalogr EEG Clin Neurophysiol.* 1957;9:673-690.
35. van der Kolk B, Blitz R, Burr W, Sherry S, Hartmann E. Nightmares and trauma: a comparison of nightmares after combat with lifelong nightmares in veterans. *Am J Psychiatry.* 1984;141:187-190.
36. Greenberg R. Dream interruption insomnia. *J Nerv Ment Dis.* 1967;144:18-21.
37. Frederickson PA, Krueger BR. Insomnia associated with specific polysomnographic findings. In: Kryger MH, Roth T, Dement WC, eds. *Principles and Practice of Sleep Medicine.* Philadelphia, Pa: WB Saunders Co; 1989:476-489.
38. Broughton RJ. Sleep disorders: disorders of arousal? *Science.* 1968;159:1070-1078.
39. Kales A, Jacobson A, Paulson MJ, Kales JD, Walter RD. Somnambulism: psychophysiological correlates, I: all-night EEG studies. *Arch Gen Psychiatry.* 1966;14:586-594.
40. Hurwitz TD, Schenck CH, Mahowald MW. Sleepwalking-sleep terrors-REM sleep behavior disorder: overlapping parasomnias. *Sleep Res.* 1991;20:260. Abstract.