

***Mycobacterium genavense* Infection Presenting as a Solitary Brain Mass in a Patient with AIDS: Case Report and Review**

Stephen M. Berman, Ronald C. Kim, Dennis Haghghat, Maury E. Mulligan, Joshua Fierer, and Frederic C. Wyle

Departments of Medicine and Pathology, Veterans Affairs Medical Center, Long Beach; University of California, Irvine; and Veterans Affairs Medical Center, La Jolla, California

Patients with AIDS are prone to developing infections with opportunistic pathogens. Recently, a new mycobacterium, *Mycobacterium genavense*, has been found to cause infection in patients with AIDS. Previously published reports indicate that patients who are infected with this organism present with the same clinical features as do patients with disseminated infection due to organisms of the *Mycobacterium avium* complex. We describe an unusual case of a patient with AIDS who presented with grand mal seizures and a mass lesion in his brain, which was found to be caused by infection with *M. genavense*. No evidence of disseminated infection could be found in this patient. We discuss the microbiology of this organism and review the literature on *M. genavense* infections. Clinicians should be aware of this organism so that efforts at culture and identification will be made.

Patients with AIDS develop numerous opportunistic infections and are particularly prone to infections caused by *Mycobacterium tuberculosis* and by organisms belonging to the *Mycobacterium avium* complex (MAC). Most MAC infections are disseminated, and the patients usually present with chronic fevers and weight loss and often with anemia [1]. Recently there have been several reports of disseminated infection due to *Mycobacterium genavense*, a new member of the genus *Mycobacterium* [2–5]. All of the patients described in these reports presented with signs and symptoms similar to those seen in patients with disseminated MAC infection [1]. We describe a patient with AIDS who presented after having a seizure; he was found to have a cerebral mass lesion that was caused by infection with *M. genavense*. We believe that this is the first patient with infection due to this organism to present in such a fashion.

Case Report

On 30 November 1992 a 50-year-old male homosexual was admitted to the Long Beach Veterans Affairs Medical Center after having a grand mal seizure. He had tested positive for infection with the human immunodeficiency virus (HIV) in May 1992. At that time his CD4 lymphocyte count was 84/mm³. He was treated with zidovudine, trimethoprim-sulfamethoxazole (three times per week), and fluconazole for oral candidiasis. Questioning of the patient revealed that he had had two episodes of right arm tremor within the previous month, right arm paresthesias and weakness for 2

weeks, and memory impairment and confusion over the month preceding admission.

Physical examination was remarkable for multiple lesions of molluscum contagiosum and several lesions of Kaposi's sarcoma on both lower extremities. Slight weakness of the right side, a mild sensory deficit in the right upper extremity, and slightly slurred speech were noted. A computed tomographic scan (without contrast medium) of the patient's head showed a large area of cerebral edema with mild mass effect in the upper left parietal lobe. Enzyme immunoassay revealed serum IgG (218 IU/L) to *Toxoplasma*. He was empirically treated with pyrimethamine and sulfadiazine for possible toxoplasmosis of the CNS despite the fact that the radiological findings were atypical for this infection.

Seven days later he had another grand mal seizure. Magnetic resonance imaging (MRI) showed a solid, enhancing, peripheral left parietal mass (2 cm wide × 1.3 cm thick) that abutted onto the dura; there was slight meningeal enhancement and an 8-cm area of surrounding edema (figure 1). The patient was given dexamethasone to reduce the edema and underwent a stereotactic CT-guided needle biopsy of the mass. Histopathological examination of the biopsy specimen showed a scattered, sometimes perivascular lymphohistiocytic inflammatory infiltrate in the cerebral cortex and white matter, but there was no evidence of granulomata or multinucleated giant cells. Ziehl-Neelsen staining of the biopsy specimen revealed clusters of acid-fast bacilli (AFB). Therapy with isoniazid, rifampin, pyrazinamide, clarithromycin, and ciprofloxacin was initiated to treat infection due to *M. tuberculosis* and *M. avium*. Eventually culture of the biopsy specimen yielded *M. genavense*. Therapy was changed to that with clarithromycin, ciprofloxacin, and ethambutol. The dosage of dexamethasone was slowly tapered over a 12-week period.

Repeated MRI performed 6 months after the diagnosis was made showed a marked decrease in the size of the mass and decreased edema. The patient did well clinically while

Received 1 February 1994; revised 26 April 1994.

Reprints or correspondence: Dr. Stephen M. Berman, 5901 East Seventh Street, 111-ID, Long Beach, California 90822.

Clinical Infectious Diseases 1994;19:1152–4

© 1994 by The University of Chicago. All rights reserved.
1058-4838/94/1906-0026\$02.00

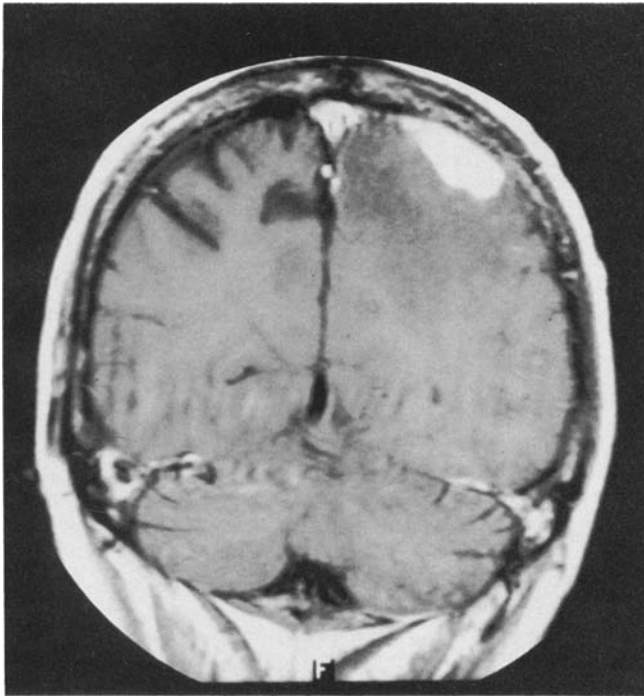


Figure 1. Magnetic resonance imaging scan with gadolinium showing a solid, enhancing mass (2 cm × 1.3 cm) in the left parietal area of a patient with AIDS and infection due to *Mycobacterium genavense*.

receiving the above-described regimen plus phenytoin (not including dexamethasone); he did not have any seizures for several months. MRI performed 1 year after he started receiving therapy showed complete resolution of the mass lesion and the edema.

We were unable to detect or isolate AFB from blood, bone marrow, stool, or sputum, and examination of the bone marrow did not reveal any evidence of granulomatous infection.

Microbiology

The initial fluorochrome smear of the brain biopsy specimen revealed numerous AFB. The tissue was inoculated directly into BACTEC 12B broth (Becton Dickinson, Towson, MD) and onto Middlebrook 7H11 agar. There was no growth on the agar. Growth in the BACTEC 12B broth increased slowly for the first 2 weeks and then began to decrease; numerous AFB were apparent in the bottle at this time. Subculture of the broth in another BACTEC-12B bottle did not produce growth. However, the organism grew slowly in BACTEC 12B broth supplemented with 10% brain-heart infusion medium (Difco, Detroit). The isolate was sent to Dr. Erik Böttger who identified it as *M. genavense* on the basis of analysis of the 16S rRNA [3]. The organism was also

subcultured on Middlebrook 7H11 agar supplemented with 2 µg of mycobactin J (Allied Laboratories, Fayette, MO) and on Löwenstein-Jensen culture medium supplemented with human blood. Colonies grew slowly and were dysgonic and nonpigmented after 6 weeks. They were negative for niacin production and nitrate reduction and positive for urease production, characteristics consistent with those of *M. genavense* [6, 7].

Discussion and Literature Review

A fatal infection with an unidentified AFB recently occurred in a patient with AIDS [2]. The organism could not be grown in culture, and nucleic acid analysis indicated that the organism was not *M. avium* or *Mycobacterium leprae*. Böttger et al. [3] later described 18 patients with advanced HIV infection who had similar illnesses. The authors were able to grow AFB in liquid medium only. With use of DNA amplification techniques, they determined that the organism was a new member of the genus *Mycobacterium*, and they named it *M. genavense*. All 18 patients whom they described presented with fever, diarrhea, and marked weight loss. Subsequently, Wald et al. [4] described seven patients with AIDS who had similar symptoms; cultures of blood from these patients yielded *M. genavense*. The authors were able to culture the organism only on Middlebrook 7H11 agar supplemented with mycobactin J (2 µg/mL); however, there was never enough growth for standard biochemical analysis and drug susceptibility testing.

More recently, Pecheré et al. [5] reviewed the clinical features of 44 cases (including some of the cases mentioned herein) of *M. genavense* infection that occurred in six countries; 74% of the patients had wasting, 50% had diarrhea, 26% had abdominal pain, and virtually all had fevers and/or night sweats. The estimated mortality rate was 68% at 12 months after diagnosis. It is significant that patients who received medication that was effective against mycobacteria (especially *M. avium*) survived for markedly longer periods than those who did not receive therapy.

M. genavense has recently been isolated and characterized in the laboratory by use of a variety of techniques [6]. However, there are no data on the organism’s antibiotic susceptibility patterns. Böttger et al. [7] believed that regimens for *M. avium* infection may be effective in treating patients with *M. genavense* infection because the clinical features of patients infected with either organism are similar; our case supports this belief because the patient responded to treatment with agents that are frequently used to treat *M. avium* complex infections [8].

To our knowledge, this is the first case of infection with *M. genavense* presenting as a mass lesion in the brain with no other signs of disseminated infection. We were unable to find

evidence of the organism in any other site outside the brain. The findings in this case illustrate the value of aggressive intervention (including biopsy of mass lesions in the CNS of HIV-infected patients) when there is no response to antitoxoplasmal therapy. The findings also point out the difficulty of identifying fastidious mycobacteria and selecting appropriate therapy. To increase the diagnostic yield for cases of infection with *M. genavense*, consideration should be given to inoculating all liquid cultures that are positive for AFB onto Löwenstein-Jensen agar supplemented with human blood or onto Middlebrook 7H11 agar containing mycobactin J. Finally, further work needs to be done in the laboratory to facilitate antibiotic susceptibility testing of this organism.

Acknowledgments

The authors thank Dr. Erik Böttger and his laboratory staff for their assistance in definitively identifying the isolate as *M. genavense*.

References

1. Hawkins CC, Gold JWM, Whimbey E, et al. Mycobacterium avium complex infections in patients with the acquired immunodeficiency syndrome. *Ann Intern Med* 1986;105:184–8.
2. Hirschel B, Chang HR, Mach N, et al. Fatal infection with a novel, unidentified mycobacterium in a man with the acquired immunodeficiency syndrome. *N Engl J Med* 1990;323:109–13.
3. Böttger EC, Teske A, Kirschner P, et al. Disseminated “*Mycobacterium genavense*” infection in patients with AIDS. *Lancet* 1992;340:76–80.
4. Wald A, Coyle MB, Carlson LC, Thompson RL, Hooton TM. Infection with a fastidious mycobacterium resembling *Mycobacterium simiae* in seven patients with AIDS. *Ann Intern Med* 1992;117:586–9.
5. Pechéré M, Emler S, Wald A, et al. Infection with *Mycobacterium genavense* (MG): clinical features in 44 cases [abstract no. WS-B10-2]. In: Program and abstracts of the 9th International Conference on AIDS (Berlin). 1993.
6. Coyle MB, Carlson LC, Wallis CK, et al. Laboratory aspects of “*Mycobacterium genavense*,” a proposed species isolated from AIDS patients. *J Clin Microbiol* 1992;30:3206–12.
7. Böttger E, Hirschel B, Coyle MB. *M. genavense* sp. nov. *Int J Syst Bacteriol* 1993;43:841–3.
8. Chiu J, Nussbaum J, Bozzette S, et al. Treatment of disseminated Mycobacterium avium complex infection in AIDS with amikacin, ethambutol, rifampin, and ciprofloxacin. *Ann Intern Med* 1990;113:358–61.