

Cerebral Infarction Due to Painless Thoracic Aortic and Common Carotid Artery Dissections

Catherine Veyssier-Belot, MD; Ariel Cohen, MD; Didier Rougemont, MD; Claude Levy, MD; Pierre Amarenco, MD; Marie-Germaine Bousser, MD

Background: Aortic arch dissection is usually lethal unless emergency surgery is performed. The dissection rarely may have a benign outcome or may occur without pain and be revealed by cerebral infarction. It is then likely to be seen primarily by a neurologist. In such cases, the value of new noninvasive diagnostic testing has not been reported.

Case Description: A 51-year-old man had a sudden left-sided hemiplegia due to hemorrhagic capsular and caudate infarcts on the right side. Cervical ultrasound examination with color flow imaging showed a bilateral common carotid artery dissection extending up to the bifurcation. Transesophageal echocardiography showed an aortic arch dissection, involving the innominate and left common carotid artery origins, which was confirmed by magnetic resonance imaging and aortography. The patient spontaneously fully recovered and is still alive 24 months after the stroke onset.

Conclusions: This case emphasizes the usefulness of new noninvasive techniques such as transesophageal echocardiography and color-coded Doppler echocardiography in the diagnosis and follow-up of painless dissection of aortic and common carotid arteries. This cause of stroke may be underestimated. (*Stroke*. 1993;24:2111-2113.)

KEY WORDS • aortic arch • cerebral infarction • dissection • echocardiography • ultrasonics

Neurological symptoms related to acute aortic dissection have been reported^{1,2} and have been found to clearly worsen the prognosis.³ However, their mechanism is generally unclear because such patients usually rapidly died. New screening tools such as transesophageal echocardiography, color-coded Doppler echocardiography, and magnetic resonance imaging are now available for the diagnosis of aortic arch and common carotid artery dissections⁴ and should allow a better understanding of the mechanism of cerebral infarction in such cases. We had the unique opportunity to compare the usefulness of these new noninvasive techniques with angiography in a patient presenting with an ischemic stroke as the first symptom of aortic and common carotid artery dissections.

Case Report

A 51-year-old right-handed man with a past history of heavy smoking suddenly had a left-sided hemiplegia with facial palsy and dizziness. Computed tomographic (CT) scan without contrast showed a right capsular and caudate hemorrhagic infarct. Blood pressure was initially normal, and the patient did not report any thoracic pain. Electrocardiogram was normal. The next day the

patient developed signs of cardiovascular collapse with convulsions and coma. He was transferred to the intensive care unit, where the shock resolved rapidly and the state of consciousness improved. Over the next few days, blood pressure remained high (190/100 mm Hg), and fever (39°C), inflammatory state, and anemia appeared (erythrocyte sedimentation rate, 130 mm/h; platelet count, 900 000/mm³; fibrin, 12 g/L; white blood cell count, 25 000/mm³). The patient was treated for a presumed aspiration pneumonia.

Two weeks later, the patient was fully conscious but still had a left-sided hemiplegia and facial weakness, with no sensory or visual field disturbance. Blood pressure was 180/100 mm Hg. Femoral pulses were weak, and left posterior tibial and dorsalis pedis pulses were not found. Bruits were present in carotid and femoral arteries bilaterally. No diastolic murmur was heard at cardiac examination. Serum creatinine was 120 μmol/L. Cervical ultrasound examination with color-coded Doppler showed a subintimal dissection with a false lumen of the right innominate artery and of the right and left common carotid arteries extending up to their bifurcation (Fig 1 left). Transcranial Doppler was normal. Transthoracic echocardiography was normal, but thoracic aorta was poorly visualized. Transesophageal echocardiography was performed under local anesthesia, mild sedation (midazolam 5 mg IV), and continuous blood pressure monitoring. It showed a dissection involving the ascending aorta, the arch, and the thoracic aorta (Fig 1 right). The mobile intimal flap separating the true and false lumen was visualized 2 cm above the aortic leaflets. There was no evidence of entry tear using Doppler color flow imaging and no sign of aortic valve

Received May 20, 1993; final revision received July 6, 1993; accepted July 6, 1993.

From the Departments of Neurology (C.V.-B., D.R., P.A., M.-G.B.), Cardiology (A.C.), and Neuroradiology (C.L.), Hôpital Saint-Antoine, Université Pierre et Marie Curie, Paris, France.

Review of this manuscript was directed by Editor-in-Chief Mark L. Dyken.

Correspondence to P. Amarenco, MD, Service de Neurologie, Hôpital Saint-Antoine, 184 rue du Fg St-Antoine, 75571 Paris Cédex 12, France.

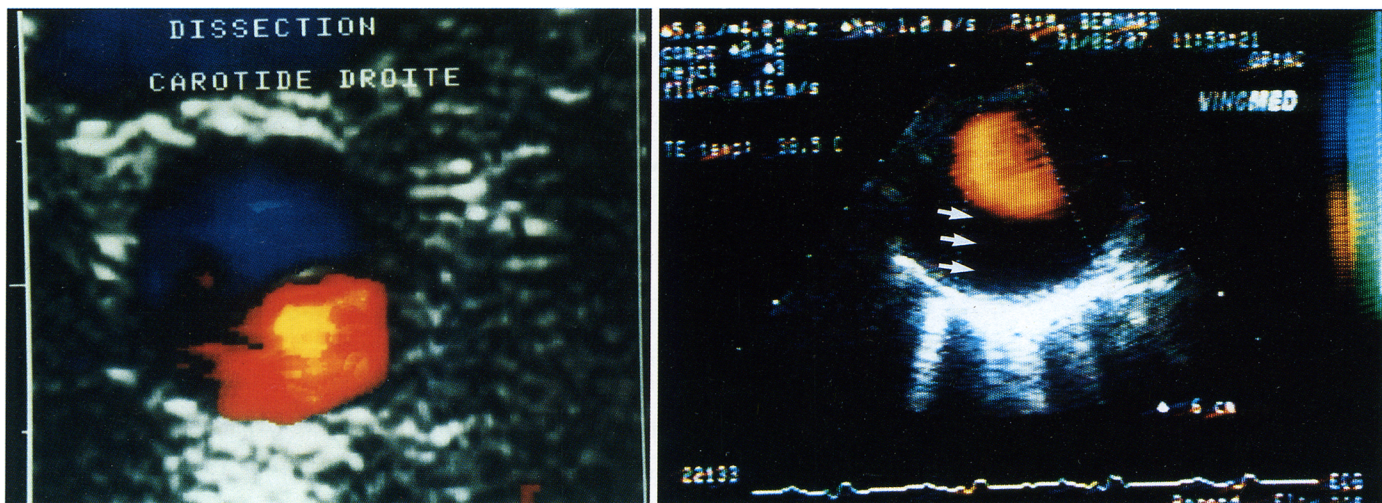


FIG 1. Left, Echography of the common carotid artery with color flow imaging. Dissection of the artery is shown; the residual lumen is coded in red and the false channel in blue. Right, Transesophageal echocardiography of the aortic arch with color flow imaging. The residual lumen is coded in red and false channel of the dissection in black (white arrows).

incompetence, pericardial effusion, or left ventricular dysfunction. The false channel was well defined and extended into the ostia of the innominate and left common carotid arteries. Magnetic resonance imaging showed the false channel in common carotid arteries and along the thoracic and abdominal aorta (Fig 2). Aortography confirmed the lesions and showed an involvement of the abdominal aorta, left renal artery, and both common femoral arteries (Fig 3). There were no signs of fibromuscular dysplasia and no clinical and familial evidence of Marfan or Ehlers-Danlos syndrome. The patient did not undergo surgery.

Within 8 weeks, the patient fully recovered. Two years later, he is still alive and has had no recurrent neurological or cardiovascular symptoms. Follow-up cervical ultrasound examination with color-coded Doppler and transesophageal echocardiography showed

spontaneous echo contrast in the false lumen with no thrombosis in both the cervical arteries and aorta.

Discussion

The clinical presentation of this patient was most unusual. First, the typical "tearing pain" of aortic arch dissection was lacking, a feature observed in less than 10% of cases.^{1,5} Second, short- and long-term outcomes were favorable. Painless aortic dissections with neurological symptoms are more likely to be seen by neurologists and might have been underdiagnosed in the past in the absence of angiography with aortography. Neurological ischemic complications are found in less than 20% of patients with aortic dissection and involve the brain, spinal cord, and peripheral nerves.^{3,6}

Cerebral infarcts are due to common carotid occlusion or artery-to-artery embolism from a thrombus

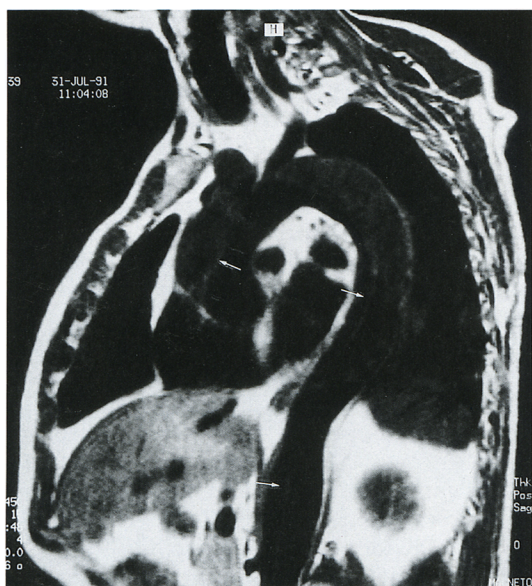

FIG 2. Magnetic resonance imaging of the aortic arch and cervical arteries showing a dissection with false channel (arrows).

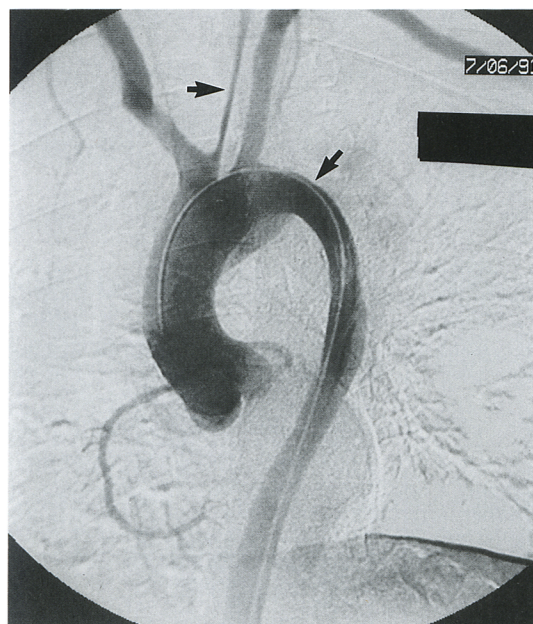


FIG 3. Angiography of the aortic arch showing a narrowing of the lumen of the thoracic aorta and left carotid.

developed on the intimal surface of the dissected artery. However, in such a severe condition the exact mechanism is usually determined at autopsy.^{2,7} The common carotid artery can be occluded at its origin by progression of the false lumen with subsequent thrombosis or by intimal detachment at the branch orifice. It can also be involved by the upward progression of the dissection without lumen occlusion. In our patient, it was demonstrated using color flow duplex scanning of extracranial arteries and transesophageal echocardiography (Fig 1). This is, to our knowledge, the first case report of a living individual with combined common carotid and aortic arch dissections demonstrated by these noninvasive techniques.

The common carotid artery is often poorly visualized at aortic arch angiography, and this might explain why the association of aortic and common carotid artery dissection, although common at autopsy,⁷ was never reported intravital.^{8,9} Doppler color flow imaging with B-mode duplex scanning is now recommended for the diagnosis of common carotid artery dissection.⁸

Aortography is still considered the gold standard to demonstrate the dissection of the aorta and its branches and recognize aortic valve incompetence; furthermore, it allows coronary angiography. However, it is an invasive and potentially dangerous procedure that requires several injections of contrast media and can be falsely negative. Both CT and ultrafast CT are accurate in detecting aortic dissection, its extent, and pericardial effusion in critically ill patients, but they give no information about the aortic valve and require several bolus injections of contrast material. Magnetic resonance imaging is useful to evaluate thoracic aortic dissection, flow void, and false lumen¹⁰ with a sensitivity of 90% and a specificity of 100%, but it cannot be performed in patients with assisted ventilation, metallic prosthetic heart valve, or pacemaker. Transesophageal echocardiography allows noninvasive bedside diagnosis of aortic dissection¹¹ with a 99% sensitivity and 98% specificity.¹² It also assesses the ascending aorta, pericardium, and aortic valve and in most cases allows a decision regarding surgery to be made without other investigations.^{4,11,13,14} However, transesophageal echocardiography can be falsely negative in localized aortic arch dissections and falsely positive in the presence of echo reverberations. Transesophageal echocardiography is also acknowledged to be more sensitive than transthoracic echocardiography in searching for a source of emboli in patients with cerebral infarction.¹⁶ The present case shows that it is probably the best way to diagnose aortic arch dissection in that situation and to follow up this lesion.

Aortic arch dissection is rarely seen at a chronic stage (with onset of dissection more than 15 days previously) because of the high mortality rate in the first 15 days. Rapid surgery is usually required¹ and significantly improves survival,³ even in patients with neurological symptoms.³ However, in the present case, the extension

of the dissection from the aortic arch up to the bifurcation of common carotid arteries contraindicated surgery. Nevertheless, at 24-month follow-up the patient had no residual symptoms or signs, and duplex scanning and transesophageal echocardiography found a spontaneous echo contrast within the false lumen without any vessel dilatation or thrombus formation.

Painless aortic arch dissection can rarely occur with cerebral infarction and in that case is likely to be seen by neurologists. In that situation, Doppler color flow imaging and transesophageal echocardiography are accurate and complementary noninvasive techniques to detect aortic arch and common carotid artery dissections.

References

1. De Sanctis RW, Doroghazi RM, Austen WG, Buckley MJ. Aortic dissection. *N Engl J Med*. 1987;317:1060-1067.
2. Chase TN, Rosman NP, Price DL. The cerebral syndromes associated with dissecting aneurysm of the aorta: a clinicopathological study. *Brain*. 1968;91:173-192.
3. Carrel T, Laske A, Jenny R, von Segesser L, Turina M. Neurological complications associated with acute aortic dissection: is there a place for a surgical approach? *Cerebrovasc Dis*. 1991;1:296-301.
4. Nienaber CA, Spielmann RP, von Kodolitsch Y, Siglow V, Piepho A, Jaup T, Nicolas V, Weber P, Triebel H-J, Bleifeld W. Diagnosis of thoracic aortic dissection: magnetic resonance imaging versus transesophageal echocardiography. *Circulation*. 1992;85:434-447.
5. Gerber O, Heyer EJ, Vieux U. Painless dissections of the aorta presenting as acute neurological syndromes. *Stroke*. 1986;17:644-647.
6. Waltimo O, Karli P. Aortic dissection and paraparesis. *Eur Neurol*. 1980;19:254-257.
7. Hirst AE, Johns VJ, Kime SW. Dissecting aneurysm of the aorta: a review of 505 cases. *Medicine*. 1958;37:217-279.
8. Steinke W, Schwartz A, Hennerici M. Doppler color flow imaging of common carotid artery dissection. *Neuroradiology*. 1990;32:502-505.
9. Dalen JE, Alpert JS, Cohn LH, Black H, Collins JJ. Dissection of the thoracic aorta: medical or surgical therapy? *Am J Cardiol*. 1974;34:803-807.
10. Goldman AP, Kotler MN, Scanlon MH, Ostrum B, Parameswaran R, Parry WR. The complementary role of magnetic resonance imaging, Doppler echocardiography, and computed tomography in the diagnosis of dissecting thoracic aneurysms. *Am Heart J*. 1986;111:970-981.
11. Erbel R, Mohr-Kahaly S, Oelert H, Rennollet H, Brunier A, Thelen M, Meyer J. Diagnosis strategies in suspected aortic dissection: comparison of computed tomography, aortography, and transesophageal echocardiography. *Am J Cardiac Imaging*. 1990;4:157-172.
12. Erbel R, Engberding R, Daniel W, Roelandt J, Visser C, Rennollet H. Echocardiography in diagnosis of aortic dissection. *Lancet*. 1989;1:457-461.
13. Treasure T, Raphael MJ. Investigation of suspected dissection of the thoracic aorta. *Lancet*. 1991;338:490-495.
14. Adachi H, Kyo S, Takamoto S, Kimura S, Yokote Y, Omoto R. Early diagnosis and surgical intervention of acute aortic dissection by transesophageal color flow mapping. *Circulation*. 1990;82(suppl 4):IV-19-IV-23.
15. Mohr-Kahaly S, Erbel R, Rennollet H, Wittlich N, Drexler M, Oelert H, Meyer J. Ambulatory follow-up of aortic dissection by transesophageal two-dimensional and color-coded Doppler echocardiography. *Circulation*. 1989;80:24-33.
16. Lee RJ, Bartzokis T, Yeoh T-K, Grogan HR, Choi D, Schnittger I. Enhanced detection of intracardiac sources of cerebral emboli by transesophageal echocardiography. *Stroke*. 1991;22:734-739.