

Embolic Stroke by Compression Maneuver During Transcranial Doppler Sonography

Nadja Khaffaf, MD; Ronald Karnik, MD; Walther-Benedikt Winkler, MD;
Andreas Valentin, MD; Jörg Slany, MD

Background and Purpose Embolic complications during ultrasound examinations are a rare cause of neurological deficits. The present case documents the occurrence of embolism by a nonobstructive compression maneuver during transcranial Doppler examination, resulting in a minor stroke.

Case Description A 63-year-old man suffered from recurrent transient ischemic attacks. Duplex sonography showed a small echogenic plaque at the right carotid bifurcation. During transcranial Doppler studies with a reverberating compression maneuver of the right common carotid artery low in the neck,

multiple emboli signals were detected, and the patient developed a left-sided hemiparesis with slurred speech. Funduscopy revealed cholesterol emboli in the inferior temporal arteriole of the right eye. These findings suggested embolization as the cause of the stroke.

Conclusions Compression maneuvers should not be performed in patients with recent neurological symptoms, even in the case of only small lesions in the extracranial carotid territory. (*Stroke*. 1994;25:1056-1057.)

Key Words • Doppler • embolism • ultrasonics

Compression tests in the region of the extracranial carotid system are an integrated component of transcranial Doppler sonography (TCD).¹⁻³ Embolic complications during ultrasound examinations are a rare cause of neurological deficits.⁴ However, a few cases of cerebral embolism after carotid sinus pressure have been reported.^{5,6} The present case documents the occurrence of embolism by a compression maneuver during TCD examination, resulting in stroke in a 63-year-old male patient.

Case Report

A 63-year-old man suffered for 1 month from recurrent transient ischemic attacks (TIAs) with left-sided hemiparesis. The patient had a history of coronary heart disease, long-standing cigarette smoking, mild hypercholesterolemia, insulin-dependent diabetes mellitus, and hypertension. Neurological examination on admission revealed no pathological findings. Duplex sonography showed the extracranial carotid system to be free of arteriosclerotic lesions except for a small echogenic plaque at the right carotid bifurcation (Fig 1). Subsequently TCD studies were performed using the transtemporal approach. Frequency spectra with a low mean blood flow velocity of 35 cm/s were detected at a depth of 55 to 65 mm on the right side. Reverberating compression maneuvers of the right common carotid artery were performed to discriminate the right middle cerebral artery from the posterior cerebral artery. During these compression maneuvers multiple emboli signals appeared on the scope (Fig 2). Immediately after the high-frequency signals were detected, the patient

developed a left-sided hemiparesis and speech impairment. Funduscopy examination performed 24 hours later showed asymptomatic retinal cholesterol emboli in the inferior temporal arteriole. Cerebral angiographic studies confirmed the duplex sonographic findings, demonstrating a small plaque in the region of the right carotid bifurcation. The other parts of the extracerebral and intracerebral carotid system appeared free of arteriosclerotic lesions.

The patient was treated conservatively with platelet antiaggregants. He recovered nearly completely within 2 weeks and showed only a slight weakness of the left arm at the time of discharge.

Discussion

Cholesterol emboli, dislodged by a reverberating compression maneuver of the common carotid artery, resulted in a minor stroke in this patient. In our neurosonographic laboratory such compression tests are performed only in selected patients with very complex hemodynamic flow patterns or when discrimination of certain basal cerebral arteries is not possible. Compression tests are always carried out by an experienced physician according to the recommendation of Aaslid¹: nonobstructive reverberating compression of the common carotid artery low in the neck after duplex examination has shown the site of compression to be free of arteriosclerotic plaques. Despite these precautionary measures, vibrating compression led to the dispersion of cholesterol emboli obviously originating from the small plaque at the bifurcation. This is the first example of cerebral embolism resulting from compression of the common carotid artery proved by TCD. Spencer et al³ showed that microemboli dislodged during carotid endarterectomy are detected reliably by TCD. Transient signals with a high amplitude (up to 10 dB greater than the background Doppler signal) and a relatively narrow spectrum, occurring randomly during the cardiac cycle, are characteristic of emboli. To the ear, signals indicat-

Received November 3, 1993; final revision received January 17, 1994; accepted January 20, 1994.

From the Second Department of Medicine, Krankenhaus Rudolfstiftung, Vienna, Austria.

Correspondence to Nadja Khaffaf, MD, Second Department of Medicine, Krankenhaus Rudolfstiftung, Juchgasse 25, A-1030 Vienna, Austria.

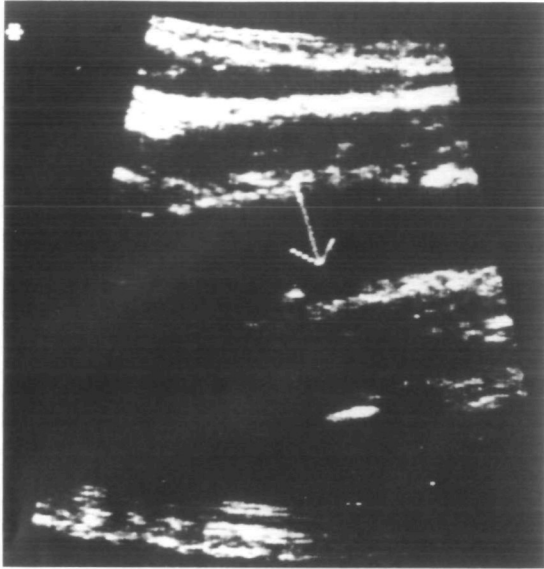


FIG 1. Duplex sonographic evaluation of the right carotid bifurcation demonstrating a small echogenic plaque with a possible ulceration (arrow).

ing emboli are harmonic in tone, with a chirping or whistling quality. This acoustic quality enables an experienced investigator to differentiate clearly between emboli signals and artifacts.

Fundusoscopic examination 24 hours after the acute event suggested that stroke in this patient had been caused by cholesterol emboli. We found characteristic yellow fragments in the right inferior temporal arteriole, whereas the retinal arteries of the left eye appeared free of cholesterol crystals. In 1961 Hollenhorst⁷ first described orange-, yellow-, and copper-colored fragments seen at retinal arteriolar bifurcations and suggested that these were cholesterol crystals rising from ulcerated arteriosclerotic lesions of cardiac valves, aorta, or the carotid arteries. In 1963 David et al⁸ found doubly refractile cholesterol crystals in the eye of a patient with a fatal ipsilateral cerebral infarct after undergoing surgical exploration of the ipsilateral carotid artery; it was elected, however, not to open the artery because of

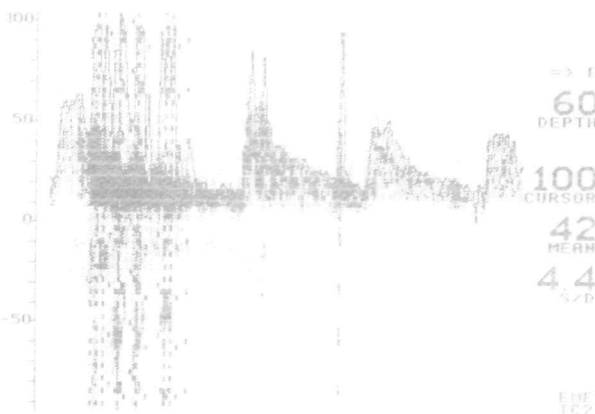


FIG 2. Transcranial Doppler frequency spectra of the right middle cerebral artery showing a shower of microemboli passing through the vessel.

normal blood flow measurements. Histochemical and optical characteristics of the material were identical to those found in the patient's atheroma of the carotid artery and of the embolus of the middle cerebral artery. The retinal cholesterol emboli in our patient were considered to be asymptomatic because ocular symptoms such as monocular visual loss and monocular visual field loss on examination were not detected. This is in accordance with the findings of Bruno et al,⁹ who described 70 cases of asymptomatic retinal cholesterol emboli associated with hypertension, cigarette smoking, and the presence of heterogeneous or echolucent carotid plaque on ultrasound.

In 1981 Beal et al⁵ reported the first case of cerebral atheromatous embolism after carotid sinus pressure. A 79-year-old man had experienced paroxysmal atrial tachycardia, which was converted to sinus rhythm by firm compression of the left carotid sinus for approximately 4 seconds. One minute after sinus massage he developed a right hemiparesis and slurred speech. He died of sepsis 2 weeks after the ictus. Neuropathologic examination showed typical atheromatous material in the middle cerebral artery containing an abundance of cholesterol clefts. In this case the firm compression maneuver led to the fatal stroke. Friedman⁴ described two cases of TIAs resulting from carotid duplex scanning. Both patients suffered recurrent TIAs during the weeks before undergoing ultrasound examination. They experienced brief TIAs, identical to those experienced previously, under manipulation of the ultrasound transducer, which was applied with the usual pressure. During surgery, deep ulcers with fresh thrombus over the surface were detected at the carotid bifurcations of these patients.

In conclusion, our case and the two cases of Friedman suggest that ulcerated lesions in patients with recurrent TIAs are potentially unstable and that manipulation of an ultrasound transducer or compression maneuvers might precipitate embolization from a friable ulcer. In these cases reverberating maneuvers are probably more dangerous than a gently performed obstructive manual compression lasting several seconds.

References

1. Aaslid R. Transcranial Doppler examination techniques. In: Aaslid R, ed. *Transcranial Doppler Sonography*. New York, NY: Springer-Verlag New York, Inc; 1986:39-59.
2. Arnolds BJ, von Reutern G-M. Transcranial Doppler sonography: examination technique and normal reference values. *Ultrasound Med Biol*. 1986;12:115-120.
3. Spencer MP, Thomas GI, Nicholls SC, Sauvage LR. Detection of middle cerebral artery emboli during carotid endarterectomy using transcranial Doppler ultrasonography. *Stroke*. 1990;21:415-423.
4. Friedman SG. Transient ischemic attacks resulting from carotid duplex imaging. *Surgery*. 1990;107:153-155.
5. Beal MF, Park TS, Fisher M. Cerebral atheromatous embolism following carotid sinus pressure. *Arch Neurol*. 1981;38:310-312.
6. Bastulli JA, Orłowski JP. Stroke as a complication of carotid sinus massage. *Crit Care Med*. 1985;13:869.
7. Hollenhorst RW. Significance of bright plaques in the retinal arterioles. *JAMA*. 1961;178:23-29.
8. David NJ, Klintworth GK, Friedberg SJ, Dillon M. Fatal atheromatous cerebral embolism associated with bright plaques in the retinal arterioles. *Neurology*. 1963;13:708-713.
9. Bruno A, Russell PW, Jones WL, Austin JK, Weinstein ES, Steel SR. Concomitants of asymptomatic retinal cholesterol emboli. *Stroke*. 1992;23:900-902.