

Case report

Paraballism associated with anterior opercular syndrome: a case report

A. Nicolai*, L.G. Lazzarino

Divisione Neurologica, Ospedale Civile di Gorizia, Via Brigata Treviso 8/L, 34070 Gorizia (Piedimonte), Italy

Received 16 July 1993; revised 30 September 1993; accepted 30 September 1993

Abstract

We describe the combination of acute bilateral ballism and anterior opercular syndrome in a 75-year-old female hypertensive patient with bilateral multiple small infarcts involving the basal ganglia, the subcortical white matter and the area of the subthalamic nucleus, detected by CT scan and MRI. These clinical manifestations were accompanied by apathy, somnolence and cognitive changes usually observed in cortical involvement. Pathogenetic mechanisms for this unusual clinical picture are discussed on the basis of CT, MRI, and SPECT findings.

Key words: Paraballism; Ballism; Anterior opercular syndrome; Pseudobulbar palsy

1. Introduction

Hemichorea-hemiballism (HH) is characterized by continuous, irregular, and throwing involuntary movements involving one side of the body, usually due to deep infarcts in the contralateral subthalamic region, in the basal ganglia or in the thalamus [1–7]. The generalized form, also called bilateral ballism or paraballism (PB) is a rare disturbance sometimes described as a consequence of multiple and bilateral lesions in the same location [8,9]. The acute anterior opercular syndrome (AOS), or labio-glosso-pharyngo-laryngo-facial paralysis is usually caused by bilateral lesions in the opercular cortex [10–12]; rare cases arising from single cortical [13] or subcortical ischemic lesions [14], or from multiple deep infarcts, have also been described [15].

We report the case of a patient with the acute onset of an unusual combination of paraballism and opercular syndrome, associated with multiple, bilateral subcortical infarcts.

2. Case report

A 75-year-old woman was admitted because of sudden onset of involuntary movements in both upper and lower limbs, accompanied by sudden development of dysphagia, dysarthria, and mild weakness on the left side. She had a history of mild arterial hypertension of 5 years duration. Her relatives had noted a progressive worsening of retentive memory during the last 2 years, but denied any other disturbance. On admission, blood pressure was 220/120 mm Hg and in subsequent records the average values of diastolic pressure exceeded 115 mm Hg. Antihypertensive treatment was started (ACE inhibitors and diuretics), with improvement of blood pressure. The patient was apathetic and lethargic, but when aroused, showed continuous, coarse, flinging movements in all extremities. The movements involved the proximal muscles of shoulders, arms, pelvis, and thighs including abduction, adduction, internal, and external rotation of the arms, extension of the forearms, abduction, and internal rotation of the thighs. These movements could not be suppressed voluntarily and disappeared during sleep. Tendon reflexes were asymmetric, brisker on the left, with flexor plantar responses; slight left-sided weakness was also observed. Funduscopy showed typical hypertensive abnormalities with straightening of arterioles and segmental narrowing of arterioles. She was almost

*Corresponding author.

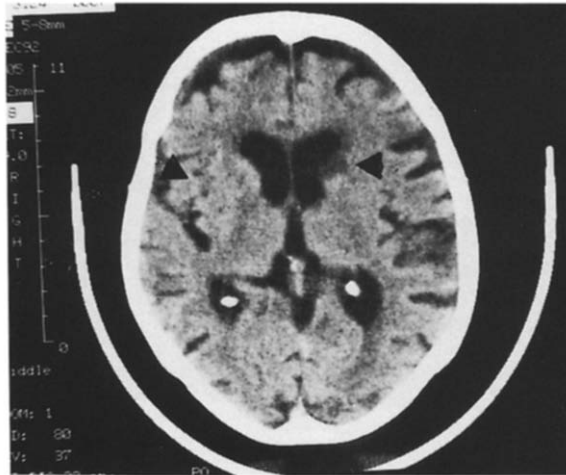


Fig. 1. Unenhanced CT scan showing multiple subcortical infarcts involving the basal ganglia and the subcortical white matter (arrow on the left). A more recent infarct in the head of the left caudate nucleus (arrow on the right) and marked frontal atrophy are also evident.

totally anarthric, aphonic and could not swallow. The soft palate drooped bilaterally, the gag reflex was absent and tongue movements were slowed with impaired protrusion. Abulia persisted for about 2 days, then the patient gradually became more alert and within a week she regained near-normal consciousness, although lack of interest in doing anything and long periods of drowsiness persisted. Speech output could not be examined because of aphonia and articulatory difficulty, while the assessment of comprehension, performed by the Token test, showed no abnormalities [16]. Other neuropsychological functions, evaluated by using the items proposed by Biasiach et al. [17] revealed disorders of attention and of retentive verbal memory. The EEG showed diffuse slow waves, particularly over the left hemisphere. Extracranial Doppler ultrasound was unremarkable. A unenhanced CT scan performed ten days after admission demonstrated multiple bilateral small infarcts in the basal ganglia, including the head of the caudate nucleus on the left side (Fig. 1). A ^{99}Tc -HMPAO SPECT of the brain performed 3 months after onset demonstrated relatively decreased uptake of the tracer in the left and right fronto-parieto-temporal regions, and in the basal ganglia. At that time a brain MRI confirmed the presence of multiple and bilateral deep infarcts in the putamen, globus pallidus, caudate nucleus, thalamus, claustrum, external capsule, and in the area of the subthalamic nucleus of Luys (Fig. 2).

3. Discussion

Clinical studies [1–3,6,7] and animal experiments [18] suggest that ballism arises from disruption of inhibitory pallido-subthalamic and pallido-thalamic pathways. These involuntary movements can also result from le-

sions of other deep structures such as putamen, caudate nucleus, and parts of the thalamus, following either damage to these structures themselves or interruption of their neuronal circuits, even in absence of changes in the subthalamic nucleus; regardless of lesion location, infarction and hemorrhage is the most common pathology [1–9].

The patient reported showed the unusual association of PB with AOS. PB is a rare syndrome the neuro-anatomic basis of which is not completely known [8,9]. Hoogstraten et al. [8] reviewed 12 cases of paraballism and concluded that the common denominator in the majority of cases was more or less extensive bilateral damage of the basal ganglia including, though not preferentially, the subthalamic nucleus. Dewey et al. [9] in their study of 21 patients with unilateral or bilateral ballism confirmed the variable anatomic location of the lesions, since only 5 of these patients had a lesion in the region of the subthalamic nucleus of Luys [9].

AOS is characterized by labio-glosso-pharyngo-laryngo-facial paralysis with automatic-voluntary dissociation and is classically ascribed to the direct and bilateral involvement of the opercular cerebral cortex [10,12]. In our patient as well as in other cases [15] the acute onset of pseudobulbar palsy may be explained by the effects of a recent infarct disrupting cortico-nuclear pathways in a patient in whom multiple cortico-nuclear interruptions were already present, due to previous bilateral infarcts in the basal ganglia. Inbody and Jankovic [19] coined the term 'hyperkinetic mutism' to designate the association of bilateral ballism and mutism. Their patient also showed altered consciousness with disorders of attention, and the etiology was at least in part due to bilateral parieto-occipital watershed infarcts. The hyperkinetic movements were presumed to be secondary to the combination of watershed infarcts and prior ischemia to the striatum. Hesselink et al. [20] described a patient with bilateral ballism and severe anarthria associated with CT

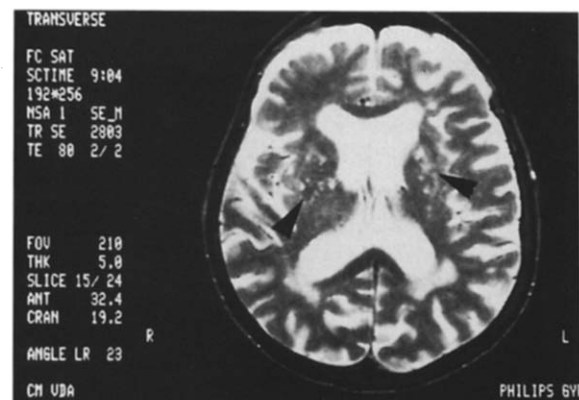


Fig. 2. T2-weighted (TR 2803, TE 80) performed three months after onset, revealing multiple bilateral ischemic lesions in the basal ganglia, thalamus, claustrum, external capsule, subcortical white matter, and in the area of the subthalamic nucleus.

evidence of an ischemic lesion of the head of the left caudate nucleus. The authors suggested that the clinical manifestations were secondary to several small infarcts, though not detected by CT-scan. In our patient, the multiple small ischemic lesions in the basal ganglia, thalamus, and subcortical white matter as revealed by CT and MRI (Figs. 1 and 2) probably produced AOS as well as parballism. The patient also showed cognitive and behavioral disturbances usually considered the result of cortical involvement. The basal ganglia are connected by several cortico-basal ganglia-thalamo-cortical loops involving the associative frontal, parietal, and temporal cortices [21–23]. It is likely that disruption of cortical connections, of deep gray nuclei, or of the surrounding tissue may cause distance effects in the form of reduced metabolic activity on the functionally connected cortex producing the neuropsychological disorders. In our patient, SPECT examination showed bilateral hypometabolism of anterior cortical areas which would be consistent with this hypothesis.

References

- [1] Adams, R.D. and Victor, M. (1985) *Principles of Neurology*, McGraw-Hill, New York.
- [2] Whittier, J.R. (1947) Ballism and the subthalamic nucleus (nucleus hypothalamicus corpus Luysii). *Arch. Neurol. Psychiat.*, 58: 672–692.
- [3] Carpenter, M.B. (1955) Ballism associated with partial destruction of the subthalamic nucleus of Luys. *Neurology*, 479–489.
- [4] Martin, J.P. (1957) Hemichorea (hemiballism) without lesions in the corpus Luysii. *Brain*, 80: 1–10.
- [5] Kase, C.S., Mulsby, G.O., de Juan, E. and Mohr, J.P. (1981) Hemichorea-hemiballism and lacunar infarction in the basal ganglia. *Neurology*, 31: 452–455.
- [6] Buruma, O.J.S. and Lakke, J.P.W.F. (1986) Ballism. In: Vinken, P.J., Bruyn, G.W. and Klawans, H.L. (Eds.), *Handbook of Clinical Neurology*, rev. series, vol. 5, Elsevier, Amsterdam, pp. 368–380.
- [7] Dewey, R.B. and Jankovic, J. (1989) Hemiballism-hemichorea. Clinical and pharmacological findings in 21 patients. *Arch. Neurol.*, 46: 862–867.
- [8] Hoogstraten, M.C., Lakke, J.B.W.F. and Zwarts, M.J. (1986) Bilateral ballism: a rare syndrome. Review of the literature and presentation of a case. *J. Neurol.*, 233: 25–29.
- [9] Orgogozo, J.M. and Bogousslavsky, J. (1989) Lacunar syndromes. In: Vinken, P.J., Bruyn, G.W. and Klawans, A.L. (Eds.), *Handbook of Clinical Neurology*, rev. series, vol. 54, Part II, Elsevier, Amsterdam, pp. 235–269.
- [10] Foix, C., Chavany, J.A. and Marie, J. (1926) Diplégie facio-linguomasticatrice d'origine cortico-sous corticale sans paralysie des membres. *Rev. Neurol.*, 33: 214–219.
- [11] Bruyn, G.W. and Gathier, J.C. (1969) The operculum syndrome. In: Vinken, P.J. and Bruyn, G.W. (Eds.), *Handbook of Clinical Neurology*, Elsevier, Amsterdam, pp. 776–783.
- [12] Mariani, C., Spinnler, H., Sterzi, R. and Vallar, G. (1980) Bilateral perisylvian softenings: bilateral anterior opercular syndrome (Foix-Chavany-Marie syndrome). *J. Neurol.*, 223: 269–284.
- [13] Rebusci, G.G., Gambetti, P. and Bottazzi, G. (1964) Le syndrome unilatéral de l'opercule rolandique. A propos de trois observations cliniques. *Acta Neurol. Belg.*, 64: 1267–1268.
- [14] Posteraro, L., Pezzoni, F., Varalda, M., Fugazza, G. and Mazzucchi, A. (1991) A case of unilateral opercular syndrome associated with a subcortical lesion. *J. Neurol.*, 238: 337–339.
- [15] Besson, G., Bogousslavsky, J., Regli, F. and Maeder, P. (1991) Acute pseudobulbar or suprabulbar palsy. *Arch. Neurol.*, 48: 501–507.
- [16] De Renzi, E. and Faglioni, P. (1978) Normative data and screening power of a shortened version of the Token test. *Cortex*, 14: 41–49.
- [17] Bisiach, E., Cappa, S. and Vallar, G. (1983) Guida all'esame neuropsicologico. Cortina, Milan.
- [18] Hammond, C., Feger, J., Bioulac, B. and Souteyrand, J.P. (1979) Experimental hemiballism in the monkey produced by unilateral kainic acid lesion in the corpus Luysii. *Brain Res.*, 171: 577–580.
- [19] Inbody, S. and Jankovic, J. (1986) Hyperkinetic mutism: bilateral ballism and basal ganglia calcification. *Neurology*, 36: 825–827.
- [20] Hesselink, J.M.K., van Gijn, J. and Verwey, J.C. (1987) Hyperkinetic mutism. *Neurology*, 37: 1566.
- [21] Marsden, C.D. (1984) Function of the basal ganglia as revealed by cognitive and motor disorders in Parkinson's disease. *Can. J. Neurol. Sci.*, 11: 129–135.
- [22] Oberg, R.G.E. and Divac, I. (1979) 'Cognitive functions' of the neostriatum. In: Divac, I. and Oberg, R.G.E. (Eds.), *The Neostriatum*, Pergamon Press, Oxford, pp. 291–313.
- [23] Caplan, L.R., Schmahmann, J.D., Kase, C.S., Feldmann, E., Baquis, G., Greenberg, J.P., Gorelick, P.B., Helgason, C. and Hier, D.B. (1990) Caudate infarcts. *Arch. Neurol.*, 47: 133–143.