

---

# Acute Carotid Artery Thrombosis After Neck Irradiation

Rob Reed, MD, Shahzad Sadiq, MD

---

Over the past several decades radiation therapy has become an important modality in the treatment of numerous malignant diseases. Although its benefits and efficacy are undeniable, tumor irradiation has significant side effects that must be considered. These include central nervous system damage, myelosuppression, gastrointestinal toxicity, skin changes, and pneumonitis. Most of these changes are mediated by small vessel damage and occlusion. Larger vessels also can be affected, and several case reports in the literature describe delayed arterial occlusive disease or embolic disease involving the aorta and the carotid, subclavian, and iliac arteries (Table 1). Nearly all of these cases occurred years after completion of the radiation therapy. The most acute cases reported occurred between 6 months and 3 years after completion of therapy. In this case report we describe acute left carotid arterial thrombosis causing neurologic symptoms that occurred during the course of radiation treatment for Hodgkin's disease.

## ABBREVIATIONS

CT, Computed tomography; PTT, Partial thromboplastin time; PT, Prothrombin time; WBC, White blood cells

## CASE REPORT

The patient, a 60 year old woman, developed left cervical lymphadenopathy in October 1991. She was diagnosed as having Hodgkin's disease and underwent staging laparotomy and splenectomy in November 1991. Radiation therapy via a standard anteroposterior and posteroanterior mantle port was performed in 20 fractions over 32 days with 6 MV photons. The total dose to the left neck was 4680 rad. On December 30, 1991, the patient developed sudden onset of right facial droop and right hemiparesis. Laboratory values on admission were as follows: PTT, 23.5 sec; PT, 12.9 sec; WBC, 8100 per cu mm; hemoglobin, 12.9 g/dl; hematocrit, 38.5 ml/dl; platelets, 463 per cu mm. The initial CT scan of the brain was negative. Duplex and color Doppler ultrasonography of the carotid arteries revealed soft thrombus in the left internal carotid artery with a tail (Fig. 1). The patient underwent anticoagulation therapy with gradual resolution of the neurologic symptoms. A second CT scan of the brain on January 4, 1992 revealed ischemic changes in the distribution of the left middle cerebral artery. A second sonogram of the carotid arteries on January 27, 1992, demonstrated complete resolution of the intraluminal thrombus with no evidence of significant underlying atherosclerotic disease (Fig. 2). The patient also had a normal echocardiogram. Given the history of recent irradiation to the neck and the absence of significant atherosclerosis within the left carotid artery, this case suggests an acute radiation-induced thrombosis of the left common carotid artery with embolism to the middle cerebral artery.

## DISCUSSION

Radiation effects on biologic tissues have been studied extensively. In 1899, only 4 years after the discovery of x-rays, Gassman described radiation-induced

---

Received December 21, 1993, from the Department of Radiology, St. Joseph Mercy Hospital, Pontiac, Michigan. Revised manuscript accepted for publication April 6, 1994.

Address correspondence and reprint requests to S. Sadiq, MD, Dept. of Radiology, St. Joseph Mercy Hospital, 900 N. Woodward, Pontiac, MI 48341.

**Table 1: Comparison of Radiation-related Vascular Complications**

Author(s)	Type of Neoplasm or Disease	Anatomic site	Time Interval*
Glick <sup>2</sup>	Vocal cord	Carotid arteries (bilateral)	16 years
Hayward <sup>3</sup>	Thyroid	Left carotid artery	27 years
Kearsley and Tattersall <sup>4</sup>	Vocal cord	Right carotid artery	17 years
	Breast	Right carotid artery	11.5 years
Levinson et al <sup>5</sup>	Larynx	Left carotid artery	25 years
	Parotid	Right carotid artery	34 years
	Hyperthyroidism	Right carotid artery	32 years
Osgood et al <sup>6</sup>	Nasopharynx	Right carotid artery	15 years
Peters et al <sup>7</sup>	Breast	Right subclavian artery	19 years
	Breast	Left axillary artery	
	Breast	Left subclavian artery	36 years
	Hodgkin's disease	Left anterior descending artery	
	Uterus	Iliac-femoral arteries	7 years
	Cervix	Left femoral artery	1 year
	Cervix	Iliac arteries (bilateral)	3 years
Call et al <sup>10</sup>	Hodgkin's disease	Left carotid artery	2.5 years
	Hodgkin's disease	Left carotid artery	2.5 years
	Rhabdomyosarcoma	Right carotid artery	2 years
Conomy and Kellermeyer <sup>11</sup>	Hodgkin's disease	Left carotid artery	8 months
Kagan et al <sup>12</sup>	Hodgkin's disease	Multifocal	6 months

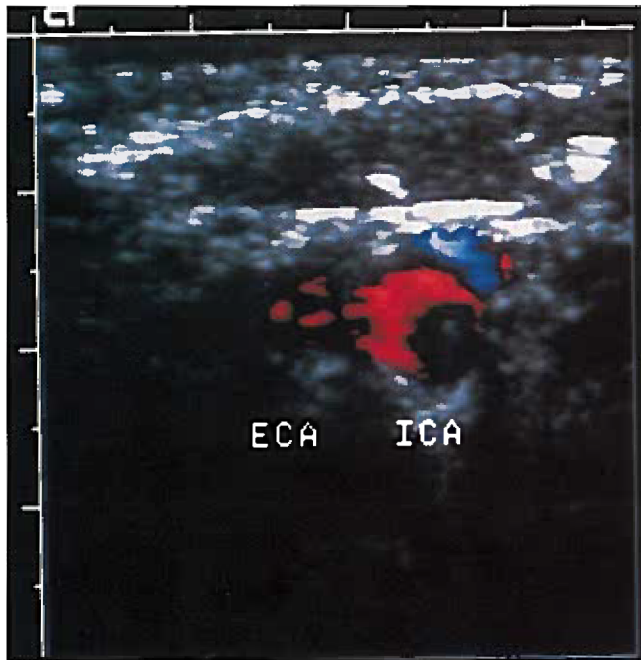
\*Interval between cessation of therapy and onset of symptoms.

vascular changes consisting of intimal thickening and vacuolization with medial changes.<sup>1</sup> Further work by Fajardo and Berthrong<sup>1</sup> and others characterized the vascular damage caused by radiation. The endothelial cell is injured initially and subsequently undergoes intimal damage. This is followed by formation of mural thrombus and myointimal proliferation. The most sensitive segments are the smallest arterioles and capillaries, and occlusion of these vascular channels is an important precipitating factor in radiation damage of the skin, lung, kidneys, heart, gastrointestinal tract, and the central nervous system. Larger arteries are affected less commonly because of their strong supporting walls and large lumen diameter.

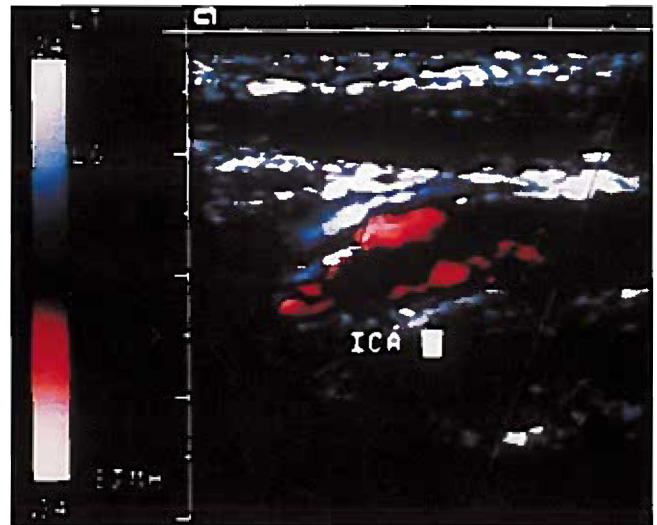
The majority of the reported cases in the literature are of delayed large artery stenosis or occlusion occurring years after completion of radiation thera-

py.<sup>2-7</sup> The pathogenesis of delayed vascular occlusion is thought to be accelerated atherosclerotic disease at the site of arterial wall damage. The histologic changes that occur were well documented in animal models by Gold<sup>8</sup> and Kirkpatrick.<sup>9</sup> Several other authors report vascular complications occurring between 6 months and 3 years after radiation therapy.<sup>7,10,11,12</sup> In the majority of these instances, as in our case, thrombotic occlusion occurred in an irradiated segment of the vascular system that was free of significant underlying atherosclerotic disease.

The biologic effects of radiation and the potential complications of brachytherapy are well known. Radiation-induced disease affects the smallest segments of the vascular system, resulting in endothelial damage and thrombotic occlusion. The endothelium of larger arteries is affected similarly. However, because of the larger lumen and stiffer walls, clinical

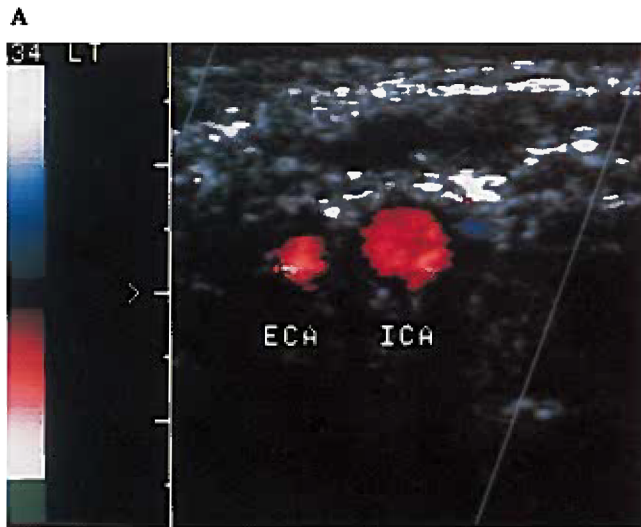


A



B

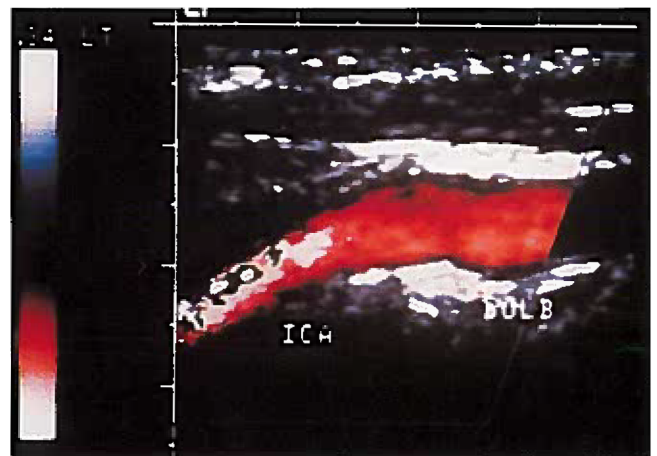
Figure 1 Transverse (A) and longitudinal (B) color Doppler sonograms of the left internal carotid artery obtained on December 31, 1991. The images demonstrate intraluminal thrombus with a freely moving tail located within the proximal internal carotid artery.



A

Figure 2 Transverse (A) and longitudinal (B) color Doppler sonograms of the left internal carotid artery obtained on January, 27, 1992. Complete resolution of the intraluminal thrombus has occurred, and there is no evidence of underlying atherosclerotic disease.

B



signs and symptoms often are delayed by months or years and are mediated by accelerated atherosclerosis. The case presented here is an exception to this rule in that acute large artery thrombosis occurred in the absence of significant atherosclerotic change in a patient with a normal coagulation profile. The presence of neurologic or ischemic symptoms in a patient who is undergoing or has previously had radiation therapy should initiate the appropriate diagnostic tests so that therapy can be started without delay.

#### REFERENCES

1. Fajardo LF, Berthrong M: Vascular lesions following radiation. *Pathol Annu* 23:297, 1988
2. Glick B: Bilateral carotid occlusive disease following irradiation for carcinoma of the vocal cords. *Arch Pathol* 93:352, 1972
3. Hayward RH: Arteriosclerosis produced by radiation. *Surg Clin North Am* 52:359, 1972
4. Kearsely JH, Tattersall MHN: Cerebral embolism in cancer patients. *Q J Medi* 203:279, 1982
5. Levinson SA, Close MB, Ehrenfeld WK, et al: Carotid artery occlusive disease following external cervical irradiation. *Arch Surg* 107:395, 1973
6. Osgood CP, Karumaratre ER, Sandler R, et al: Carotid occlusion in a 27 year old man: A case report. *Neurosurgery* 18:459, 1986
7. Peters WR, Schlicke CP, Schmutz DD: Peripheral vascular disease following radiation therapy. *Am Surg* 45:700, 1979
8. Gold H: Production of Atherosclerosis in the Rat. *Arch Pathol* 71:268, 1961
9. Kirkpatrick JB: Pathogenesis of foam cell lesions in irradiated arteries. *Am J Path* 50:291, 1967
10. Call GK, Bray PF, Smoker WR, et al: Carotid thrombosis following neck irradiation. *Int J Radiat Oncol* 18:635, 1990
11. Conomy JP, Kellermeyer RW: Delayed cerebrovascular consequences of therapeutic radiation. *Cancer* 36:1702, 1975
12. Kagan AR, Bruce DW, diChiro G: Fatal foam cell arteritis of the brain after irradiation for Hodgkin's disease-angiography and pathology. *Stroke* 2:232, 1971
13. Silverberg GD, Britt RH, Goffinet DR: Radiation induced carotid artery disease. *Cancer* 41:130, 1978