



Case Report

Neonatal tuberous sclerosis presenting with intractable seizures

Paola Lago ^a, MD, Clementina Boniver ^b, MD, Gian Luca Casara ^b, MD,
Anna Maria Laverda ^b, MD, Angela Fiore ^a, MD, Sabrina Salvadori ^c, MD,
Carla Carollo ^d, MD, Onofrio Sergio Saia ^a, MD

A 2-day old girl with status epilepticus, unresponsive to maximum pharmacological intervention, is reported. Findings of brain and cardiac lesions pointed to the diagnosis of tuberous sclerosis. One of the brain lesions was unusually large, occupying most of the right temporo-parietal lobe.

Key words: Tuberous sclerosis, neonatal; Status epilepticus; Neonatal seizure, intractable; Cardiac rhabdomyom

1. INTRODUCTION

When diagnosed in the neonatal period, tuberous sclerosis (TS) is characterized by either neonatal seizures due to brain lesions or, more often, by signs of congestive heart failure or arrhythmia due to accompanying cardiac rhabdomyomas [1].

This case report describes a newborn girl who presented unresponsive status epilepticus at the age of 2 days and was diagnosed as having TS by bedside ultrasonography showing multiple brain tubers and cardiac tumors.

2. CASE REPORT

A female infant weighing 3,430 g was delivered after 39 weeks gestation to a healthy 30 year-old primigravida. Family history was unremarkable. The entire course of pregnancy had been uneventful. The Apgar

scores were 8 at 1 min and 10 at 5 min. At 2 days of age she was admitted to our NICU with clonic jerks of the mouth, chin, left arm and eyes, cardiac arrhythmia, and hematuria. An abdominal mass was palpated and there were no other remarkable findings on physical examination. Brain ultrasound revealed two hyperechogenic areas in the right parietal cortical and subcortical regions and in the left thalamus. At 5 days of age, CT disclosed a large, high-density, round lesion, with no contrast enhancement over the right temporo-parietal lobe, while no abnormalities were evident in the left hemisphere. MRI obtained at 3 weeks of age showed a large area of hyperintense signal on T₁-weighted sequences, which was much more intense in the subcortical region, with gyral anomaly and widening of the subarachnoid space. There was also evidence of a second area of increased signal in the left corona radiata, with extension to the basal ganglia (Fig. 1). Both lesions showed a hypointense signal on T₂-weighted image. A 2D echocardiogram showed two hyperechogenic mass lesions confined to the free wall of the left ventricle and to the muscular part of the septum. These findings were compatible with cardiac rhabdomyoma, causing dysrhythmia but no hemodynamic disturbance. Grade I atrioventricular block was evident on EKG.

The findings of brain and cardiac lesions pointed to a diagnosis of TS. No retinal, renal or liver involvement was detected [1,2]. Hypomelanotic macules were not found using ultraviolet light. A left adrenal hemorrhage was evident on renal ultrasound examination. During

Division of ^a Neonatology, ^b Neurology and ^c Cardiology, Department of Pediatrics, and ^d Department of Neuroradiology, University of Padova, Padova, Italy

Received 28 September 1993; accepted 20 February 1994

Correspondence address: P. Lago, MD, Department of Pediatrics, University of Padova School of Medicine, Division of Neonatology, Via Giustiniani 3, 35128 Padova, Italy. Fax: (39) (49) 821 3502.

hospitalization, the child was hemodynamically stable, and required no vasoactive drugs.

The clinical picture was dominated by intractable seizures, which persisted despite treatment with various anti-epileptic drugs. Neurophysiological monitoring included repeated EEG tracings and continuous cerebral function monitoring (CFM). During clinical seizures EEG showed right Rolandic rhythmic discharge of sharp waves, spikes and complex waves, while interictal tracings were characterized by multifocal abnormalities, more evident in the right hemisphere, and brief sequences of α -like activity. The CFM tracings showed the 'saw-tooth' pattern characteristic of repeated seizure activity.

The patient was first treated with phenobarbital 20 mg/kg loading dose, followed by 6 mg/kg once a day. Despite a serum phenobarbital level above the therapeutic range (215 mmol/l) the seizures could not be controlled. Several anti-epileptic drugs were tried: intravenous phenytoin (loading dose 18 mg/kg, followed by 7 mg/kg t.i.d. until therapeutic range, 84 μ mol/l, was obtained), repeated intravenous diazepam 0.5 mg/kg boluses, intravenous lidocaine (loading dose 2 mg/kg, followed by 6 mg/kg/h infusion), valproic acid (60 mg/kg t.i.d.) and vigabatrin 100 mg/kg t.i.d. per os. Barbiturate coma (BC) induced with pentobarbital sodium 3 mg/kg bolus i.v. as a loading dose, followed by 5-9 mg/kg/h drip infusion was attempted at 2

weeks of age, resulting in partial control of the electrical discharges in the brain. Attempts to wean the infant from the BC after 5 days, 1 week and 2 weeks failed, as critical activity reappeared as soon as the infusion rate of pentobarbital sodium was reduced.

The child died of cardiorespiratory arrest at 1 month of age. The postmortem examination confirmed the presence of cerebral tubers, cardiac rhabdomyomas and adrenal hemorrhage.

3. DISCUSSION

Tuberous sclerosis is a neurocutaneous syndrome transmitted through a dominant gene, with variable expression and penetrance. A high incidence (50%) of new mutations is reported [1-3]. In this case, the genetic work-up performed in the parents and their siblings was negative, suggesting a new genetic mutation.

In neonatal TS, multiple cardiac rhabdomyomas are classically present and a spontaneous involution of these tumors has quite often been observed at an early age [4].

Macroscopic hematuria associated with adrenal hemorrhage has occasionally been reported in newborn infants [5]. Renal function was always normal in our patient, and hematuria, possibly due to compression of

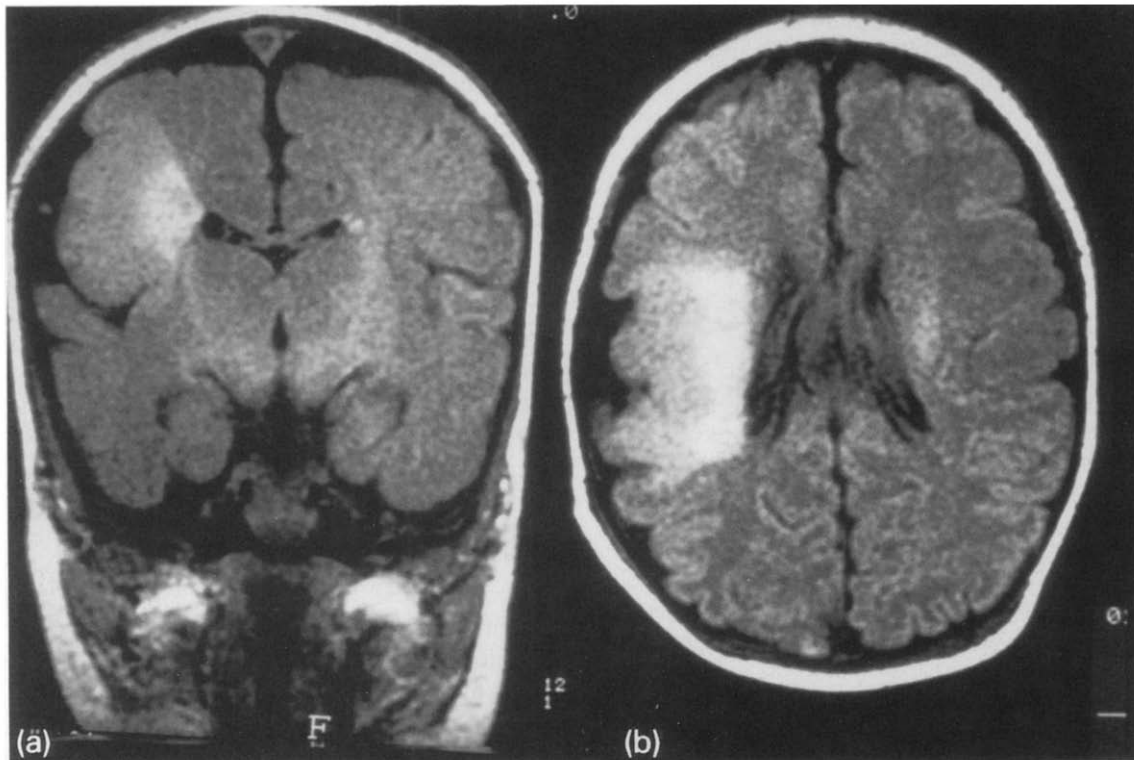


Fig. 1. MRI T₁-weighted image, on coronal (a) and axial (b) view: a large area of increased signal is more evident in the deep white matter of the right temporo-parietal region, with gyral anomaly and widening of the subarachnoid space. Another small area of increased signal is evident in the paraventricular left parietal region.

the renal vein (pseudothrombosis), recovered within a few days.

The clinical presentation of TS in the newborn is very variable [6-8]. At the onset the most frequent symptoms are cardiac arrhythmia or heart failure, due to rhabdomyoma, while seizures are seen later. This case was unusual because it was dominated by a precocious status epilepticus which proved very difficult to control with drugs; a surgical approach was not considered because of the extension of the lesions.

REFERENCES

1. Gomez MR. *Tuberous sclerosis*. New York: Raven, 1979.
2. Bourneville DM. Sclerose tubereuse des circonvolution cerebrales: idiotie et epilepsie hemiplegique. *Arch Neurol (Paris)* 1880; **1**: 81-91.
3. Roch ES. Neurocutaneous syndromes. *Pediatr Clin North Am* 1992; **39**: 591-620.
4. Shiraishi H, Yanagisawa M, Kuramatsu T, et al. Cardiac tumor in a neonate with tuberous sclerosis: echocardiographic demonstration and magnetic resonance imaging. *Eur J Pediatr* 1988; **148**: 50-2.
5. Demi M, Salano F, Badocco R, et al. Macroscopic hematuria associated with neonatal adrenal hemorrhage. *Pediatria Medica e Chirurgica* 1985; **7**: 889-92.
6. Christophe C, Bartholome J, Blum D, et al. Neonatal tuberous sclerosis. US, CT and MRI diagnosis of brain and cardiac lesions. *Pediatr Radiol* 1989; **19**: 446-8.
7. Kingsley DPE, Kendall BE, Fitz CR, et al. Tuberous sclerosis: a clinicoradiological evaluation of 110 cases with particular reference to atypical presentation. *Neuroradiology* 1986; **28**: 38-46.
8. Hayashi Y, Yoshimura K, Nakae Y, et al. Neonatal tuberous sclerosis with heart and brain tumors. *Acta Paediatr Jpn (Tokyo)* 1990; **32**: 571-4.