

Severe complications following thrombolytic therapy of an acute thrombosis of a prosthetic mitral valve

M.M. Hirschl¹, M. Gwechenberger², M. Zehetgruber², H. Weber²

¹ Abteilung für Notfallmedizin, Universität Wien, Währinger Gürtel 18–20, A-1090 Wien, Austria

² Klinik für Innere Medizin II, Abteilung für Kardiologie, Universität Wien, Währinger Gürtel 18–20, A-1090 Wien, Austria

Received: 10 November 1993 / Returned: 16 December 1993 / Accepted: 7 February 1994

Abstract. Thrombosis of prosthetic cardiac valves is a rare but potentially lethal complication. As emergency surgical intervention of thrombotic prosthetic cardiac valves is correlated with high mortality, fibrinolytic therapy has been recently recommended as a therapy with high efficacy and no severe side effects. We report on a patient with thrombosis of a prosthetic mitral valve who developed severe embolic complications following the administration of the thrombolytic agent. On admission the patient showed signs of incipient cardiogenic shock. The diagnosis of thrombotic obstruction of the prosthetic mitral valve was confirmed by transesophageal echocardiography. The effective valve area was 0.41 cm². Pulmonary arterial blood pressure and wedge pressure were significantly elevated. A fibrinolytic therapy with recombinant tissue-type plasminogen activator according to the Neuhaus scheme was attempted. Within 60 min after start of treatment the effective valve area increased (1.41 cm²), and the pulmonary capillary wedge pressure decreased. However, peripheral and cerebral embolism occurred. Occlusion of the right brachial and right femoral artery was ascertained by Doppler ultrasound. Embolism into the right leg made an embolectomy with a Fogarty catheter necessary. Computed tomography revealed two lesions located in the occipital and left temporal area of the brain. Correlated with the lesions evaluated in computed tomography, right hemiplegia and complete aphasia was observed. The neurological status of the patient has only slightly improved to the present. To our knowledge no severe persistent neurological deficits following thrombolytic therapy have been reported. We therefore assume that the risk of severe neurologi-

cal complications is underestimated. It is suggested that fibrinolytic therapy is a reasonable alternative in severely compromised patients with thrombotic prosthetic cardiac valves, but the final value of this treatment cannot be ascertained due to the small number of patients and the underestimation of severe embolic complications.

Key words: Prosthetic heart valve – Thrombosis – Fibrinolysis – Embolism – Neurological deficits

Thrombosis of prosthetic cardiac valves is a rare but potentially lethal complication. Treatment of such emergencies is a matter of controversy in the published data [4, 13, 14]. Its classic treatment is surgery, associated with a high perioperative mortality rate, especially in critically ill patients [11]. Emergency operations of thrombotic prosthetic heart valves are associated with a mortality rate of 17.5–55% [2, 10, 11]. Due to the high perioperative mortality rate other authors have attempted fibrinolytic therapy in patients with thrombosis of prosthetic heart valves [1, 3–9, 12, 14, 15]. In addition to hemorrhagic complications, a major concern regarding fibrinolytic therapy for prosthetic valve thrombosis is embolization of thrombotic material. However, reported embolic events, either peripheral or cerebral, have always classified as minor and transient complications. In the case of cerebral embolism no persistent neurological deficits have been described. In contrast, we present a case report in which fibrinolytic therapy of a thrombotic prosthetic mitral valve resulted in a persistent severe neurological deficit due to cerebral embolism. This report presents our experience of this case and a review of the literature.

Case report

A 63-year-old woman underwent aortic and mitral valve replacement with Carbomedics prothesis in

Abbreviations: PAP=pulmonary arterial pressure; PCWP=pulmonary capillary wedge pressure; rt-Pa=recombinant tissue-type plasminogen activator

Correspondence to: M.M. Hirschl

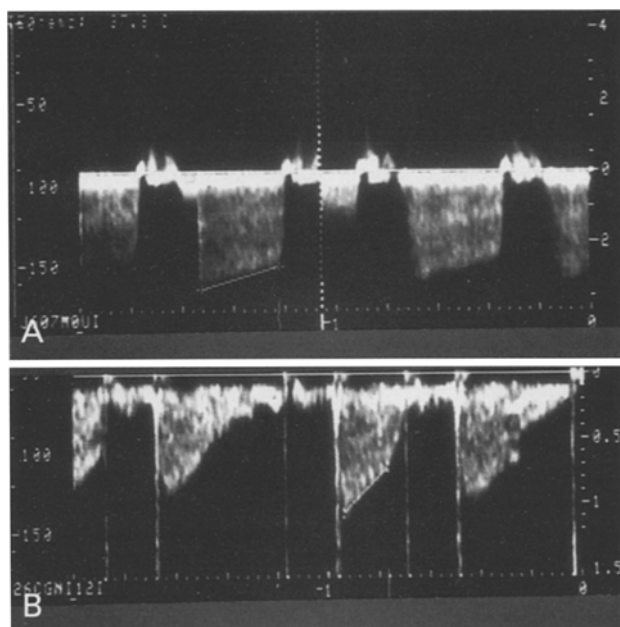


Fig. 1. Velocity flow profile of a thrombotic prosthetic mitral valve using a continuous wave Doppler analysis before (A) and after thrombolytic therapy (B)

1989. Four years later a permanent intracardial pacemaker was inserted due to a sick sinus syndrome. Postoperatively a hemothorax developed, and anticoagulation therapy was stopped for 24 h. Then the anticoagulation therapy with heparin was resumed. However, the patient developed the clinical signs of pulmonary edema and cardiogenic shock and was admitted to the intensive care unit. On admission her thrombin time was 75 s. Thrombotic occlusion of the mitral or aortic valve was suspected. Clinical diagnosis of a thrombotic mitral valve was confirmed by transthoracic and later by transesophageal echocardiography. The aortic valve showed no abnormalities. The Doppler examination revealed an abnormally high blood flow velocity and a pressure half time of 0.53 s. The effective valve area was 0.41 cm^2 (Fig. 1A). Because of the progressive respiratory failure the patient was sedated and intubated, and controlled respiration was established. In addition, cardiogenic shock was observed, with a systemic arterial blood pressure of 70/45 mmHg, and acute renal failure developed. Therefore, dobutamine ($10 \mu\text{g kg}^{-1} \text{ min}^{-1}$) and suprarenine ($1 \mu\text{g kg}^{-1} \text{ min}^{-1}$) were infused continuously. A Swan-Ganz catheter was inserted via the left subclavian vein. Pulmonary arterial pressure (PAP) was 56/47 mmHg, wedge pressure (PCWP) 45 mmHg, and cardiac output was 1.92 l/min. Because of the low output and the high risk of emergency surgery fibrinolytic therapy with recombi-

nant tissue-type plasminogen activator (rt-PA) was attempted.

According to the scheme published by Neuhaus et al. [17] a 15-mg rt-PA intravenous bolus was given, followed by intravenous infusion of 50-mg rt-PA over 30 min and a further 35 mg over the following 60 min. Within 60 min after the start of therapy the patient's general condition had improved markedly. PAP decreased to 26/21 mmHg and PCWP from 45 to 13 mmHg, and cardiac output increased from 1.92 l/min to 3.39 l/min. The level of catecholamines was reduced continuously. Echocardiographic examination revealed a decreased pressure half time of 0.15 s and a marked reduction in blood velocity across the mitral valve (Fig. 1B). The calculated mitral valve area increased to 1.41 cm^2 . However, no complete lysis of the thrombosis of the valve could be established. Therefore surgical intervention was planned for the next day. During fibrinolytic therapy peripheral and cerebral embolism was observed. Occlusion of the right brachial and right femoral artery was ascertained by Doppler ultrasound. In addition, cerebral embolism was suspected because a side difference in the pupils was observed. Computed tomography revealed two lesions located in the occipital and left temporal area of the brain. Embolism into the right leg made embolectomy with a Fogarty catheter necessary. However, postoperatively a compartment syndrome developed, and a fasciotomy of the right lower limb was performed.

After the end of sedation severe neurological deficits became obvious. A right hemiplegia and complete aphasia were observed. The neurological deficits correlated well with the results of the computed tomography. The postoperative course of the patient was complicated by sepsis with *Pseudomonas aeruginosa*; the focus of the sepsis was the fasciotomy wound of the right leg. The patient is still in the hospital 10 weeks after the operation. A slight improvement in her neurological status has been observed. The patient is now able to speak a few words, but the hemiplegia of the right side persists.

Discussion

Our case report demonstrates a severe and persistent neurological deficit due to cerebral embolism following fibrinolytic therapy of thrombotic obstruction of a prosthetic mitral valve. Reviewing the literature, we have found 82 additional cases in which fibrinolysis of left-sided thrombotic prosthetic heart valves has been attempted. The findings of recently published reports are summarized

Table 1. Data in 75 patients of left-sided prosthetic valve thrombosis after episodes of thrombolytic therapy

Authors	Patients/ Episodes	Position	Success	Surgery	Complications	Drug (dosage)
Witchitz et al. [19]	12/13	8 M/4A	complete 8 partial 2 failure 3	3 (3rd, 8th, 75th day)	hemopericardium 1, uterine bleeding 1, cerebral embolism 1	7 SK (bolus: 500.000 I.U. and 100.000 I.U./h over 12–96 h) 6 UK (bolus: 150.000 and 75.000–150.000 I.U. over 24–48 h)
Ledain et al. [8]	26/28	15 M/11A	complete 23, partial 3, failure 2	6	peripheral embolism 3, cerebral embolism 2	19 SK (bolus: 500.000 I.U. and 1.500.000 I.U. over 10 h) 9 UK (4.500 I.U./kg/h over 12 h)
Kurzrok et al. [7]	1/1	1 M	Complete	No	Splenic infarction	SK (bolus: 500000 IU and 100000 IU/h over 24 h)
Gagnon et al. [5]	1/1	1 M	Complete	No	No	SK (bolus: 250000 IU and 200000 IU/h over 48 h)
Wright [20]	1/1	1 M	Complete	No	subdural hematoma	SK (600000 IU/h over 72 h)
Page et al. [12]	3/3	2 M/1 A	Complete 3	Not mentioned	Peripheral embolism 2	2 UK (4500 IU/kg/h over 12 h) 1 UK + SK (4500 IU/kg/h over 12 h and 2000000 IU over the next 12 h)
Amann et al. [1]	1/1	1 M	Complete	No	Hematoma	SK (bolus: 100000 IU and 60000 IU over 48 h)
Lopez et al. [9]	7/10	7 M	Complete 10	4 (8th,15th, 19th day, 8 months)	Allergic reaction 2, retroperitoneal hematoma 1, cerebral hemorrhage 1	3 SK (bolus: 250000–1500000 IU and 100000IU/h over 22–64 h) 3 UK (bolus: 250.000–300.000 I.U. and 100.000 I.U./h over 13–70 h 4 rt-PA (100 mg in 90–180 min)
Ortuno et al. [11]	1/1	1 M	Complete	No	No	SK (3000000 IU over 45 h)
Silber et al. [17]	12/12	3 M/9 A	Complete 9, partial 1, failure 2	No	Severe ecchymoses 1, hemarthrosis 1, cerebral embolism 1, hematoma 1	2 SK (bolus 250000 IU and 100000 IU/h over 72 h) 8 UK (4.400 I.U./kg/h over 24 hour) 2 Heparin
Rabago et al. [16]	10/11	Not known	Complete 7, failure 4	4	Embolism 4	11 SK (average 2500000 IU over 16 h)

A, Aortic; M, mitral; SK, streptokinase; UK, urokinase

in Table 1. Complete success was accomplished in 82% and clinical improvement with partial success in 7%. In 11 of the 82 cases fibrinolytic therapy failed to resolve the thrombotic obstruction. Surgical intervention after fibrinolysis was necessary in 17 patients. Reoperation was successful in 14 (82%), and 3 (18%) patients died postoperatively. Hemorrhagic complications were retroperitoneal hematoma, hemopericardium, subdural hematoma, and cerebral hemorrhage. Embolic events were observed in 13 patients (5 peripheral, 4 cerebral, 4 not defined). One of the peripheral embolic events required embolectomy. None of the cerebral events caused persistent neurological deficits. The overall rate of complications was 33%. 47 (57%) cases were treated with streptokinase, 28 (34%) with urokinase, 4 (5%) with rt-PA, 2 (3%) with heparin, and 1 with combined urokinase and streptokinase. The duration of treatment ranged from

90 min to 96 h. However, no correlation between the used drug, the duration of administration, and the risk of embolization could be established. In view of the fact that 85 fibrinolytic attempts have been performed in left-sided obstructions, the number of arterial embolizations seems rather low. We have also compared the incidence of arterial embolizations with the number of embolic events after fibrinolytic therapy of thrombotic tricuspid valves. No events of pulmonary embolism have been reported in these patients [18–20]. However, the number of patients with thrombotic tricuspid valves treated with fibrinolytic agents is very small.

Due to this low rate of severe complications and the high perioperative mortality some authors have recommended fibrinolysis as the treatment of choice in thrombotic prosthetic heart valves [1, 7, 12]. We believe that an assessment of embolic complications is still not possible due to the small num-

ber of patients treated with fibrinolysis. Furthermore, the rate of severe complications seems underestimated in the recent literature.

As demonstrated by our case report, embolic complications with persistent neurological deficit may occur following thrombolysis. We therefore feel that patients in hemodynamically stable conditions should undergo surgical intervention without any delay after the diagnosis of prosthetic valve thrombosis. The mortality rate in these patients is about 8–12% [2, 10] and does not necessarily carry a high risk compared with elective valve surgery, provided the patient's condition is not unstable [4]. If anticoagulation therapy is inadequate prior to the thrombosis of prosthetic heart valve, and no life-threatening hemodynamic decompensation exists, a trial of therapeutic anticoagulation may be attempted to improve prosthetic valve hemodynamics, as demonstrated by Waksmonski et al. [13]. If the patient is hemodynamically compromised, an attempt should be made to stabilize the hemodynamic and respiratory situation under the conditions of an intensive care unit. However, if catecholamine therapy and/or controlled ventilatory support fail to stabilize the critically ill patient, an attempt with a fibrinolytic therapy should be made.

In conclusion, in our experience fibrinolytic therapy is not a treatment of choice for thrombotic prosthetic left-sided heart valves, but a reasonable alternative in severely compromised patients.

References

- Amann FW, Kiowski W, Pfisterer M, Burckhardt D (1986) Fibrinolytic therapy in thrombotic obstruction of a tilting disc prosthesis. *Am Heart J* 112:1084–1088
- Cambier P, Mombaerts P, De Geest H, Collen D, Van de Werf F (1987) Treatment of prosthetic tricuspid valve thrombosis with recombinant tissue-type plasminogen activator. *Eur Heart J* 8:906–909
- Cohen ML, Barzilai B, Gutierrez F, Jaffe AS, Eisenberg P (1990) Treatment of prosthetic tricuspid valve thrombosis with low-dose tissue plasminogen activator. *Am Heart J* 120:978–980
- Deviri E, Sareli P, Wisenbaugh T, Cronje SC (1991) Obstruction of mechanical heart valve prostheses clinical aspects and surgical management. *J Am Coll Cardiol* 17:646–650
- Gagnon RM, Beaudet R, Lemire J, Carignan L, Guimond C, Cousineau G (1984) Streptokinase thrombolysis of a chronically thrombosed mitral prosthetic valve. *Cath Cardiovasc Diagn* 10:5–7
- Kontos GJ, Schaff HV (1985) Thrombotic occlusion of a prosthetic heart valve: diagnosis and treatment. *Mayo Clin Proc* 60:118–122
- Kurzrok S, Singh AK, Most AS, Williams DO (1987) Thrombolytic therapy for prosthetic cardiac valve thrombosis. *J Am Coll Cardiol* 9:592–598
- Ledain LD, Ohayon JP, Colle JP, Lorient-Roudaut FM, Roudaut RP, Besse PM (1986) Acute thrombotic obstruction with disc valve prostheses: diagnostic considerations and fibrinolytic treatment. *J Am Coll Cardiol* 7:743–751
- Lopez FG, Mata GV, Toral AR, Bailon IR, Mondejar EF, Lasuen PA (1993) Thrombolytic treatment for massive thrombosis of prosthetic cardiac valves. *Intensive Care Med* 19:145–150
- Neuhaus KL, Feuerer W, Jeep-Tebbe S, Niederer W, Vogt A, Tebbe U (1989) Improved thrombolysis with a modified dose regimen of recombinant tissue-type plasminogen activator. *J Am Coll Cardiol* 14:1566–1569
- Ortuno F, Fontcuberta J, Pons-Llaurado G, Montserrat I, Cladellas M, Llobet JM, Grau E (1988) Successful treatment of prosthetic heart-valve thrombosis with high short-term doses of streptokinase. *Lancet* II:626 (letter)
- Page A, Gateau P, Roudant R, Lorient MF, Baudet E, Besse P (1980) Traitement thrombolytique dans les thromboses de prothese valvulaires. *Nouv Presse Med* 42:3186–3190
- Pansini S, Ottino G, Forsennati PG, Serpieri G, Zattera G, Casabona R, di Summa M, Villani M, Poletti GA, Morea M (1990) Reoperations on heart valve prostheses: an analysis of operative risks and late results. *Ann Thorac Surg* 50:590–596
- Pavie A, Bors V, Gandjbakhch I, Cabrol C (1984) Surgery of prosthetic valve thrombosis. *Eur Heart J* 5 [Suppl D]:39–42
- Peterffy A, Henze A, Savidge Gf, Landou C, Björk VO (1980) Late thrombotic malfunction of the Björk-Shiley tilting disc valve in the tricuspid position: principles for recognition and management. *Scand J Thorac Cardiovasc Surg* 14:33–41
- Rabago R, Corrales M, Rey M, Tunon J, Criado A, Zaragoza R, Rabago P (1993) Fibrinolytic therapy for prosthetic heart valve thrombosis. *Circulation* 88 [Suppl]:1-342
- Silber H, Khan SS, Matloff JM, Chauv A, DeRobertis M, Gray R (1993) The St.Jude valve, thrombolysis as the first line therapy for cardiac valve thrombosis. *Circulation* 87:30–37
- Waksmonski CA, Dye R, Riley M, Berman A (1990) Resolution of prosthetic valve stenosis (presumed thrombosis) without thrombolytic therapy or surgical intervention. *Am J Med* 89:539–540
- Witchitz S, Veyrat C, Moisson P, Scheinman N, Rozenstajn L (1980) Fibrinolytic treatment of thrombus on prosthetic heart valves. *Br Heart J* 44:545–554
- Wright JO, Hiratzke LF, Brandt B, Doty DB (1982) Thrombosis of the Björk-Shiley prosthesis: illustrative cases and review of the literature. *J Thorac Cardiovasc Surg* 84:138–144