

Cerebral network underlying unilateral motor neglect: evidence from positron emission tomography

Hans-Jürgen von Giesen, Gottfried Schlaug, Helmuth Steinmetz, Reiner Benecke,
Hans-Joachim Freund, Rüdiger J. Seitz *

Department of Neurology, Heinrich Heine University Düsseldorf, Moorenstraße 5, D-40225 Düsseldorf, Germany

Received 29 October 1993; revised 24 February 1994; accepted 2 March 1994

Abstract

In 4 male patients (age range 50–73 years) with unilateral motor hemineglect as a sequelae of circumscribed cerebral infarction, depressions of the regional cerebral glucose metabolism (rCMRGlu) were mapped to identify the metabolically affected cerebral structures. Motor neglect was defined according to Castaigne by lack of spontaneous and pain-induced motor activity on one side of the body in the absence of paresis, pyramidal signs, and sensory loss. The depressions of the rCMRGlu as determined by positron emission tomography (PET) were found to exceed the areas of structural damage but to be restricted to the affected cerebral hemisphere. Significant mean rCMRGlu depressions followed a focal pattern involving the premotor, prefrontal, parietal and cingulate cortex, as well as the thalamus. In correspondence to the lack of significant mean rCMRGlu depressions in primary sensorimotor cortex, basal ganglia, and cerebellum the cortico-spinal pathway was spared as indicated by preserved magnetic evoked motor potentials. Our data provide evidence suggesting that motor hemineglect is a disturbance in a cerebral network of higher order cortical areas subserving motor activity in the presence of an intact motor cortical output system.

Key words: Motor neglect; Cerebral glucose metabolism; Positron emission tomography; Evoked potentials; Motor network

1. Introduction

The neglect syndrome (Heilman 1985) is defined as a behavioral failure to report, respond, or orient to novel or meaningful stimuli presented to the body side contralateral to a brain lesion. This failure cannot be attributed to either sensory or motor defects. The neglect syndrome may affect different modalities appearing either as hemi-inattention, sensory extinction or motor neglect (akinesia, intentional neglect). Although often accompanied by multimodal neglect, pure motor neglect can be defined as a clinical entity (Castaigne et al. 1970, 1972). Neglect may be caused by lesions of the parietal (Critchley 1953; Castaigne et al. 1970) or frontal cortex (Castaigne et al. 1972) or by subcortical lesions that damage or functionally suppress a presumed subcortico-cortical network (Mesulam 1981). Recent SPECT studies (Bogousslavsky et al.

1988) or PET on hemineglect (Fiorelli et al. 1991) revealed a widespread depression of perfusion or metabolism involving the entire cerebral cortex ipsilateral to the lesion. The present PET study describes patients with motor neglect showing specific patterns of significant metabolic disturbances in the affected cerebral hemisphere. Thus, we were able to examine the hypothesis that interference with cortical higher order control areas may underlie motor hemineglect. Further, we ascertained by means of magnetic motor evoked potentials that the primary motor cortical output system was electrophysiologically intact in our patients. Our results substantiate the hypothesis of a distributed cerebral network outside the cortical motor strip subserving voluntary motor activity.

2. Patients and methods

Four patients were examined neurologically by three independent observers. The clinical findings are summarized in Table 1. Neurological examination was in particular directed to establish the degree of motor

* Corresponding author. Tel.: (+49-211) 311-8977; Fax: (+49-211) 311-8469.

impairment. Paresis was graded according to the quantitative scale by Demeurisse et al. (1980). Motor neglect was assessed by eight clinical criteria as established by Castaigne et al. (1970, 1972). These criteria were: (1) absence of paresis, (2) absence of muscle tone changes, (3) absence of pyramidal signs, (4) absence of spontaneous limb movements of the affected side, (5) limb movement of the affected side in response to tough encouragement, (6) absence of withdrawal of affected limbs out of uncomfortable positions, (7) normal sensation, (8) normal rapid alternating movements.

Sensory neglect was excluded by simultaneous cutaneous stimulation of homologous sites of both sides of the body (cancellation test), visual neglect by line bisection test (Albert 1973; Halsband et al. 1985).

Case reports

Case 1. J.Sc., a right-handed, 50-year-old clerk suffered two infarctions in the territory of the left medial cerebral artery following an angiographically proven occlusion of the left internal carotid artery. The first stroke led to an infarct of the left mid-frontal gyrus

with the full clinical picture of motor neglect as described in Table 1. All signs were completely reversible. The second stroke 6 weeks later led to a complete right-sided hemiplegia with only partial recovery for the right leg in spite of continuous therapy with heparin. PET scanning was performed shortly before the occurrence of the second stroke.

Case 2. J.Si., a right-handed, 73-year-old retired tram driver suffered a circumscribed hypertensive hemorrhage in the left anterior thalamus. He was on warfarin therapy since left-side femoro-cru-ral bypass surgery 3 years before. On admission the patient was drowsy and markedly disoriented. Neurological examination disclosed a right-sided loss of motor activity and amnesic aphasia. In addition, there was a severe motor neglect as specified in Table 1. In parallel with resorption of the hemorrhage the patient's state improved remarkably with complete recovery of motor function within 8 weeks. In contrast, a slight residual amnesic aphasic speech disturbance was still present at that time. PET scanning was performed 2 months after hemorrhage. There was additional evidence of mild sensory polyneuropathy due to diabetes mellitus.

Case 3. W.K., a right-handed, 66-year-old chemistry worker presented with a hypertensive and initially space-occupying hemorrhage involving the right thalamus and the posterior part of the internal capsule. Clinically, he showed left-sided homonymous hemianopia, hemihypesthesia and motor neglect (Table 1). In addition, there was

Table 1
Clinical presentation and electrophysiology of 4 male patients with motor neglect

Clinical presentation and electrophysiology of 4 male patients with motor neglect									
Case	Criteria of motor neglect (Castaigne et al. 1970; 1972)	Motricity Index (Demeurisse et al. 1980)	MEP (CMCT; amplitude)		SSEP (latency; amplitude)			EEG	
				(msec)	(mV)	(msec)	(μ V)		
1.	no paresis	upper limb	left FDI	6	4.4	not done			10/sec alpha activity (50 μ V) 4/sec theta focus in FP1, F3, F7, T3 and T5
	no muscle tone changes	100	right FDI	7	7.1				
	no pyramidal signs	lower limb	left TA	16	6.3				
	no spontaneous activity	100	right TA	17	4.2				
	no activity without enforcement	total	left deltoid	6	1.7				
		100	right deltoid	no answer					
	no withdrawal of limbs								
	no sensory disorders								
	no disturbance of rapid alternating movements								
2.	no muscle tone changes	upper limb	left FDI	5	3.8	left M	21.2	5.7	8–9/sec alpha activity (20 μ V) diffuse bihemispheric presence of theta waves, delta waves are seen in FP1, F3, C3, P3, O1 and accentuated in F7 T3 and T5
	no spontaneous activity	75	right FDI	5	5.0	right M	21.6	5.7	
	no activity without enforcement	lower limb	left TA	19	2.8	left T	47.6	0.7	
	no withdrawal of limbs	54	right TA	19	4.8	right T	47.6	0.7	
	no sensory disorders	total							
		65							
	no paresis	upper limb	left FDI	8	9.2	left M	21.6	0.5	
	no muscle tone changes	100	right FDI	8	7.0	right M	20.4	2.5	
	no pyramidal signs	lower limb	left TA	17	2.7	left T	no answer		
	no spontaneous activity	100	right TA	17	2.9	right T	43.6	0.5	
3.	no activity without enforcement	total	left biceps	7	1.8			generalized slowing with pre- dominant 6–7/sec theta activity (50 μ V) 2/sec delta focus in F8, T4, T6	
		100	right biceps	7	3.5				
			left rectus	13	1.8				
			right rectus	11	6.5				
	no paresis	upper limb	left FDI	7	8.1	left M	21.2		5.3
	no muscle tone changes	100	right FDI	7	8.2	right M	20.4		10.4
	no pyramidal signs	lower limb	left TA	18	3.5	left T	45.6		1.4
	no spontaneous activity	100	right TA	18	6.1	right T	43.6		5.8
	no activity without enforcement	total	left rectus	13	7.3				
		100	right rectus	13	3.8				
4.	no withdrawal of limbs		left deltoid	7	1.1				
	no disturbance of rapid alternating movements		right deltoid	5	5.0				

FDI: first dorsal interosseus muscle; TA: tibial anterior muscle; M: median nerve; T: tibial nerve.

visuomotor ataxia as described by Rondot et al. (1977), impaired memory with disorientation in time and space, and depressed mood. Within two months a good recovery of his general condition occurred. A two-year follow-up revealed a persistent hemihypesthesia on the left side of the body with deafferentation of the left arm and concomitant sensory hemineglect of the left leg, face and trunk. Also the left-sided homonymous hemianopia and visuomotor ataxia had persisted. At this stage PET scanning was performed.

Case 4. K.B., a right-handed, 57-year-old biological technical assistant developed an acute ischemic stroke of the right basal ganglia on the basis of an occlusive cerebral artery disease including a 90% stenosis of the right internal carotid artery and a 70–80% stenosis of the left internal carotid artery. Four weeks prior to admission, he had suffered a few right hemisphere transient ischemic attacks. As evident from MRI there was a further brain lesion in the right angular and superior parietal gyrus. There was a history of coronary and peripheral arterial disease, nicotine abuse and hypercholesterolemia. Neurological examination disclosed a severe left-sided loss of motor activity involving the face, arm and leg fulfilling seven criteria of motor neglect (Table 1). In addition, there was a slight reduction of pinprick sensation on the side of his body. PET scanning was performed three weeks after infarction of the basal ganglia when there was still a motor neglect for the left hand but no changes of muscle tone and no pyramidal signs. The further clinical course during the following weeks revealed a slight residual left-sided central hemiparesis including presence of pyramidal signs.

Electrophysiology

Motor evoked potentials (MEP) as indicators for the fastest conducting nerve fibers in the cortico-spinal tract (Hess et al. 1987) were elicited by transcranial magnetic stimulation of the brain with a Novamatrix 200 HP® (maximum output of 2.0 tesla). Capacitors were rapidly discharged through a standard flat circular coil (outer diameter 12 cm). Technical and methodological details have been given repeatedly (Barker et

al. 1985; Boyd et al. 1986; Benecke et al. 1988a,b; Maccabee et al. 1991). To obtain MEP of the upper extremities, the coil was positioned with its center over the vertex, to obtain MEP of the lower extremities, it was positioned 4 cm anteriorly (Meyer et al. 1991). Clockwise and anticlockwise coil currents were used to stimulate the right or left hemisphere, respectively. Stimulation strength was individually determined for every limb at 1.5 threshold level. Threshold level was defined as the stimulation strength which induced a visible MEP in at least 3 of 5 trials with the muscle examined at rest. During stimulation all patients were encouraged to perform a voluntary contraction of the examined muscle. Surface EMG recordings were taken from various muscles in all patients including the first dorsal interosseus (FDI) and tibial anterior (TA) muscles representing distal muscles of the upper and lower extremities and the deltoid (patients 1 and 4), rectus femoris muscle (patients 3 and 4) and the biceps brachii muscle (patient 3) all representing proximally located muscles. EMG signals were amplified using a Toennies Myograph II® with bandpass filtering between 20 and 3000 Hz. Data were collected and evaluated on an IBM-compatible PC using Autolab® data collecting programs. Maximum peak-to-peak amplitudes of compound muscle action potentials and minimum onset latencies were determined, five trials for each muscle were analyzed. Furthermore, the amplitudes were expressed as a percentage of the compound muscle action potential obtained after supramaximal electrical stimulation of the supplying nerve (maximal M wave) and compared to normal values (Benecke et al. 1988a).

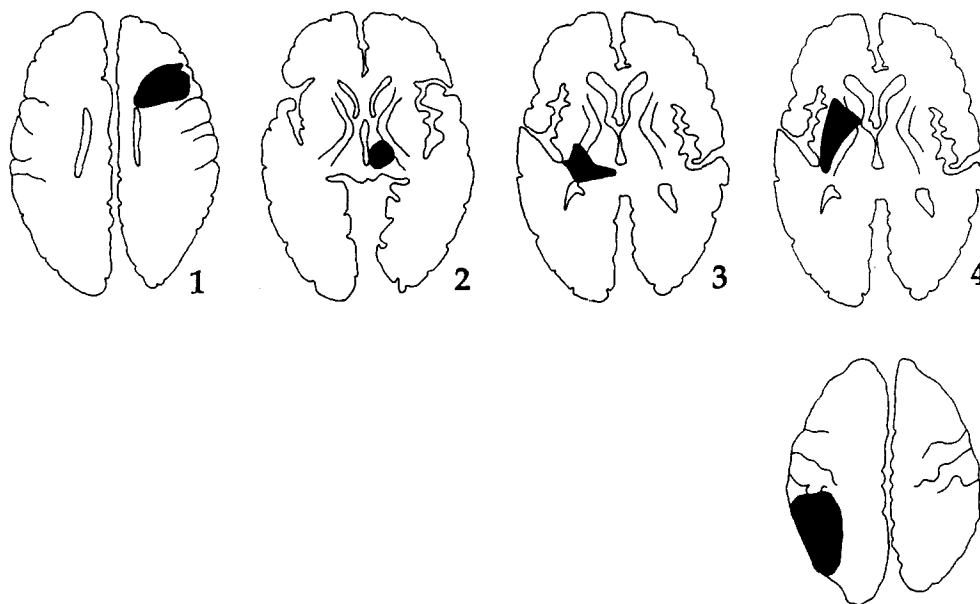


Fig. 1. Localization of structural defects in the 4 patients with motor neglect. Lesions were plotted on templates derived from the atlas of Matsui and Hirano (1978). Shown are the slices with the largest lesion extent. Left in the templates corresponds to right in the patients. The coordinates of the lesion centers in the stereotactic space of Talairach and Tournoux (1988) are $x = -36$, $y = 20$, $z = 24$ (case 1), $x = -14$, $y = 13$, $z = -7$ (case 2), $x = 18$, $y = -20$, $z = -6$ (case 3), $x = 24$, $y = -5$, $z = -8$ and $x = 45$, $y = -36$, $z = 44$ (case 4).

Central motor conduction time was calculated by subtracting the peripheral conduction time after nerve root stimulation from the onset latency of the fastest cortically evoked potential (Claus 1990; Hess et al. 1987).

Somatosensory evoked potentials (SSEP) were registered with a Medilec MS 92[®] registration unit after serial electrical stimulation of the median and tibial nerves (3 sweeps/sec just below motor threshold) in patients 1, 2 and 4. 200 responses were averaged for each registration, electrodes were positioned at Cz' for the tibial and at C3'/C4' for the median nerve, respectively. As detailed by Stöhr et al. (1983) base-to-peak amplitudes were calculated.

Electroencephalography (EEG) was registered routinely with a Mingograf[®] EEG 21 (Siemens) with an input impedance of 200 M Ω , 500 pF, symmetrical, and CMRR of 100 dB with AC suppressor. Scalp electrodes were placed following the international "10-20 system" (Jasper 1958).

Lesion topography

Lesions were localized initially by computed tomography (CT) with a Siemens Somatom Plus and subsequently by magnetic resonance imaging (MRI) with a 1.5 T Siemens Magnetom. Structural defects as visualized in T1-weighted MR images in the chronic stage were outlined and plotted on the corresponding templates from the anatomical atlas of Matsui and Hirano (1977). Lesions are depicted with their largest extent in Fig. 1. In addition, the spatial coordinates of the lesions were localized in the stereotactic space of Talairach and Tournoux (1988).

Positron emission tomography

For this PET study, 12 healthy volunteers (mean age 48 ± 14 yrs (SD)) served as controls. All controls denied any neurological, psychiatric or medical disorder and were normal on neurological and neuropsychological examination. All patients and controls were informed that the purpose of the study was to investigate the rCMRGlu pattern during resting wakefulness. None had undergone previous PET scanning. Written informed consent was obtained in accordance with guidelines approved by the Ethics Committee of the Heinrich Heine University Düsseldorf and the Declaration of Human Rights, Helsinki 1975.

PET scanning was performed with a Scanditronix PC 4096/7WB PET camera as described in detail previously (Seitz et al. 1994). In short, the subjects' were placed comfortably on the scanner bed and the gantry of the PET camera was aligned with the orbitomeatal line. There was no noise in the scanner room, speech was prohibited and the lights were dimmed. The subjects were asked not to move or speak, their eyes were open to prevent sleep. Prior to PET scanning, the subjects' left hand was warmed up to about

40°C for 45 min to ensure arterialization of blood in the dorsal hand veins with an oxygen saturation of more than 90%. After bolus injection of 200 MBq 2-[¹⁸F]fluoro-2-deoxy-D-glucose (FDG), 23 arterialized venous blood samples with an initial frequency of 6 per min were drawn to determine the arterial FDG input function. Calculation of the rCMRGlu was performed according to Phelps et al. (1979). The kinetic constants and the lumped constant of 0.52 were taken from Reivich et al. (1985). Image reconstruction was carried out with a Hanning filter of 5 mm (full width half maximum, FWHM) which provided an image resolution (FWHM) of 7.1 mm and an axial resolution (FWHM) of 6.5 mm (Rota Kops et al. 1990).

Image evaluation was done by use of the CBA on a SPX 3100/M76 VAX station. As described in detail earlier (Seitz et al. 1990) the brain atlas structures were adapted by translations, angulations, and linear and nonlinear scaling to fit the brain shape of each subject as presented in the PET and MR images. Thereafter, using these deformation parameters the individual parametric PET images were reformatted to the spatial orientation and standard shape of the atlas brain. Thus, a set of 14 spatially standardized parametric images was obtained for each of the different subjects. By this procedure, all stroke lesions were transposed into the left hemisphere. From these spatially standardized parametric PET images, mean images and corresponding images of the mean standard error (SEM) could be calculated pixel-by-pixel for our patients and control subjects. The differences of the mean rCMRGlu between the patients and controls were calculated pixel-by-pixel and their significance assessed from t-maps. Only mean rCMRGlu differences with a $t > 3.182$ (3 degrees of freedom, corresponding to $p < 0.05$; Sachs 1984) that occurred in clusters of at least 12 pixels were considered as reliable signals (Seitz et al. 1994). The mean rCMRGlu differences were localized to anatomical structures by interactive overlay of the anatomical structures retrieved from the data base of the computerized brain atlas (Greitz et al. 1991). Finally, the centers of gravity of the cortical and cerebellar ROIs as defined in the t-images were localized in the stereotactic space of Talairach and Tournoux (1988), as the spatial dimension and orientation of the computerized brain atlas were known (Seitz et al. 1990; Gulyas and Roland 1992).

3. Results

Table 1 shows that five to eight criteria of motor neglect as defined by Castaigne (1970, 1972) were present in our patients. Only one patient had a slight hemiparesis resulting in a mean motricity index of 91.3 ± 17.6 (SD) according to Demeurisse et al. (1980)

for all subjects. These data clearly support the diagnosis of motor neglect. Still, in case 3 there was an additional mild sensory neglect and a homonymous hemianopia to the right side. One patient presented with a slight amnesic aphasia (case 2).

Fig. 1 demonstrates the localization of the structural brain lesions in the 4 patients. It is evident that the lesions were confined to one hemisphere and circumscribed in all patients. One lesion was located in the left midfrontal gyrus, one in the anterior part of the left thalamus, one in the right thalamus extending into the posterior limb of the internal capsule, and one in the right lentiform nucleus. In the latter patient a further brain lesion was present in the right angular and superior parietal gyri. All lesions resulted from vascular events and were located at various sites known to possibly result in motor neglect (Heilman et al. 1983). However, patient 1 who fulfilled all criteria of motor neglect had a lesion in the left premotor cortex (Fig. 1).

Electrophysiological data

The details of the MEP are given in Table 1. In all patients, threshold levels were symmetrical both for upper and lower extremities, the absolute stimulation strength varying between 1.5 and 1.9 tesla for both the upper and lower extremities. MEP to distal muscles (FDI, TA) were normal on both sides with regard to central motor conduction time (CMCT), amplitude, and configuration of the evoked muscle potentials. With the exception of patient 1, where no answer to the contralateral deltoid muscle could be elicited, MEP to all other proximal muscles (deltoid, biceps brachii, rectus femoris muscles) showed normal CMCT in all patients with no relevant side differences. The evoked muscle action potential of the contralateral deltoid muscle was reduced in amplitude (1.1 vs 5.0 mV) and disperse in patient 4 (see Fig. 2). In patient 3, the evoked muscle potential of the rectus femoris muscle was slightly reduced in amplitude (1.8 vs 6.5 mV). MEP to the more distal muscles under study did not deviate

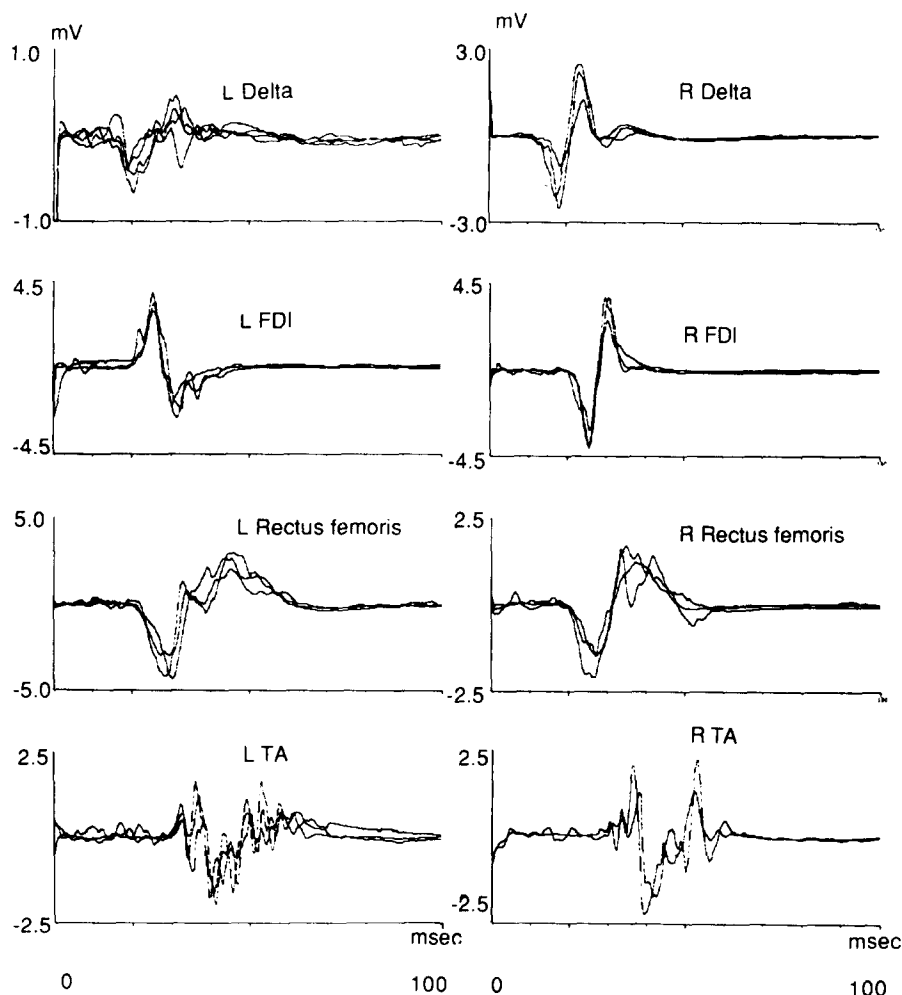


Fig. 2. Motor evoked potentials of patient 4 with bilaterally normal responses to distal muscles (first dorsal interosseus, tibialis anterior) and the proximal rectus femoris muscles with regard to central motor conduction time, amplitude and configuration. In contrast, MEP to the left deltoid as proximal muscle showed slight abnormalities with amplitude reduction and potential dispersion.

Table 2

Mean rCMRGlu depressions in 4 patients with motor neglect due to unilateral stroke

Antomical region (Greitz et al. 1991)	Functional Area (Roland 1987)	Stereotaxic Coordinates (Talairach and Tournoux 1988)	Mean rCMRGlu		Mean rCMRGlu of Controls \pm SD ($\mu\text{mol}/100\text{ g}/\text{min}$)
			depression (%)	(cm^3)	
G. precentralis	Motor hand area	$x = -37, y = -15, z = 49$	46	4.25	33.6 ± 7.1
G. postcentralis	Sensory hand area	$x = -36, y = -28, z = 48$	54	3.96	32.7 ± 6.9
G. frontalis medius	Premotor cortex	$x = -40, y = -7, z = 40$	50 *	5.84	35.7 ± 7.3
G. frontalis medius	Frontal eye field	$x = -26, y = 20, z = 48$	50 *	3.21	34.9 ± 6.9
G. front. inf. p. triang.	Broca's area	$x = -26, y = 19, z = 4$	51 *	6.56	34.1 ± 8.0
G. pariet. sup. lat.	Sup. parietal lobule	$x = -26, y = -48, z = 45$	49 *	3.78	35.7 ± 6.9
Precuneus	Sup. parietal medial	$x = -16, y = -58, z = 49$	51 *	8.14	35.1 ± 7.6
C. supramarginalis	Supramarginal	$x = -43, y = -37, z = 38$	54 *	2.51	32.0 ± 6.9
G. angularis	Angular	$x = -51, y = -59, z = 24$	51 *	19.32	34.2 ± 8.1
G. opercularis	Sec. somatosensory (SII)	$x = -42, y = -24, z = 18$	42 *	3.36	36.9 ± 8.0
G. temporalis sup.	Superior temporal	$x = -59, y = -15, z = 9$	48 *	3.59	35.9 ± 7.6
G. frontalis medius	Midfrontal anterior	$x = -28, y = 37, z = 6$	56 *	2.91	31.3 ± 6.6
G. front. inf. p. orbit.	Inferior prefrontal	$x = -40, y = 41, z = -4$	56 *	2.72	31.1 ± 6.6
G. cinguli	Cingulate gyrus	$x = -7, y = -6, z = 28$	36	5.67	28.2 ± 6.7
Thalamus	Thalamus	$x = -13, y = -21, z = 14$	52 *	5.85	33.4 ± 7.3
Putamen/Pallidus	Basal ganglia	$x = -22, y = -1, z = 6$	57	6.20	36.2 ± 7.9
Cerebellum	Cerebellar hemisphere	$x = 21, y = -63, z = 22$	41	5.79	31.6 ± 6.6

* Significant mean rCMRGlu depressions ($p < 0.001$, corrected for effective image resolution) were on the side of the stroke lesion. Mean rCMRGlu depressions were calculated as $(\text{rCMRGlu}_{\text{control}} - \text{rCMRGlu}_{\text{Neglect}}) \times 100 / \text{rCMRGlu}_{\text{Control}}$.

from normals in their amplitudes expressed as a percentage of the maximal M-waves (Benecke et al. 1988a). For comparison, in a previous study, in more than 30% of healthy subjects responses to the deltoid or vastus medialis muscles failed to appear (Benecke et al. 1988a). Thus, while MEPs to distal muscles were normal, MEPs to proximal muscles were only mildly but not significantly altered in our patients.

Somatosensory evoked potentials (SSEP) were recorded in 3 patients (Table 1). In case 1 no SSEP were recorded, since he did not show any impairment of sensation. Patient 2 showed symmetrical SSEP suggesting that the thalamic hemorrhage did not affect the ventral posterolateral nucleus. Bilateral latency prolongation from the tibial nerves was due to slight concomitant polyneuropathy. Patients 3 and 4 had prolonged latencies and diminished amplitudes from the affected leg or arm and leg corresponding to their clinical deficits (Table 1).

Electroencephalography (EEG) recordings revealed slow waves of the theta-band over both hemispheres (patients 2 and 3) and concomitant focal slowing predominantly over the frontal and temporal electrodes in all patients.

Metabolic data

In all patients PET revealed a widespread depression of rCMRGlu clearly exceeding the structural lesions. The mean CMRGlu for the whole brain ($17.8\text{ }\mu\text{mol}/100\text{ g}/\text{min}$; $p < 0.02$) was significantly reduced compared to the aged-matched controls due to a severe reduction in the affected hemisphere ($14.0\text{ }\mu\text{mol}/100\text{ g}/\text{min}$; $p < 0.02$) and a slight reduction in the contralateral hemisphere ($20.7\text{ }\mu\text{mol}/100\text{ g}/\text{min}$;

$p < 0.05$). Regional analysis showed that the depressions of the mean rCMRGlu were restricted to the cerebral hemisphere ipsilateral to the stroke lesions including the pre- and postcentral gyrus, the lentiform nucleus and the contralateral cerebellum (Table 2). While common areas were identified by t-map analysis (Fig. 3); the individual data showed a 35% reduction compared to the left side in the right primary visual and visual association cortex related to the left homonymous hemianopia and visual ataxia in case 3. Similarly, there was a 15% reduction of the rCMRGlu compared to the right side in the left parietal opercular region in case 2 who suffered from amnesic aphasia. The degree of the significant mean rCMRGlu depressions was in the range of 41 to 56% compared to the values in the healthy control subjects (Table 2). The structures involved included the medial and inferior frontal gyrus, the precuneus, the superior lateral parietal gyrus, the supramarginal and angular gyrus, the superior temporal gyrus, and the thalamus. The two largest areas of significant rCMRGlu depression were localized in the angular gyrus and the medial superior parietal cortex (precuneus). However, there were also large areas of rCMRGlu depressions in the premotor cortex and Broca's areas. There was also a pronounced mean rCMRGlu depression in the midportion of the cingulate gyrus, this, however, did not reach significance (Fig. 3).

4. Discussion

Since the early work by Hartmann (1907) and Liepmann (1908) and later by Critchley (1953) it is well

established that abnormal motor behavior in the absence of hemiparesis may be caused by circumscribed lesions of the cerebral cortex outside the primary sensorimotor cortex. Lesions in the parietal lobe have been related to apraxia, while lesions in the frontal lobe were related to disturbance of preparation, initiation and skillful execution of movement (reviewed by Freund 1987). Castaigne described a further clinical entity of abnormal motor behavior that he established as motor neglect (Castaigne et al. 1970, 1972). In strictly clinical terms he described motor neglect as “a motor disorder localized to the right or the left hemibody, consisting of paucity of movement without paralysis or hypertension, without sensory changes, asomatognosia or anosognosia” and defined eight criteria

including absence of pyramidal signs. According to our experience spontaneous withdrawal of affected limbs out of uncomfortable positions is lacking in motor neglect. However withdrawal to painful stimuli or movement in response to vigorous encouragement is usually preserved.

Although defined as clinical entity, underlying structural lesions were reported in various locations including the temporal, parietal, frontal and cingulate cortex as well as subcortically in thalamus and mesencephalic reticular formation (Castaigne et al. 1972; Watson et al. 1973, 1974, 1979, 1981; Damasio et al. 1980; Heilman et al. 1983; Laplane et al. 1986). Unlike our patients motor neglect is most often one aspect of a more generalized multimodal neglect or hemi-inatten-

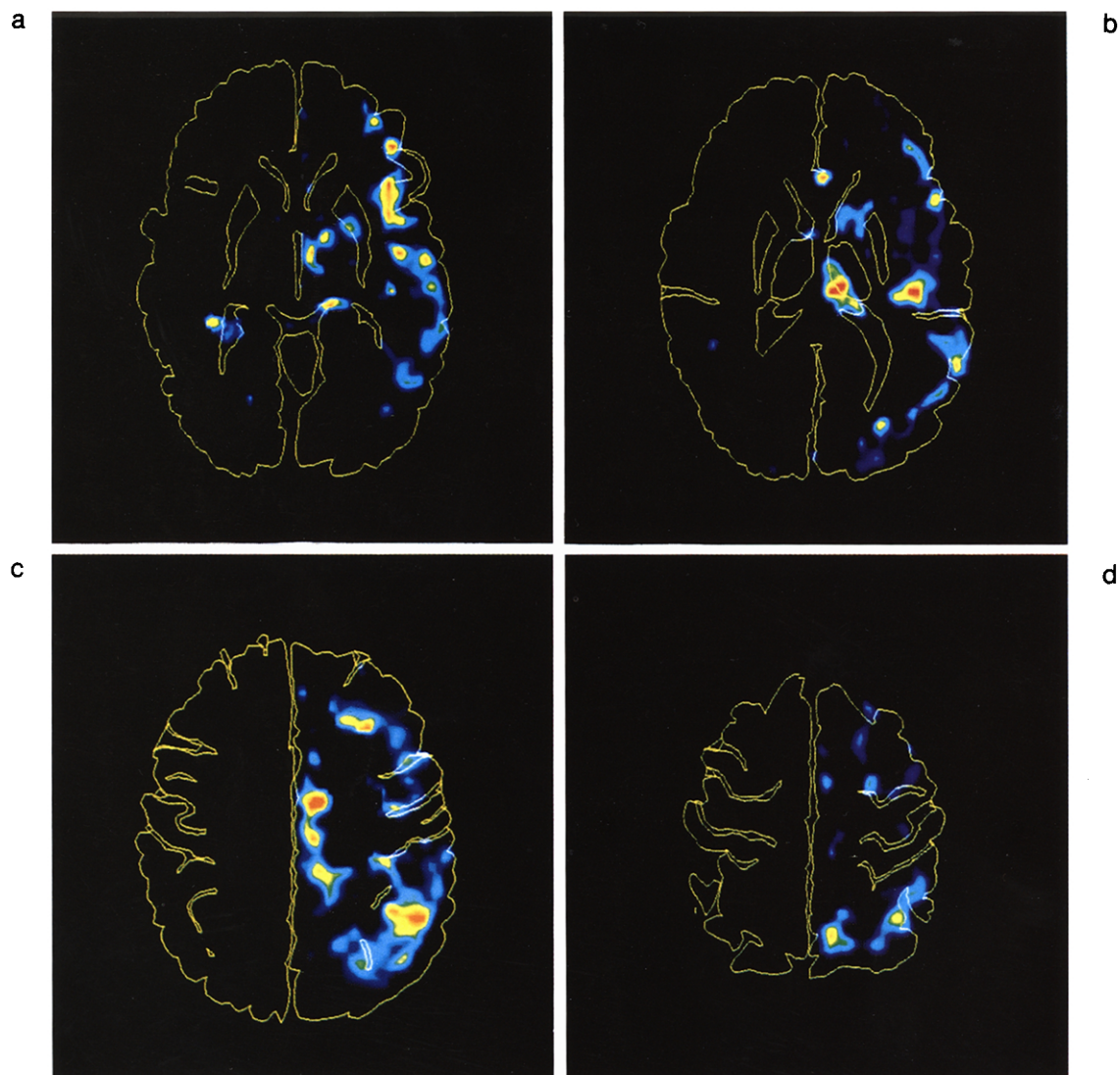


Fig. 3. Areas of significant mean rCMRGlu depression in the 4 patients with motor neglect compared to healthy controls. Only the depression in the cingulate gyrus did not reach significance. Over the t-maps the structures of the computerized brain atlas (Greitz et al. 1991) were superimposed. Besides the cerebral surface the cerebral structures shown are putamen, inferior frontal gyrus pars triangularis and lateral ventricles (a), putamen, thalamus, lateral ventricles, lateral sulcus (b), precentral, central, postcentral (c,d) and intraparietal (c) sulcus. Left in the images corresponds to the affected side.

tion in severe cerebral stroke (Coslett et al. 1993; Mesulam 1990).

The neurobehavioral discussion swings between views stating that neglect may result from a defect of intention (Watson et al. 1978) from an arousal-attention mechanism (Heilman and Valenstein 1972; Watson et al. 1973, 1977b; Halsband et al. 1985) or from a neural representation deficit inducing attentional disturbances as secondary phenomena with predominant damage to the right cerebral hemisphere (Bisiach and Vallar 1988; Laplane 1990; Rizzolatti and Berti 1990). In a more general conception, Mesulam (1990) proposed a disruption of a cortical network in hemineglect that is normally sustained in conscious awareness. This network is composed of local components including the parietal association cortex, a limbic component in the cingulate gyrus, a frontal component (premotor cortices including the frontal eye field) and a subcortical component attributed to the mesencephalic reticular formation, the ventrolateral thalamus and the intralaminar thalamic nuclei (Mesulam 1981, 1990; Laplane and Degos 1983). Lesions in only one component of this network yield partial unilateral neglect syndromes. Thus, the multiplicity of neglect-causing lesions does not result from a diffuse cerebral localization but, instead, reflects the existence of a highly organized and interconnected network subserving directed attention (Mesulam 1990). While the individual components allow for behavioral specialization such as sensory representational and motor exploratory function mediated primarily in the parietal lobe (Pause et al. 1989; Bisiach et al. 1990; Daffner et al. 1990; Liu et al. 1992), a separate role has been attributed to the anterior and posterior cingulate cortex, possibly reflecting a segregation between attentional and intentional neural mechanisms (Paillard et al. 1990).

Therefore, we wished to map anatomically the cerebral structures that were metabolically affected secondary to a circumscribed vascular lesion in patients who had suffered from motor neglect. The aim of this study was to examine, if this approach provides a means to identify those areas in the brain that subserve normal motor activity but are functionally impaired in motor neglect. It would, of course, be more elegant to demonstrate the functional impaired brain regions in a PET activation study. By definition however, voluntary movements of the affected limbs are not performed by patients suffering from motor neglect. Thus, our intention was to identify the brain areas with remote metabolic depressions. For the purpose of this study, the PET images of different subjects were spatially standardized and a statistical comparison to a group of healthy subjects was performed pixel-by-pixel. We provided evidence that the rCMRGlu was severely depressed in our patients throughout the cerebral hemisphere ipsilateral to the stroke lesion. This widespread

depression of the mean rCMRGlu resulted from the different locations of the structural brain lesions in the frontal and parietal cortex as well as in the basal ganglia and thalamus (Fig. 1). T-map analysis, however, demonstrated focal areas of significant mean rCMRGlu depression that were common for the examined cohort as discussed in detail elsewhere (Seitz et al. 1990, 1993). Thus, in spite of the different locations of the structural lesions in our patients, the areas of significant mean rCMRGlu depression indicated common abnormalities with small inter-subject variance among our patients.

We show that the areas of significant mean rCMRGlu depression included on the lesion side the medial and inferior frontal gyrus, the temporo-parietal region, the precuneus, the superior lateral parietal gyrus, the supramarginal and angular gyrus, the superior temporal gyrus, and the thalamus (Table 2). There was also a pronounced mean rCMRGlu depression in the cingulate gyrus, this was, however, not significant (Fig. 3). In contrast, no significant mean rCMRGlu depressions occurred in the primary structures of the motor output system such as the ipsilateral pre- and postcentral gyrus, the lentiform nucleus and the contralateral cerebellum. The hypometabolic anatomically defined areas in our study are thus almost identical to those theoretically discussed in the etiopathogenesis of motor neglect as outlined above. Since the rCMRGlu has been shown to be related to synaptic activity (Yarowsky et al. 1983; Kadakara et al. 1985) it can be assumed that the regions with significantly lower mean rCMRGlu represent areas with depressed neuronal activity. We can thus in vivo reliably demonstrate the existence of the proposed cortico-subcortical network (Mesulam 1990) and we can further demonstrate an ubiquitous depression of neuronal activity in all parts of the network once a damage to one single part occurred. Accordingly and as described earlier (Watson et al. 1977), electroencephalographic changes in our patients extended over the entire hemisphere with marked EEG slowing especially over the frontal and temporo-parietal lobes.

Our findings substantiate and extend earlier results by Fiorelli and co-workers (1991) who found a widespread hypometabolism only of the lesioned side sparing consistently the occipital lobe in predominant motor neglect. An important difference to our study are their findings of the inconsistent depression of metabolism in the thalamus and of the primary motor and sensory cortical areas at least in some of their patients. In accordance to measurements of glucose utilization in monkey with a frontal lobe neglect (Deuel et al. 1984) that revealed a hypometabolism in various parts of the thalamus, we interpret our finding as compatible with the above discussed cortico-subcortical network, especially as the mesencephalic reticular acti-

vating system probably projects to the cortex in a diffuse polysynaptic fashion (Scheibel and Scheibel 1967) and this projection may occur through the thalamus (Steriade and Glenn 1982). Further, in our 4 patients with motor neglect no dysfunction of the cortico-spinal tract could be detected by transcranial magnetic stimulation. Rather, normal CMCT to virtually all distal and proximal muscles under study proved the functional integrity of the motor cortical output system.

In conclusion, we interpret the rCMRglu depressions to represent remote effects that have repeatedly been demonstrated in patients with focal cerebral lesions (Feeney and Baron 1986), and assumed to underlie the neuropsychological impairment ensuing stroke (Baron et al. 1986). Evidence from systematic mapping studies suggests that these remote rCMRglu depressions are not unstructured or diffuse but circumscribed in relation to the structural stroke lesion (Heiss et al. 1992). The patterns of the remote rCMRglu depressions appear to result from deafferentation or/and retrograde degeneration due to structural nerve fiber damage thus being detectable for many years after stroke (Martin and Raichle 1983; Seitz et al. 1994). Our data indicate that interconnected cortical and subcortical areas subserving motor activity were affected simultaneously by the underlying stroke lesion. It is hypothesized that in motor neglect the intact motor cortical output system is deprived from sensory information and voluntary drive needed for movement execution.

Acknowledgement

This study was supported by the Sonderforschungsbereich 194 of the Deutsche Forschungsgemeinschaft.

References

- Albert, M.L. (1973) A simple test of visual neglect. *Neurology*, 23: 658–664.
- Barker, A.T., Jalinous, R. and Freeston, I.L. (1985) Non-invasive magnetic stimulation of the human motor cortex. *Lancet*, 1: 1106–1107.
- Baron, J.C., D'Antona, R., Pantano, P. et al. (1986) Effects of thalamic stroke on energy metabolism of the cerebral cortex. *Brain*, 109: 1243–1259.
- Benecke, R., Meyer, B.U., Göhmann, M. and Conrad, B. (1988a) Analysis of muscle responses elicited by transcranial stimulation of the cortico-spinal system in man. *Electroencephal. clin. Neurophysiol.*, 69: 412–422.
- Benecke, R., Meyer, B.U., Schönle, P. and Conrad, B. (1988b) Transcranial magnetic stimulation of the human brain: responses in muscles supplied by cranial nerves. *Exp. Brain Res.*, 71: 623–632.
- Bisiach, E. and Vallar, G. (1988) Hemineglect in humans. In: Boller, F. and Grafman, J. (Eds.), *Handbook of Neuropsychology*, Vol. 1, Elsevier, Amsterdam, pp. 195–222.
- Bisiach, E., Geminiani, G., Berti, A. and Rusconi, M.L. (1990) Perceptual and premotor factors of unilateral neglect. *Neurology*, 40: 1278–1281.
- Bogousslavsky, J., Miklossy, J., Regli, F. et al. (1988) Subcortical neglect: neuropsychological, SPECT and neuropathological correlations with anterior choroidal artery infarction. *Ann. Neurol.*, 23: 448–452.
- Boyd, S.G., Rothwell, J.C., Cowan, J.M.A. et al. (1986) A method of monitoring function in corticospinal pathways during scoliosis surgery with a note on motor conduction velocities. *J. Neurol. Neurosurg. Psychiat.*, 49: 251–257.
- Castaigne, P., Laplane, D., Degos, J.-D. (1970) Trois cas de négligence motrice par lésion rétrorolandique. *Rev. Neurol. Paris*, 122 (4): 233–242.
- Castaigne, P., Laplane, D., Degos, J.-D. (1972) Trois cas de négligence motrice par lésion frontale prérolandique. *Rev. Neurol. Paris*, 126: 5–15.
- Claus, D. (1990) Central motor conduction: Method and normal results. *Muscle Nerve*, 13: 1125–1132.
- Coslett, H.B., Schwartz, M.F., Goldberg, G. et al. (1993) Multi-modal hemispatial deficits after left hemisphere stroke. A disorder of attention? *Brain*, 116: 527–554.
- Critchley, M. (1953) *The Parietal Lobes*, Hafner, New York.
- Daffner, K.R., Ahern, G.L., Weintraub, S., Mesulam, M.-M. (1990) Dissociated neglect behavior following sequential strokes in the right hemisphere. *Ann. Neurol.*, 28: 97–101.
- Damasio, A.R., Damasio, H. and Chui, H.G. (1980) Neglect following damage to frontal lobe or basal ganglia. *Neuropsychologia*, 18: 123–131.
- Demeurisse, G., Demol, O. and Robaye, E. (1980) Motor evaluation in vascular hemiplegia. *Eur. Neurol.*, 19: 382–389.
- Deuel, R.K. and Collins, R.C. (1984) The functional anatomy of frontal lobe neglect in the monkey: behavioral and quantitative 2 deoxyglucose studies. *Ann. Neurol.*, 15: 521–529.
- Feeney, D.M. and Baron, J.C. (1986) Diaschisis. *Stroke*, 17: 817–830.
- Fiorelli, M., Blin, J., Bakchine, S. et al. (1991) PET studies of cortical diaschisis in patients with motor hemi-neglect. *J. Neurol. Sci.*, 104: 135–142.
- Freund, H.J. (1987) Abnormalities of motor behavior after cortical lesions in humans. In: *Handbook of Physiology, The Nervous System*, V, chapter 19, pp. 763–810.
- Greitz, T., Bohm, C., Holte, S. and Eriksson, L. (1991) A computerized brain atlas: construction, anatomical content, and some applications. *J. Comput. Assist. Tomogr.*, 15(1): 26–38.
- Gulyas, B. and Roland, P.E. (1991) Cortical fields participating in form and colour discrimination in the human brain. *NeuroReport*, 2: 585–588.
- Halsband, U., Gruhn, S. and Ettlinger, S. (1985) Unilateral spatial neglect and defective performance in one half of space. *Int. J. Neurosci.*, 28: 173–195.
- Hartmann, F. (1907) Beiträge zur Apraxielehre. *Monatsschr. Psychiat. Neurol.*, 2: 97–118 + 4: 248–270.
- Heilman, K.M. and Valenstein, E. (1972) Frontal lobe neglect in man. *Neurology*, 22: 660–664.
- Heilman, K.M., Valenstein, E. and Watson, R.T. (1983) Localization of neglect. In: Kertesz, A. (Ed.), *Localization in Neuropsychology*, Academic Press, New York, pp. 471–492.
- Heiss, W.-D., Huber, M., Fink, G.R., Herholz, K., Pietrzyk, U., Wagner, R. and Wienhard, K. (1992) Progressive derangement of perinfarct viable tissue in ischemic stroke. *J. Cereb. Blood Flow Metab.*, 12: 193–203.
- Hess, C.W., Mills, K.R. and Furray, N.M.F. (1987) Responses in small hand muscles from magnetic stimulation of the human brain. *J. Physiol.*, 388: 397–419.
- Jasper, H. (1958) Report of the committee on methods of clinical examination in electroencephalography. *Electroencephal. clin. Neurophysiol.*, 10: 370–375.

- Kadekaro, M., Crane, A.M. and Sokoloff, L. (1985) Differential effects of electrical stimulation of sciatic nerve on metabolic activity in spinal cord and dorsal root ganglion in the rat. *Proc. Natl. Acad. Sci. USA*, 82: 6010–6013.
- Kinsbourne, M. (1977) Hemi-neglect and hemisphere rivalry. In: E.A. Weinstein and R.P. Friedland (Eds.), *Advances in Neurology*, Vol. 18, Raven Press, New York, pp. 41–49.
- Laplane, D. and Degos, J.D. (1983) Motor neglect. *J. Neurol. Neurosurg. Psychiat.*, 46: 152–158.
- Laplane, D., Baulac, M. and Curydakis, C. (1986) Négligence motrice d'origine thalamique. *Rev. Neurol. Paris*, 142/4: 375–379.
- Laplane, D. (1990) La négligence motrice a-t-elle un rapport avec la négligence sensorielle unilatérale? *Rev. Neurol. Paris*, 146/10: 635–638.
- Liepmann, H. (1908) *Drei Aufsätze aus dem Apraxiegebiet*. Karger, Berlin.
- Liu, G.T., Bolton, A.K., Price, B.H. and Weintraub, S. (1992) Dissociated perceptual-sensory and exploratory-motor neglect. *J. Neurol. Neurosurg. Psychiat.*, 55: 701–706.
- Maccabee, P.J., Amassian, V.E., Cracco, R.Q. et al. (1991) Stimulation of the human nervous system using the magnetic coil. *J. Clin. Neurophysiol.*, 8(1): 38–55.
- Martin, W.R.W. and Raichle, M.E. (1983) Cerebellar blood flow and metabolism in cerebral hemisphere infarction. *Ann. Neurol.*, 14: 168–176.
- Matsui, T. and Hirano, A. (1978) *An atlas of the human brain for computed tomography*, Gustav Fischer Verlag, Stuttgart.
- Mesulam, M.-M. (1981) A cortical network for directed attention and unilateral neglect. *Ann. Neurol.*, 10: 309–325.
- Mesulam, M.-M. (1990) Large-scale neurocognitive networks and distributed processing for attention, language, and memory. *Ann. Neurol.*, 28: 597–613.
- Meyer, B.U., Britton, T.C., Kloten, H. et al. (1991) Coil placement in magnetic brain stimulation related to skull and brain anatomy. *Electroencephal. clin. Neurophysiol.*, 81: 38–46.
- Paillard, J. (1990) Initiation du mouvement et négligence motrice – À propos de la négligence motrice – issues et perspectives. *Rev. Neurol. Paris*, 146/10: 600–611.
- Pause, M., Kunesch, E., Binkofski, F. and Freund, H.-J. (1989) Sensorimotor disturbances in patients with lesions of the parietal cortex. *Brain*, 112: 1599–1627.
- Phelps, M.E., Huang, S.C., Hoffman, E.J. et al. (1979) Tomographic measurement of local cerebral glucose metabolic rate in humans with (F-18)2-fluoro-2-deoxy-D-glucose: validation of method. *Ann. Neurol.*, 6: 371–388.
- Reivich, M., Alavi, A., Wolf, A. et al. (1985) Glucose metabolic rate kinetic model parameter determination in humans: the lumped constants and rate constants for (18 F) fluorodeoxyglucose and (11 C) deoxyglucose. *J. Cereb. Blood Flow Metab.*, 5: 179–192.
- Rizzolatti, G. and Berti, A. (1990) Neglect as a neural representation deficit. *Rev. Neurol. Paris*, 146/10: 626–634.
- Roland, P.E. (1987) Metabolic mapping of sensorimotor integration in the human brain. In: *Motor Areas of the Cerebral Cortex*, CIBA Foundation Symp. 132, John Wiley & Sons, Chichester, pp. 251–268.
- Rondot, P., de Recondo, J. and Ribadeau Duma, J.L. (1977) Visuo-motor ataxia. *Brain*, 100: 355–376.
- Rota Kops, E., Herzog, H., Schmid, A. et al. (1990) Performance characteristics of an eight-ring whole body PET scanner. *J. Comput. Assist. Tomogr.*, 14: 437–445.
- Sachs, L. (1984) *Angewandte Statistik*, Springer-Verlag, Berlin, Heidelberg, New York, Tokyo.
- Scheibel, M.E. and Scheibel, A.B. (1967) Structural organization of nonspecific thalamic nuclei and their projection towards cortex. *Brain Res.*, 6: 60–94.
- Seitz, R.J., Bohm, C., Greitz, T. et al. (1990) Accuracy and precision of the computerized brain atlas programme for localization and quantification in positron emission tomography. *J. Cereb. Blood Flow Metab.*, 10: 443–457.
- Seitz, R.J., Knorr, U., Schlaug, G. et al. (1993) Comparison of inter-subject averaging and individual response identification for mapping of motor function in the human brain with positron emission tomography. In: Uemura, K., Lassen, N.A., Jones, T. and Kanno, I. (Eds.), *Quantification of Brain Function*, ICS No. 1030, Excerpta Medica, Amsterdam, pp. 561–568.
- Seitz, R.J., Schlaug, G., Kleinschmidt, A. et al. (1994) Remote depressions of cerebral metabolism in hemiparetic stroke: topography and relation to motor and somatosensory function. *Hum. Brain Mapp.*, 1: 81–100.
- Steriade, M. and Glenn, L. (1982) Neocortical and caudate projections of intralaminar thalamic neurons and their synaptic excitation form the midbrain reticular core. *J. Neurophysiol.*, 48: 352–370.
- Stöhr, M., Dichgans, J., Voigt, K. and Buettner, U.W. (1983) The significance of somatosensory evoked potentials for localization of unilateral lesions within the cerebral hemispheres. *J. Neurol. Sci.*, 61: 49–63.
- Talairach, J. and Tournoux, P. (1988) *Co-planar stereotaxic atlas of the human brain. 3-Dimensional proportional system: an approach to cerebral imaging*, Thieme Verlag, Stuttgart, New York.
- Watson, R.T. and Heilman, K.M. (1979) Thalamic neglect. *Neurology*, 29: 690–694.
- Watson, R.T., Heilman, K.M., Cauthen, J.C. et al. (1973) Neglect after cingulectomy. *Neurology*, 23: 1003–1007.
- Watson, R.T., Heilman, K.M., Miller, B.D. et al. (1974) Neglect after mesencephalic reticular formation lesions. *Neurology*, 24: 294–298.
- Watson, R.T., Andriola, M. and Heilman, K.M. (1977a) The electroencephalogram in neglect. *J. Neurol. Sci.*, 34: 343–348.
- Watson, R.T., Miller, B.D. and Heilman, K.M. (1977b) Evoked potential in neglect. *Arch. Neurol.*, 34: 224–227.
- Watson, R.T., Miller, B.D. and Heilman, K.M. (1978) Nonsensory neglect. *Ann. Neurol.*, 3: 505–508.
- Watson, R.T., Valenstein, E. and Heilman, K.M. (1981) Thalamic neglect; possible role of the medial thalamus and nucleus reticularis thalami in behaviour. *Arch. Neurol.*, 38: 501–506.
- Yarowsky, P., Kadekaro, M. and Sokoloff, L. (1983) Frequency-dependent activation of glucose utilization in the superior cervical ganglion by electrical stimulation of cervical sympathetic trunk. *Proc. Natl. Acad. Sci. USA*, 80: 4179–4183.