

Management of tentorial dural arteriovenous malformations: transarterial embolization combined with stereotactic radiation or surgery

ADAM I. LEWIS, M.D., THOMAS A. TOMSICK, M.D., AND JOHN M. TEW, JR., M.D.

Departments of Neurosurgery and Neuroradiology, University of Cincinnati College of Medicine, and Mayfield Neurological Institute, Cincinnati, Ohio

✓ The clinical, anatomical, and radiological features of nine cases of tentorial dural arteriovenous malformations (AVM's) are presented, and 45 reported cases are reviewed. Unlike dural AVM's of the transverse sigmoid and cavernous sinuses that usually have a benign natural history, dural AVM's of the tentorium typically present with hemorrhage or progressive neurological deficit. In this series, patients ranged in age from 52 to 72 years and included five men and four women. These patients presented with subarachnoid hemorrhage, parenchymal hemorrhage, brainstem dysfunction, cerebellar signs, and obstructive hydrocephalus. Malformations were fed principally by the meningohypophyseal trunk, branches of the middle meningeal artery, and the occipital artery. Venous drainage was uniform through the cortical veins (predominantly the mesencephalic, petrosal, and cerebellar veins). Eight of the nine patients had an associated venous aneurysm(s); two had more than one venous aneurysm, and two patients had a vein of Galen aneurysm associated with the tentorial dural AVM. Eight of nine patients improved after treatment, including four patients with complete obliteration of the dural AVM. Based on our experience, we have developed a treatment protocol for tentorial dural AVM's that uses transarterial embolization followed by direct microsurgery or stereotactic radiation. These therapies, applied in a staged manner, have proven safe and relatively effective for the treatment of dural AVM's.

KEY WORDS • tentorium • dural arteriovenous malformation • embolization • meningohypophyseal trunk • radiosurgery

TENTORIAL dural arteriovenous malformations (AVM's) are arteriovenous fistulas located in the tentorial dura mater. They are fed primarily from branches of the meningohypophyseal trunk, middle meningeal artery, and occipital artery. Unlike the less aggressive dural AVM's of the lateral and cavernous sinuses that drain into venous sinuses, tentorial dural AVM's drain into pial veins. Often tentorial dural AVM's present as high-flow fistulas with an associated venous aneurysm. These characteristics make dural AVM's prone to subarachnoid hemorrhage (SAH) and parenchymal hemorrhage, which may lead to serious neurological sequelae (Fig. 1).

In 1962, Ciminello and Sachs⁸ first reported successful obliteration of a tentorial dural AVM by ligating a posterior meningeal branch from the vertebral artery. Since then, another 44 cases have been described.^{1-3,9-13,15-17,19-21,24-26,28-30,32,33,36,37} In a review of the literature on dural AVM's, Awad and associates² estimated that tentorial dural AVM's comprised 8.4% of all intracranial dural AVM's found that 31 of 32 presented with hemorrhagic or nonhemorrhagic

stroke. With features such as a multitude of feeding vessels, cortical venous drainage, and deep location, dural AVM's of the tentorium are extremely difficult to obliterate.

Tentorial dural AVM's form a unique subset of intracranial dural AVM's. We present the clinical, anatomical, and radiological features of 54 tentorial dural AVM's, including nine new patients from our series. Based on our experience with these complex malformations, we have developed a treatment protocol that combines transarterial embolization with stereotactic radiation or microsurgery. The rationale and success of our treatment strategies are discussed.

Clinical Material and Methods

Patient Population

Between 1982 and 1992, we evaluated and treated nine patients with symptomatic dural AVM's of the tentorium (Table 1). Patients included five men and four women, ranging in age from 52 to 72 years old

TABLE 1
Clinical and angiographic features of tentorial dural arteriovenous malformations in nine patients*

Case No.	Age (yrs), Sex	Symptoms	Arterial Supply	Venous Drainage	Venous Aneurysm	Treatment	Complications	Outcome	Residual DAVM
1	52, M	SAH, BSD, progressive headaches, ataxia	MMA, MHT, OA, AccMA, AFR, STA	Rosenthal, petrosal	1	embolization × 3, surgical excision	hemorrhagic venous infarction with postop hematoma	severely disabled	no
2	53, M	hydrocephalus, tinnitus, dysarthria, ataxia	MMA, MHT, ILT, TB-SCA, AccMA	sylvian, cerebellar, pontine	2 bilateral petrosal	embolization × 2, radiosurgery 1875 cGy, VP shunt	transient radiation injury to brain stem, partial thrombosis of DAVM	myelopathy resolved, improved gait & speech	yes
3	66, M	BSD, raised ICP, hydrocephalus, diplopia	MMA, MHT, OA, PMA	petrosal, basilar	1 (vein of Galen)	embolization × 2, radiosurgery 1700 cGy, VP shunt	none	DAVM obliterated, BSD relieved, gait improved	no
4	72, M	ICH, BSD, hydrocephalus	MHT, MMA, ILT, AccMA	mesencephalic, petrosal, Rosenthal	1	embolization, radiosurgery 1500 cGy, VP shunt	none	normal exam	no
5	67, F	SAH, BSD, vertigo, left UE numbness	MHT, AFR	petrosal, mesencephalic	1 indenting brain stem	surgical excision, VP shunt	none	lt. face hypalgesia	no
6	63, F	ICH, hydrocephalus	MHT(B), OA, MMA(B), StmA	Rosenthal, petrosal	2 (vein of Galen)	embolization × 2, radiosurgery 1800 cGy, VP shunt	none	normal exam, improved memory	yes
7	65, M	dysarthria, ataxia, (B)UE weakness	MHT, MMA, OA	pontine, basilar, cerebellar	0	embolization × 2, radiosurgery 2000 cGy	none	decreased BSD, decreased ataxia, improved UE strength	yes
8	63, F	SAH, ataxia	(B)TB-SCA, (B)PCA, MHT	vein of Galen	1	embolization, radiosurgery 800 cGy	none	normal exam	no
9	54, F	lt. eye 20/100, proptosis, chemosis	MHT, MMA, OA, IMA, PaurA	inferior, ophthalmic, Rosenthal	1 indenting brain stem	embolization, radiosurgery 1500 cGy	none	lt. eye 20/25, normal ocular pressure	yes

* Abbreviations: DAVM = dural arteriovenous malformation; SAH = subarachnoid hemorrhage; BSD = brainstem dysfunction; MMA = middle meningeal branches; MHT = meningohypophyseal trunk; OA = occipital artery; AccMA = accessory meningeal artery; AFR = artery of the foramen rotundum; STA = superior temporal artery ICP = intracranial pressure; ICH = intracerebral hemorrhage; ILT = inferior lateral trunk; UE = upper extremity; TB-SCA = tentorial branch of the superior cerebellar artery; MHT = meningohypophyseal trunk; PMA = posterior meningeal artery; VP = ventriculoperitoneal; (B) = bilateral; STmA = stylomastoid artery; PCA = posterior cerebellar artery; IMA = internal maxillary artery; PaurA = posterior auricular artery.

(mean 61 years). In this series, five patients suffered an SAH or intracerebral hemorrhage, three presented with obstructive hydrocephalus, and two with progressive neurological deficits. Our patients frequently presented with brainstem dysfunction, cerebellar signs, and hydrocephalus. The presenting neurological deficits in 54 patients with dural AVM's are summarized in Table 2.

Diagnostic Studies

A cerebral angiogram was performed in each of the nine patients to make a definitive diagnosis and to plan endovascular therapy. Angiograms included bilateral selective injection of the internal carotid, external carotid, and vertebral arteries. Magnetic resonance (MR) imaging (at 1.5 tesla) with and without

gadolinium enhancement was performed in eight of nine patients and MR angiography was performed in four.

Treatment Protocol

Eight patients underwent 14 transarterial embolization procedures via a percutaneous transfemoral route. One patient did not undergo embolization because the feeding vessels were too small to cannulate. Prior to the actual embolization of feeding arteries, amytal or lidocaine was injected to ensure that normal capillaries were not embolized inadvertently. Amytal was used to test for ischemia of brain tissue (gray matter), and lidocaine was used to test for ischemia to the cranial nerves (white matter). The feeding arteries were injected with a glue mixture of N-butyl cyanoacrylate,

Management of tentorial dural arteriovenous malformations

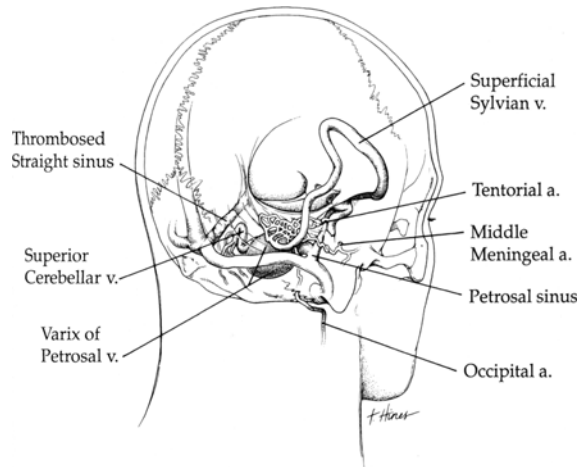


FIG. 1. Schematic drawing of a dural arteriovenous malformation of the tentorium with arterial supply from the tentorial artery of the meningohypophyseal trunk, middle meningeal artery branches, and occipital artery. The plexiform nidus is in the dura mater of the tentorium. Cerebellar and vermician veins drain the malformation posteriorly, a petrosal vein with an associated giant venous aneurysm drains the malformation inferolaterally, and a dilated superficial sylvian vein drains it superiorly. The straight sinus is thrombosed.

pantopaque, and tantalum powder in a 1:1:1 ratio or polyvinyl alcohol (PVA) sponges (250 to 700 μm size). Sponge particles larger than 250 μm were used to avoid inadvertent embolization of arteries that supply cranial nerves.

Seven patients underwent stereotactic radiation of the dural AVM nidus using a linear accelerator in doses ranging from 800 to 2000 cGy (mean 1560 cGy); the dural AVM was localized employing the Cosman-Roberts-Wells stereotactic coordinate system.

Two patients had surgical excision of their nidus, one by an anterior petrosal approach and the other by a subtemporal approach, and both underwent intra- and postoperative angiography. Five patients required ventriculoperitoneal shunting for hydrocephalus, which was caused by obstruction of the cerebral aqueduct in three cases and SAH in two.

Follow-Up Evaluations

Patients returned after treatment at 1 month, 6 months, 1 year, and 2 years or sooner if symptoms recurred or progressed. Both MR imaging and MR angiography performed after embolization procedures were undertaken to evaluate patency of the nidus, thrombosis of the varix, parenchymal edema, and ventricular size. One year after radiosurgery, MR imaging and MR angiography were performed to evaluate patency of the dural AVM and the surrounding brain. If MR images demonstrated a flow void within the dural AVM, the malformation was assumed to be patent and the patient was not subjected to the risk of an angiogram unless further embolization procedures were necessary. When thrombosis of the dural AVM

TABLE 2
Presenting neurological deficits in 54 tentorial dural AVM's*

Deficit	No. of Cases	Percent
subarachnoid hemorrhage	25	46
intracerebral hemorrhage	15	28
hydrocephalus	15	28
hemi- or tetraparesis	14	26
cerebellar signs	12	22
brainstem dysfunction	11	20
myelopathy	10	19
cranial nerve palsy	9	17
dysphagia/dysarthria	8	15
visual loss	7	13
tinnitus	7	13
headache	6	11
raised intracranial pressure	6	11
vertigo	4	7

* AVM's = arteriovenous malformations.

was seen on MR imaging and angiography, the patient underwent selective four-vessel cerebral angiography to confirm complete obliteration of the malformation. Cerebral angiography was performed 2 years after stereotactic radiosurgery.

Illustrative Cases

Case 3

History. This 66-year-old man with a dural fistula and a dilated vein of Galen had previously undergone placement of a ventriculoperitoneal shunt for obstructive hydrocephalus. Despite achieving good decompression of the ventricular system, symptoms of brainstem compression persisted. The patient was referred to our institution for further evaluation and treatment.

Angiographic Studies. A cerebral angiogram demonstrated a dural AVM of the tentorium fed principally by both meningohypophyseal arteries with contributions from the right middle meningeal, right occipital, and left posterior meningeal arteries. Drainage from the nidus was through the cortical veins. The angiogram also demonstrated a patent giant vein of Galen aneurysm and thrombosis of the straight sinus (Fig. 2 upper left).

Treatment Protocol. The patient underwent embolization of the occipital artery and the right meningohypophyseal trunk. Partial thrombosis of the vein of Galen aneurysm occurred. Gait ataxia, memory, and coordination improved markedly. He then underwent stereotactic radiation of the residual nidus with 1700 cGy to the 80% isodose line.

Outcome. Approximately 15 months after embolization and radiation, the patient developed increased frequency of headaches, evidence of brainstem compression, and gait ataxia. At this time, the right middle meningeal artery was embolized and the entire malformation, including the vein of Galen aneurysm,

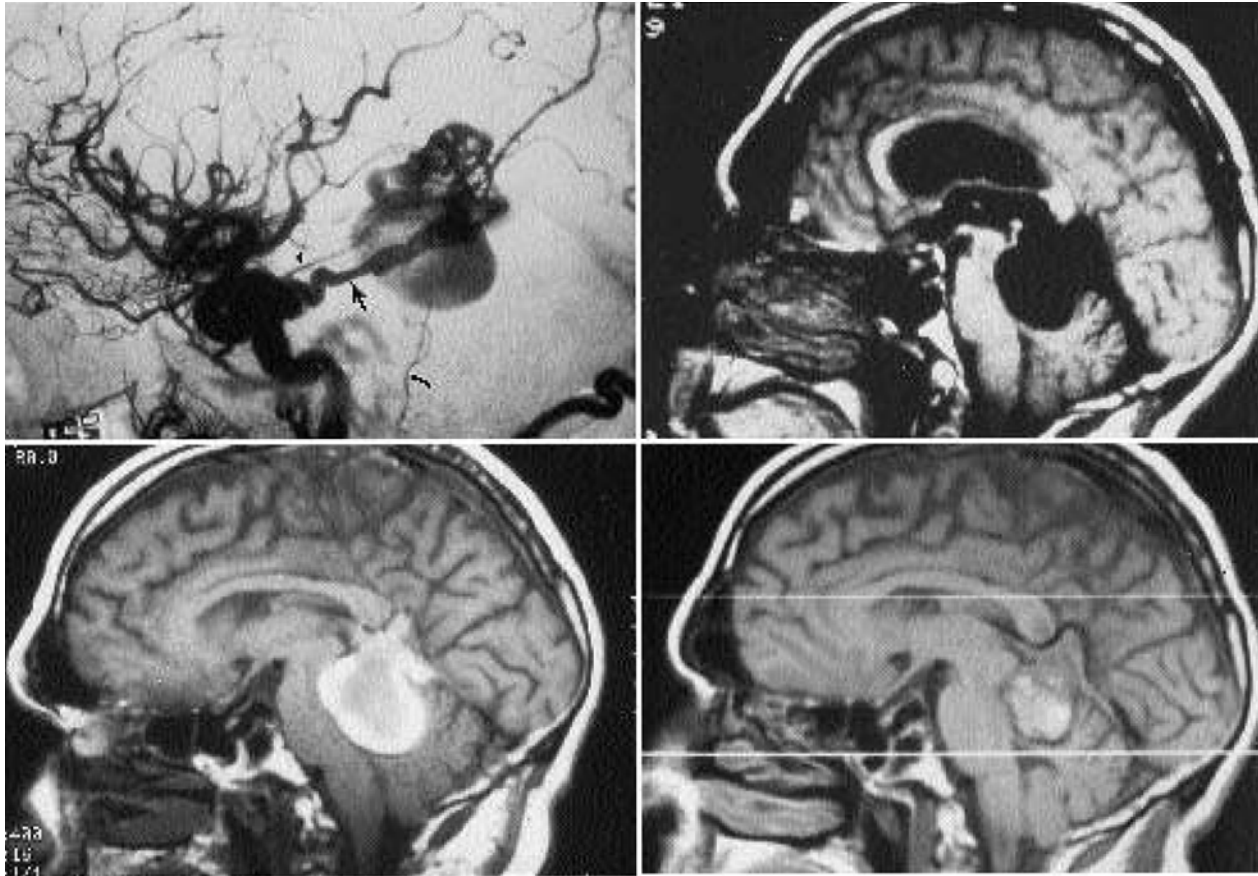


FIG. 2. Angiographic and magnetic resonance (MR) imaging studies of the dural arteriovenous malformation (AVM) presenting in Case 3. *Upper Left:* Lateral right internal carotid angiogram showing a dilated tentorial artery (*large arrow*), middle meningeal artery (*arrowhead*), and occipital artery (*small arrow*) feeding a plexiform nidus that drained through a dilated vein of Galen aneurysm. The straight sinus is thrombosed. *Upper Right:* A T₁-weighted sagittal MR image performed before embolization and radiosurgery showing the flow void within the nidus and the aneurysm. There is moderate obstructive hydrocephalus. *Lower Left:* Magnetic resonance image demonstrating that the dural AVM and vein of Galen aneurysm are completely thrombosed after two embolization procedures and radiosurgery with 1700 cGy. The patient recovered rapidly from symptoms of brainstem compression. *Lower Right:* Follow-up sagittal MR image 1 year later showing the vein of Galen aneurysm to be smaller with less mass effect exists on the brain stem compared with the previous study. Note that the lateral and third ventricles are small after ventriculoperitoneal shunting.

became completely thrombosed (Fig. 2 *lower left*). There was no evidence of residual malformation on MR imaging or angiography. During a routine 1-month follow-up office visit, he was walking independently and swallowing without difficulty; the headaches had resolved. A follow-up angiogram 2 years after radiosurgery confirmed obliteration of the tentorial dural AVM.

Case 2

History and Examination. This 53-year-old man had previously received a ventriculoperitoneal shunt for obstructive hydrocephalus from bilateral petrosal venous aneurysms that compressed the sylvian aqueduct. Four years after shunting, he developed an insidious onset of headaches, tinnitus, slurred speech,

and gait disturbance. Neurological examination was remarkable for dysarthria, left pronator drift, left-sided cerebellar signs, and myelopathy.

Radiological Studies. A computerized tomography (CT) scan of the head showed a patent giant right petrosal venous aneurysm and a partially thrombosed giant sister petrosal venous aneurysm indenting the left brain stem; however, there was no evidence of hemorrhage. There were numerous dilated cerebellar veins and parenchymal swelling of the brain stem and cerebellum. A cerebral angiogram showed that the malformation was fed by the right middle meningeal artery, right meningohypophyseal trunk, artery of the inferior cavernous carotid artery, accessory meningeal artery, and a tentorial branch of the superior cerebellar artery. The venous drainage was through the superfi-

Management of tentorial dural arteriovenous malformations

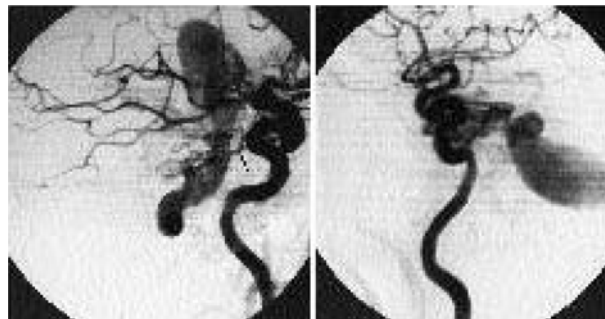


FIG. 3. Case 2. *Left:* Lateral right internal carotid angiogram showing a tentorial dural arteriovenous malformation fed by the meningo-hypophyseal trunk (arrow). An elongated and dilated petrosal venous aneurysm extends from the lateral ventricles to the posterior fossa. *Right:* A lateral left internal carotid angiogram of the same patient demonstrating a giant sister petrosal venous aneurysm on the left side and a plexiform nidus filling from the left internal carotid artery branches.

cial sylvian, superior cerebellar, and pontine veins. Both petrosal aneurysms filled angiographically and the straight sinus was thrombosed (Fig. 3).

Treatment Protocol. The patient underwent embolization of the left and right middle meningeal arteries, the left accessory meningeal artery, and the tentorial artery from the meningeal hypophyseal trunk. The nidus of the dural malformation was then stereotactically irradiated with 1875 cGy at the 80% isodose line.

Outcome. The patient initially improved neurologically, spoke fluently, and ambulated independently. Unfortunately, 14 months later he developed right-sided facial numbness, dysarthria, and a mild left-sided hemiparesis. Magnetic resonance imaging showed radiation-induced edema of the brain stem. Since that time, the patient has regained strength on

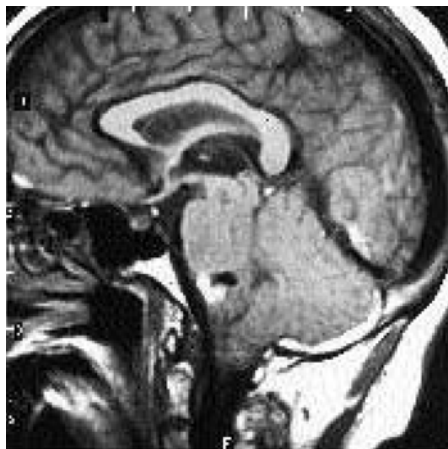

FIG. 4. Case 5. A T_1 -weighted sagittal magnetic resonance image showing a petrosal venous aneurysm indenting the brain stem. The surrounding high-intensity signal represents subacute blood from rupture of the venous aneurysm.

his left side and the dysarthria has diminished. At a 20-month follow-up examination (6 months after the onset of radiation injury), MR imaging and MR angiography showed resolution of the radiation changes, a marked decrease in the size and number of dilated veins, and thrombosis of the nidus. An angiogram was performed to confirm the obliteration; however, on angiography there was persistent flow to the nidus from a small branch of the right middle meningeal artery.

Case 5

History and Examination. This 67-year-old woman with a previous history of hypertension and vertigo suffered an SAH. On physical examination she was lethargic and hypesthetic on the left side of the face and left upper extremity and had a diminished gag reflex and decreased right uvula elevation. The remaining neurological examination was normal.

Radiographic Studies. A CT scan showed diffuse SAH around the basal cisterns. A cerebral angiogram demonstrated feeding arteries from the meningo-hypophyseal trunk to a nidus located at the petrous apex. Venous drainage was through the pontomesencephalic and petrosal veins. An associated venous aneurysm indented the brain stem at the right lateral pontomedullary junction. Hemorrhaging from the venous aneurysm was evident on MR imaging (Fig. 4).

Treatment. Embolization of the dural AVM was not attempted because the feeding vessels were too small. A right anterior petrosal approach to the dural malformation was performed. Several small feeding arteries on the tentorium were coagulated with bipolar electrocautery. The tentorium was then split, exposing the tentorial artery. The tentorial artery from the meningo-hypophyseal trunk could be seen draining into an arterialized pontomesencephalic vein. Upon clipping the feeding artery, the vein and venous aneurysm collapsed. Intra- and postoperative angiograms showed no evidence of residual malformation.

Outcome. The patient developed communicating hydrocephalus postoperatively and underwent ventriculoperitoneal shunting. One year after surgery her neurological deficits are left-sided hypalgesia in the first and second divisions of the trigeminal nerve and a mildly diminished left corneal reflex. Currently, she is able to provide daily care for her two grandchildren.

Results

Radiological Studies

Our experience and a review of the literature concerning the arterial supply and venous drainage for 54 tentorial dural AVM's are summarized in Table 3. In our nine patients, dural AVM's were fed primarily by arteries from the meningo-hypophyseal trunk, middle meningeal branches, and occipital artery. Venous drainage was uniform through the cortical veins (predominantly from the mesencephalic, petrosal, and

TABLE 3
Arterial supply and venous drainage of 54 tentorial
dural AVM's*

Arterial Supply	No. of Cases (%)	Venous Drainage	No. of Cases (%)
meningohypophyseal trunk	36 (67)	Cortical	16 (30)
middle meningeal branches	35 (65)	mesencephalic	13 (24)
occipital	31 (57)	cerebellar/vermian	12 (22)
posterior cerebral (tentorial branch)	13 (24)	petrosal	12 (22)
superior cerebellar (tentorial branch)	12 (22)	spinal veins	7 (13)
posterior meningeal	10 (19)	vein of Galen	7 (13)
ascending pharyngeal	9 (17)	pontine	5 (9)
accessory meningeal	8 (15)	basilar	4 (7)
inferior lateral trunk	4 (7)	vein of Rosenthal	4 (7)

* AVM's = arteriovenous malformations.

cerebellar veins). Eight of nine patients had an associated venous aneurysm(s), two had more than one aneurysm, and two patients had a vein of Galen aneurysm associated with the dural AVM.

Endovascular Therapy

Eight of nine patients in our series underwent transarterial embolization, all of whom had reduced fistula flow after embolization and no endovascular complications. Five (62.5%) of the eight patients required repeat embolization procedures. One patient (Case 1) had a progression of symptoms despite undergoing three separate embolization procedures, and he required surgical excision of the dural AVM. All cases were inaccessible from a percutaneous transvenous route.

Radiosurgical Results

Seven patients underwent stereotactic radiation of the dural AVM nidus. Five (71.4%) of seven patients showed thrombosis of the dural AVM on MR imaging at a 24-month follow-up examination; two other cases had a follow-up examination at less than 24 months, but MR imaging or MR angiography or both showed more than a 50% reduction in venous flow. On angiography three patients (Cases 4, 6, and 8) demonstrated total obliteration of their dural AVM's, and another patient (Case 3) had total obliteration after a third embolization procedure. One patient (Case 2) suffered transient radiation injury to the brain stem 14 months after radiosurgery. Follow-up examination after radiosurgery ranged from 9 to 35 months (mean 24 months).

Surgical Management

Surgical excision of the tentorial dural AVM was performed in two cases, the first because symptoms progressed despite three separate embolization procedures. Although the malformation was eliminated, the

patient (Case 1) suffered a distant hemorrhagic venous infarction postoperatively and remains severely disabled. The second patient (Case 5) underwent surgical excision because the arterial feeding vessels were too small to embolize. Follow-up intervals for all nine patients ranged from 9 months to 10 years (mean 30 months). Except for the patient described in Case 1, all patients improved. Overall, five patients (56%) had complete obliteration and four (44%) had partial obliteration of their dural AVM at the time of this report. There has been no recurrent hemorrhage or mortality that can be associated with this procedure.

Discussion

Presentation of the Tentorial Dural AVM

The most common presentation of a tentorial dural AVM is hemorrhage, perhaps due to the development of pial venous drainage. Of all cases in this study and among those reported in the literature, 40 (74%) of 54 patients presented with hemorrhage. In comparison, only 15% of other intracranial dural AVM's, including those in the anterior cranial fossa, presented with hemorrhage.² Hemorrhage occurs either from cortical veins or venous aneurysms. Furthermore, patients may slowly and progressively decline in neurological function due to venous hypertension, which causes a decrease in cerebral perfusion and ischemia to the surrounding tissues.¹⁹ Venous hypertension also leads to enlarged and tortuous draining veins and the formation of varices. In this series, eight of nine patients had a venous aneurysm(s); overall, 31 (57.4%) of 54 tentorial dural AVM's demonstrated a venous aneurysm. Patients who present with myelopathy rarely have associated venous aneurysms but appear to become symptomatic before varices form, whereas patients with venous aneurysms usually remain clinically silent until the aneurysm has ruptured.

Venous stenosis is a known risk factor for hemorrhage in pial AVM's and dural AVM's of the transverse sigmoid sinus.^{18,27} In this series, the initial angiograms showed significant venous stenosis in every case, and the failure of a venous sinus to opacify either from thrombosis or venous hypertension was seen in seven cases. On histological examination, we have found endothelial proliferation, collagen deposition, smooth-muscle formation, and recanalization within the veins and varices of dural AVM's. Presumably these changes are a response to the high pressure and turbulent flow caused by the direct shunting of arterial blood. Venous restrictive disease may be the initial process that leads to venous hypertension, sinus thrombosis, antegrade flow through cortical veins, and varix formation.

Tentorial dural AVM's that drain into spinal medullary veins may produce myelopathy.^{31,32,37} Two of our patients (Cases 2 and 7) demonstrated signs of myelopathy that improved markedly after embolization. Because dural AVM's of the tentorium are often high-flow fistulas, they may produce an arterial steal phenomenon. In contrast, most intracranial dural

Management of tentorial dural arteriovenous malformations

AVM's have low-flow shunts and rarely show signs of arterial steal.¹⁹

Compression of the sylvian aqueduct by a large distended vein or varix may produce obstructive hydrocephalus.^{10,24} Communicating hydrocephalus may occur after SAH or decreased cerebrospinal fluid (CSF) absorption from venous congestion.^{16,33,34} In addition, venous hypertension may raise intracranial pressure (ICP) by increasing CSF pressure and decreasing CSF absorption.^{34,35} Fifteen (27.8%) of 54 patients with tentorial dural AVM's presented with hydrocephalus and 10 (18.5%) required ventricular shunting.

Dural AVM's may undergo spontaneous thrombosis or regression.⁴ There have been no reports of tentorial dural AVM's resolving spontaneously. The multitude of small dural arteries, a variety of venous pathways, and high flow may prevent spontaneous closure.

Anatomy of the Tentorial Dural AVM

Tentorial dural AVM's are similar in regard to arterial supply: all nine cases in our series were supplied by the meningohypophyseal trunk. Additionally, the middle meningeal branch vessels and the occipital artery supplied the dural AVM in most patients. Venous drainage varied greatly and depended on the tentorial location of the malformation.²³ Those located near the petrous apex along the incisura drained via mesencephalic and basilar veins and the vein of Rosenthal. Those in the lateral region near the transverse sigmoid sinus drained through the inferior temporal, occipital, and superficial sylvian veins. Those in the midline near the junction of the falx drained via cerebellar and vermian veins.³² Signs and symptoms did not predict the location of the dural AVM on the tentorium. Two patients presented with a rare dural-based vein of Galen aneurysm.^{24,28,30} Two cases presented with two venous aneurysms; dural AVM's with more than one venous aneurysm have not been reported previously.

Pathogenesis of the Tentorial Dural AVM

Like other intracranial dural AVM's, the etiology of dural AVM's of the tentorium is unclear. Most patients (74%) with tentorial dural AVM's present in the fifth and sixth decades of life. Thrombosis of a dural sinus is seen in the majority of cases. Numerous tiny arteries feeding the dural AVM suggest that arterial recruitment contributed to the formation of tentorial dural AVM's. These anatomical features form a strong argument for the suggestion that tentorial dural AVM's are acquired lesions.^{6,14}

On the other hand, tentorial dural AVM's do not always demonstrate a thrombosed sinus. Many tentorial dural AVM's are located near the petrous apex, which is an embryonic vascular border zone between the internal maxillary artery system and the pharyngo-occipital system. Over time, embryonic arteriovenous fistulas between the two systems may have opened and created the dural AVM.¹¹ There are no reports of

tentorial dural AVM's arising as a result of trauma or surgical procedure. Interestingly, tentorial dural AVM's occur more than twice as often in men than women; this represents a gender predominance similar to that found in cases of anterior cranial fossa dural AVM's, a disorder regarded as congenital in nature.²² In contrast, cavernous sinus and transverse sinus dural AVM's have a female predominance and are believed to be acquired fistulas.²² The arguments for a congenital etiology are equally compelling to those arguments made for an acquired origin.

Treatment Protocol

Transarterial Embolization. Based on the anatomy, the natural history, and our experience with dural AVM's, we have developed a protocol to treat these complex vascular malformations. After performing cerebral angiography, treatment begins with transarterial embolization of the feeding arteries from the external carotid artery. Miyasaka and coworkers²⁶ were the first to embolize a dural AVM using Gelfoam particles. We found that adhesive glue (N-butyl cyanoacrylate) was more easily controlled, was more permanent than PVA sponge, and produced better results than PVA sponges. However, physicians not familiar with glues should not use them to perform endovascular procedures.

Venous hypertension and arterial steal were decreased by reducing arterial flow to the fistula. However, in our experience, multiple procedures were often required and cure was obtained in only one case, although symptoms were palliated in every patient. Many feeding arteries were too small to embolize or were invisible on angiography. Sometimes arteries of the meningohypophyseal trunk were cannulated but were not embolized because the risk of occluding normal capillary beds was too high. It is unknown whether partial embolization of dural AVM's reduces the risk of hemorrhage. Although none of our patients rebled after partial embolization, we suspect that, as with other vascular malformations, the risk for hemorrhage remains unchanged if the dural AVM is not entirely obliterated.

Transvenous Embolization. Access to tentorial dural AVM's is not available via a percutaneous route because drainage takes place entirely through the pial veins. Bamwell, *et al.*,³ successfully obliterated a falx-tentorial dural AVM by employing open craniotomy and direct injection of glue into a ligated vein. However, multiple pathways on the venous side make total obliteration using a transvenous route very difficult. In fact, occluding the venous side before decreasing flow from the arterial side may aggravate venous hypertension and increase the risk of hemorrhage. Furthermore, hemorrhagic venous infarction may occur as a result of occluding normal draining veins. The transarterial approach is safer, more effective, and should be the first line of treatment. After transarterial embolization, the patient is treated by stereotactic radiation or direct surgical obliteration. If the patient

improves neurologically after arterial embolization, we recommend stereotactic radiation of the dural AVM nidus. If new symptoms arise or old ones recur while waiting for nidal thrombosis to take place, another transarterial embolization is performed on accessible feeding arteries. Surgery is indicated if the feeding arteries are too small to embolize, if the patient does not improve after transarterial embolization, or if the risk of radiation injury to the surrounding structures is too high.

Radiosurgical Results. Conventional or stereotactic radiation of dural AVM's has been reported infrequently but with good results and minimal morbidity.^{5,7,38} Radiosurgery is well suited for tentorial dural AVM's because they are deep seated and usually have a multitude of tiny vessels feeding a small (< 3 cm) plexiform nidus. The goal of radiosurgery is to eliminate the remaining feeding arteries that are too small or cannot be embolized without a risk of infarction. There is a risk for hemorrhage and radiation injury to the brain stem, but there have been no episodes of hemorrhage and only one case of transient neurological deficit in seven treated patients. Preliminary results show that stereotactic radiosurgery and transarterial embolization are safe and effective in eliminating most tentorial dural AVM's.

Microsurgical Techniques. Direct surgical ligation and excision of the dural AVM are indicated when transarterial embolization has not alleviated neurological symptoms or when arterial vessels are too small to embolize. Grisoli, *et al.*,¹¹ reported good results when they clipped the venous side of the shunt. We believe that tentorial dural AVM's are clinically distinct from cavernous and transverse sinus dural AVM's and behave more like parenchymal AVM's. In our experience, ligation of draining veins or sinuses is associated with a high incidence of hemorrhagic venous infarction. Tentorial dural AVM's should be surgically obliterated from the arterial side. To ligate only the venous side may provoke brain swelling and an inadvertently high risk of cerebellar infarction. Clipping a venous aneurysm is unnecessary because it will collapse and thrombose when the fistula is obliterated. Intraoperative angiography should be performed to confirm obliteration of dural AVM's.

Conclusions

Tentorial dural AVM's are a unique subset of intracranial dural AVM's that are prone to hemorrhage from cortical veins or associated venous aneurysms. Tentorial dural AVM's are difficult to obliterate by embolization because of the multiple tiny feeding arteries that are adjacent to vital normal vascular beds. Reducing arterial flow by embolization and obliterating the remaining dural malformation with radiosurgery or direct microsurgery is the best treatment strategy. Combining these therapies in a staged manner has proven safe and effective for the treatment of tentorial dural AVM's.

Acknowledgments

The authors thank Tonya Hines for her medical illustration, Mary Kemper and Laura Bofinger for editorial assistance, and Alexis Rostoker for transcription.

References

1. Aminoff MJ: Vascular anomalies of the intracranial dura mater. **Brain** **96**:601-612, 1973
2. Awad IA, Little JR, Akrawi WP, et al: Intracranial dural arteriovenous malformations: factors predisposing to an aggressive neurological course. **J Neurosurg** **72**:839-850, 1990
3. Barnwell SL, Halbach VV, Higashida RT, et al: Complex dural arteriovenous fistulas. Results of combined endovascular and neurosurgical treatment in 16 patients. **J Neurosurg** **71**:352-358, 1989
4. Bitoh S, Arita N, Fujiwara M, et al: Dural arteriovenous malformation near the left sphenoparietal sinus. **Surg Neurol** **13**:345-349, 1980
5. Chandler HC Jr, Friedman WA: Successful radiosurgical treatment of a dural arteriovenous malformation. Case report. **Neurosurgery** **33**:139-142, 1993
6. Chaudhary MY, Sachdev VP, Cho SH, et al: Dural arteriovenous malformation of the major venous sinuses: an acquired lesion. **AJNR** **3**:13-19, 1982
7. Chen MN, Imaya H, Nakazawa S: [Four cases of intracranial AVM successfully treated with radiation therapy.] **No Shinkei Geka** **18**:1161-1166, 1990 (Jpn)
8. Ciminello VJ, Sachs E Jr: Arteriovenous malformations of the posterior fossa. **J Neurosurg** **19**:602-604, 1962
9. Debrun G, Chartres A: Infra- and supratentorial arteriovenous malformations. A general review. About 2 cases of spontaneous supratentorial arteriovenous malformations of the dura. **Neuroradiology** **3**:184-192, 1972
10. Fardoun R, Adam Y, Mercier P, et al: Tentorial arteriovenous malformation presenting as an intracerebral hematoma. Case report. **J Neurosurg** **55**:976-978, 1981
11. Grisoli F, Vincentelli F, Fuchs S, et al: Surgical treatment of tentorial arteriovenous malformations draining into the subarachnoid space. Report of four cases. **J Neurosurg** **60**:1059-1066, 1984
12. Halbach VV, Higashida RT, Hieshima GB, et al: Treatment of dural fistulas involving the deep cerebral venous system. **AJNR** **10**:393-399, 1989
13. Hand J, Shiino A, Kodooka M: Dural arteriovenous malformation of the tentorium. Report of a case and a review of the literature. **Nippon Geka Hokan** **57**:107-114, 1988
14. Houser OW, Campbell JK, Campbell RJ, et al: Arteriovenous malformation affecting the transverse dural sinus — an acquired lesion. **Mayo Clin Proc** **54**:651-661, 1979
15. Kaech D, de Tribolet N, Lasjaunias P: Anterior inferior cerebellar artery aneurysm, carotid bifurcation aneurysm, and dural arteriovenous malformations of the tentorium in the same patient. **Neurosurgery** **21**:575-582, 1987
16. Kosnick EJ, Hunt WE, Miller CA: Dural arteriovenous malformations. **J Neurosurg** **40**:322-329, 1974
17. Laine E, Galibert P, Lopez C, et al: Anéurysmes artérioveineux intra-duraux de la fosse postérieure. **Neurochirurgie** **9**:147-157, 1963
18. Lalwani AK, Dowd CF, Halbach VV: Grading venous restrictive disease in patients with dural arteriovenous fistulas of the transverse/sigmoid sinus. **J Neurosurg** **79**: 11-15, 1993
19. Lasjaunias P, Chiu M, Ter Brugge K, et al: Neurological manifestations of intracranial dural arteriovenous malfor-

Management of tentorial dural arteriovenous malformations

- mations. **J Neurosurg** 64:724–730, 1986
20. Lasjaunias P, Halimi P, Lopez-Ibor L, et al: Traitement endovasculaire des malformations vasculaires dures (MVD) pures "spontanées." Revue de 23 cas explorés et traités entre mai 1980 et octobre 1983. **Neurochirurgie** 30:207–223, 1983
 21. Malik GM, Pearce JE, Ausman JI, et al: Dural arteriovenous malformations and intracranial hemorrhage. **Neurosurgery** 15:332–339, 1984
 22. Martin NA, King WA, Wilson CB, et al: Management of dural arteriovenous malformations of the anterior cranial fossa. **J Neurosurg** 72:692–697, 1990
 23. Matsushima T, Suzuki SO, Fukui M, et al: Microsurgical anatomy of the tentorial sinuses. **J Neurosurg** 71:923–928, 1989
 24. Mayberg MR, Zimmerman C: Vein of Galen aneurysm associated with dural AVM and straight sinus thrombosis. Case report. **J Neurosurg** 68:288–291, 1988
 25. Miyagi K, Iwasa H, Yoshimizu N, et al: [Tentorial dural arteriovenous malformation — a case report.] **Neurol Surg** 4:1185–1191, 1976 (Jpn)
 26. Miyasaka K, Takei H, Nomura M, et al: Computerized tomography findings in dural arteriovenous malformations. Report of three cases. **J Neurosurg** 53:698–702, 1980
 27. Miyasaka Y, Yada K, Ohwada T, et al: An analysis of venous drainage system as factor in hemorrhage from arteriovenous malformations. **J Neurosurg** 76:239–243, 1992
 28. Newton TH, Weidner W, Greitz T: Dural arteriovenous malformation of the posterior fossa. **Radiology** 90:27–35, 1968
 29. Nishino A, Sakurai Y, Takahashi A, et al: [Superior petrosal sinus dural arteriovenous malformation with varix indenting the brain stem — review of a case and review of the literature.] **No To Shinkei** 43:62–69, 1991 (Jpn)
 30. O'Reilly GV, Hammerschlag SB, Ronthol M, et al: Case report. Aneurysmal dilatation of the Galenic venous system caused by a dural arteriovenous malformation. **J Comput Assist Tomogr** 5:899–903, 1981
 31. Partington MD, Rüfenacht DA, Marsh WR, et al: Cranial and sacral dural arteriovenous fistulas as a cause of myelopathy. **J Neurosurg** 76:615–622, 1992
 32. Picard L, Bracard S, Islak C, et al: Dural fistulae of the tentorium cerebelli. Radioanatomical, clinical and therapeutic considerations. **J Neuroradiol** 17:161–181, 1990
 33. Sawamura Y, Janzer RC, Fankhauser H, et al: Arteriovenous malformation in meningotheelial meningioma: case report. **Neurosurgery** 29:109–113, 1991
 34. Sundt TM Jr, Piepgras DG: The surgical approach to arteriovenous malformations of the lateral and sigmoid dural sinuses. **J Neurosurg** 59:32–39, 1983
 35. Tomsick TA, Tew JM Jr, Lukin RR, et al: Intracranial arteriovenous malformation with increased intracranial pressure: response to embolization, in Smith RR, Haerer AF, Russell WF (eds): **Vascular Malformations and Fistulas of the Brain**. New York: Raven Press, 1982, pp 119–127
 36. Viñuela F, Fox AJ, Pelz DM, et al: Unusual clinical manifestations of dural arteriovenous malformations. **J Neurosurg** 64:554–558, 1986
 37. Wrobel CJ, Oldfield EH, Di Chiro G, et al: Myelopathy due to intracranial dural arteriovenous fistulas draining intrathecally into spinal medullary veins. Report of three cases. **J Neurosurg** 69:934–939, 1988
 38. Yamada F, Fukuda S, Matsumoto K, et al: [Effect of radiotherapy on dural arteriovenous malformation. Long-term follow-up study and clinical evaluation.] **Neurol Med Chir** 24:591–599, 1984 (Jpn)

Manuscript received September 7, 1993.

Accepted in final form May 5, 1994.

Address reprint requests to: Adam I. Lewis, M.D., Department of Neurosurgery, University of Cincinnati College of Medicine, 231 Bethesda Avenue, Cincinnati, Ohio 45267-0515.