

Brief Report

Vascular Chorea: Case Report with Pathology

Kailash P. Bhatia, Gabriel Lera, *Philip J. Luthert, and C. David Marsden

*University Department of Clinical Neurology, Institute of Neurology, and *Department of Neuropathology, Institute of Psychiatry, London, England*

Summary: We report a patient with long-standing systemic hypertension who developed progressive generalized chorea and dementia beginning at 70 years of age with no family history or other features to suggest Huntington's disease. At postmortem examination, congophilic angiopathy and atherosclerosis causing neostriatal neuronal loss and gliosis were found, in addition to plaques and neurofibrillary tangles in the cortex. This case is a rare demonstration of a vascular pathology causing late onset generalized chorea in association with dementia due to Alzheimer's-type cortical changes. **Key Words:** Generalized chorea—Dementia—Vascular pathology.

Hemichorea and hemiballism are known to occur with contralateral ischemic infarcts involving the striatum, either proven on autopsy (1,2) or documented in life by computed tomography (CT) and/or magnetic resonance imaging (MRI) brain scan (3). Vascular disease affecting the basal ganglia is included in most lists of causes of generalized chorea (4,5), but proven cases are difficult to find (6-8). In all three reports there was an acute onset of the chorea and bilateral involvement of striatal structures. Two of these patients were shown to have lacunar lesions in the basal ganglia at autopsy (7,8), whereas the other had lacunes in the basal ganglia on MRI (6). The patient described by Tabaton et al. (6) recovered in 5 months with no specific treatment, whereas the patient described by Sethi et al. (7) continued to have choreic movements up to 1 year after onset, when she died of a cardiac cause. The patient described by Folstein et al. (8) had dementia in addition to generalized chorea and was found on autopsy to have small infarcts in the striatum that had not been detected on CT scan.

To our knowledge, chronic progressive generalized chorea due to cerebrovascular disease has not been previously documented.

CASE REPORT

An 85-year-old woman developed gradual cognitive decline beginning with apathy and inability to cope with housework at 70 years of age. She was thought to be depressed and was treated with imipramine for a few months with some benefit. Six years later she developed involuntary movements and an increasing memory deficit and sustained many falls. When seen at 78 years of age in 1977 by one of us (C.D.M.), she had generalized chorea and dementia. She had not taken any other drugs. She worsened over the next years, and her speech became incomprehensible. In 1982 she was severely cognitively impaired, the mini-mental test score being 2/30, and she could not read or write. Her speech was slow but fluent, and the content was appropriate. Her gait was slow, broad based, and irregular. Eye movements were normal for her age. She had generalized chorea. There were no other neurological abnormalities on examination. Investigations showed a normal blood count, with no acanthocytes, and normal serum biochemistry except

Address correspondence and reprint requests to Professor C. D. Marsden, Institute of Neurology, Queen Square, London WC1N 3BG, England.

for raised cholesterol levels. Thyroid function tests indicated hypothyroidism with positive cytoplasmic antithyroid autoantibodies. A CT scan showed an incidental small calcified falx meningioma without mass effect or edema, as well as some cerebral atrophy. Results of an electrocardiogram were abnormal, indicating an old anteroseptal myocardial infarction. She was one of 13 siblings, none of whom were known to have involuntary movements, although one sister had become confused and forgetful at a late age. Both her parents had died in their late 60s with no neurological disorder. She had three normal children.

She was treated with thyroid replacement therapy, but continued to decline cognitively. A year before she died in 1985, she was grossly demented and had an orofacial dyskinesia and choreiform movements, mainly of the upper limbs, tongue, and neck. Her gait was staggering, broad based, and slow, and she tended to fall. Her speech was slurred and slow. There was a full range of eye movements. The limb tone and power was normal, the deep tendon reflexes brisk, and the plantar responses flexor. There were no sensory or cerebellar signs. She had moderate hypertension for many years. A repeat CT scan showed no change in the size of the falx meningioma. She died a year later after a chest infection, and a postmortem examination was performed.

Macroscopic Examination of the Brain

The unfixed brain weighed 850 g. There was generalized atrophy with widening of the sulci, especially over the frontal and parietal regions. There was an anterior falx meningioma 1 cm in diameter. Slicing showed massive dilatation of the lateral ventricle (Fig. 1) and *état lacunaire* (9) of the basal gan-

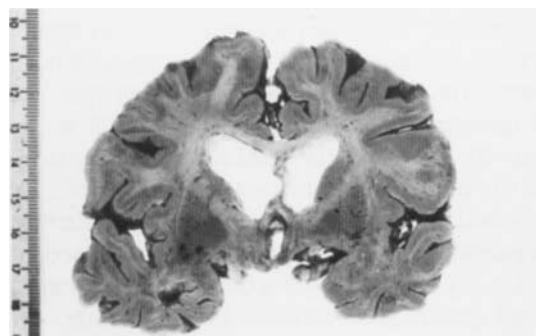


FIG. 1. Coronal slice of the cerebral hemispheres showing enlargement of the ventricles and sulcal widening. Note the preserved contour of the head of the caudate.

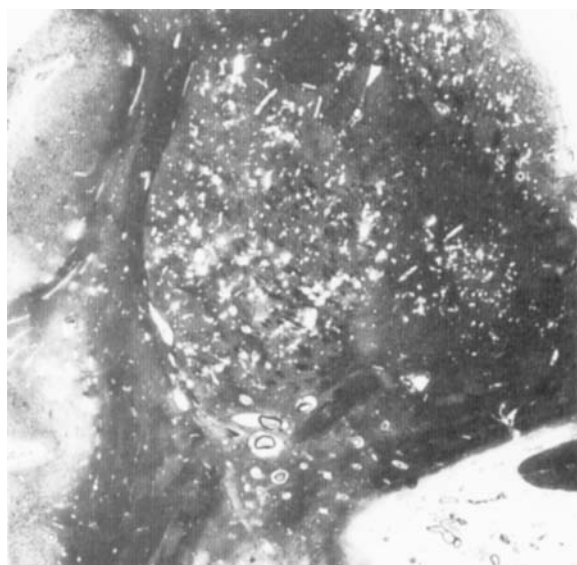


FIG. 2. Macroscopic photograph of a 2 × 2-cm portion of a section of the striatum and adjacent structures impregnated with silver according to Gleees and Marsland. The caudate (top right) is separated from the putamen (center) by the internal capsule. Note the numerous "holes" within the deep grey matter.

glia [seen clearly in a low-power micrograph of a histological section (Fig. 2)]. The arteries at the base of the brain were widely patent, with moderate atheroma.

Microscopic Examination of the Central Nervous System

The caudate and lentiform nuclei showed severe, widespread fibrillary gliosis and moderate neuronal loss without relative preservation of either small or large neurons. There were numerous, large perivascular spaces giving a lacelike appearance to the tissue (Fig. 3). Many of these spaces contained thick or thin-walled vessels. Congophilic angiopathy, as determined by Congo red staining and positive β A4 immunohistochemistry was a feature of meningeal vessels and penetrating arterioles. Dyschoric amyloid, that is, amyloid extending into the cerebral parenchyma, was noted in relation to capillaries, signifying relatively severe angiopathy. However, there was no β A4 deposition in vessels of the basal ganglia. Walls of meningeal arteries often contained plaques of atheroma, and arteriolosclerosis was evident.

Plaques and neurofibrillary tangles were plentiful throughout most of the neocortex and hippocampus and neurofibrillary tangles were also seen in the locus coeruleus and raphé nuclei. One small cortical

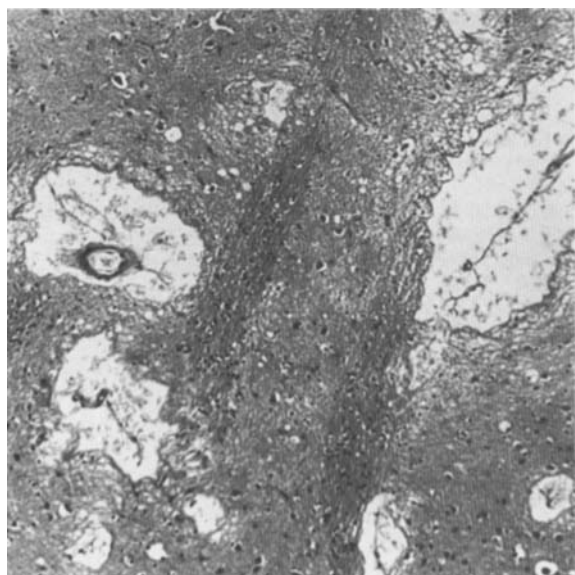


FIG. 3. Photomicrograph of an $\sim 2 \times 2$ -mm portion of striatum showing enlarged perivascular spaces containing amorphous material (hematoxylin and eosin).

scar was seen, and in one instance, patchy gliosis was associated with a perivascular ring of iron pigment. Much of the subcortical white matter throughout both cerebral hemispheres was mildly gliotic.

A small scar was seen in the cortex of the cerebellum, and leptomeningeal vessels here also showed congophilic change. The dentate, red, and subthalamic nuclei all appeared normal, as did the substantia nigra.

Examination of Other Organs

The thyroid gland showed microscopic changes of fibrosis and distortion of the follicular pattern and lymphocyte infiltrate associated with follicular destruction consistent with Hashimoto's thyroiditis.

The lungs showed bronchopneumonic changes, but the heart and other organs were unremarkable and there was no evidence of amyloid deposition outside the brain.

DISCUSSION

This patient, who had a long history of systemic hypertension, developed progressive intellectual decline at 70 years of age followed a few years later by generalized chorea. Huntington's disease was the considered initial diagnosis, but there was no family history and the eye movements were normal even late in the disease. She continued to dement

despite adequate thyroid replacement therapy for incidental hypothyroidism. There also was an incidental small falx meningioma, which was not thought to contribute to either the dementia or the chorea.

Other causes of chorea in the elderly, namely drugs, metabolic and endocrine disorders, neuroanthocytosis, polycythemia rubra vera, lupus erythematosus, infections, intoxications, trauma, and tumors, were considered and ruled out by the history, clinical features, and appropriate investigations.

The neuropathology in this case showed sufficient plaque and tangle formation in the neocortex to make the diagnosis of Alzheimer's disease, given the history of dementia. However, much of the pathology seems to have a vascular basis. Congophilic angiopathy, as part of her Alzheimer's disease, appears to have contributed to the cortical damage and also may have contributed to the white matter gliosis (10). Given the absence of congophilic angiopathy in the basal ganglia, it seems likely that the changes here were due to atheroma and hypertensive arteriolar changes, although congophilic angiopathy in meningeal vessels may have been a contributing factor. To exclude Huntington's disease with total confidence by neuropathological investigation alone is not possible because some rare, well-documented cases of Huntington's disease have no discernable histopathology (11). However, Huntington's disease seems implausible in this case. The clinical features were not typical of this condition, and selective loss of small neurons in the basal ganglia was not seen. There was an entirely sufficient explanation for the deep grey matter pathology in the form of significant vascular disease.

In conclusion, vascular disease may rarely be the cause of sporadic senile chorea, although careful investigation of such cases more often than not shows Huntington's disease (12).

REFERENCES

1. Austregesilo A, Galloti O. Sur un cas d'hémiplégie et d'hémichorée avec lésion du noyau caudé. *Rev Neurol* 1924; 1:41-43.
2. Martin JP. Hemichorea (hemiballismus) without lesions in the corpus Luysii. *Brain* 1957;80:1-10.
3. Saris S. Chorea caused by caudate infarction. *Arch Neurol* 1983;40:590-591.
4. Purdon Martin J. Choreatic syndromes: In: Vinken PS, Bruyn GW, eds. *Handbook of clinical neurology*. Vol. 6. Amsterdam, The Netherlands: Elsevier/North Holland, 1968:435-439.
5. Weiner WJ, Lang AE. Huntington's disease. In: Weiner

- WJ, Lang AE, eds. *Movement disorders, a comprehensive survey*. New York: Futura, 1989:293-346.
6. Tabaton M, Mancardi G, Loeb C. Generalised chorea due to bilateral small deep cerebral infarcts. *Neurology* 1985;35: 588-589.
 7. Sethi KD, Nichols FT, Yaghami F. Generalised chorea due to basal ganglia lacunar infarcts. *Mov Disord* 1987;2:61-66.
 8. Folstein S, Abbott M, Moses R, Parlad I, Clark A, Folstein M. A phenocopy of Huntington's disease: lacunar infarcts of the corpus striatum. *Johns Hopkins Med J* 1981;148:104-113.
 9. Graham DI. Hypoxia and cerebrovascular disorders. In: Hume Adams J, Duchon LW, eds. *Greenfields neuropathology*. London: Edward Arnold/London, 1992:214.
 10. Gray F, Dubas F, Roullet E, Escourrolle R. Leukoencephalopathy in diffuse hemorrhagic cerebral amyloid angiopathy. *Ann Neurol* 1985;18:54-59.
 11. Richardson EP. Huntington's disease: some recent neuropathological studies. *Neuropathol Appl Neurobiol* 1990;16: 451-460.
 12. Bateman D, Boughey AM, Nurs B, Scaravilli F, Marsden CD, Harding AE. A follow-up study of isolated cases of suspected Huntington's disease. *Ann Neurol* 1992;31:293-298.