

## Writing Tremor After Discrete Cortical Infarction

Jong S. Kim, MD; Myoung C. Lee, MD

**Background** Hand tremor is a rare manifestation of stroke, and writing tremor has not been reported to be produced by stroke. We describe a patient who developed a unilateral hand tremor mimicking primary writing tremor after discrete cerebral cortical infarction.

**Case Description** A 67-year-old man developed mild right hemiparesis. Brain magnetic resonance imaging showed a discrete cortical infarct in the left frontal area. After recovery of motor power, the patient showed significant right hand tremor exclusively during writing or similar motor activities including tooth brushing or shaving. The tremor was tempo-

rarily alleviated by clonazepam but persisted until 7 months of follow-up. Medical history suggested that the patient had mild essential tremor, but he did not experience tremor on writing before the onset of stroke.

**Conclusions** This observation suggests that unilateral hand tremor mimicking primary writing tremor may be produced by cortical infarction. It remains unclear whether the patient's previous essential tremor played an additional role in the development of this symptom. (*Stroke*. 1994;25:2280-2282.)

**Key Words** • cerebral infarction • tremor

Recently hand or hemibody tremor was reported to be produced by stroke.<sup>1-3</sup> However, to our knowledge, writing tremor (WT) has not been reported to be caused by stroke. We describe a patient who developed unilateral hand tremor mimicking primary WT after discrete cortical infarction.

### Case Report

A 67-year-old hypertensive right-handed man developed sudden, mild, right hemiparesis during lunch. Medical history revealed that he had coronary heart disease with repeated episodes of angina pectoris and had used aspirin, a calcium channel blocker (amlodipine besylate), and isosorbide-5-mononitrate for 3 months. He was a retired government official and had been writing normally before this episode (documented from his handwriting written a few weeks before the event). He denied having any resting or action tremor, but his wife stated that she had observed occasional mild hand tremor when he used his hands. The motor power of his right extremities improved on the way to the emergency department.

At the emergency department the patient's initial blood pressure was 180/95 mm Hg, and the results of neurological examination were normal except for minimal weakness of the right hand. The motor power of his hand normalized the next day. The patient was heparinized for 2 days before being placed back on his previous medications. Brain computed tomographic scan performed the day of admission did not show any abnormalities. Brain magnetic resonance imaging was obtained 3 days after admission and showed a discrete cortical infarct in the left frontal lobe between the

precentral and central sulci (Fig 1). The numerous small high signal intensities seen in the centrum semiovale were considered clinically insignificant. Echocardiogram did not show evidence of thrombus formation, and carotid Doppler scan showed findings suggestive of multifocal atheromatous plaque in both common carotid arteries and the left proximal internal carotid artery. Angiogram was refused by the patient.

During 7 days of admission, the patient noticed that he had difficulties in tooth brushing because of hand tremor. The patient thought this symptom was due to the arm weakness, and detailed tests for the tremor were not performed at that time. On follow-up visit 3 weeks after the initial episode, neurological examination including motor power and sensory function of all modalities was normal. No spasticity or ataxia was noted in the right extremities. The patient stated that he persistently experienced bursts of right hand tremor during tooth brushing or shaving, necessitating the use of both hands. A similar degree of tremor also occurred when he used a screwdriver or mixed foods. He was able to eat or drink with his right hand but had short bursts of tremor when he lifted food to his mouth. The hand tremor, however, was most marked during writing, which was exacerbated on writing fast, when intermittent jerky, myoclonic hand movements were added (Fig 2). He had no tremor when writing with his left hand. Transient, coarse hand tremor of 4 to 5 Hz was also noted when the patient fully pronated or supinated his right forearm with his elbow flexed. There was no resting hand tremor or cogwheel rigidity in the hands. On stretching the arms, very mild postural finger tremor was noted bilaterally, which was accentuated during terminal movements on the finger-to-nose test. However, he was able to carry a cup full of water without difficulty with his right arm.

The patient was given an anticholinergic (trihexylphenidine), which was not tolerated because of development of dry mouth and confusion. Clonazepam 0.5

Received June 20, 1994; final revision received August 1, 1994; accepted August 1, 1994.

From the Department of Neurology, University of Ulsan, Asan Medical Center, Seoul, South Korea.

Correspondence to Jong S. Kim, MD, Department of Neurology, Asan Medical Center, Song-Pa, PO Box 145, Seoul 138-600, Korea.

© 1994 American Heart Association, Inc.

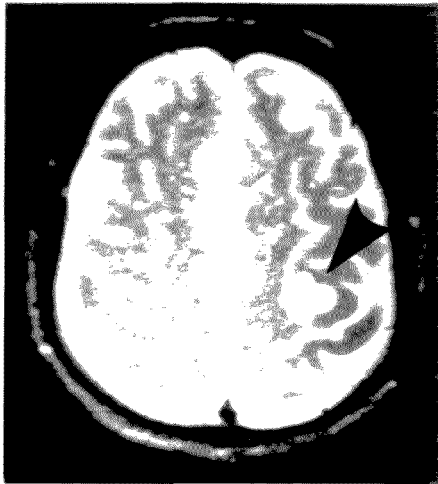

FIG 1. T<sub>2</sub>-weighted magnetic resonance image shows discrete cortical infarct in left frontal area (arrowhead).

mg three times a day relieved the tremor markedly, although mild WT was still observed (Fig 2). However, he complained of somnolence and took medication irregularly. The WT persisted, although slightly diminished in severity, at 7 months of follow-up.

### Discussion

Primary WT is a task-specific tremor mainly induced by the act of writing or similar motor activities.<sup>4-8</sup> Our patient developed unilateral hand tremor most markedly during writing but also during active movements involving pronation of the right forearm. During writing, jerky, myoclonic hand movements, symptoms commonly seen in patients with primary WT,<sup>4,7</sup> were occasionally added. However, dystonic hand posture was never observed in this patient. Therefore, the characteristics of the patient's tremor are similar to those of primary WT.

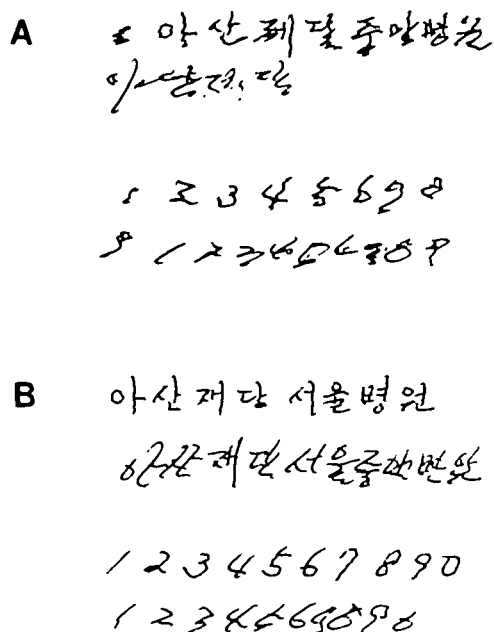


FIG 2. Handwriting of the patient before (A) and after (B) clonazepam medication. Upper rows, Normal writing; lower rows, fast writing.

Despite occasional unilateral clinical presentations,<sup>5</sup> most of the reported patients with WT did not have any cerebral lesions that were responsible for the tremor, although a few patients had a seemingly unrelated history of meningitis<sup>4</sup> or perinatal hypoxia.<sup>5</sup> Our patient is the first who developed unilateral WT after cerebral infarction. Although there have been a few reports of stroke-related tremor, these were delayed-onset resting<sup>1-3</sup> or postural<sup>3</sup> hand tremors caused by basal ganglionic<sup>1,2</sup> or thalamic<sup>1,3</sup> infarcts. Our patient was unique in that he presented with task-specific tremor after an infarct in the cortical area. The cause of the infarction in this patient remains unclear, although embolism was suggested as a possible pathogenetic mechanism.

The pathogenetic mechanism of primary WT remains obscure, and that of WT shown in this patient also remains speculative. Rothwell et al<sup>4</sup> found that WT was temporarily abolished by partial motor point anesthesia of pronator teres in their patient and suggested that abnormal responses to muscle spindle input from pronator teres may be responsible for primary WT. In our patient unilateral hand tremor was noted during tooth brushing soon after the patient's motor weakness improved. Unfortunately, writing was not tested at that time, and we do not know the exact time interval between the onset of stroke and development of WT. Brain magnetic resonance imaging showed that the lesion was situated on the frontal cortex between the central and precentral sulci,<sup>9</sup> a portion of Brodmann's area 4 that probably represents hand area. According to previous experiments with monkeys, there are substantial interconnections and feedback systems between sensory and motor areas in the sensorimotor cortex.<sup>10</sup> Group 1 muscle afferents reach to area 3a in advance of similar sensory evoked responses in area 4, and perturbations of muscle spindle discharge during the performance of learned movements in conscious monkeys affect the neurons of the motor cortex.<sup>11</sup> Jones et al<sup>10</sup> even suggested that area 3a may be a part of area 4. Therefore, it may be speculated that the discrete lesion in our patient may have interrupted or reset the spindle impulses to area 3a or 4, and consequent alterations of motor discharges might have manifested as WT in our patient. Alternatively, the cortical lesion in this patient might have affected cerebellothalamocortical or fronto-pontocerebellar circuits. However, this possibility appears unlikely since our patient did not show ataxia in the right extremity.

Considering the patient's history and examination, it appears that this patient had essential tremor before the onset of stroke. However, the patient's bilateral postural hand tremor was very mild, and the unilateral, coarse hand tremor developed after the stroke was clearly task specific. Therefore, the patient's WT should not be a simple exaggeration of the previous essential tremor. However, it remains possible that the cortical infarct may somehow have altered the characteristics of essential tremor, thus producing WT in the right hand. Whatever the actual explanation, the patient presented here, along with our previously reported cases,<sup>1</sup> suggests that strategically located minor strokes may modulate the sensorimotor circuitry and produce movement disorders. Our case also suggests that development of unilateral WT in elderly patients may require imaging studies.

## References

1. Kim JS. Delayed onset hand tremor caused by cerebral infarction. *Stroke*. 1992;23:292-294.
2. Dethy S, Luxen A, Bidaut LM, Goldman S. Hemibody tremor related to stroke. *Stroke*. 1993;24:2094-2096.
3. Ferbert A, Gerwig M. Tremor due to stroke. *Mov Disord*. 1993;8:179-182.
4. Rothwell JC, Traub MM, Marsden CD. Primary writing tremor. *J Neurol Neurosurg Psychiatry*. 1979;42:1106-1114.
5. Klawans HL, Glantz R, Tanner CM, Goetz CG. Primary writing tremor: a selective action tremor. *Neurology*. 1982;32:203-206.
6. Kachi T, Rothwell JC, Cowan JMA, Marsden CD. Writing tremor: its relationship to benign essential tremor. *J Neurol Neurosurg Psychiatry*. 1985;48:545-550.
7. Ravits J, Hallett M, Baker M, Wilkins D. Primary writing tremor and myoclonic writer's cramp. *Neurology*. 1985;35:1387-1391.
8. Elble RJ, Koller WC. *Tremor*. Baltimore, Md: Johns Hopkins University Press; 1990:146-150.
9. Sobel DF, Gallen CC, Schwartz BJ, Waltz TA, Copeland B, Yamada S, Hirschko EC, Bloom FE. Localizing the central sulcus: comparison of MR anatomic and magnetoencephalographic functional methods. *Am J Neuroradiol*. 1993;14:915-925.
10. Jones EG, Coulter JD, Hendry HC. Intracortical connectivity of architectonic fields in the somatic sensory, motor and parietal cortex of monkeys. *J Comp Neurol*. 1978;181:291-348.
11. Evarts EV, Tanji J. Reflex and intended responses in motor cortex pyramidal tract neurons of monkey. *J Neurophysiol*. 1976;39:1069-1080.

## Writing tremor after discrete cortical infarction.

J S Kim and M C Lee

*Stroke*. 1994;25:2280-2282

doi: 10.1161/01.STR.25.11.2280

*Stroke* is published by the American Heart Association, 7272 Greenville Avenue, Dallas, TX 75231

Copyright © 1994 American Heart Association, Inc. All rights reserved.

Print ISSN: 0039-2499. Online ISSN: 1524-4628

The online version of this article, along with updated information and services, is located on the  
World Wide Web at:

<http://stroke.ahajournals.org/content/25/11/2280>

**Permissions:** Requests for permissions to reproduce figures, tables, or portions of articles originally published in *Stroke* can be obtained via RightsLink, a service of the Copyright Clearance Center, not the Editorial Office. Once the online version of the published article for which permission is being requested is located, click Request Permissions in the middle column of the Web page under Services. Further information about this process is available in the [Permissions and Rights Question and Answer](#) document.

**Reprints:** Information about reprints can be found online at:  
<http://www.lww.com/reprints>

**Subscriptions:** Information about subscribing to *Stroke* is online at:  
<http://stroke.ahajournals.org/subscriptions/>