

Brief Communication

Intractable Complex Partial Seizures Associated with Posterior Cerebral Artery Giant Aneurysm: A Case Report

Elza M. T. Yacubian, Sérgio Rosemberg, Helga C. A. da Silva, Carmen L. Jorge, Evandro de Oliveira, and Luís Marques de Assis

Departments of Neurology, Neurosurgery, and Pathology, Neuropathology Division, University of São Paulo School of Medicine, São Paulo, Brazil

Summary: Giant aneurysms have rarely been reported in association with intractable complex partial seizures (CPS). We report a 30-year-old man with intractable CPS since age 18 years. Seizure onset was electrically localized to right temporal lobe. Preoperative neuroimaging studies showed a partially thrombosed giant aneurysm of the right posterior cerebral artery. Selective amygdalo-

hippampectomy and occlusion of the posterior cerebral artery did not cause deficits. The patient has been seizure-free for 15 months after operation. We review the relevant literature on aneurysms as a cause of epilepsy. **Key Words:** Epilepsy—Complex partial seizures—Giant aneurysm—Hemosiderosis—Amygdalohippampectomy.

In a population-based study, Annegers (1993) reported that the etiology in ~70% of the cases of epilepsy was unknown and for the remaining were as follows: cerebrovascular disease 13.2%, developmental disorders 5.5%, head trauma 4.1%, brain tumors 3.6%, CNS infections 2.6%, degenerative CNS diseases 1.8%, and other causes 0.5%. In a specialized neurology service, recognized etiologic factors were detected in 44% of epileptic patients, excluding hereditary seizures and symptomatic neoplastic epilepsy (Bergamini et al., 1977). The most frequent causes were birth injuries (17.8%), craniocerebral trauma (12.2%), infections (11.9%), and CNS malformations and congenital metabolic encephalopathies (1.8%) (Bergamini et al., 1977). Swartz et al. (1992) demonstrated neuropathologic alterations in 93% of hippocampi in temporal lobe epilepsy. Cerebral aneurysms have rarely been reported in association with temporal lobe epilepsy. In a survey of 666 patients with this type of epilepsy, Currie et al. (1971) reported structural abnormalities in 169; only 1 had an aneurysm in the middle cerebral artery. In some large series of giant unruptured intracranial aneurysms (Locksley,

1966a,b; Morley and Barr, 1969; Drake, 1979; Hosobuchi, 1985; Liang-fu and Da-jie, 1987; Battaglia et al., 1988) the main signs and symptoms were related to bleeding or mass lesion. We report a 30-year-old man with a 12-year history of intractable complex partial seizures (CPS) who was diagnosed as having a giant cerebral aneurysm of the posterior cerebral artery, review the relevant literature on aneurysms as a cause of epilepsy, and discuss the possible pathogenetic mechanisms.

CASE REPORT

A 30-year-old man was admitted to the hospital because of intractable CPS. When he was 15 years old, he complained of episodes of diplopia and dizziness when he turned his head. At age 17 years, after physical exercise, he experienced an episode of headache, tonic posture of the limbs, vomiting, and loss of urine. The headache persisted for 7 days, when he had a generalized tonic-clonic seizure (GTC). One year later, he began having recurrent spells (two or three times each day) characterized by loss of breathing, sialorrhea followed by impairment of consciousness, and oral automatisms. During sleep, frequent GTC occurred. Despite treatment with 1,400 mg carbamazepine, 300 mg phenytoin (PHT), and 10 mg clobazam daily, he experienced ~ 12 CPS a month.

General and neurologic examinations were nor-

Received March 1993; revision accepted November 1993.

Address correspondence and reprint requests to Dr. E. Márcia Targas Yacubian at Department of Neurology do H.C.F.M.U.S.P., Av. Dr. Eneas de Carvalho Aguiar 255, Instituto Central-Sala 5011-A, 05403-São Paulo, São Paulo, Brazil.

mal. Routine laboratory tests were negative. Videotelemetered interictal scalp/zygomatic EEG recording showed bursts of theta activity mixed with sharp discharges over the right mesiobasotemporal region, and during the usual seizure the EEG showed rhythmic 4–6-HZ sharp wave activity initially recorded on the right zygomatic electrode. Computed tomography showed a small calcification in the ambiens cistern on the right side. Magnetic resonance imaging (Figs. 1 and 2) disclosed a spherical mass measuring 2.5 cm in diameter at the ambiens cistern, which compressed the right cerebral peduncle and the right hippocampal formation. Axial spin-echo T2-weighted MRI showed a partially thrombosed aneurysm with central high signal intensity, which presumably represented methemoglobin and a peripheral ring of low signal intensity consistent with hemosiderin deposition. A lower intensity signal on the medial aspect consistent with a patent lumen signal void was also observed. Cerebral angiography showed a partially thrombosed saccular aneurysm at the origin of the right posterior cerebral artery (Fig. 3). Selective amygdalohippocampotomy and occlusion of the posterior cerebral artery proximal to the aneurysm were performed. Pathologic findings included severe neuronal loss, gliosis, and abundant macrophages with hemosider-

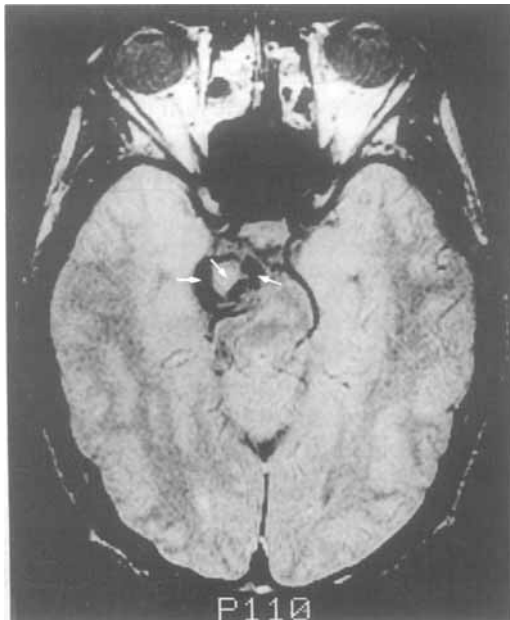

FIG. 1. Proton density image of partially thrombosed giant aneurysm of right cerebral posterior artery showing heterogeneous signal intensity. Central high signal intensity presumably represents methemoglobin, and the low signal intensity peripheral ring is consistent with hemosiderin deposition, except in the medial aspect of the aneurysm, where a lower intensity signal represents the patent lumen signal void (arrows).

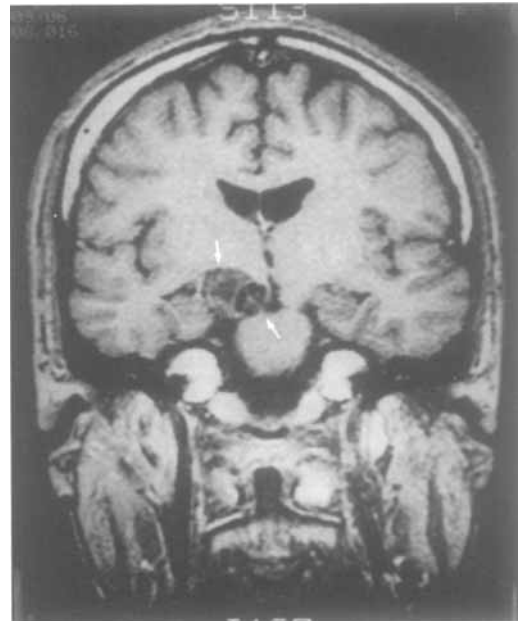


FIG. 2. Coronal T1-weighted magnetic resonance imaging. The patent lumen is evident as a signal void in the medial part of the aneurysm, which compresses the right cerebral peduncle (arrows). The thrombosed part of the aneurysm is apparent laterally, deviating and compressing the right hippocampal formation (arrows).

in. The patient has been followed for 15 months and has been seizure-free since the operation. He is treated with 300 mg PHT daily.

DISCUSSION

Giant intracranial aneurysms, which are aneurysms > 2.5 cm in diameter, usually present with clinical signs of subarachnoid hemorrhage or mass lesion leading to chronic headache, visual disturbance, or cranial nerve palsies (Hosobuchi, 1985).

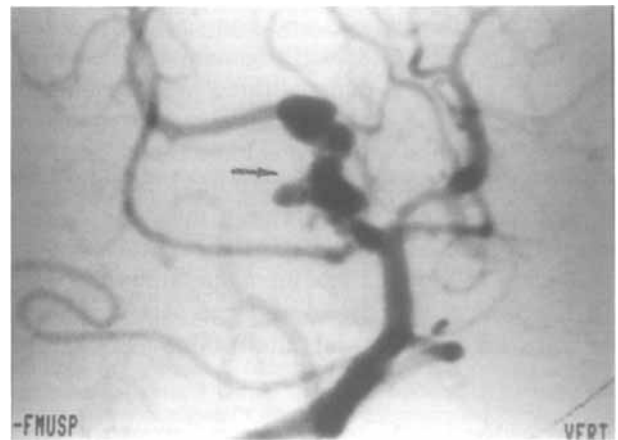


FIG. 3. Vertebrobasilar arteriogram shows in right cerebral posterior artery the vertically oriented residual patent lumen of the giant aneurysm (arrow). The thrombosed portion of the aneurysm is not documented by the arteriogram.

When a patient has epileptic seizures, the possibility of an intracranial aneurysm is rarely raised. Only 4% of the 2,621 patients reported by Locksley (1966a) who had a first subarachnoid hemorrhage had epilepsy before bleeding. In 151 cases of unruptured aneurysms, epilepsy was detected in 36% of the middle cerebral and 8% of the posterior communicating cerebral artery (Locksley, 1966b), although the characteristics of the seizures were not described.

In a series of 28 patients with giant aneurysms reported by Morley et al. (1969), 3 had epilepsy. Two of them had seizures for many years before undergoing successful operation for the aneurysm. In all, the aneurysms were located at the middle cerebral artery. In this series, there were no posterior cerebral artery aneurysms, probably because of their precocious tendency to rupture.

Liang-fu and Da-jie (1987) reported epilepsy in 2 of 21 cases of giant aneurysms, both located at the middle cerebral artery. Sengupta et al. (1978) described 6 cases of epilepsy and aneurysms. The interval between onset of seizures and diagnosis varied from 1 day to 30 years. Five patients had partial seizures (1 focal motor, 1 versive, 1 psychic, 1 vertiginous, 1 CPS with automatism) and 1 had GTC. In all patients, the aneurysms were located at the middle cerebral artery. EEG in 4 patients showed temporal lobe foci. Five patients who underwent operation with obliteration of the aneurysms were seizure-free, although they continued to be treated with antiepileptic drugs (AEDs). The only patient who was not operated on because epilepsy was the only complaint died six months later of severe subarachnoid hemorrhage. Liang-fu and Da-jie (1987) reported that although the mechanism of epilepsy due to intracranial aneurysm is not known, in 2 of their patients the calcified walls of the aneurysms might have acted as hamartomas, causing epilepsy. Another possibility is that aneurysms may leak without producing clinical manifestations of subarachnoid hemorrhage. These minor leakages may produce localized damage to brain and cause an epileptogenic focus. Whittle et al. (1985) described 4 patients with CPS for several years who were shown to have giant aneurysms of the middle cerebral artery. None had a history of subarachnoid hemorrhage. Operative findings included compression of mesiotemporal cortex and evidence of previous hemorrhage from the aneurysms. In 2 patients, clipping of the aneurysm with decompression of the adjacent temporal lobe cured the seizure disorder. In the other 2 patients, the aneurysms could only be wrapped and the seizures continued. Leibrok et al. (1983) reported a patient with auto-

nomic partial seizures followed by GTC owing to a thrombosed basilar artery apex aneurysm. They postulated that emboli from this aneurysm traveled through the posterior cerebral artery and its branches to the temporal lobe, with resultant microinfarction and subsequent development of an epileptogenic focus.

Our patient showed strong evidence of a relation between epilepsy and giant aneurysm of the posterior cerebral artery. Clinically, onset of the seizures occurred 1 year after an acute episode characterized by sudden headache followed by vomiting, tonic posture of the limbs, and loss of urine, which might have been consecutive to bleeding. Hosobuchi (1985) reports that patients with giant aneurysms who do not present with recent subarachnoid hemorrhage show evidence of a more remote history of bleeding that probably occurred when the aneurysm was smaller.

Whether patients with a temporal lobe lesion should undergo removal of hippocampus in addition to resection of the lesion is still controversial. Added to the uncertainty about the role of hippocampus in generation of seizures in such patients is the concern about the neuropsychologic sequelae, especially with regard to memory function after resection of a healthy hippocampus (Fried et al., 1992). Fried et al. (1992) suggested that patients with mesiotemporal lesions and a history of early seizure onset have profound cell loss in all hippocampal fields except CA2 and that this structure therefore may be included in the resection. During the surgical procedure, we noted that aneurysm walls and the mesiotemporal lobe structures were yellow; we then performed selective amygdalohippocampectomy.

The neuropathologic examination in our case confirmed the findings of Fried et al. (1992): There was severe neuronal loss and signs of old bleeding characterized by the presence of numerous macrophages with hemosiderin in the mesiotemporal lobe. Recurrent slight bleeding without clinical manifestations of subarachnoid hemorrhage as reported by Sengupta et al. (1978) also may have provoked localized brain damage acting as an epileptogenic focus.

Willmore et al. (1978) demonstrated that injection of ferrous or ferric chloride into rat or cat sensorimotor cortex resulted in recurrent focal paroxysmal EEG discharges as well as behavioral convulsions and electrical seizures. The pathologic findings included iron-filled macrophages, ferruginated neurons, and astroglial cells. Willmore et al., (1978) postulated that neurochemical alterations induced by the main metallic ions in whole blood could be

responsible for development of human posttraumatic epilepsy. Although Lange et al. (1980) could not confirm this model of chronic epilepsy in cats, our case suggests that bleeding may have elicited an epileptogenic focus. Compression of the giant aneurysm against the hippocampus is another possible mechanism (Stewart et al., 1980), associated or not with the previous mechanism. Whatever the mechanism, giant intracranial aneurysms, although constituting only a few of the possible etiologic agents, might be considered in temporal lobe epilepsy.

REFERENCES

- Annegers JF. The epidemiology of epilepsy. In: Wyllie E, ed. *The treatment of epilepsies: principles and practice*. Philadelphia: Lea & Febiger, 1993:157-64.
- Battaglia R, Pasqualin A, Da Pian R. Italian cooperative study on giant intracranial aneurysms: 1. Study design and clinical data. *Acta Neurochirurg* 1988;42P:49-52.
- Bergamini L, Bergamasco B, Benna P, Gilli M. Acquired etiological factors in 1,785 epileptic subjects: clinical anamnestic research. *Epilepsia* 1977;18:437-44.
- Currie S, Heathfield KWG, Henson RA, Scott DF. Clinical course and prognosis of temporal lobe epilepsy. A survey of 666 patients. *Brain* 1971;94:173-90.
- Drake CG. Giant intracranial aneurysms: experience with surgical treatment in 174 patients. *Clin Neurosurg* 1979;26:12-95.
- Fried I, Jung KH, Spencer DD. Hippocampal pathology in patients with intractable seizures and temporal lobe masses. *J Neurosurg* 1992;76:735-40.
- Hosobuchi Y. Giant intracranial aneurysms. In: Wilkins RH, Rengachary SS, eds. *Neurosurgery*. New York: McGraw Hill, 1985:1404-14.
- Lange SC, Neafsey EJ, Wyler AR. Neuronal activity in chronic ferric chloride epileptic foci in cats and monkey. *Epilepsia* 1980;21:251-4.
- Leibrok LG, Bennett D, Bloch S. Complex partial seizures associated with unruptured thrombosed basilar artery apex aneurysm. *Surg Neurol* 1983;19:17-20.
- Liang-fu Z, Da-jie J. Large and giant intracranial aneurysms—diagnosis and surgical treatment. *Chin Med J* 1987;100:392-7.
- Locksley HB. Report on the cooperative study of intracranial aneurysms and subarachnoid hemorrhage: natural history of subarachnoid haemorrhage, intracranial aneurysms and arteriovenous malformations. *J Neurosurg* 1966a;25:219-39.
- Locksley HB. Report on the cooperative study of intracranial aneurysms and subarachnoid hemorrhage: natural history of subarachnoid hemorrhage, intracranial aneurysms and arteriovenous malformations. *J Neurosurg* 1966b;25:321-68.
- Morley TP, Barr HWK. Giant intracranial aneurysms: diagnosis, course and management. *Clin Neurosurg* 1969;16:73-94.
- Sengupta RP, Saunders M, Clarke PRR. Unruptured intracranial aneurysms—an unusual source of epilepsy. *Acta Neurochirurg* 1978;40:45-53.
- Stewart RM, Samson D, Diehl J, Hinton R, Dittmore QM. Unruptured cerebral aneurysms presenting as recurrent transient neurologic deficits. *Neurology* 1980;30:47-51.
- Swartz BE, Tomiyasu U, Delgado-Escueta AV, Mandelkern M, Khonsari A. Neuroimaging in temporal lobe epilepsy: test sensitivity and relationships to pathology and postoperative outcome. *Epilepsia* 1992;33:624-34.
- Whittle IR, Allsop JL, Halmagyi GM. Focal seizures: an unusual presentation of giant intracranial aneurysms. *Surg Neurol* 1985;24:533-40.
- Willmore LJ, Sypert GW, Munson JB. Recurrent seizures induced by cortical iron injection: a model of posttraumatic epilepsy. *Ann Neurol* 1978;4:329-36.
- Willmore LJ, Sypert GW, Munson JB, et al. Chronic focal epileptiform discharges induced by injection of iron into rat and cat cortex. *Science* 1978;200:1501-3.