



Vascular Malformations of the Brain in Hereditary Hemorrhagic Telangiectasia (Rendu-Osler-Weber Disease)

Kenji Kikuchi, Masayoshi Kowada, and Hiroyasu Sasajima

Neurosurgical Service, Akita University Hospital, Akita, Japan

Kikuchi K, Kowada M, Sasajima H. Vascular malformations of the brain in hereditary hemorrhagic telangiectasia (Rendu-Osler-Weber disease). *Surg Neurol* 1994;41:374-80.

Six patients with vascular malformation of the brain in hereditary hemorrhagic telangiectasia (HHT) were reviewed to determine clinical and radiographic characteristics of these lesions. There were two patients with arteriovenous fistula (AVF), three with arteriovenous malformation (AVM), and one with multiple AVMs associated with AVF. Seizures were the most common presenting symptom (seen in three patients), and two of them had intracerebral hematomas (ICH). In the remainder, the malformations were incidentally found in the course of evaluation of other diseases. Their locations were variable, but the majority was superficially confined to the cerebral cortex. Arterial supply was from mostly one feeding artery that was a cortical branch of either anterior, middle, or posterior cerebral artery. In six of nine malformations, the venous drainage was through a superficial cerebral vein into either the superior sagittal sinus or transverse sinus. Direct surgery was done on two patients with ICH, artificial embolization on one, and stereotactic radiosurgery on one. The cerebral vascular malformations in HHT are not infrequent, and in particular the importance of computed tomography and cerebral angiography should be recognized in patients with pulmonary AVF associated with HHT.

KEY WORDS: Arteriovenous fistula; Arteriovenous malformation; Hereditary hemorrhagic telangiectasia; Stereotactic radiosurgery

Hereditary hemorrhagic telangiectasia (HHT), or Rendu-Osler-Weber disease, is an autosomal dominant disorder of angiodyplasia characterized by a triad of mucocutaneous and visceral telangiectasia, recurrent epistaxis, and familial history [12]. In particular, pulmonary arteriovenous fistula (AVF) is relatively common, and has been reported in 23.5% of HHT patients

[3]. Conversely, 40%–60% of patients with such pulmonary AVF have other signs of HHT [6]. Neurologic manifestations and complications secondary to pulmonary AVF are particularly recognized [13,15]. However, vascular malformations of the brain in HHT have rarely been documented in the literature, and their clinical implications have not been appreciated sufficiently [17]. In this report we review six new HHT cases associated with vascular malformation of the brain, with special reference to the clinical profiles, the angiographic characteristics, and the mode of management.

Summary of Cases

The features of six patients with vascular malformation of the brain in association with HHT were collected from a retrospective review of clinical, radiologic, and surgical records (Table 1). There were two men and four women, ranging in age from 2 to 53 years with a mean age of 23 years. Among them there were two familial occurrences; cases 1 (mother) and 3 (daughter), and cases 2 (mother) and 6 (son).

Clinical Presentation

Three patients presented with generalized seizures. Two of these had parietal and fronto-temporal intracerebral hematomas that in one of these patients also caused hemiparesis. One patient presented with high fever, headache, and hemiparesis and was found to have a brain abscess in the left frontal lobe. The remaining two patients had no history of neurologic symptoms attributable to the malformations; they were diagnosed by computed tomography (CT) during the course of evaluation and treatment of other diseases of HHT, or CT was obtained because a family member of each of these patients was then known to be affected by vascular malformations of the brain.

Radiographic Features

Cerebral angiography was performed on all six patients to define the vascular anatomy. Including one patient

Address reprint requests to: Kenji Kikuchi, M.D., Neurosurgical Service, Akita University Hospital, 1-1-1 Hondo, Akita 010, Japan.
Received July 8, 1993; accepted September 21, 1993.

Table 1. Vascular Malformations of the Brain in Rendu-Osler-Weber Disease

Case	Age/Sex	Type and Location	Feeding Arteries	Draining Veins	Neurologic Symptoms	Treatment	Associated Lesions
1	24/F	AVF Rt. frontal	Branch of ACA	Superficial veins to SSS	None	Embolization	
2	16/F	AVF Lt. parietal	Branch of MCA	Superficial vein to SSS	Seizure (ICH)	Removal	
3	2/F	AVM Lt. parietal	Two branches of MCA	Superficial vein to SSS	Motor Weakness Seizure (ICH)	Removal	
4	36/M	AVM Rt. occipital	Branch of PCA	Superficial vein to TS	Seizure	Medication	Pulmonary AVF
5	53/F	AVM Lt. thalamus	Branch of PCA	Superior thalamic vein	Motor Weakness	None	Pulmonary AVF Brain abscess
6	7/M	AVF Lt. frontal	Branch of ACA	Pericallosal vein to GVG	None	Clipping	Pulmonary AVF
		AVM Lt. frontal	Median artery of the corpus callosum	Pericallosal vein to GVG	None	Radiosurgery	
		AVM Rt. frontal	Branch of ACA	Superficial vein to SSS	None	Radiosurgery	
		AVM Rt. parietal	Branch of ACA	Superficial vein to SSS	None	Radiosurgery	

Abbreviations: AVM, arteriovenous malformation; AVF, arteriovenous fistula; F, female; M, male; Blt., bilateral; Rt., right; Lt., left; ACA, MCA, & PCA, anterior, middle, & posterior cerebral artery; SSS, superior sagittal sinus; TS, transverse sinus; GVG, great vein of Galen; ICH, intracerebral hematoma.

who had three AVMs independently, there were nine lesions of vascular malformations to be analyzed in this series, including three AVFs and six AVMs. The malformations were supplied principally by one cortical and terminal branch of either the anterior, middle, or posterior cerebral artery (ACA, MCA, PCA), and only one AVM received blood supply from the two branches of the MCA. Venous drainage was through superficial cerebral veins into the superior sagittal sinus, or transverse sinus. Size of the AVM nidus was either small (< 2 cm) cases 3, 5, 6) or moderate (3 cm) (case 4). Three malformations existed in the frontal lobe, three in the parietal lobe, one in the occipital lobe, and one in the thalamus—thus a majority of the cerebral vascular malformations in association with HHT in this series occupied the superficial cortical structure of the cerebral hemisphere. As to the hemodynamics, five malformations were demonstrated to be of relatively slow-flow shunt as the draining veins were not opacified until the capillary phase on angiograms.

Treatment and Outcome

Surgical treatment was carried out in three patients. In two of these with hemorrhage the AVF with aneurysmal dilation (case 2) and the AVM (case 3) were totally extirpated, and both patients fully recovered neurologically after surgery. In another asymptomatic patient (case 6) the cerebral AVF was obliterated by placing a clip on the feeding artery. Endovascular surgery was

performed in two patients, in one of whom the AVM was obliterated with the use of polyvinyl alcohol (PVA) particles and ethylene vinyl alcohol (EVAL) (case 1). In another AVF patient (case 6), an attempt was made to obstruct it by injecting a platinum coil, but the coil did not remain in the AVF. Three small malformations independently found in one patient underwent successful stereotactic radiosurgery (case 6). This was the first reported case with multiple AVMs, in which radiosurgery was undertaken and all the malformations simultaneously disappeared in less than 1 year after the procedure (as evidenced by angiography). Radiation-induced complications were not seen. A deep-seated malformation of the thalamus incidentally found in a patient with a recurrent brain abscess was not subjected to any treatment (case 5).

Associated Vascular Lesions

Three of six patients were associated with pulmonary AVF. Two patients (cases 5 and 6) had clinical symptoms such as cyanosis and clubbing of the fingers secondary to the pulmonary lesion. Another was asymptomatic (case 4) and had an abnormal shadow pointed out on the chest x-ray at annual check-up. Familial occurrence of pulmonary AVF was seen in cases 4 and 5. The father and the uncle of the patient in case 4 underwent surgical resection of pulmonary AVF. A 43-year-old sister of the patient in case 5 was also diagnosed as HHT associated with pulmonary AVF.

The family pedigree in case 5 showed 11 individuals in three generations affected by HHT.

Illustrative Case Reports

Case 1 (AVF)

A 24-year-old woman was admitted with signs and symptoms of meningitis of 3 days' duration. She had suffered from epistaxis since early childhood. Family history included a father, grandfather, and aunt with frequent episodes of epistaxis, and a daughter with a cerebral AVM (case 3). Physical examination revealed telangiectase on the upper lip, the tongue, the mucosa of the nasal cavity, and the hand. Post-contrast CT scan revealed abnormal linear enhancement in the frontal region, which was further confirmed by magnetic resonance imaging (MRI) as flow-void images (Figure 1). Right carotid angiograms demonstrated an AVF directly connecting the enlarged right middle internal frontal artery of the callosomarginal artery to the two superficial cerebral veins draining into the superior sagittal sinus (Figure 2). The AVF was embolized with the combined use of PVA particles (250-400 μm) and 0.5 mL of EVAL by superselectively catheterizing the right middle internal frontal artery with the use of a Tracker-18 catheter. Complete obliteration of the AVF was obtained. After the procedure the patient became slightly somnolent and had 4/5 left hemiparesis. CT disclosed a hypodense area involving the right frontal lobe. It was postulated that EVAL was overflowed to obliterate a normal branch of the feeding artery. The patient made a full recovery and eventually returned to normal life with no neurologic deficits.

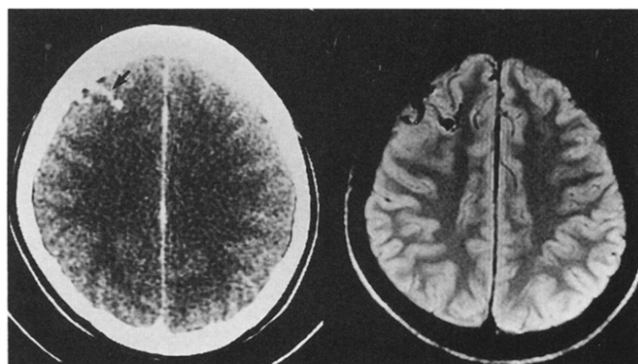


Figure 1. Case 1: Contrast-enhanced CT scan (left), demonstrating a "vermiform" enhancement in the right frontal lobe (arrow), which corresponds to a flow-void image on proton density-weighted MRI (TR 2000; TE 30) (right). These findings are consistent with the presence of a vascular malformation.

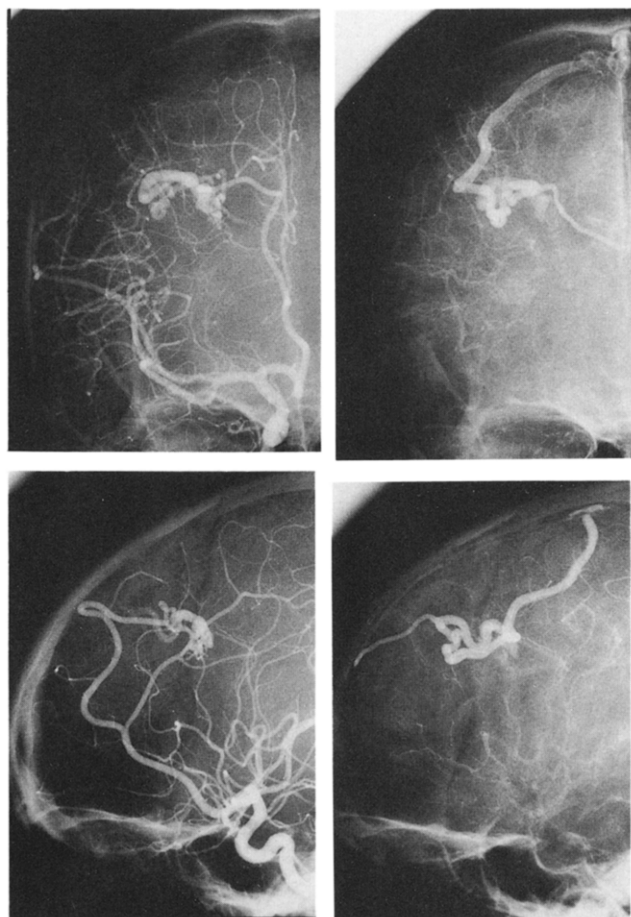


Figure 2. Case 1: Right carotid angiograms of arterial (left) and capillary phases (right) with anteroposterior (upper) and lateral views (lower). A direct vascular connection is seen between the middle internal frontal artery of the right anterior cerebral artery and two superficial cerebral veins draining into the superior sagittal sinus. Venous drainage is ultimately opacified during the capillary phase.

Case 3 (AVM)

A 2-year-old girl, daughter of the patient in case 1, suddenly began to walk clumsily and tended to stumble easily because of motor weakness in her left lower extremity. Then she had generalized convulsions. She was also known to have frequent epistaxis. CT scan disclosed an intracerebral hematoma at the left parietal region (Figure 3 A). Left carotid angiograms demonstrated an AVM fed by the moderately dilated central and posterior parietal arteries of the left MCA, and draining into the superior sagittal sinus through the ascending cerebral vein (Figure 3 B). She underwent a right parietal craniotomy for removal of the AVM and the intracerebral hematoma. Pathologic examination of the surgical specimens revealed a classical appearance of AVM (Figure 4). There were no new neurologic deficits, and the postoperative course was uneventful.

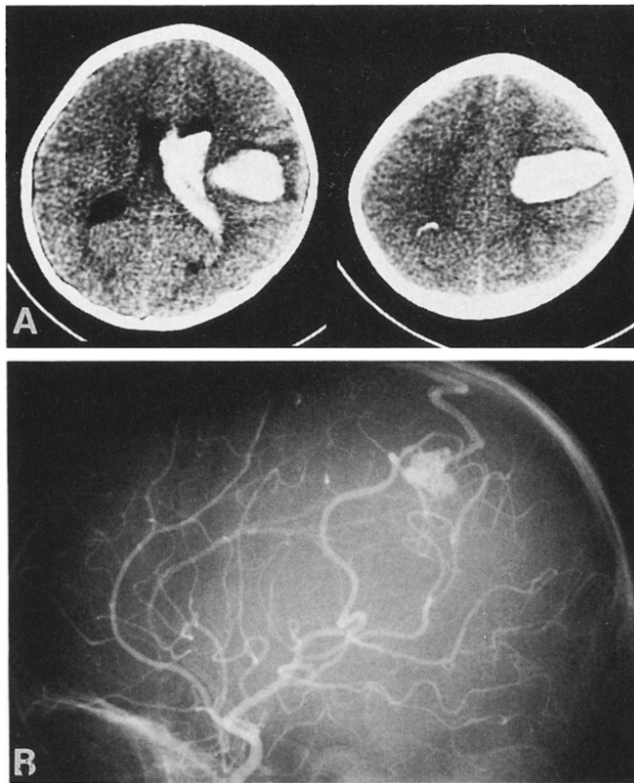


Figure 3. Case 3: Plain axial CT (A) showing a hyperdense area in the left fronto-parietal region, indicative of the presence of an intracerebral hematoma. Carotid angiogram with lateral view (B) disclosed an AVM. The arterial supply, nidus, and venous drainage are simultaneously visualized during the arterial phase on angiograms, suggesting an ordinary pattern of hemodynamics for AVM with a high flow shunt.

Case 6 (Multiple AVMs Associated With AVF)

A 7-year-old boy, son of the patient in case 2, had presented at another hospital 2 years previously with cyanosis of the lips and fingers evident on exertion. He was diagnosed as pulmonary AVF and underwent surgical removal of it. The family history prompted his physician to have CT done; an abnormal enhancing lesion was disclosed involving the left frontal lobe. Physical examination disclosed telangiectases of the right middle finger and the tip of the tongue (Figure 5). He repeatedly suffered from epistaxis before admission. Left carotid angiograms demonstrated an AVF fed by the dilated anterior internal frontal artery of the left ACA and directly draining into the vein of the corpus callosum through a large aneurysmal dilation. Venous drainage further extended into the straight sinus through the vein of Galen. In addition three small AVMs were separately seen supplied by the median artery of the corpus callosum, and the middle internal, frontal, and paracentral arteries of the right ACA, respectively (Figure 6 A). In order to obliterate the AVF, Tracker-18 catheter was placed selectively into the feed-

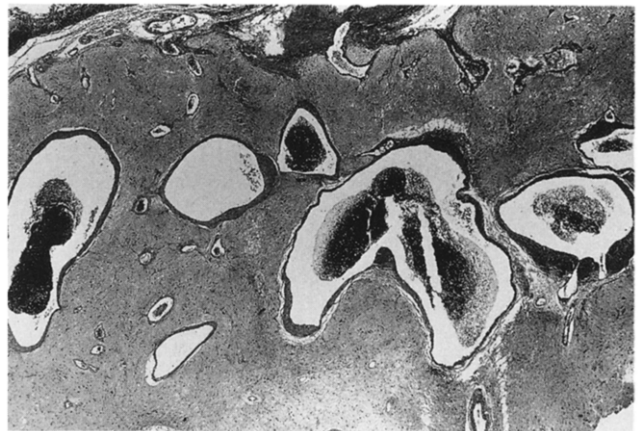


Figure 4. Case 3: Photomicrograph of the resected AVM, revealing a collection of variously thrombosed blood vessels with hyalinized thickened walls. The intervening neural tissue is present.

ing artery of the AVF and a platinum minicoil was carefully injected. However, the minicoil failed to remain in the AVF, migrated into the draining vein, and eventually disappeared. The coil was seen caught in the hilum of the left lung. Seven days after the endovascular surgery, he underwent a bifrontal craniotomy for clipping of the feeder of the AVF. About 1 year later the patient was further treated with stereotactic radiosurgery for the three remaining AVMs. Total doses ranged from 25 to 31.3 Gy for each lesion with 80%–90% covering isodose. Follow-up angiography done 8 months after radiosurgery confirmed complete obliteration of all three AVMs (Figure 6 B). Radiation-induced complications did not develop. The patient returned to school with no neurologic deficits.

Discussion

Neurologic symptoms in HHT arise as complications of: (1) pulmonary AVF, (2) vascular lesions of the brain and spinal cord, and (3) portal systemic encephalopathy. Of these, pulmonary AVF is relatively common [3,17]. Three of our six patients with HHT had pulmonary AVF, and one of these patients also had a brain abscess. In these patients cerebral AVMs and AVFs were detected by CT and subsequently confirmed by angiography during the course of evaluation for pulmonary AVF. Indeed, as Merland [10] indicated, the association of asymptomatic cerebrovascular malformations and pulmonary fistulae is not uncommon. Therefore, CT is an important screening and diagnostic test for cerebral vascular malformations when pulmonary AVF is diagnosed. In addition, the importance of carefully taking family history of HHT should be emphasized because pulmonary AVF is one of the most common conditions

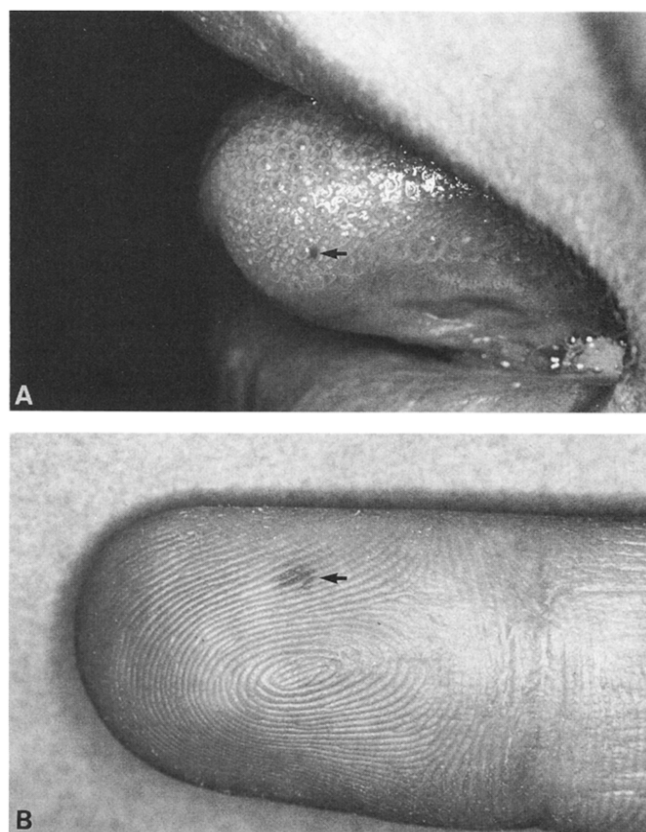


Figure 5. Case 6: Photographs of mucocutaneous telangiectases (arrows) on the tip of the tongue (A) and the right index finger (B).

associated with this inherited disorder [3]. In particular, familial pulmonary AVF as seen in cases 4 and 5 may be regarded as another characteristic criterion for diagnosis of HHT.

In contrast to pulmonary AVF, vascular malformations of the brain in patients with HHT are much less common and have rarely been documented by angiography or CT scan [17,19]. Roman et al [15] reviewed more than 200 reported patients with HHT involving the central nervous system (CNS), and it was found that 27.9% of neurologic symptoms arose from vascular malformations of the brain; 48.4% of neurologic symptoms were related to complications of pulmonary AVF such as brain abscess and other intracranial suppurative diseases. Telangiectases and angiomas comprised 46.8% of all the CNS vascular malformations including those of spinal cord, followed in order by cerebral AVMs and aneurysms that constituted 22.1% and 7.8%, respectively. The association of AVMs and cerebral aneurysms or telangiectases has also been described [7]. Telangiectases in the brain are usually asymptomatic and found in the post-mortem examinations [4]. In addition asymptomatic cerebral AVFs without the presence of vascular nidus

are also known to be associated with HHT [5,11]. By contrast a variety of symptoms such as chronic headaches, seizures, focal neurologic deficits, or intracranial hemorrhage were documented in association with AVMs in HHT [1]. In our series the AVMs tend to be small in size, mostly smaller than 2 cm, and situated in the cortex. Arterial supply is primarily from a cortical branch of either the ACA, MCA, or PCA, and with a relatively slow-flow shunt, drainage is through a superficial vein into the superior sagittal sinus or the transverse sinus. Kawaguchi et al [8] described an HHT case of three cerebral AVMs whose sizes and locations were precisely documented by CT and angiography. They measured 1 × 1 cm, 1.5 × 1.5 cm, and 2 × 2 cm in sizes, and were all fed by terminal arteries of major cerebral vessels. This documentation illustrates characteristics of the radiographic appearances of AVMs in HHT. Cerebral AVFs have similar radiographic characteristics as to location, arterial supply, and venous drainage, and can be regarded as pial AVFs.

Surgical treatment of the cerebrovascular lesions in HHT has rarely been documented, and in particular there were no reports regarding the feasibility and indication of surgical management. Waller and Greenberg [19] documented an HHT case of multiple AVMs, one of which was surgically removed. Since then a review of the literature showed there were four previously published HHT cases of AVMs that were surgically treated and thoroughly documented [1,2,8,14]. Interestingly, they all happened to be the cases of multiple AVMs as in case 6 of our series. Since each AVM tends to be small and localized in the cortex, an aggressive approach to surgical excision of these multiple accessible AVMs has been so far undertaken. When multiple lesions exist in close proximity and only minimal neurologic deficits are anticipated postoperatively, then one-stage operation by a large craniotomy may be feasible for removal of the lesions as documented by Schlachter et al [16]. When the multiple lesions involve both cerebral hemispheres or supratentorially and infratentorially, then two-stage operations may be chosen [2,8,14]. Therefore surgical decision-making should be used on a case-by-case basis.

As for endovascular treatment, great versatility in superselectively catheterizing a terminal feeding artery is necessary to achieve a success in obliteration of the AVM and AVF in HHT, because they are often situated in the cortex fed by a cortical, terminal branch of the cerebral artery. In case 1 EVAL, a liquid embolic agent, was used and overflowed to obliterate a normal branch of the feeding artery. A microballoon catheter should have been passed to a point just proximal to the AVF in order to avoid overflow and occlusion of normal branches with EVAL. In case 6 proper selection of

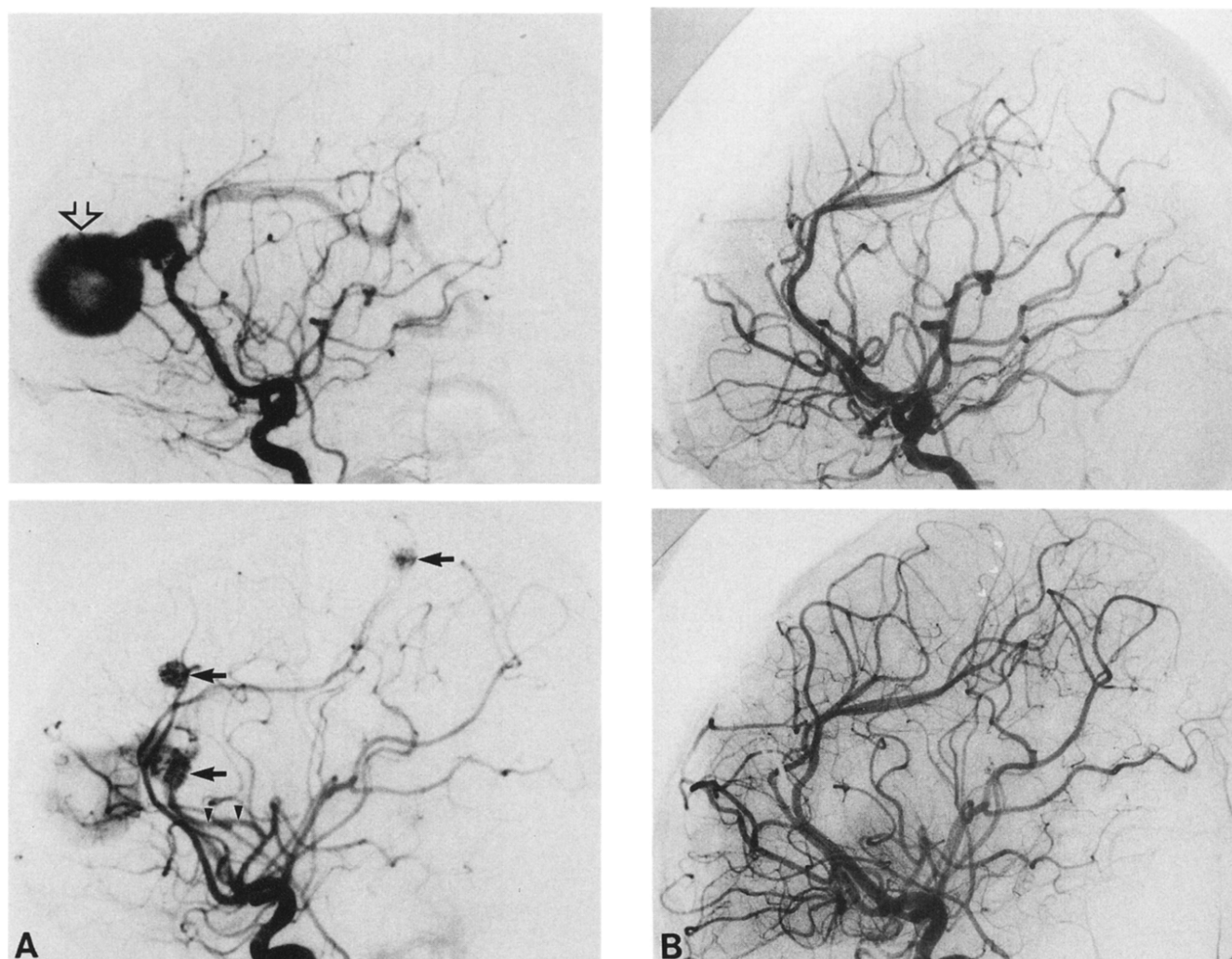


Figure 6. Case 6: Left (upper) and right (lower) carotid angiograms before (A) and after (B) craniotomy and stereotactic radiosurgery. A cerebral AVF is seen fed by a dilated left anterior internal frontal artery and draining into an anomalous vein of the corpus callosum with aneurysmal dilation (open arrow). In addition three small AVMs (arrows) are visualized separately supplied by (1) the median artery of the corpus callosum (arrowheads), (2) the right middle internal frontal artery, and (3) the right paracentral artery. Complete disappearance of both AVF and three AVMs is confirmed after feeder clipping of the AVF and stereotactic radiosurgery for the AVMs (B).

embolization materials was also difficult and occlusion of the vein of Galen would have resulted in devastating outcome. Although the technical difficulty of both catheterization and proper selection of emboli remains, it appears that endovascular surgery, given the present state of technical development, may be the treatment of choice for the vascular lesions in HHT, especially those fistulous lesions that may not be amenable to surgical interruption.

Strategies for treating AVMs have been drastically changed with the advent of stereotactic radiosurgery [9,18]. In view of the clinical and radiographic characteristics of the AVMs in HHT, radiosurgery is also indicated as a treatment of choice. In particular a size of AVM is an important factor for predicting successful obliteration by radiosurgery. Lundsford et al [9] docu-

mented that overall angiographic obliteration rate at 2 years was 80%, and it further increased up to 88% for lesions of less than 4 cm³. Of further interest is their data that AVMs in children were obliterated sooner after treatment than in adults. In the present communication the efficacy of radiosurgery to obliterate AVM was confirmed in a 7-year-old boy (case 6) with multiple small AVMs, each of which measured less than 1 cm in diameter. It is assumed that radiosurgery will be frequently used for the treatment of multiple AVMs. Radiation effects on the surrounding brain, however, may be increased due to multiple sites of irradiation. Meticulous dosimetry planning including selection of collimators and dose determination should be carefully calculated to avoid undue radiation-induced complications.

The authors thank Takanobu Shioya, M.D., Noritaka Yanagida, M.D., and Akifumi Suzuki, M.D., who each contributed a case to this series.

References

1. Adams HP Jr, Subbiah B, Bosch EP. Neurologic aspects of hereditary hemorrhagic telangiectasia. Report of two cases. *Arch Neurol* 1977;34:101-4.
2. Aesch B, Lioret E, de Toffol B, Jan M. Multiple cerebral angiomas and Rendu-Osler-Weber disease: case report. *Neurosurgery* 1991;29:599-602.
3. Bergqvist N, Hessen I, Hey M. Arteriovenous pulmonary aneurysms in Osler's disease (telangiectasia hereditaria haemorrhagica). Report of four cases in the same family. *Acta Med Scand* 1962;171:301-9.
4. Bird RM, Jaques WE. Vascular lesion of hereditary hemorrhagic telangiectasia. *N Engl J Med* 1959;260:597-9.
5. Chandler D. Pulmonary and cerebral arteriovenous fistula with Osler's disease. *Arch Intern Med* 1965;116:277-82.
6. Deramond H, Renard A, Thiebot J, Legars D, Trimez G. Les manifestations neurologiques revelatrices de fistules arterio-veineuses pulmonaires (Neurologic manifestations revealing pulmonary arteriovenous fistulas). *J Neuroradiol* 1983;10:1-14.
7. Eto RT, Harley JD, Chikos PM, Graebner RW. Subarachnoid hemorrhage in hereditary hemorrhagic telangiectasia. A report of two cases. *Neuroradiology* 1974;8:127-30.
8. Kawaguchi T, Fujita S, Yamada H, Nishida Y, Izawa I. Multiple cerebral and pulmonary arteriovenous malformations in association with brain and subcutaneous abscesses: a possible variant of hereditary hemorrhagic telangiectasia. Case report. *Neurol Med Chir (Tokyo)* 1990;30:272-6.
9. Lunsford LD, Kondziolka D, Flickinger JC, Bissonette DJ, Jungreis CA, Maitz AH, Horton JA, Coffey RJ. Stereotactic radiosurgery for arteriovenous malformations of the brain. *J Neurosurg* 1991;75:512-24.
10. Merland JJ, Djindjian R. Manifestations cerebrales de la maladie de Rendu-Osler (Cerebral manifestations of Rendu-Osler disease). *J Neuroradiol* 1974;1:257-85.
11. Nakao S, Fukumitsu T, Yamamoto T, Sakamoto H. Cerebral and pulmonary arteriovenous fistula with possible hereditary hemorrhagic telangiectasia: case report. *Neurol Surg (Tokyo)* 1986;14:901-6.
12. Perry WH. Clinical spectrum of hereditary hemorrhagic telangiectasia (Osler-Rendu-Weber disease). *Am J Med* 1987;82:989-97.
13. Press OW, Ramsey PG. Central nervous system infections associated with hereditary hemorrhagic telangiectasia. *Am J Med* 1984;77:86-92.
14. Reddy K, West M, McClarty B. Multiple intracerebral arteriovenous malformations. A case report and literature review. *Surg Neurol* 1987;27:495-9.
15. Roman G, Fisher M, Perl DP, Poser CM. Neurological manifestations of hereditary hemorrhagic telangiectasia (Rendu-Osler-Weber disease): report of 2 cases and review of the literature. *Ann Neurol* 1978;4:130-44.
16. Schlachter LB, Fleischer AS, Faria MA Jr, Tindall GT. Multiple intracranial arteriovenous malformations. *Neurosurgery* 1980;7:440-4.
17. Sobel D, Norman D. CNS manifestations of hereditary hemorrhagic telangiectasia. *AJNR* 1984;5:569-73.
18. Steiner L, Lindquist C, Adler JR, Torner JC, Alves W, Steiner M. Clinical outcome of radiosurgery for cerebral arteriovenous malformations. *J Neurosurg* 1992;77:1-8.
19. Waller JD, Greenberg JH. Hereditary hemorrhagic telangiectasia with cerebrovascular malformations. *Arch Dermatol* 1976;112:49-52.