

SHORT REPORT

Saccadic dysmetria and "intact" smooth pursuit eye movements after bilateral deep cerebellar nuclei lesions

U Büttner, A Straube, A Spuler

Abstract

Two patients with well defined lesions of midline cerebellar structures including the fastigial nuclei on both sides presented with saccadic hypermetria but well preserved smooth pursuit eye movements. This is a remarkable finding as the oculomotor vermis (lobules VI, VII) and the fastigial nucleus are known to play a part in the control of smooth pursuit eye movements and unilateral fastigial lesions lead to a smooth pursuit deficit to the contralateral side (besides saccadic dysmetria). The results are discussed with regard to related deficits seen in patients with Wallenberg's syndrome and after lesions of the pontine reticular formation.

(*J Neurol Neurosurg Psychiatry* 1994;57:832-834)

It recently became evident that the oculomotor vermis (lobules VI and VII)¹ and its major output structure, the caudal fastigial nucleus (fastigial oculomotor region),^{2,3} are not only involved in the accuracy of saccades⁴ but also in the control of smooth pursuit eye movements.⁵ Experimental studies in monkeys showed a clear directional effect on saccade accuracy and smooth pursuit eye movements for the fastigial oculomotor region. A unilateral injection of the GABAergic-substance muscimol into the fastigial oculomotor region leads to contralateral hypo and ipsilateral hypermetric saccades⁴ and to a pronounced decrease of smooth pursuit related optokinetic slow phase velocity⁶ and smooth pursuit gain⁷ to the contralateral side.

With this in mind, the question arises as to what effect is to be expected from bilateral lesions in the fastigial oculomotor region. This has been clearly answered for saccades, whereby a general hypermetria is found.⁴ The effect that bilateral lesions in the fastigial oculomotor region have on smooth pursuit performance has not been studied in humans.

In this report we present two patients with well defined bilateral lesions of the deep cerebellar nuclei including the fastigial oculomotor region. Both of them had a pronounced saccadic hypermetria but no smooth pursuit eye movement deficit.

Case reports

CASE 1

A 29 year old woman suddenly developed a gait and postural ataxia pronounced on the left side. A cerebellar a-v malformation had been diagnosed on MRI. A neurological examination revealed the ataxia for gait and posture pronounced on the left side, along with dysarthria, slight weakness of the left extremities, and a stocking-like hypaesthesia of the left leg. There was no positional or positioning nystagmus. For oculomotor deficits see later.

Before surgery, the angioma was partly embolised by interventional angiography and was completely removed all the way through the cerebellum down to the roof of the fourth ventricle. After surgery, the lesion had a triangular shape in the sagittal plane on MRI with the base destroying lobules III to VIII of the vermis and the apex extending to the fourth ventricle, destroying the fastigial nuclei on both sides. In the coronal plane, the lesion had an oval shape extending over the midline with a lateral diameter of 1.5 to 2.0 cm. The dentate nuclei and the floccular region were intact on both sides (fig 1).

CASE 2

A 36 year old woman was admitted to hospital after she had had several attacks of positioning vertigo. On examination, there was some central positioning vertigo with nystagmus beating to the uppermost ear. Other oculomotor findings are described below. The remaining cranial nerves were unremarkable. The tendon reflexes were brisk and the Babinski sign negative. There was slight ataxia of posture and gait. The remaining neurological examination was normal.

On MRI a large midline tumour was found and diagnosed as a Lindau tumour. The large, nearly circular lesion with a diameter of 4.3 cm extended over the midline with the centre 3-5 mm to the left. It extended from the fourth ventricle to the tentorium, totally destroying lobules V-VII on the midline. All the cerebellar nuclei were destroyed with some possible sparing of lateral parts of dentate nucleus on the right side. The floccular region and most of its brainstem connections were intact. The patient underwent surgery after the eye movement recordings.

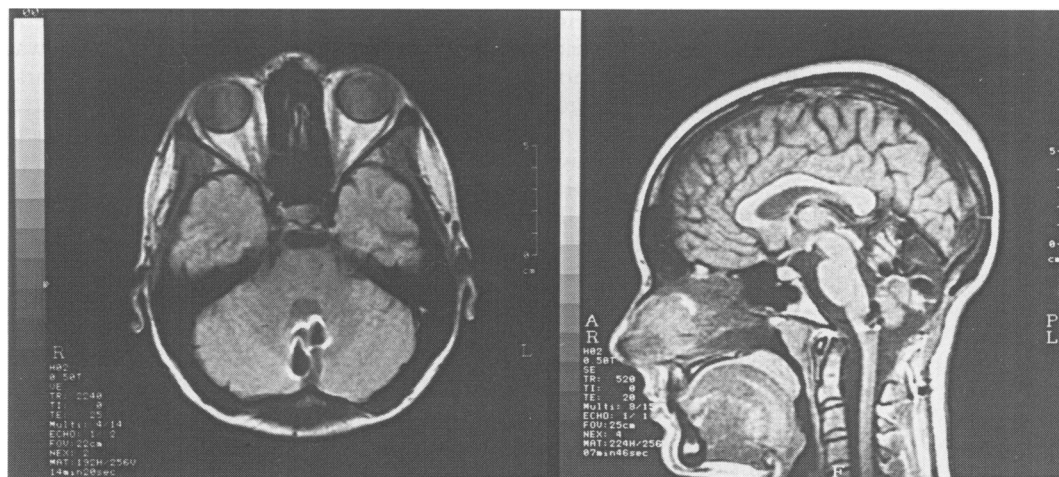Department of
Neurology and
Neurosurgery
A Spuler

Klinikum
Grosshadern, Ludwig
Maximilians
University, 81377
Munich, Germany
U Büttner
A Straube

Correspondence to:
Professor Dr U Büttner,
Neurologische Klinik,
Klinikum Grosshadern,
D 81377 München,
Marchioninistrasse 15,
Germany.

Received 21 June 1993 and
in final revised form
27 October 1993.
Accepted 1 November 1993

Figure 1 MRI of patient 1 after surgery of a cerebellar a-v malformation. Coronal (left) and sagittal (right) plane. The lesion extends over the midline and destroys the vermis (lobules III to VIII) and both fastigial nuclei. On the right some clip artefacts projections on to the medulla can be seen.



Histopathology verified the diagnosis of a haemangioblastoma (Lindau tumour).

Eye movement recordings

METHODS

Horizontal and vertical eye positions were recorded by DC-electro-oculography. The eye movement variables investigated were: spontaneous eye movements in light and darkness, fixation of small visual targets in 10° steps up to $\pm 40^\circ$ horizontally and $\pm 20^\circ$ vertically, optokinetic nystagmus up to $90^\circ/\text{s}$ stimulus velocity in the horizontal and $30^\circ/\text{s}$ in the vertical direction. Vestibular nystagmus responses in the dark were determined after a sudden stop from $90^\circ/\text{s}$ whole body rotation. The vestibulo-ocular reflex (VOR) was also tested during horizontal sinusoidal stimulation (0.1 Hz , $\pm 80^\circ$) in the dark. To investigate saccadic dysmetria, a small laser spot was presented up to 40° laterally, in most instances stepping between the lateral and midposition. For smooth pursuit eye movements the target moved horizontally ($\pm 25^\circ$) in front of the patient at $0.1\text{--}0.4\text{ Hz}$, corresponding to $\pm 16\text{--}63^\circ/\text{s}$. During visual suppression of the VOR, the patient fixated a target moving with the head during sinusoidal vestibular stimulation (0.1 Hz , $\pm 80^\circ$). All recordings were written out on paper charts for evaluation and quantitative analysis. For

saccadic dysmetria, the gain of the first (primary) saccade⁸ after the target step was determined from at least 20 target steps of 20° around the midposition. Smooth pursuit gain was taken as the ratio of eye position/stimulus position for three to five cycles.

Results

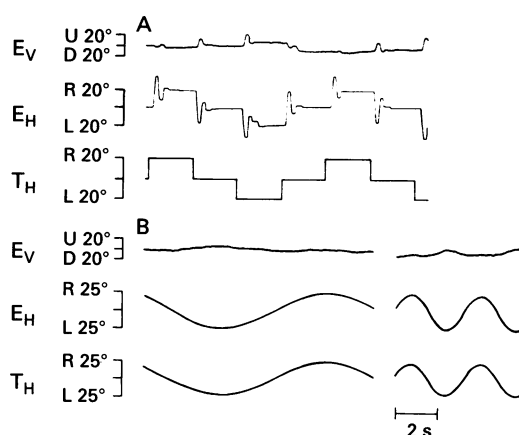
CASE 1

Recordings were taken 11 days after surgery. There was no spontaneous nystagmus in light or darkness. Saccades could be performed in all directions with a normal amplitude and velocity range. They were unremarkable during spontaneous eye movements in light and darkness. There was no horizontal or vertical gaze evoked nystagmus. Optokinetic nystagmus was within normal limits. Vestibular nystagmus after whole body rotation was slightly asymmetrical (duration right: 28 s, left: 23 s). The VOR in the dark was normal. The saccadic dysmetria was severe (fig 2).⁸⁻¹⁰ All 20° target steps were followed by hypermetric primary saccades with a gain of up to 2.0. On average, the gain was 1.7 (SD 0.15). The hypermetria was symmetrical for left and rightward saccades. Centripetal saccades were more hypermetric (average gain 1.82) than centrifugal saccades (average gain 1.6). Also vertical saccades were hypermetric, more pronounced for upward (average gain 1.6) than for downward (average gain 1.3) saccades. By contrast, smooth pursuit eye movements were very well preserved. At 0.1 Hz the gain was virtually 1.0 with long periods of hardly any catch up saccades. The gain at 0.3 Hz was still 0.9 (fig 2). Also, the visual suppression of the VOR was within normal limits.

CASE 2

This patient also had neither spontaneous nystagmus in light or darkness nor gaze evoked nystagmus. Horizontal and vertical spontaneous saccades were normal. Vestibular nystagmus after whole body rotation was symmetrical (duration left 35 s, right 37 s). The VOR in the dark and the visual suppression of the VOR were normal. During horizontal smooth pursuit, the gain was above

Figure 2 Eye movement recordings of patient 1 after surgery. (A) horizontal saccades to visual target steps; (B) horizontal smooth pursuit eye movements. EV = vertical, EH = horizontal eye position, and TH = horizontal target position. There is severe saccadic hypermetria, but no (0.1 Hz left) or only little (0.3 Hz , right) smooth pursuit impairment.



0.85 up to 0.3 Hz. Horizontal saccadic hypermetria was symmetrical to the left and right. All saccades overshoot the target up to 11° corresponding to a gain of 1.55 (average gain 1.32 (SD 0.14)). For this patient too, centripetal saccades (average gain 1.36) were more hypermetric than centrifugal saccades (average gain 1.27). There was also some vertical saccadic hypermetria but blink artefacts prevented detailed analysis here.

Discussion

Two patients are presented with large, well defined cerebellar lesions straddling the midline, and including deep cerebellar nuclei on both sides, particularly the fastigial oculomotor region. Both patients had a severe, symmetrical saccadic hypermetria with primary saccades overshooting a 20° target by nearly 100%. As has been found experimentally,⁴ centripetal saccades were more hypermetric than centrifugal saccades. All other eye movements were normal. More specifically, there was no gaze evoked nystagmus and smooth pursuit eye movements were well preserved.

At first glance, knowing the effects of unilateral lesions in the fastigial oculomotor region, this is a somewhat surprising finding. Experimentally, unilateral fastigial oculomotor region lesions have a severe effect both on saccades as well as on smooth pursuit eye movements^{6,7}—with the smooth pursuit deficit having a similar magnitude as that found after bilateral ablation of the floccular region.¹¹

Noticeably, no smooth pursuit deficit to the ipsilateral side has been found after unilateral lesions in the fastigial oculomotor region.^{6,7} As both saccades and smooth pursuit show a similar deficit (a decreased gain) to the contralateral side, by analogy with the saccadic system an increased smooth pursuit gain to the ipsilateral side might be postulated. As smooth pursuit eye movements are controlled in closed loop with continuous feedback signals, this might be the reason that this is not the case. The specific mechanisms, however, are not known.

The corresponding deficit of saccades and smooth pursuit is similar to that found after lateral medulla oblongata lesions (Wallenberg's syndrome).^{12,13} In this syndrome too, hypometric saccades with a decreased smooth pursuit gain to the contralateral side and hypermetric saccades with a normal smooth pursuit gain to the ipsilateral side are found. This deficit has been attributed to a lesion of olivocerebellar fibres passing through the dorsolateral medulla oblongata to the Purkinje cells in the cerebellar cortex.¹³ Functionally, a loss of climbing fibre activity leads to increased Purkinje cell activity, which has an inhibitory effect on fastigial oculomotor region activity similar to local microinjections of muscimol in the fastigial oculomotor region.^{4,6}

It is known that the fastigial oculomotor region projects to the paramedian pontine reticular formation (PPRF) in the brainstem.² It fits very well with our findings that after

unilateral PPRF lesions, smooth pursuit to the ipsilateral side was also severely impaired, whereas smooth pursuit was possible in both directions after bilateral PPRF lesions.¹⁴

Thus fastigial oculomotor region lesions seem to have similar effects on saccades and smooth pursuit eye movements. Unilateral lesions lead to hypometric saccades and cogwheel smooth pursuit to the contralateral side. Hypermetric saccades and "intact" smooth pursuit are found to the ipsilateral side after unilateral and bilateral lesions. As a general principle, a gain reduction is obvious in both types of eye movements. An increased gain only manifests itself, however, in the saccadic system.

The unusual finding that unilateral fastigial oculomotor region lesions cause a smooth pursuit deficit, and that bilateral lesions do not can be best explained if it is assumed that the fastigial oculomotor region affects smooth pursuit acceleration and deceleration. According to this hypothesis, a lack of acceleration causes a pursuit deficit to the contralateral side and a lack of deceleration to the ipsilateral side, which in this direction does not produce an obvious eye movement deficit. It has to be postulated that the combined effect of a bilateral lesion is a net deceleration deficit on both sides. Potentially, this could lead to eye movements which are too fast (gain >1). This would cause a retinal error in the opposite direction, however, which apparently can still be prevented by the smooth pursuit system.

We thank K Schuler for eye movement recordings. The work was supported by Deutsche Forschungsgemeinschaft (SFB 220, D7).

- 1 Yamada J, Noda H. Afferent and efferent connections of the oculomotor cerebellar vermis in the macaque monkey. *J Comp Neurol* 1987;265:224–41.
- 2 Noda H, Sugita S, Ikeda Y. Afferent and efferent connections of the oculomotor region of the fastigial nucleus in the Macaque monkey. *J Comp Neurol* 1990;302:330–48.
- 3 Büttner U, Fuchs AF, Markert-Schwab G, Buckmaster P. Fastigial nucleus activity in the alert monkey during slow eye and head movements. *J Neurophysiol* 1991;65:1360–71.
- 4 Robinson FR, Straube A, Fuchs AF. Role of the caudal fastigial nucleus in saccade generation. II. Effects of muscimol inactivation. *J Neurophysiol* 1993;70:1741–58.
- 5 Pierrot-Deseilligny Ch, Amarenco P, Rouillet E, Marteau R. Vermal infarct with pursuit eye movement disorders. *J Neurol Neurosurg Psychiatry* 1990;53:519–21.
- 6 Kurzan R, Straube A, Büttner U. The effect of Muscimol microinjections into the fastigial nucleus on the optokinetic response and the vestibulo-ocular reflex in the alert monkey. *Exp Brain Res* 1993;94:252–60.
- 7 Straube A. *Über die elektrophysiologischen Grundlagen und die pharmakologische Beeinflussung der Augenbewegungen beim Affen und ihre Bedeutung in der Therapie von Augenbewegungsstörungen. Habilitationsschrift.* München: Ludwig-Maximilians-Universität, 1993.
- 8 Bötzel K, Rottach K, Büttner U. Normal and pathological saccadic dysmetria. *Brain* 1993;116:337–53.
- 9 Selhorst JB, Stark L, Ochs AL, Hoyt WF. Disorders in cerebellar ocular motor control. II. Macrosaccadic oscillation: An oculographic, control system and clinico-anatomical analysis. *Brain* 1976;99:509–22.
- 10 Baloh RW, Konrad HR, Honrubia V. Vestibulo-ocular function in patients with cerebellar atrophy. *Neurology* 1975;25:160–8.
- 11 Zee DS, Yamazaki A, Butler PH, Gücer G. Effects of ablation of flocculus and paraflocculus on eye movements in primates. *J Neurophysiol* 1981;46:878–99.
- 12 Leigh RJ, Zee DS. *The neurology of eye movements.* 2nd ed. Philadelphia: FA Davis Company, 1991. (Contemporary Neurology Series Vol 35.)
- 13 Waespe W, Wichmann W. Oculomotor disturbances during visual-vestibular interaction in Wallenberg's lateral medullary syndrome. *Brain* 1990;113:821–46.
- 14 Henn V, Lang W, Hepp K, Reisine H. Experimental gaze palsies in monkeys and their relation to human pathology. *Brain* 1984;107:619–36.