



Cerebral Demyelination with 5-Fluorouracil and Levamisole

Athanasios B.-T. Fassas, Anna M. Gattani & Susan Morgello

To cite this article: Athanasios B.-T. Fassas, Anna M. Gattani & Susan Morgello (1994) Cerebral Demyelination with 5-Fluorouracil and Levamisole, *Cancer Investigation*, 12:4, 379-383, DOI: [10.3109/07357909409038226](https://doi.org/10.3109/07357909409038226)

To link to this article: <http://dx.doi.org/10.3109/07357909409038226>



Published online: 11 Jun 2009.



Submit your article to this journal [↗](#)



Article views: 16



View related articles [↗](#)



Citing articles: 3 View citing articles [↗](#)

Cerebral Demyelination with 5-Fluorouracil and Levamisole

Athanasios B.-T. Fassas, M.D.,
Anna M. Gattani, M.D., and Susan Morgello, M.D.

*Department of Neoplastic Diseases
Jerald H. Ruttenberg Cancer Center
and Department of Pathology (Division of Neuropathology)
Mount Sinai Medical Center
New York, New York*

ABSTRACT

We report a patient who developed multifocal cerebral demyelination with the use of 5-fluorouracil, levamisole, and leucovorin as adjuvant treatment for intestinal adenocarcinoma. The clinical features were acute confusion, restlessness, ataxia, and slurred speech. Magnetic resonance imaging revealed multifocal enhancing white matter lesions. Brain biopsy showed a well-demarcated area of demyelination in cerebral white matter. The patient improved clinically and radiologically after cessation of chemotherapy and a short course of steroids. There have been only 4 previously reported cases of multifocal leukoencephalopathy related to the use of combination 5-fluorouracil and levamisole. The extensive use of these agents as adjuvant treatment for colorectal carcinoma may result in more frequent recognition of this form of neurological toxicity.

INTRODUCTION

Colorectal adenocarcinoma is one of the most common cancers of adults in the United States. Adjuvant chemotherapy with 5-fluorouracil (5-FU) and levamisole has been shown to decrease the overall death rate and risk of cancer recurrence in Dukes C disease. The toxic effects of this regimen—nausea, vomiting, stoma-

titis, diarrhea, dermatitis, and leukopenia—are essentially the same as those of 5-FU alone. In most cases, side effects do not necessitate discontinuation of therapy.

Recently, 4 patients with a multifocal leukoencephalopathy related to 5-FU/levamisole were described (1,2). Cerebral biopsy in 2 of them revealed active demyelination, and in all, symptoms necessitated discon-

tinuation of the drugs. Herein, we describe an additional patient who developed this demyelinating syndrome and discuss the prior cases and postulated mechanisms of toxicity.

CASE REPORT

A 37-year-old white man, without personal or family history of neurological disease, sought medical attention because of weight loss and bloody stools. A well-differentiated adenocarcinoma of the distal duodenum was resected. Ten years later, the patient developed a periampullary, poorly differentiated signet-cell adenocarcinoma with transmural invasion, which was resected. No other sites of malignancy were found. Chemotherapy with 5-fluorouracil (5-FU) (450 mg/m² iv days 1–5), levamisole (50 mg po tid days 1–3 and 14–16), and leucovorin (20 mg/m² iv days 1–3) in cycles of 28 days was begun.

Fourteen weeks after the introduction of chemotherapy and 6 days after the last dose (a total of 12.1 g 5-FU and 2.8 g levamisole), the patient presented acutely with confusion, restlessness, slurred speech, unsteady gait, and agitation. Neurological examination revealed an alert, suspicious man with partial aphasia and confusion, mild left facial and arm weakness, diffuse hyperreflexia with clonus, and extensor plantar responses bilaterally. A computed tomography (CT) scan with contrast demonstrated multiple enhancing lesions, 3–18 mm in size, in cerebral and cerebellar white matter and pons. Dexamethasone was begun for 72 hr at 4 mg iv every 6 hr and tapered over a 21-day period until discontinued. An electroencephalogram showed marked, diffuse cerebral slowing. A lumbar puncture yielded normal cerebrospinal fluid (CSF), and serum titers for toxoplasmosis, Lyme disease, cytomegalovirus, syphilis and human immunodeficiency virus were negative. The patient's neurological symptoms improved gradually. Magnetic resonance imaging (MRI) of the head demonstrated multiple discrete lesions in supratentorial white matter with sparing of gray matter (Fig. 1). Nearly all lesions enhanced with gadolinium. Within 2½ weeks the patient was free of neurological signs and symptoms; however, a repeat MRI showed no significant change. As the lesions persisted, a stereotaxic brain biopsy was performed. It revealed a well-demarcated focus of demyelination with macrophage infiltrates, several millimeters deep to the cortical margin (Fig. 2). Lymphocytic infiltrates were not prominent. Special stains for bacteria, fungi, acid-fast bacilli, and *Toxoplasma* were negative,

and viral inclusions were not seen. The patient was discharged from the hospital in very good health.

DISCUSSION

Four patients with 5-FU/levamisole-associated leukoencephalopathy have been reported previously (1,2). Three presented with ataxia and a rapid decline in mental status, and 1 presented with episodes of loss of consciousness. All presented between 8 and 19 weeks after the initiation of chemotherapy, at total doses of 9.5–15.7 g of 5-FU and 2.25–3.7 g of levamisole (Table 1). In all patients, MRI demonstrated multifocal white matter lesions, enhancing after administration of gadolinium. Stereotaxic biopsies in 2 patients revealed demyelination. All patients improved clinically and radiologically within 1–6 months, after prompt discontinuance of chemotherapy. None were rechallenged with 5-FU or levamisole. Dexamethasone was given to 3 patients; however, improvement occurred in the fourth without steroids. The role of steroids in management of the syndrome is therefore unknown, but they may hasten resolution of symptoms in selected patients (1). All features of our patient are consistent with the clinical, radiological, and histological characteristics of these 4 patients.

Both 5-FU and levamisole have been independently implicated in neurological disorders. The most common neurological toxicity of 5-FU is an acute cerebellar syndrome, with an incidence of 0.6–7% (3). It may consist of slurred speech, ataxia, coarse nystagmus, and dizziness. It is not related to the age or sex of the patient, occurrence of hematological or mucocutaneous toxicity, or the total drug dosage. The dysfunction appears totally reversible (3). Less common, with 3 reported cases in the literature, is 5-FU-related encephalopathy (4,5). These patients present with confusion and severe psychomotor retardation in the absence of localized findings. Total doses of 5-FU in the 3 patients were 3, 8, and more than 15 g. Neuroimaging studies were normal in all. All improved dramatically with return to baseline status within 1–2 months of cessation of therapy. A more severe subacute leukoencephalopathy has also been related to carmofur (1-hexylcarbonyl-5-fluorouracil), one of the masked compounds of 5-FU (6). In a report from Japan, where carmofur is extensively used, 5 of 19 patients died and 2 had persistent akinetic mutism (6).

The pathogenesis of neurological syndromes related to 5-FU and its metabolites is not known. The neuropathology observed in animal models suggests a direct

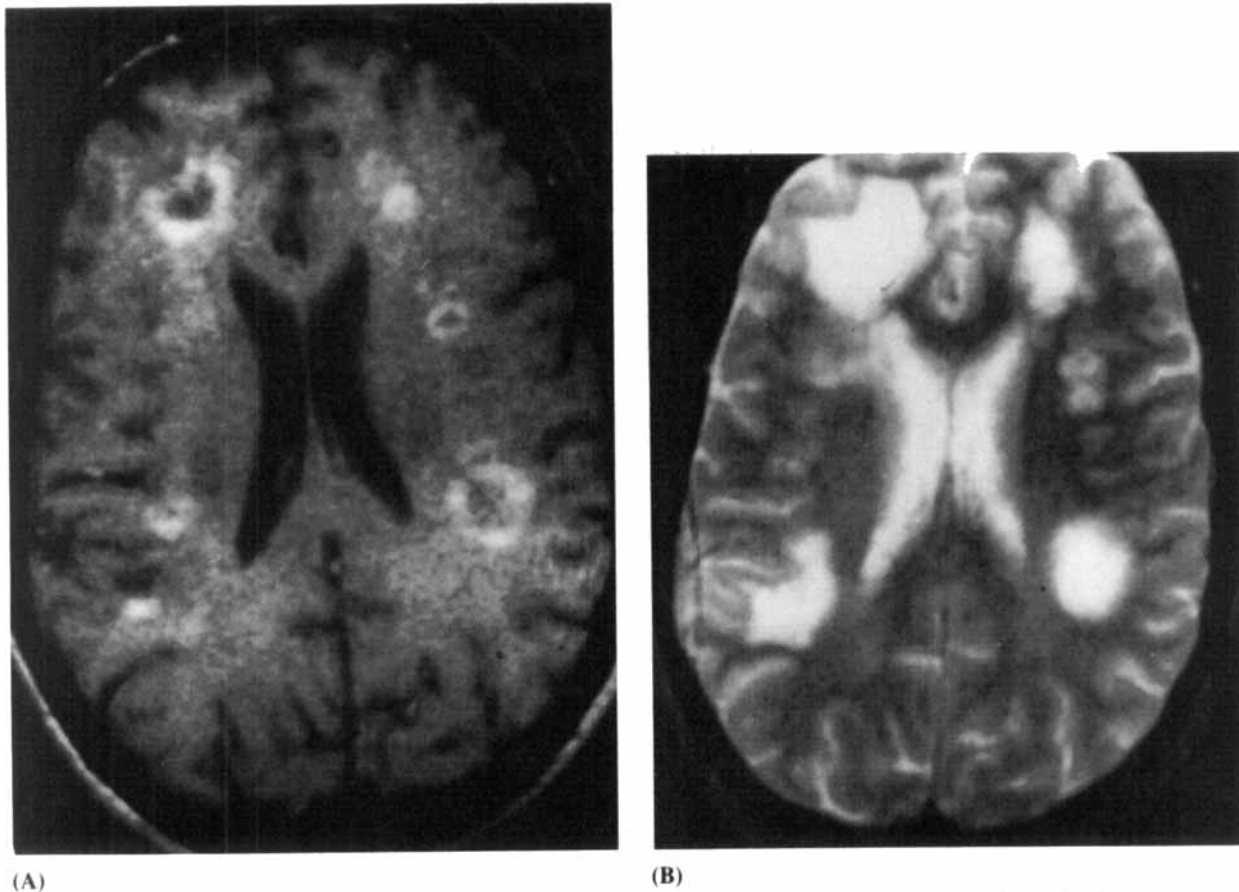


Figure 1 (A) Axial projection of a T1-weighted magnetic resonance image demonstrating multiple ring-enhancing white matter lesions. (B) Axial projection of a T2-weighted image demonstrating multifocal high-intensity lesions.

toxic effect on myelin, with splitting of the intraperiod line and vacuole formation (7). Koenig and Patel suggest that toxicity is not due to 5-FU itself, but to 5-fluoroacetate and fluocitrate, degradation products of α -fluoro- β -alanine (the major catabolite of 5-FU), and potent inhibitors of the Krebs cycle (8). There are no reports of blood or CSF fluocitrate levels in patients with 5-FU toxicity.

Levamisole is used extensively as an antihelminthic and, more recently, as an anticancer agent. It has a broad range of immunomodulatory effects, including enhancement of antibody production to several antigens, augmentation of cellular immune responses, augmentation of chemotaxis, enhancement of the phagocytic activity of polymorphonuclear leukocytes, and increase of delayed-type hypersensitivity reactions. Levamisole has been associated with a variety of neurological syndromes, including insomnia, headache, dizziness, and fatigue—a spectrum unlike that seen with 5-FU. A re-

port from China documented 10 patients who developed encephalopathy 2-3 weeks after taking levamisole in doses of 75–350 mg (9). Head CT scans revealed scattered low-density shadows in white matter in all patients. The small doses and short duration of drug administration prior to onset of neurological symptoms in these patients may implicate a hypersensitivity reaction in the pathogenesis of this encephalopathy. In a dog model, oral administration of levamisole resulted in cerebral perivascular cuffing by mononuclear cells, suggesting that there may be an inflammatory component to levamisole-associated central nervous system dysfunction (10).

The proposed mechanisms of 5-FU and levamisole-induced neurotoxicity may have direct relevance to their combined effects. If 5-FU and its metabolites act as direct myelin toxins, and levamisole is capable of enhancing an immune response to damaged myelin, it is conceivable that the agents in combination result in an

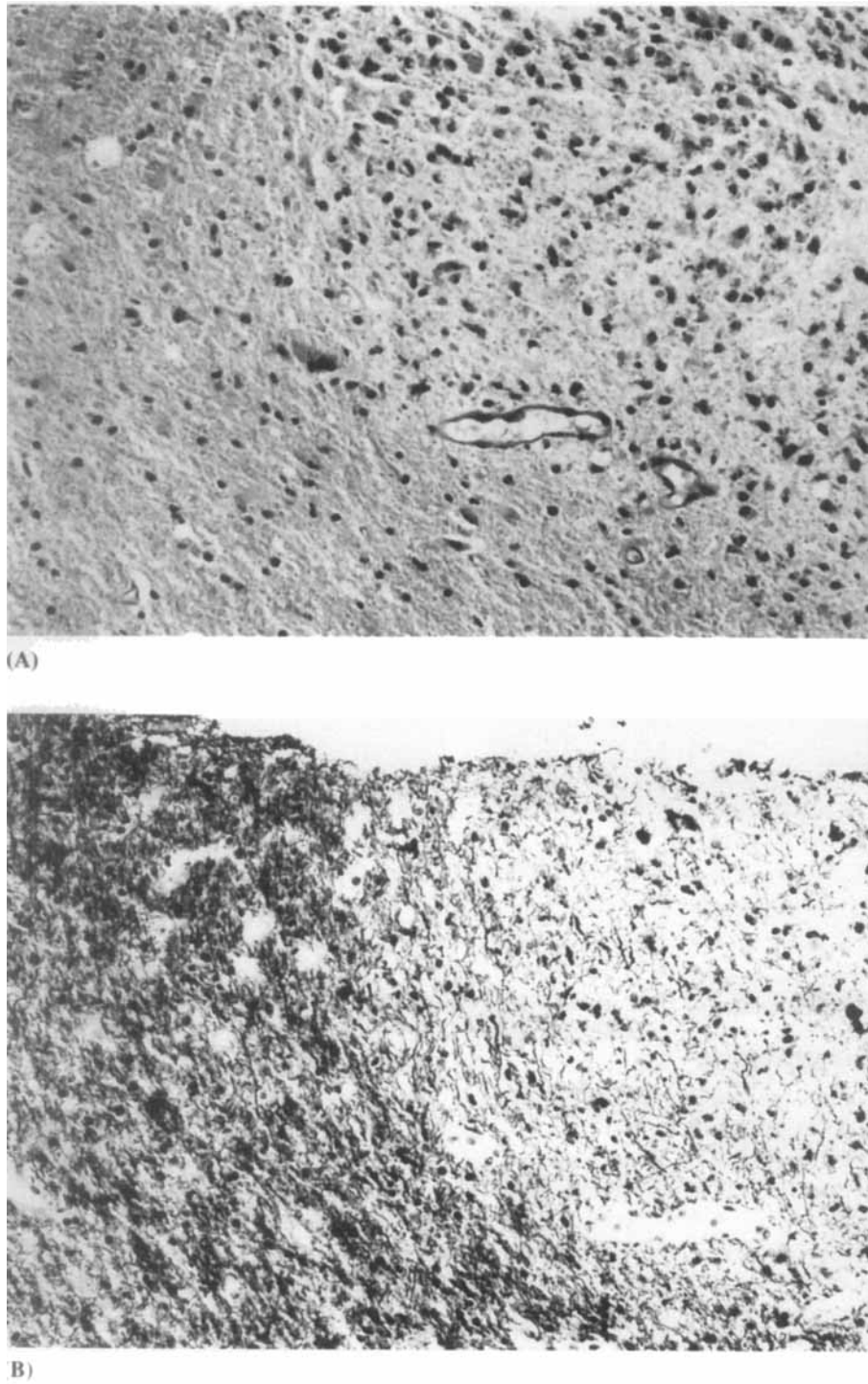


Figure 2 (A) Photomicrograph demonstrating focal region of hypercellularity (hematoxylin and eosin stain, original magnification 100 \times). (B) The same region, viewed with Luxol fast blue stain, reveals well-circumscribed demyelination (Luxol fast blue stain, original magnification 100 \times).

Table 1*Quantity and Duration of Chemotherapy in Patients with 5-FU and Levamisole-Induced Encephalopathy*

Patient no. (author)	Age/sex	Total dose 5-fluorouracil (mg)	Total dose levamisole (mg)	Duration of chemotherapy prior to symptoms (weeks)
1 (Hook et al.)	68/M	9,730	2700	15
2 (Hook et al.)	45/F	12,170	3600	18
3 (Hook et al.)	74/F	15,700	3750	19
4 (Kimmel et al.)	74/M	9,515	2250	9
5 (present case)	38/M	12,100	2800	14

immune host reaction directed against myelin. Precedent for this mechanism is seen in the animal model experimental allergic encephalitis, where myelin fragments in the context of immune stimulation induce demyelinating disease. Indeed, the human counterpart to experimental allergic encephalitis, multiple sclerosis, is histologically indistinguishable from the biopsied lesions of 5-FU/levamisole toxicity. One therefore cannot rule out the possibility that 5-FU/levamisole "unmasks" clinically silent multiple sclerosis. Further observations of patients undergoing this common chemotherapy are thus indicated, with clinicians alerted to the potential neurotoxicity of these agents.

Finally, the importance of recognizing 5-FU/levamisole-associated leukoencephalopathy must be emphasized, particularly because a neurologically symptomatic cancer patient with multiple contrast-enhancing lesions on MRI might be presumed to have cerebral metastases and receive cranial irradiation. The consequences of radiating demyelinating lesions may be clinically devastating. In our patient, the distribution of the lesions, confined to white matter and not at the gray-white junction, and the lack of surrounding edema argued against the possibility of metastatic disease. The documentation of demyelination on cerebral biopsy was important, as the therapeutic approach to and prognosis of this patient would be very different had he received alternative diagnoses of tumor or infection.

ACKNOWLEDGMENTS

The authors thank Dr. Mika Lidov for providing representative radiology and Ms. Amy Hsu for assistance with photography.

Address correspondence to: Susan Morgello, M.D., Department of Pathology (Neuropathology), Box 1134, Mount Sinai Medical Center, 1 Gustave Levy Place, New York, NY 10029.

REFERENCES

1. Kimmel DW, Schutt AJ: Multifocal leukoencephalopathy: Occurrence during 5-fluorouracil and levamisole therapy and resolution after discontinuation of chemotherapy. *Mayo Clin Proc* 68:363-365, 1993.
2. Hook CC, Kimmel DW, Kroles LK, et al: Multifocal inflammatory leukoencephalopathy with 5-fluorouracil and levamisole. *Ann Neurol* 31:262-267, 1992.
3. Weiss HD, Walker MD, Wiernik PH: Neurotoxicity of commonly used antineoplastic agents (first of two parts). *N Engl J Med* 291:75-81, 1974.
4. Greenwald ES: Organic mental changes with fluorouracil therapy. *JAMA* 235:248-249, 1976.
5. Lynch HT, Proszcz CP, Albano WA, Lynch JF: Organic brain syndrome secondary to 5-fluorouracil toxicity. *Dis Colon Rectum* 24:130-131, 1981.
6. Kuzahara S, Ohkoshi N, Kanemaru K, et al: Subacute leukoencephalopathy induced by carmofur, a 5-fluorouracil derivative. *J Neurol* 234:365-370, 1987.
7. Okeda R, Karakama T, Kimura S, Toizumi S, Mithushima T, Yokoyama Y: Neuropathologic study on chronic neurotoxicity of 5-fluorouracil and its masked compounds in dogs. *Acta Neuropathol (Berl)* 63:334-343, 1984.
8. Koenig HK, Patel A: Biochemical basis for fluorouracil neurotoxicity: The role of Kreb's cycle inhibition by fluoroacetate. *Arch Neurol* 23:155-160, 1970.
9. Hunan Medical University: Analysis of 10 subjects with encephalopathy due to levamisole. *Bull Hunan Med Univ* 14(1):1-6, 1989.
10. Vandervelde M, Boring JG, Hoff EJ, Gingerich DA: The effect of levamisole on the canine central nervous system. *J Neuropathol Exp Neurol* 37:165-173, 1978.