

P. Mancuso  
I. Chiaramonte  
M. Carpinteri  
S. Cicero  
A. Zingale  
L. Basile  
R. Tropea

## Idiopathic middle cerebral artery occlusion in children: report on three cases

Received: 27 November 1991

P. Mancuso<sup>1</sup> (✉) · I. Chiaramonte  
M. Carpinteri · S. Cicero · A. Zingale  
L. Basile · R. Tropea  
Istituto di Neurochirurgia,  
Università degli studi di Catania,  
Piazza S. Maria di Gesù, 2,  
I-95100 Catania, Italy  
Fax: (095) 31 71 07

<sup>1</sup> Mailing address:  
Via Necropoli Grotticelle, 16/A,  
I-96100 Siracusa, Italy

**Abstract** Three cases of middle cerebral artery occlusion in children are reported. The origin of M1 was the site of occlusion in two cases, while occlusion 1 cm after the origin of M1 was found in the third. The possible etiological diagnosis was infectious arteritis in the first two cases, cranial trauma in the third. In no case were serious contralateral motor deficits detected in follow-up examinations. Follow-up

digital subtraction angiography showed complete regression of arterial lesions in the second case. The authors conclude that middle cerebral artery occlusion may have a benign clinical course in children; surgical revascularization is indicated only in highly selected cases.

**Key words** Cerebral ischemia  
Cerebral arteritis  
Middle cerebral artery

### Introduction

Cerebrovascular occlusive disease is relatively frequent in adults, in whom atherosclerosis is implicated as the most common cause. Cerebral infarction is rare in children, however, where the incidence according to Schoenberg et al. [12] is 2.52 cases per 100 000 per year, 55% of which are ischemic. Among the many causes of pediatric stroke are heart or systemic diseases [3, 10] (leukemia, sickle cell anemia, homocystinuria, collagen diseases), arteritis of infectious or idiopathic origin, and trauma; atherosclerosis has been reported as a rare cause [4].

With cerebral angiography and, more recently, computed tomography (CT) and magnetic resonance imaging (MRI), the individual ischemic lesions can be accurately diagnosed and well evaluated in terms of their anatomical location and extension. Radiologically, pediatric stroke differs very little from adult ischemic stroke, but the histological response of the young brain and various etiological and physiopathological factors may produce expected clinical courses in children, requiring different management options.

This report deals with three cases of idiopathic middle cerebral artery occlusion with a benign clinical course in pediatric patients.

### Case reports

#### Case 1

A 12-year-old boy was referred to our institute 1 week after suffering a right hemiparesis and mixed aphasia of gradual onset. The clinical picture had been heralded by transient ischemic attacks in the left carotid territory. Cerebral CT and MRI performed in the referring hospital revealed two ischemic lesions, the first in the anterior limb of the left internal capsule, the second located in the left posterior temporal lobe (Fig. 1). Laboratory tests, electro- and echocardiogram and medical evaluation all had normal findings. Cerebral angiography showed total occlusion of the origin of the left middle cerebral artery with late filling of insular branches via collateral circulation from the pericallosal and posterior cerebral arteries. Severe stenosis of the supraclinoid tract of the internal carotid artery was also detected (Fig. 2).

The patient's neurologic status improved with physiotherapy, and 1 month after onset he was able to walk.

An embolic etiology of the stroke was excluded due to the normal cardiologic findings; the angiographic picture with concurrent carotid siphon stenosis suggested a diagnosis of infectious arteritis, presumably from an undiagnosed nasopharyngeal infection.

#### Case 2

This 9-year-old boy was admitted to our institute with the neurologic signs and symptoms of left hemiparesis and left lateral homony-

mous hemianopia. Cerebral CT showed diffuse swelling of the right hemisphere with a midline shift. MRI showed a large right temporoparietal infarction (Fig. 3). Cerebral angiography showed total occlusion of the origin of the right middle cerebral artery and marked carotid siphon stenosis (Fig. 4). Laboratory tests and cardiologic and medical evaluations all gave normal findings.

The clinical course was favorable, and 2 years after onset the patient is able to walk and has virtually no neurologic complaints apart from a slight left-side spasticity. A diagnosis of arteritis was made on the basis of multiple arterial lesions. Digital subtraction angiography 2 months later disclosed recanalization of the middle cerebral artery; carotid stenosis was no longer visible (Fig. 5).

### Case 3

This 8-year-old boy was referred to our institute from the Pediatric Department with a past clinical history of cranial trauma. Neurologic examination disclosed no focal deficits apart from moderate mental retardation and slight choreoathetosis. CT showed an ischemic lesion in the head of the right caudate nucleus. MRI confirmed the diagnosis and in addition showed a hypointense lesion in the right sylvian cistern (Fig. 6); a possible diagnosis of sylvian arteriovenous malformation was made. Laboratory tests and cardiologic and medical evaluations had normal results. Cerebral angiography showed total right middle cerebral arterial occlusion 1 cm after the origin; collateral circulation was via the lenticulostriate (the possible arteriovenous malformation seen on MRI), pericallosal, and posterior cerebral arteries. Concurrent occlusion of the terminal tract of the homolateral posterior temporal artery together with an accessory middle cerebral artery were also shown (Fig. 7).

Possible etiological diagnosis was post-traumatic occlusion of the right middle cerebral artery, although a diagnosis of arteritis could not be excluded.

### Discussion

Unlike in adults, atherosclerosis plays a minor role in stroke in children, many other etiological or predisposing factors such as sickle cell anemia, homocystinuria, congenital or acquired cardiac malformations, leukemias, disseminated intravascular coagulation, or familial lipid or lipoprotein abnormalities being more common [3, 5, 10].

The patients described here are not amenable to surgery, and medical treatment of the underlying disease represents the only therapeutic option. However, several other cases of pediatric stroke have been reported which were amenable to complete neuroradiologic study and, eventually, to surgical treatment. Shillito [14] reported 25 cases of ischemic stroke in children managed from 1948 to 1962. Review of angiographic studies resulted in 6 diagnoses of internal carotid artery occlusion in the neck and 21 of intracranial vascular occlusive lesions. Two patients underwent middle cerebral artery embolectomy. Eighteen had had a respiratory infectious disease, high fever, or childhood exanthema prior to the onset of neurologic deficits; no predisposing factors were found in the remaining seven patients. Shillito concluded that

nasopharyngeal or paranasal sinus infections may result in intracranial arterial occlusion due to either extension of arteritis to carotid artery branches or thromboembolism. Egg-Oloffson et al. [2] found a preceding nasopharyngeal infection in 6 of 11 cases of pediatric stroke. They concluded that bacterial or viral respiratory infections may lead to arteritis with consequent thromboembolic occlusions.

A controversial issue is the role played in pediatric stroke by anatomical variations of the carotid such as kinking or coiling. Sarkari et al. [11] reported 9 cases of pediatric stroke or transient ischemic attacks where cerebral angiography showed such variations on the symptomatic side. Parrish and Byrne [9] reported 9 cases of pediatric stroke where angiographic studies showed an internal carotid coiling on the symptomatic side. Hilal et al. [6], by contrast, reviewed 87 cases of pediatric stroke and found intracranial arterial occlusions in 17 cases but no cases of concurrent carotid kinking or coiling.

Moya-moya disease is a chronic occlusive cerebrovascular disorder that can cause severe permanent neurologic deficits in children. The results of surgical treatment are encouraging [1, 7]; surgery must be performed before permanent deficits have developed [8].

Carotid fibromuscular hyperplasia was recognized as a possible cause of pediatric stroke only in 1977 when Shields [13] reported two cases where the characteristic "string of beads", which usually involves the extracranial carotid artery, involved the intracranial carotid and middle cerebral arteries. The rarity of the disease in children, however, makes it impossible to determine precise indications for surgical treatment.

→  
**Fig. 1** Case 1. CT shows a hypodense lesion involving the left internal capsule and the posterior part of the temporal lobe

**Fig. 2** Case 1. Cerebral angiography shows complete occlusion at the origin of the left middle cerebral artery; severe stenosis in the terminal tract of the carotid siphon is also visible

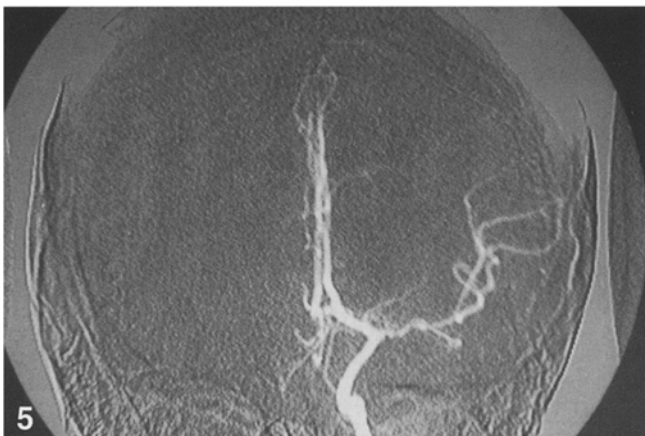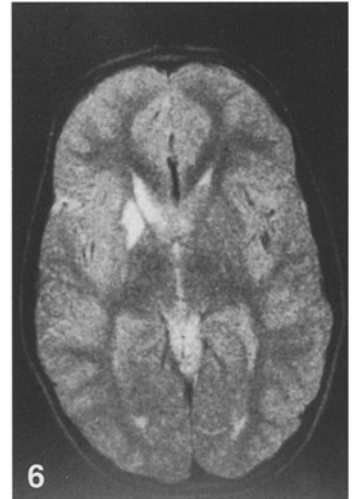
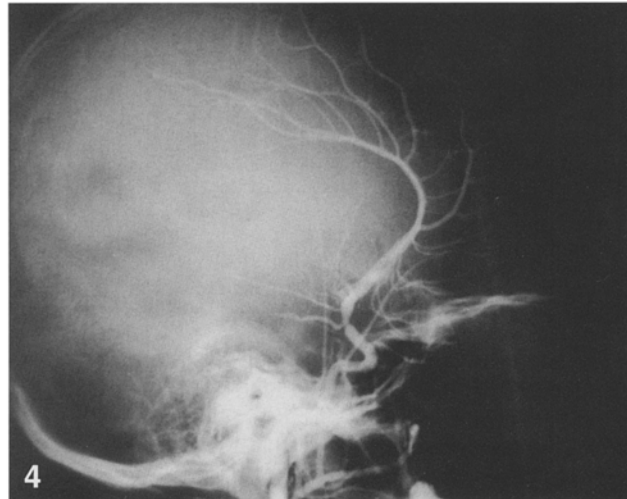
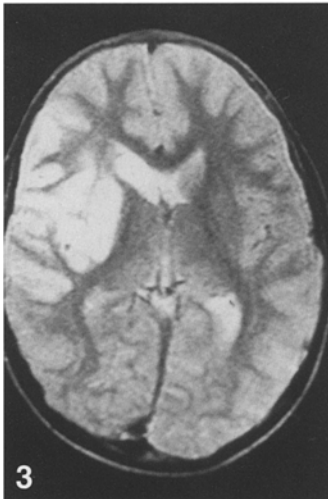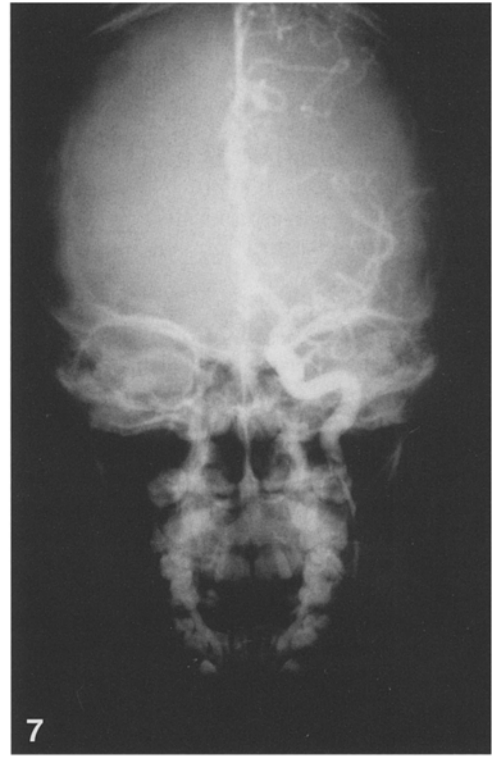
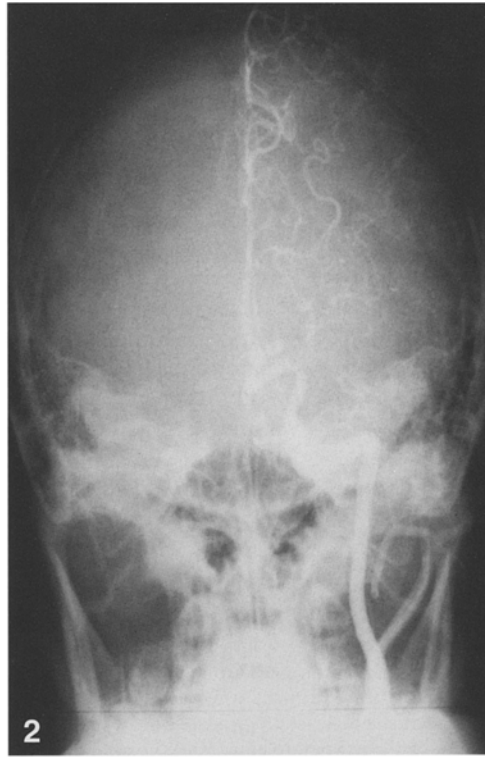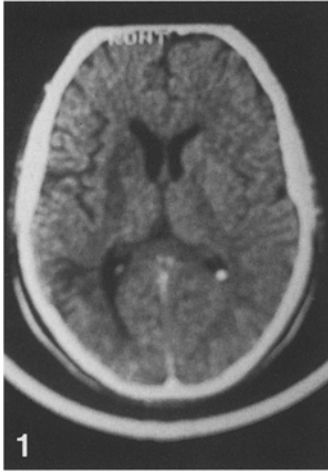
**Fig. 3** Case 2. T2-weighted MRI shows a left insulotemporal hyperintense lesion

**Fig. 4** Case 2. Cerebral angiography shows complete occlusion of the origin of the right middle cerebral artery; severe stenosis of the carotid siphon is also visible

**Fig. 5** Case 2. Follow-up digital subtraction angiography shows right middle cerebral artery recanalization; the carotid stenosis is no longer visible

**Fig. 6** Case 3. MRI shows a hyperintense lesion in the head of the right caudate nucleus

**Fig. 7** Case 3. Cerebral angiography shows occlusion of the right middle cerebral artery 1 cm after the origin; collateral circulation via the lenticulostriate and pericallosal arteries is also visible



## Conclusions

The clinical and etiological diagnosis of pediatric stroke is difficult due to the variety of causes and mechanisms underlying the condition. No etiological factors were clearly identified in the cases reported by us, since medical records did not show concurrent metabolic or cardiac diseases and neuroradiologic examinations did not suggest any chronic arteritis such as moyamoya.

In cases 1 and 2, cerebral angiography showed total occlusion of the origin of the middle cerebral artery associated with severe stenosis of the homolateral carotid siphon; the multiplicity of anatomical locations and total reversibility of the lesions, demonstrated at follow-up angiography in case 2, might be suggestive of a diagnosis of arteritis even though no symptoms or signs of infection

were recorded in either patient. Case 3 was different since the middle cerebral artery occlusion was detected 1 cm after the origin and cerebral infarction was confined to the head of the caudate nucleus; a presumptive diagnosis of traumatic occlusion was made even though no certain etiological factors could be determined.

While the potential benefit of surgery has been established in patients affected by moyamoya disease [1, 7, 8], little data is available on the role of surgical revascularization in children with idiopathic intracranial arterial occlusions.

In our opinion, the anatomical potential of sufficient collateral circulation in the immature brain [10] with the possibility of a good neurologic recovery and the reversibility of arterial occlusions, as demonstrated in case 2 by serial angiography, make surgery indicated only in highly selected cases.

## References

1. Ausman JI, Diaz FG, Ma SH, Dujovny M, Sadasivan B (1988) Cerebrovascular occlusive disease in children. A survey. *Acta Neurochir (Wien)* 94: 117-128
2. Egg-Oloffson O, Ringheim Y (1983) Stroke in children: clinical characteristics and prognosis. *Acta Paediatr Scand* 72: 391-395
3. Ferris EJ, Levine HL (1973) Cerebral arteritis: classification. *Radiology* 109: 327-341
4. Harvey FH, Pluord EG (1972) Juvenile cerebral arteriosclerosis and other cerebral arteriopathies of childhood - six autopsied cases. *Acta Neurol Scand* 48: 479-509
5. Harwood-Nash DC, McDonald P, Argent W (1971) Cerebral arterial disease in children. An angiographic study of 40 cases. *AJR* 111: 672-686
6. Hilal SK, Solomon GE, Gold AP, Carter S (1971) Primary cerebral arterial occlusive disease in children. I. Acute acquired hemiplegia. *Radiology* 99: 71-86
7. Matsushima Y, Inaba Y (1984) Moyamoya disease in children and its surgical treatment. *Child's Brain* 11: 155-170
8. Olds MV, Griebel RW, Hoffman HJ, Craven M, Chuang S, Schutz H (1987) The surgical treatment of childhood moyamoya disease. *J Neurosurg* 66: 675-680
9. Parrish CM, Byrne FP (1971) Surgical correction of carotid artery obstruction in children. *Surgery* 70: 962-968
10. Raybaud CA, Livet MO, Jiddane M, Pinsard N (1985) Radiology of ischemic strokes in children. *Neuroradiology* 27: 567-578
11. Sarkari NB, Holmes JM, Bickerstaff ER (1970) Neurologic manifestations associated with internal carotid loops and kinks in children. *J Neurol Neurosurg Psychiatry* 33: 194-200
12. Schoenberg BS, Mellinger JF, Schoenberg DG (1978) Cerebrovascular disease in infants and children: a study of incidence, clinical features and survival. *Neurology* 28: 763-768
13. Shields WD, Ziter FA, Osborn AG, Allen J (1977) Fibromuscular dysplasia as a cause of stroke in infancy and childhood. *Pediatrics* 59: 899-901
14. Shillito J (1964) Carotid arteritis: a cause of hemiplegia in childhood. *J Neurosurg* 21: 540-551