

# A Case of Cerebral Infarction Associated with Positive Antiphospholipid Antibody in a Systemic Lupus Patient

Eun Rae Jo, M.D., Hyun Jae Shin, M.D., Jae Hong Seo, M.D.,  
Sang Hwa Lee, M.D., Gwan Gyu Song, M.D. and Heui-Jung Pyo, M.D.

Department of Internal Medicine, Guro Hospital, College of Medicine, Korea University,  
Seoul, Korea

*Antiphospholipid antibody syndrome is a newly-defined clinical entity of arterial thrombosis, venous thrombotic events, recurrent spontaneous abortion and thrombocytopenia in the presence of antiphospholipid antibodies.*

*We have experienced a 23-year-old male SLE patient with positive anticardiolipin antibody who presented with left hemiparesis and paresthesia. The clinical and laboratory findings were compatible with the criteria for SLE and he was found to have anticardiolipin antibody, thrombocytopenia, prolonged partial thromboplastin time and cerebral thrombosis. Initially, he was treated with high dose steroid and warfarin and now he is being followed up with warfarin and steroid.*

**Key Words:** Antiphospholipid antibody, SLE, Cerebral thrombosis

## INTRODUCTION

In 1987, Harris et al<sup>1)</sup> proposed that the combination of clinical features, including both venous and arterial occlusive events, recurrent spontaneous abortions and thrombocytopenia with antiphospholipid antibodies (aPL), should be termed the "antiphospholipid antibody syndrome" (APS). Here, we describe a case of secondary APS in a systemic lupus patient who presented with cerebral infarction in the presence of anticardiolipin antibodies.

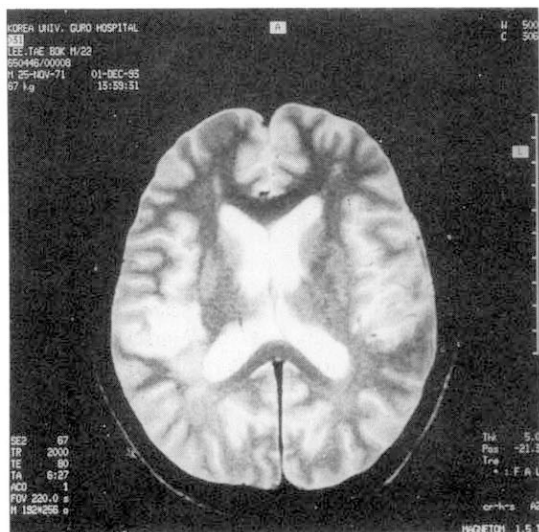
## CASE REPORT

A 23-year-old Korean man was admitted with a chief complaint of weakness and decreased sensation of left arm and leg for 7 days. He had suffered from polyarthralgia and generalized edema for 2 years, and took herbal medicine occasionally. He had a history of hair loss, but he didn't complain about allergies, photosensitivity, skin rash, oral ulcer, dry mouth, dry eye and Raynaud's phenomenon. On examination, he was normotensive (110/70 mmHg) but febrile (37.8 C). He appeared acutely ill, but showed alert mentality. There were no path-

ologic lesions in his ears, eyes, nasal or oral mucosa. The pulmonary and cardiac examinations were normal. The abdominal examination revealed shifting dullness. His joints were unremarkable, there was no cutaneous vasculitis and all peripheral pulses were present with no arterial bruits. Neurologically, he had left-side paresthesia, hemiparesis and a brisk, deep tendon reflex, but other abnormal neurologic signs were not noted.

On admission, white blood cell count was  $6.4 \times 10^3/\text{mm}^3$  with left shift (seg.neut. 55%, band neut. 32%, lymph. 10%, mono. 3%). Hematocrit was 15%, hemoglobin 5.5 gm/dl, and the reticulocyte count was 3.5%. The erythrocyte sedimentation rate was elevated at 23 mm/h (Westergren). The direct Coomb's test was positive. Review of the peripheral blood smear showed unremarkable red cell morphology. Urinalysis showed 100 mg/dl protein, 5-7 white cells and many red cell. The urine hemosiderin and hemoglobin were negative. Renal function evaluation revealed blood urea nitrogen 26 mg/dl, creatinine 1.5 mg/dl, 24 hr urine protein 3.4 gm/day, and the creatinine clearance was 55 ml/dl. The serum electrolyte were normal, except for potassium of 3.2 mmol/l. The AST was 34 IU/l, ALT 42 IU/l, alkaline phosphatase 48 IU/l, total bilirubin 0.7 mg/dl, total protein 5.8 gm/dl and albumin 2.7 gm/dl. The platelets were  $22 \times 10^3/\text{ml}$ , PT 10.7/100 (sec/%) and aPTT 34/28(sec, patient/control). Rheumatoid factor was negative and ANA was positive (speckled pattern, titer 1:160). The anti-dsDNA antibody was above 100 U/ml (N; 0-25

Address requests for reprints to: Gwan Gyu Song, M.D., Department of Internal Medicine, Guro Hosp., Korea Univ. Med. Ctr., #80 Guro-dong, Guro-gu, Seoul, 152-050, Korea



**Fig. 1.** Axial, T2-weighted spin echo MRI scan of brain shows area of high signal intensity in right parieto-temporal white matter.

U/ml). The anti-Sm, anti-RNP, anti-Ro and anti-La antibodies were all positive. Complement levels were decreased at C3 26.5 mg/dl (N; 52.6~120 mg/dl), C4 8.0 mg/dl (N; 20.5~49 mg/dl). Anticardiolipin antibodies (aCL) were positive for both IgG and IgM (by ELISA) and VDRL was reactive, TPHA nonreactive and FTA-Abs negative. The levels of protein C, protein S and antithrombin III were within normal limits. Plain radiology of chest was normal. Abdominal ultrasonography revealed moderate amount of ascites, splenomegaly and diffusely increased renal parenchymal echogenicity. Magnetic resonance imaging (MRI) brain scan revealed ischemia in right parieto-temporal white matter (Fig. 1). EKG showed sinus bradycardia and low voltage on limb leads. Echocardiography confirmed mild pericardial effusion without vegetation and thrombus.

**Course:** He was diagnosed as APS with cerebral thrombosis in SLE. He was given methylprednisolone pulse therapy and oral prednisolone. Kidney biopsy showed mixed class III and V (focal and segmental proliferative glomerulonephritis and membranous lupus glomerulonephritis) lesion with activity score 4/24, and chronicity score 1/21. After the kidney biopsy, anticoagulation therapy was begun with warfarin.

## DISCUSSION

Lupus anticoagulant, which was described in the 1950s by Conley and Hartman<sup>2)</sup>, was first associated with thrombotic events by Bowie et al in 1963<sup>3)</sup>. In 1987, Harris et al proposed that the combination of clinical features, including both venous and arterial occlusive events, recurrent spontaneous abortions and thrombocytopenia with anti-phospholipid antibodies, identified as moderate to high titers of IgG or IgM anticardiolipin antibody or the lupus anticoagulant, should be termed as the 'antiphospholipid syndrome'<sup>1)</sup>. Minor manifestations continue to be described. Cutaneous manifestations, including livedo reticularis and leg ulcers not related to venous insufficiency, are well described<sup>4)</sup>. Our patient, who was compatible with diagnostic criteria for SLE was found to have anticardiolipin antibody, false positive VDRL, prolonged partial thromboplastin time, thrombocytopenia and cerebral thrombosis. Although the majority of thrombotic episodes in patients with APL are venous<sup>5,6)</sup>, when thrombosis occurs in the arterial circulation, the brain is affected most often<sup>7,8)</sup>, and also can result in ocular complications<sup>9)</sup>, peripheral arterial disease and livedo reticularis. Cerebral ischemia is the most common neurologic symptom associated with APL<sup>10)</sup>. Venous thrombosis is often recurrent, and is frequently accompanied by pulmonary embolism. Hypertension has also been described in APS and attributed to renal thrombotic microangiopathy<sup>11)</sup>. The average prevalence of lupus anticoagulant in SLE was reported as 34%, and anticardiolipin as 44%<sup>12)</sup>.

Antiphospholipid antibodies (aPL) are defined by solid-phase immunoassay<sup>13)</sup> and phospholipid-dependent coagulation tests<sup>14)</sup>. When detected by solid-phase immunoassay, they may be named for the specific negatively charged phospholipid, such as cardiolipin, that is used as the antigen. When detected by phospholipid-dependent coagulation tests, they are called lupus anticoagulant (LAC). A prolonged activated partial thromboplastin time (APTT) is the most useful screening test for LAC, but it is considered to be an insensitive test. In general, coagulation tests with the least amount of phospholipid in the test system are the most sensitive<sup>15)</sup>. The protocols for performing solid-phase assays for aPL most commonly utilize a standard ELISA technique. However, the definition

of aPL positivity is far from uniform. A strong correlation exists between elevated anticardiolipin levels and the lupus anticoagulant<sup>12)</sup>. However, the two antibodies appear to be distinct and may be directed against different epitopes<sup>19)</sup>. The consensus of opinion is that antiphospholipid antibodies have a pathogenetic role in the vasculopathy of the antiphospholipid syndrome, but the mechanism is unknown. Any or all of the major components of the clotting system may be involved in aPL pathogenicity, including the coagulation cascade (many of these steps are phospholipid dependent), platelet activation and aggregation, and endothelial cell function. Interference with each of these has been postulated as a possible mechanism<sup>17)</sup>.

Laboratory abnormalities that can be seen in patients with aPL include a biologically false positive VDRL test, a prolonged activated partial thromboplastin time (APTT) and thrombocytopenia; an elevated erythrocyte sedimentation rate, positive antinuclear antibody (ANA) and elevated anti-DNA titers occur occasionally<sup>10)</sup>. In a patient with thrombosis or fetal loss, the presence of any or all of these findings should be considered as clues that prompt evaluation for aPL.

There are no convincing data supporting the use of any specific treatment modality in patients with APS. For the treatment of patients who had thrombotic events, longterm coagulation may be preferable<sup>18-20)</sup>. A major question is whether or how to treat patients with SLE (or others), who have never had a clinical event, with aPL. The clinical correlations of IgG and IgM aCL in patients with APS in SLE were reported that there is high correlation between IgG aCL titer and ITP, recurrent venous thrombosis and fetal loss, also between IgM aCL and livedo reticularis and chronic leg ulceration. Therefore, in patients with rheumatologic conditions, the occurrence of ischemic events, ITP, renal abnormalities or hypertension should arouse the suspicion of APS and aPL. Consideration should be given to prophylactic aspirin therapy in patients with moderate or strongly positive IgG aCL, even in the absence of any symptomatology, because there is strong correlation (in patients with SLE) of a moderately or strongly positive IgG aCL with thrombosis.

## REFERENCES

1. Harris EN, Baguley E, Asherson RA, Hughes GRV: *Clinical and serological features of the "antiphospholipid syndrome" (APS)*. *Br J Rheumatol*

- 26:19, 1987
2. Conley CL, Hartman CA: *A haemorrhagic disorder caused by circulating anticoagulants in patients with disseminated lupus erythematosus*. *J Clin Invest* 31:621, 1953
3. Bowie EJ, Thompson JH, Pasetuzzi CA, Owen CA: *Thrombosis in systemic lupus erythematosus despite circulating anticoagulants*. *J Lab Clin Med* 62:416, 1963
4. Peter M: *The clinical syndrome associated with antiphospholipid antibodies*. *J Rheumatol* 19:4, 1992
5. Elias M, Eldor A: *Thromboembolism in patients with the "lupus" type circulating anticoagulant*. *Arch Intern Med* 144:510, 1984
6. Alarcon-Segovia D, Deleze M, Oria CV: *Antiphospholipid antibodies and the antiphospholipid syndrome in systemic lupus erythematosus*. *Medicine* 68:353, 1989
7. Hart RG, Miller VT, Coull BM: *Cerebral infarction associated with lupus anticoagulants-preliminary report*. *Stroke* 15:114, 1984
8. Asherson RA, Khamashta MA, Gil A: *Cerebrovascular disease and antiphospholipid antibodies in systemic lupus erythematosus, lupus-like disease and the primary antiphospholipid antibody syndrome*. *Am J Med* 86:391, 1989
9. Galetta SL, Plock GL, Kushner JM, Wyszynski RE, Brucker AJ: *Ocular thrombosis with antiphospholipid antibodies*. *Ann Ophthalmol* 23:207, 1991
10. Levine SR, Welch KMA: *The spectrum of neurological disease associated with antiphospholipid antibodies*. *Arch Neurol* 44:876, 1987
11. Asherson RA, Cervera R: *The antiphospholipid syndrome: A syndrome in evolution*. *Ann Rheum Dis* 51:147, 1992
12. Paul EL, Samuel AS: *Antiphospholipid antibodies: Anticardiolipin and the lupus anticoagulant in Systemic Lupus Erythematosus and in non-SLE disorders*. *Ann Int Med* 112:682, 1990
13. Harris EN: *Serological detection of antiphospholipid antibodies*. *Stroke* 23 (Suppl 2):3, 1992
14. Triplett DA: *Coagulation assays for the lupus anticoagulant: Review and critique of current methodology*. *stroke* 23 (Suppl 2):11, 1992
15. Robin LB, Azzudin EG, Michael DL: *Neurologic complications of antiphospholipid antibodies*. *Rheumatic Disease Clinics of North America* 19: 833, 1993
16. McNeil Hp, Chesterman CN, Krillas SA: *Anticardiolipin antibodies and lupus anticoagulants comprise separate antibody subgroups with different phospholipid binding characteristics*. *Br J Haematol* 78:506, 1989
17. Lisa RS, Azzudin EG, Michael DL: *Antiphospholipid antibody syndrome: Immunologic and*

- clinical aspects.* 20:81, 1990
18. Rosove MH, Brewer PM: *Antiphospholipid thrombosis: Clinical course after the first thrombotic event in 70 patients.* *Ann Intern Med* 117:303, 1992
  19. Derksen RHWM, de Groot PhG, Kater L: *Patients with antiphospholipid antibodies and venous thrombosis should receive life-long anticoagulant treatment.* *Clin Exp Rheumatol* 10:662, 1992
  20. Petri M, Hochberg M, Hellmann D: *Incidence of and predictors of thrombotic events in systemic lupus erythematosus: A five year prospective study.* *Arthritis Rheum* 34:S44, 1991
-