

cluded among the hereditary neurological diseases possibly associated with TS-like disorders.

N. Nardocci
V. Rumi
M. L. Combi
L. Angelini

Department of Child Neurology, Istituto Nazionale
Neurologico "C. Besta", Milan, Italy

D. Mirabile
USSL n. 30, Seriate, Bergamo, Italy

M. G. Bruzzone
Department of Neuroradiology, Istituto Nazionale
Neurologico "C. Besta", Milan, Italy

References

1. Shapiro AK, Shapiro E. "Tourette syndrome": history and present state. In: Fried Hoff AJ, Chase TN, eds. *Advances in neurology*. New York: Raven, 1982:17-23.
2. Jankovic J. The neurology of tics. In: Marsden CD, Fahn S, eds. *Movement disorders 2*. London: Butterworth, 1987: 383-422.
3. Jankovic J. Recent advances in the management of tics. *Clin Neuropharmacol* 1986;9:100-110.
4. Fahn S, Marsden CD, Calne DB. Classification and investigation of dystonia. In: Marsden CD, Fahn S, eds. *Movement disorders 2*. London: Butterworth, 1987:332-358.
5. Wigboldous JM, Bruyn GW. Hallervorden-Spatz disease. In: Vinken PJ, Bzuyn GW, eds. *Handbook of clinical neurology*. Amsterdam: Elsevier Science, 1968:604-631.
6. Angelini L, Nardocci N, Rumi V, Strada L, Savoiaro M. Hallervorden-Spatz disease: clinical and MRI study of 11 cases diagnosed in life. *J Neurol* 1992;239:417-425.
7. Jankovic J, Kirkpatrick JB, Blomquist KA, Langlais PJ, Bird ED. Late onset Hallervorden-Spatz disease presenting as familial parkinsonism. *Neurology* 1985;35:227-234.
8. Dooling EC, Schone WC, Richardson EP Jr. Hallervorden-Spatz syndrome. *Arch Neurol* 1974;30:70-83.
9. Newell FW, Johnson RO, Huttenlocher PR. Pigmentary degeneration of the retina in the Hallervorden-Spatz syndrome. *Am J Ophthalmol* 1979;88:467-471.
10. Savoiaro M, Halliday WC, Nardocci N, et al. Hallervorden-Spatz disease: MR and pathologic findings. *Am J Neuroradiol* 1993;14:155-162.
11. Schaffert DA, Johnsen SD, Johnson PC, Drayer BP. Magnetic resonance imaging in pathologically proven Hallervorden-Spatz disease. *Neurology* 1989;39:440-442.

Micrographia with Cognitive Dysfunction: "Minimal" Sequelae of a Putaminal Infarct

To the Editor:

Micrographia is a clinical sign of basal ganglia disease and is most commonly seen in a parkinsonian syndrome. It has been described secondary to focal lesions of the left basal ganglia, including a hematoma (1), lymphoma (2), and small deep infarct (3), but in these three cases the original lesions were not restricted to a single subcortical structure. Micrographia also has been seen in association with a parkinsonian syndrome in a patient with bilateral basal ganglia lesions secondary to cyanide ingestion (4).

Left-sided subcortical infarcts (5) and hemi-Parkinson's disease with predominantly right-sided signs (6) are associated with language and verbal memory deficits, and a right basal ganglia hematoma has been associated with a disruption of automatic speech (7), but the neuropsychological effect of a lesion restricted to the dominant putamen is unclear. We report a patient who developed a prominent micrographia and mild deficits in expressive language and verbal memory secondary to a small deep infarct restricted to the left posterior putamen.

Case Report

A right-handed 63-year-old man with borderline hypertension, but no other past medical history, and no history of cognitive dysfunction noted sudden onset of slurring of speech and difficulty using his right hand. He reported slight drooping of the right side of his mouth but noticed no numbness or visual disturbance. On examination he had slight dysarthria and slight proximal weakness of his right arm and leg, which recovered over the next few days. A cerebral computed tomography (CT) scan was normal. A magnetic resonance imaging (MRI) scan showed a small deep infarct in the posterior left putamen (Fig. 1). On discharge from the hospital the patient noted that his handwriting had become smaller. A year later, he was able to write larger, with concentration, but without conscious attempts at correction still displayed progressive micrographia with some deterioration in the control of his writing (Fig. 2). He also complained of occasional word-finding difficulty and forgetfulness since his stroke, although he had developed compensatory strategies to overcome these. On examination at this time he had normal muscle tone and no rest tremor. A slight reduction in amplitude of finger tapping and of rapid repetitive alternating finger flexion and extension was noted toward the end of sustained motor sequences. With the exception of minimal weakness of finger abduction on the right side, muscle strength was normal. Muscle stretch reflexes were normal and symmetric and plantar responses were

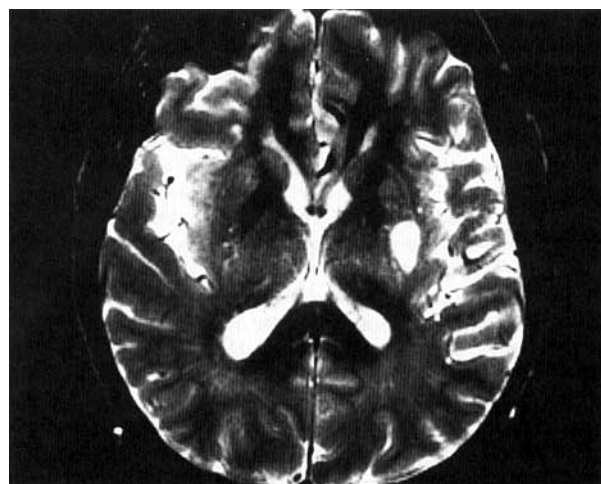


FIG. 1. T2-weighted MRI scan showing infarct of the left posterior putamen.

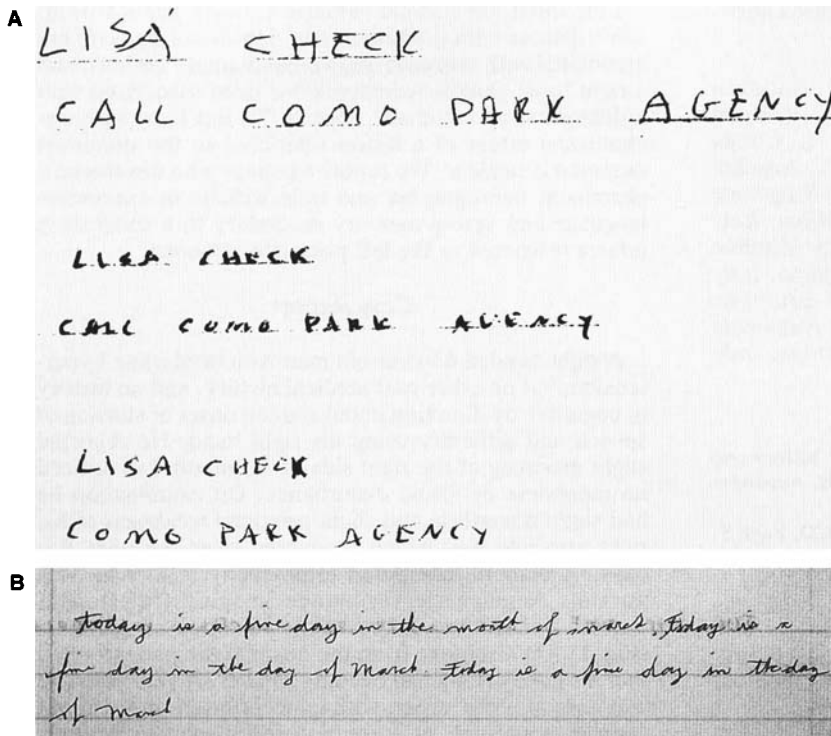


FIG. 2. A: Samples of the patient's handwriting: top line, before the stroke; middle line, 3 weeks after the stroke; bottom line, 1 year after the stroke. B: Sample of the patient's script 1 year after the stroke showing progressive decrease in size and deterioration of writing control. Note the substitution of "day in the day of March" for "day in the month of March," which is probably a perseverative error that is in keeping with the patient's other frontal dysfunction noted and discussed in the text.

flexor bilaterally. He had slightly diminished arm swing on the right side when walking, but steppage, posture, and balance were normal. There was no evidence of hypophonia, hypomimia, or generalized bradykinesia.

Neuropsychological evaluation showed no evidence of deterioration in global cognitive impairment after the stroke. The patient also displayed normal abilities on tests requiring visuospatial construction and abstract reasoning. In contrast to these average or above average scores, his performance on a test of rapid word retrieval was at least 1 SD below average. Tests of picture naming and learning of a 16-item word list demonstrated more significant impairments at least 2 SD below expectation.

Discussion

Martinez-Vila et al. reported a patient in whom micrographia was the only residual sign after a large left lenticular nucleus hemorrhage (1). CT performed 2 months later showed a hypodense lesion that mainly involved the putamen. Yoshida et al. (3) reported a patient with a subcortical infarct involving the left putamen and corona radiata in whom micrographia persisted for 7 months. Although the putamen was affected in both these cases, other subcortical structures were involved. Taken with these reports, our case strongly implicates dysfunction of the dominant putamen in the genesis of micrographia. This is not unexpected, given the greater dopamine deficiency of the putamen compared with the caudate nucleus in Parkinson's disease (8) and the primary role of the putamen in motor control (9). Our case is unusual in the extent to which the patient has been able to compensate for his micrographia. This may reflect the small size of the

putaminal infarct as well as the tendency to recover after an infarct as opposed to the tendency for progression in Parkinson's disease. Neuropsychological studies have also implicated frontal cortical dysfunction early in the course of Parkinson's disease (10), when micrographia typically manifests. The frontal cortical dopamine deficiency in Parkinson's disease may contribute to the appearance of and relative inability to compensate for micrographia.

Marsden has suggested that the basic abnormality in Parkinson's disease may be a failure of basal ganglia direction of premotor cortical areas to select the correct parameters for subsequent motor programs (11). Our case supports the idea that putaminal dysfunction may be sufficient to produce the "progressive fade and collapse" (11) of complex repetitive and sequential motor actions that is exemplified by micrographia. Together with previous observations (3), our case suggests that there may be a delayed but ultimately good recovery from the micrographia secondary to a stroke, contrasting with the typical progression of this disability in untreated Parkinson's disease and related neurodegenerative disorders.

Our patient's neuropsychological deficits also may be due to "remote effects" of basal ganglia dysfunction, the putaminal infarct resulting in partial frontal "deafferentation" via the striato-pallido-thalamo-cortical loop (12). This may lead to a lack of activation of cognitive programs, which are required for systematic retrieval of information from long-term memory. Our patient's deficits on tests of rapid word retrieval, picture naming, and verbal learning and his lack of consistency of recall from long-term memory support this hypothesis. Other patients with known pathology affecting the striato-pallido-

thalamo-cortical loops have shown a similar neuropsychological profile. Verbal memory deficits have been found in both right hemi-Parkinson's disease patients (6) and in a patient with striatonigral degeneration affecting primarily the left putamen (13). Slowed word-list generation is also a recognized phenomenon in Parkinson's disease (14) and language deficits have been found in patients with infarcts primarily affecting the putamen (15). The putamen may thus be a critical structure for the production not only of motor-based programs such as writing, but also of cognitive functions such as word retrieval and verbal learning.

P. Pulicino
D. Lichter
R. Benedict

Department of Neurology
State University of New York
Buffalo, New York, U.S.A.

References

- Martinez-Vila E, Artieda J, Obeso J, A. Micrographia secondary to lenticular haematoma. *J Neurol Neurosurg Psychiatry* 1988;51:1353-1356.
- LeWitt PA. Micrographia as a focal sign of neurological disease. *J Neurol Neurosurg Psychiatry* 1983;46:1152-1157.
- Yoshida T, Yamadori A, Mori E. [A case of micrographia with the right hand due to left putaminal infarction]. *Rinsho Shinkeigaku* 1989;29:1149-1151.
- Feldman JM, Feldman MD. Sequelae of attempted suicide by cyanide ingestion: a case report. *Int J Psychiatry Med* 1990;20:173-179.
- Damasio AR, Damasio H, Rizzo M, Varney N, Gersh F. Aphasia with nonhemorrhagic lesions in the basal ganglia and internal capsule. *Arch Neurol* 1982;39:15-20.
- Starkstein S, Leiguarda R, Gershanik O, Berthier M. Neuropsychological disturbances in hemiparkinson's disease. *Neurology* 1987;37:1762-1764.
- Speedie LJ, Wertman E, Ta'ir J, Heilman KM. Disruption of automatic speech following a right basal ganglia lesion. *Neurology* 1993;43:1768-1774.
- Nyberg P, Nordberg A, Webster P, Winblad B. Dopaminergic deficiency is more pronounced in putamen than in nucleus caudatus in Parkinson's disease. *Neurochemical Pathology* 1983;1:193-202.
- Oberg RGE, Divac I. "Cognitive" functions of the neostriatum. In: Divac I, Oberg RGE, eds. *The neostriatum*. Oxford, England: Pergamon, 1979:291-313.
- Lees AJ, Smith E. Cognitive deficits in the early stages of Parkinson's disease. *Brain* 1983;106:257-270.
- Marsden CD. What do the basal ganglia tell premotor cortical areas? In: *Motor areas of the cerebral cortex*. Ciba Foundation Symposium 132. Chichester, England: Wiley, 1987: 282-300.
- Alexander GE, DeLong MR, Strick PL. Parallel organization of functionally segregated circuits linking basal ganglia and cortex. *Ann Rev Neurosci* 1986;9:357-381.
- Sullivan EV, de La Paz R, Zipursky RTS. Neuropsychological deficits accompanying striatonigral degeneration. *J Clin Exp Neuropsychol* 1991;13:773-788.
- Crosson B. *Subcortical functions in language and memory*. New York: Guilford, 1992:42-80.
- Tanridag O, Kirshner HS. Aphasia and agraphia in lesions of the posterior putamen. *Neurology* 1985;35:1797-1801.

A Progressive Parkinsonian Syndrome Developing After Chemotherapy and Radiotherapy for Non-Hodgkin's Lymphoma

To the Editor:

A delayed, progressive encephalopathy is a well recognized complication of chemotherapy and radiotherapy for neoplastic disease, particularly after the combination of intrathecal methotrexate and radiotherapy (1,2). It has recently been proposed that the encephalopathy seen in cancer patients undergoing chemotherapy may provide insight into the processes of cell damage in neurodegenerative disorders such as Alzheimer's disease and Parkinson's disease (3). However, to date a progressive Parkinsonian syndrome after chemotherapy for malignant disease has not been described. We report such a case.

A 22-year-old woman presented with a 2-week history of facial swelling, malaise, and cough. Chest radiography showed a large, lobulated mediastinal mass, which on biopsy proved to be a high-grade non-Hodgkin's lymphoma. She was treated with dexamethasone and allopurinol, and then six cycles of CHOP (cyclophosphamide, doxorubicin, vincristine and prednisolone) at three weekly intervals with doxorubicin 45 mg, vincristine 2 mg, and cyclophosphamide 1.3 g given i.v. on days 1 and 8 of each treatment cycle. On day 8 of the first treatment cycle, 12.5 mg of methotrexate was given intrathecally. No lymphoma cells were detected in the cerebrospinal fluid (CSF) taken at the time of this therapy. Two weeks after the end of the chemotherapy, prophylactic cranial irradiation was given (2,400 rad in 10 treatments over 2 weeks). A chest radiograph taken after treatment was normal.

She remained well until 4 months later, when she noticed a tremor in her left hand. Over the next year the tremor persisted, and she experienced increasing difficulty using her left hand; for example, she found it difficult to use a fork or to make pastry. Her walking slowed and her writing deteriorated. When seen in the neurology department 18 months after the onset of the tremor, she was found to have poverty of spontaneous facial expression and blink, a tremor of both upper limbs (present at rest and on action), cogwheel rigidity of all limbs (more marked on the left than the right), bradykinesia (again more marked on the left than the right), and a positive glabellar tap. She had a stooped posture when walking; spontaneous associated swing of the arm was absent on the left and much reduced on the right. Sensation was normal. Deep tendon reflexes were present and symmetrical, and plantar responses were flexor. There was a normal change in heart rate and blood pressure on standing, and a normal variation in heart rate on deep breathing. There was no family history of any parkinsonian syndrome.

Investigation showed a normal full blood count. Results of studies of urea, electrolytes, calcium, liver enzymes, erythrocyte sedimentation rate, glucose, thyroid function, and copper were normal. Computed tomography of the head, electroencephalography, magnetic resonance imaging (MRI), and single-photon emission com-