

## Short Communication

# Primary Medullary Hemorrhage Report of Four Cases and Review of the Literature

Fernando Barinagarrementeria, MD; Carlos Cantú, MD

**Background** Primary medullary hemorrhage is uncommon. Its clinical profile and prognosis are not well known. We report four cases of medullary hemorrhage and a review of the English and French literature since 1964 to analyze the clinical presentation and prognosis.

**Case Descriptions** Of sixteen case reports of medullary hemorrhage reviewed from the literature, sixteen contained sufficient information for review and are included in this report. The age distribution of the patients was between 13 and 72 years, and 10 of these patients were men. The most frequent symptoms at onset were vertigo, sensory symptoms, and dysphagia. Presenting signs included palatal weakness, nystagmus, hypoglossal palsy, cerebellar ataxia, and limb weakness. The diagnosis was made at autopsy in 3 patients, at

surgery in 3, by computed tomography in 4, and more recently by magnetic resonance imaging in 6. In nine instances the etiology of hemorrhage was undetermined; a ruptured vascular malformation was the cause in 3 patients, 1 was attributed to the use of anticoagulants, and hypertension was the suspected cause in the other 3 patients. Mortality rate was 19%; however, survivors generally had nonincapacitating sequelae.

**Conclusions** These findings indicate that primary medullary hemorrhage presents with a characteristic syndrome of sudden onset of headache and vertigo with neurological signs that correspond to various combinations of medial and lateral medullary involvement. In those patients who survive, prognosis usually is good. (*Stroke*. 1994;25:1684-1687.)

**Key Words** • hematoma • hemorrhage • prognosis

**I**ntracerebral hemorrhage accounts for approximately 10% of strokes.<sup>1,2</sup> Brain stem hemorrhages are often restricted to the pons and represent from 5% to 9% of parenchymatous hemorrhages. The medulla oblongata is an uncommon site of bleeding, and the clinical features, treatment, and prognosis of medullary hemorrhage are not well known. We describe four patients with primary medullary hemorrhage and review others from the literature in an attempt to clarify the clinical and radiological features of this unusual entity.

### Case Descriptions

#### Case 1

A previously well 23-year-old man, initially found unconscious and cyanotic, complained of vertigo, dysphagia, dysarthria, and weakness of the right limbs on awakening. He later developed respiratory failure. On admission he was afebrile, with blood pressure of 140/90 mm Hg, heart rate of 90 beats per minute, and respiratory rate of 22 breaths per minute. He was alert, with bilateral horizontal nystagmus, a left "one-and-a-half" syndrome, right facial hypesthesia, a peripheral left facial palsy, dysarthria and dysphagia, left hypoglossal palsy, quadriparesis, and dysmetria and dysdiadochokinesia of the left limbs.

Computed tomography (CT) disclosed a hematoma in the fourth ventricle region. Magnetic resonance imaging (MRI) showed a hemorrhage in the left dorso-medial medullary region with pontine extension (Fig 1). A four-vessel cerebral angiogram was normal. The patient received supportive therapy. Neurological examination 1 year later revealed a residual "one-and-a-half" syndrome, peripheral facial palsy, and mild dysmetria on the left side.

#### Case 2

A previously healthy 18-year-old man was admitted because of sudden onset of occipital headache followed by vertigo. Two days later he developed cramplike sensations in the hands and feet and clumsiness in the right limbs, predominating in the arm. Physical examination revealed normal vital signs, with blood pressure of 120/80 mm Hg. He was alert and fully oriented, with dysarthric speech. There was a coarse bilateral horizontal nystagmus predominating on left gaze and vertical upbeating nystagmus on upward gaze, right facial hypesthesia, bilateral palatal weakness and areflexia, left hypoglossal palsy, right hemiparesis predominating in the arm, right Babinski's sign, decreased perception of pain and temperature in the right limbs, and left dysmetria and dysdiadochokinesia.

An MRI showed a small hematoma in the left medial medullary region, with ventral extension (Fig 2). A four-vessel cerebral angiogram was normal. Management was conservative. When evaluated 15 months later the patient had a mild right hemiparesis and atrophy of the left half of the tongue.

#### Case 3

A 26-year-old man with history of heavy tobacco use experienced the sudden onset of severe occipital head-

Received March 8, 1994; final revision received May 18, 1994; accepted May 18, 1994.

From the Stroke Clinic, Instituto Nacional de Neurología y Neurocirugía, "Manuel Velasco Suárez," Mexico City, Mexico.

Correspondence to Fernando Barinagarrementeria, MD, Instituto Nacional de Neurología y Neurocirugía, "Manuel Velasco Suárez," Insurgentes Sur 3877, Tlalpan, 14269, Mexico City, Mexico.

© 1994 American Heart Association, Inc.

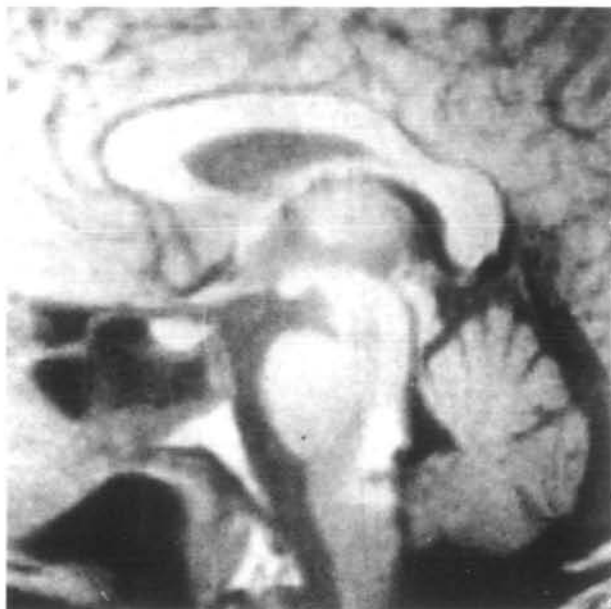

FIG 1. Sagittal T<sub>1</sub>-weighted (repetition time, 520 milliseconds; echo time, 21 milliseconds) magnetic resonance imaging scan showing a dorsal medullary hemorrhage with pontine extension.

ache and vertigo with nausea, vomiting, and a "tingling" sensation in all four limbs. In the following hours he developed dysphagia, dysarthria, and horizontal diplopia. On admission his blood pressure was 130/80 mm Hg. Neurological examination showed a normal level of consciousness, vertical (upward and downward) and bilateral horizontal gaze-evoked nystagmus predominating on left gaze, signs of bilateral palatal weakness and areflexia, and right hypoglossal palsy, right hemiparesis predominating in the leg, decreased sensation to pain and temperature in the right limbs, and bilateral dysmetria and dysidiadochokinesia.

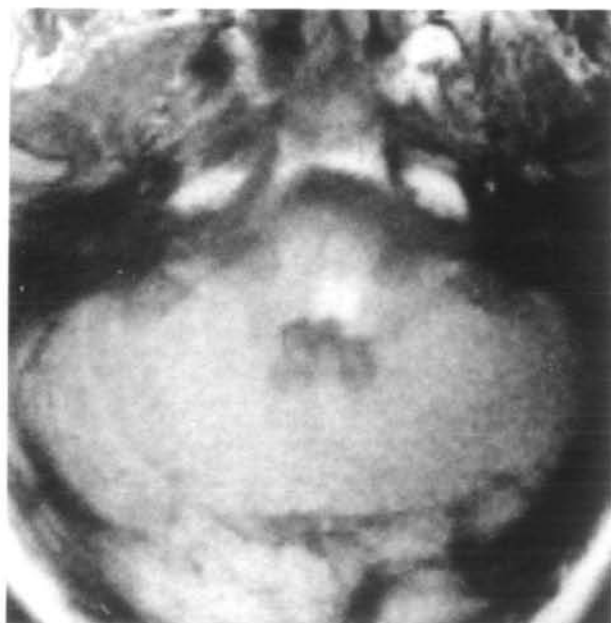


FIG 2. Axial T<sub>1</sub>-weighted (repetition time, 520 milliseconds; echo time, 26 milliseconds) magnetic resonance imaging scan of a hemorrhage in the left medial medullary region with mild ventral extension.

CT showed a small, right occipital hemorrhage. MRI revealed bilateral dorsomedial medullary hemorrhage predominating on the left side and a right occipital hemorrhage. The latter was consistent with rupture of a cavernous angioma. A four-vessel cerebral angiogram was normal. Management was conservative. Neurological evaluation 13 months later revealed unsteadiness of gait and atrophy of the left side of the tongue.

#### Case 4

A previously well 22-year-old woman was admitted because of sudden onset of left frontotemporal headache followed by vertigo and progressive left hemiparesis. She complained of pain on the left side of the neck, dysphagia, and paresthesia of the left limbs progressing to anesthesia. On initial evaluation she was alert, afebrile, with blood pressure of 190/130 mm Hg. She had a right Horner's syndrome, left horizontal nystagmus, upbeat vertical nystagmus on upward gaze, right facial hypesthesia, left palatal weakness and areflexia, left hypoglossal palsy, right hemiparesis predominating in the arm, and decreased sensation to pain and temperature in the left arm. There were no disturbances of coordination.

An MRI showed a left dorsomedial medullary hematoma with ventrolateral extension. A four-vessel angiogram was normal. She received supportive and parenteral antihypertensive therapy and was discharged on day 15 with a mild left hemiparesis. Two years later she suddenly developed headache with loss of consciousness, and she died a few hours later. No diagnostic or autopsy studies were performed.

#### Review of the Literature

In addition to the four cases reported here, by search of MEDLINE through 1963 and bibliographies of pertinent articles through 1950, we found that 18 other patients with medullary hemorrhage have been reported in the literature<sup>3-19</sup> since 1950. We included for analysis those cases with pure medullary hemorrhage and with sufficient clinical information.

We excluded from this analysis 4 cases with predominance of extramedullary hemorrhage<sup>3,7-9</sup> and 2 others from the German literature.<sup>4,5</sup> The mean age in the present series was 40.5 years (range, 13 to 72 years). There were 10 male patients. In 5 patients (31%) there was a history of hypertension, but in 4 there was evidence on admission of high blood pressure. The onset in 14 cases (87.5%) was sudden. The main symptoms included vertigo in 10 patients (62%); sensory symptoms (dysphagia, nausea and/or vomiting) in 8 (50%); headache, dysphonia, dysarthria, and limb incoordination in 7 (44%); decreased alertness in 6 (37%); limb weakness in 5 (31%); and diplopia in 3 (19%). The main neurological findings were as follows: palatal weakness in 14 patients (88%), nystagmus and/or cerebellar ataxia in 12 (75%), limb weakness in 11 (68%), hypoglossal palsy in 9 (56%), sensory disturbance in 7 (43%), peripheral facial palsy in 5 (31%), and neurovegetative abnormalities or Horner's syndrome in 3 (19%). Neuroradiological findings and topography of medullary hemorrhage are shown in the Table.

Definitive diagnosis was reached by neuropathological study in 3 patients, surgery in 3, CT scan in 4, and

**Diagnosis, Treatment, and Outcome in 16 Patients With Primary Medullary Hemorrhage**

	n (%)
<b>Neuroradiological findings</b>	
Angiography (11)	
Normal	11 (100)
Computed tomographic scan (11/13)	
Normal	2 (15)
Lower brain stem hemorrhage	11 (84)
Magnetic resonance imaging (7/16)	
Medullary hemorrhage	6 (85)
Medullary sequela of old hemorrhage*	1 (14)
Topography of medullary hemorrhage	
Isolated medullary location	11 (69)
Intramedullary predominance with mild extramedullary extension	5 (31)

\*Magnetic resonance imaging performed several months after stroke onset.

recently by MRI in 6 patients. The postulated mechanism of hemorrhage was as follows: vascular malformation in 3 patients, hypertension in 3, anticoagulants in 1, and undetermined in 9. Treatment was conservative in 11 patients (69%) and surgical in 5 (31%). Outcome was classified arbitrarily as follows: complete recovery in 3 patients (19%), mild sequelae in 9 (56%), severe sequelae in 1 (6%), and death in 3 (19%).

### Discussion

Spontaneous primary medullary hemorrhage occurs infrequently. In addition to the 4 patients herein reported, we were able to find only 12 examples in the English<sup>6,7,10,11,14,16-19</sup> and French<sup>12,13,15</sup> literature. The first patient treated and diagnosed by surgical procedure, with survival, was reported by Kempe in 1964.<sup>6</sup> Morel-Maroger et al<sup>12</sup> and Biller et al<sup>16</sup> described the first examples of medullary hemorrhage diagnosed by CT scan and MRI, respectively.

Medullary hemorrhage has no age predilection. The majority of reported cases (62%) have been males. The etiology of bleeding was a vascular malformation in 3 patients (18%), including two arteriovenous malformations<sup>10,11</sup> and one cavernous angioma (our case 3), although in our case 4 there was fatal recurrence, suggesting a vascular malformation as the etiology of bleeding. The mechanism in most of the hemorrhages (56%) has been unclear. In a recent series of 24 instances of brain stem cavernous angiomas diagnosed by MRI, three were located in the medulla, and they presented with signs of rupture<sup>20</sup> (clinical data not provided). The causative role of hypertension in medullary hemorrhage has been controversial.<sup>21</sup> Of 4 patients with history of hypertension and high blood pressure on initial evaluation, 1 developed a fatal lower medullary hemorrhage in the setting of excessive oral anticoagulation and uncontrolled hypertension<sup>7</sup>; in 2 others with predominantly medullary location, it is uncertain whether the CT-documented hemorrhage arose in the medulla or in the caudal pons,<sup>12,13</sup> and only

one was a clear instance of primary medullary hemorrhage solely attributable to hypertension.<sup>14</sup>

Because of the few reported cases, the clinical features of primary medullary hemorrhage are poorly delineated. The onset is usually sudden, with headache as the presenting symptom, followed by vertigo, palatal weakness, or sensory disturbances. The most constant findings on examination are palatal dysfunction and nystagmus, often associated with combinations of hypoglossal palsy, limb weakness, sensory disturbances, or cerebellar signs. In addition, several patients have developed respiratory and cardiac disturbances, Horner's syndrome, or hiccups.

Cerebral angiography was normal in all cases. This is a frequent issue in cavernous angiomas where cerebral angiography invariably shows only the vascular effect secondary to the acute hematoma, without abnormal local vascular structures.<sup>22,23</sup>

In conclusion, the clinical picture of primary medullary hemorrhage generally results from a combination of the features of the lateral and medial medullary syndromes. Its treatment has generally been conservative. Although surgical evacuation of medullary hematomas has been performed, the cases reported are too few to allow for treatment recommendations. Our four cases were treated with supportive measures only, and the outcome was satisfactory with relatively mild neurological residual deficits. The risk of recurrence is unknown because there was no follow-up of the reported cases. During the follow-up of our cases (between 12 and 24 months), 1 patient died suddenly, which was probably related to recurrence of bleeding.

Follow-up pathological MRI studies are needed in the future to determine the contribution of cavernous angiomas and other vascular malformations to the occurrence of these hemorrhages.

### Acknowledgment

The authors are grateful to Carlos S. Kase, MD (Neurology Department, Boston University School of Medicine, Mass) for helpful advice and criticism during the completion of this manuscript.

### References

1. Foulkes MA, Wolf PA, Price TR, Mohr JP, Hier DB. The Stroke Data Bank: design methods and baseline characteristics. *Stroke*. 1988;19:547-554.
2. Bogousslavsky J, Van Melle G, Regli F. The Lausanne Stroke Registry: analysis of 1,000 consecutive patients with first stroke. *Stroke*. 1988;19:1083-1092.
3. Bergman PS. Hemangioma of the pons: case report and review of the literature. *J Mt Sinai Hosp*. 1950;17:119-131.
4. Bosch K, Jannssen W. Plötzlicher Tod durch intramedulläres Hämangiom. *Disch Z ges Gerichl Med*. 1962;52:571-577.
5. Facon E, Scharz B, Ionesco S. Das Spontanhämatom des Hirnstamms. *Wien Klin Wochenschr*. 1962;74:655-658.
6. Kempe LG. Surgical treatment of an intramedullary haematoma simulating Wallenberg's syndrome. *J Neurol Neurosurg Psychiatry*. 1964;27:78-80.
7. Mastaglia FL, Edis B, Kakulas BA. Medullary hemorrhage: a report of two cases. *J Neurol Neurosurg Psychiatry*. 1969;32:221-225.
8. Obrador S, Dierssen G, Odoriz BJ. Surgical evacuation of a pontine medullary hematoma: case report. *J Neurosurg*. 1970;33:82-84.
9. Martin P, Noterman J. L'hématome bulboptubériantiel opérable. *Acta Neurol Belg*. 1971;71:261-268.
10. Plum F, Posner JB. *Diagnosis of Stupor and Coma*. 3rd ed. Philadelphia, Pa: FA Davis Co; 1980:29-30.

11. Cohen HCM, Tucher WS, Humphreys RP, Perrin RJ. Angiographically cryptic histologically verified cerebrovascular malformations. *Neurosurgery*. 1982;10:704-714.
12. Morel-Maroger A, Metzger J, Bories J, Gardeur D, Verger JB. Les hématomes bénins du tronc cérébral chez les hypertendus artériels. *Rev Neurol (Paris)*. 1982;138:437-445.
13. Hommel M, Borgel F, Gaio JM, Lavernhe G, Perret J. Latéropulsion ipsilatérale isolée par hématome bulbaire. *Rev Neurol (Paris)*. 1985;141:53-54.
14. Neumann PE, Mehler MF, Horoupian DS. Primary medullary hypertensive hemorrhage. *Neurology*. 1985;35:925-928.
15. Rousseaux M, Griffie G, Dhellemmes P, Dupard T, Caron J. Hématome bulbaire postéro-médian d'évolution favorable: étude de la dysautonomie. *Rev Neurol (Paris)*. 1988;144:481-488.
16. Biller J, Gentry LR, Adams HP, Morris DC. Spontaneous hemorrhage in the medulla oblongata: clinical MR correlations. *J Comput Assist Tomogr*. 1986;10:303-306.
17. Mazagri R, Shuaib A, Denath FM. Medullary hemorrhage causing vertigo and gaze nystagmus. *Ear Nose Throat J*. 1992;71:402-403.
18. Lee CC, Ryu SJ. Primary medullary hemorrhage: report of a case. *J Formos Med Assoc*. 1992;91:552-554.
19. Shuaib A. Benign brainstem hemorrhage. *Can J Neurol Sci*. 1991;18:356-357.
20. Zimmerman RS, Spetzler RF, Lee KS, Zabramski JM, Hargraves RW. Cavernous malformations of the brain stem. *J Neurosurg*. 1991;75:32-39.
21. Kase CS, Mohr JP, Caplan LR. Intracerebral hemorrhage. In: Barnett HJM, Mohr JP, Stein BM, Yatsu FM, eds. *Stroke: Pathophysiology, Diagnosis and Management*. New York, NY: Churchill-Livingstone Inc; 1992: 561-616.
22. Requena I, Arias M, Lopes-Ibor L, Pereiro I, Barba A, Alonso A, Monton E. Cavernomas of the central nervous system: clinical and neuroimaging manifestations in 47 patients. *J Neurol Neurosurg Psychiatry*. 1991;54:590-594.
23. Weber M, Vespignani H, Bracard S, Roland J, Picard L, Barroche G, Auque J, Lepoivre J. Les angiomes caverneux intracérébraux. *Rev Neurol*. 1989;145:429-436.