

Patterns of Recovery and Change in Verbal and
Nonverbal Functions in a Case of Crossed Aphasia:
Implications for Models of Functional Brain
Lateralization and Localization

LUIGI TROJANO, PIETRO BALBI, AND GIOVANNA RUSSO

*Clinica del Lavoro Foundation, IRCCS, Medical Center of Rehabilitation,
Campoli Monte Taburno, Italy*

AND

RAFFAELE ELEFANTE

Institute of Neuroradiology, School of Medicine, University of Naples Federico II, Italy

We present a 2-year verbal and nonverbal follow-up of a crossed aphasic patient. The patient had suffered from widespread ischemic damage in the area of right middle cerebral artery, with a parieto-temporal lesion. Three months post-onset he showed classical Wernicke's aphasia associated with oral, limb and constructional apraxia and left hemineglect. However, follow-up findings showed a complex, dynamic pattern entirely consistent with cognitive models of language and nonlanguage abilities. Current models of functional brain lateralizations could not satisfactorily account for such longitudinal, fine-grain observations. © 1994 Academic Press, Inc.

INTRODUCTION

Crossed aphasia is classically defined as an aphasic syndrome related to right hemisphere lesions in right-handed patients. It is an exceptional situation in which normal lateralization of language abilities is completely or partially reversed (Alexander, Fischette and Fischer, 1989). It has generally been claimed that this syndrome provides interesting observations about brain-behavior relationships.

One of the most discussed issues is whether crossed aphasia corre-

The authors are grateful to two anonymous referees for their helpful comments. Address reprint requests to Dr. Luigi Trojano, Fondazione Clinica del Lavoro, Centro Medico di Campoli del Monte Taburno, IRCCS, I-82030 Campoli M.T. (BN), Italy.

sponds to a characteristic language profile. Most studies adopt a cross-sectional methodology and describe patients observed at a particular stage of their history. Since the evolution of crossed aphasia is reported to be different from that of usual aphasic syndromes (Brown & Wilson, 1973), longitudinal studies might not support theoretical conclusions drawn from cross-sectional studies. On the other hand, appropriate timing of language examination is a related problem which was recently discussed by Ochipa and Gonzalez-Rothi (1989) and by Alexander, Fischette, and Fischer (1989), with divergent conclusions. Ochipa and Gonzalez-Rothi gave more emphasis to the evolution in the acute phase of recovery, whereas Alexander et al. underlined that the most suitable period is the post-acute stage (about 2–3 months postonset), when more certain anatomic–clinical correlations can be inferred.

Few follow-up studies on crossed aphasia have been reported. In particular, Basso, Capitani, Laiacona, and Zanobio (1985) systematically followed up verbal and nonverbal abilities in seven crossed aphasics, six of whom showed moderate to discrete improvement of verbal and nonverbal deficits. A further seven patients were reassessed about 1 year after onset (Alexander 1989, Case 1; Carr, 1981, Cases 2, 3; Coppens and Robey, 1992; Reinvang, 1987; Walker-Batson, 1988); linguistic abilities were partially recovered in five, while in the two remaining cases no relevant evolution was documented (Coppens and Robey, 1992, Case 2; Reinvang, 1987). For nonverbal deficits (limb, oral, or constructional apraxia, hemianattention), data are scarce: Alexander et al.'s patient and Coppens and Robey's Case 1 did not present such impairments, while in other patients such impairments are not sufficiently described.

This schematic review reveals the second main problem of crossed aphasia studies: the level of description (Alexander et al., 1989). Authors focus on different aspects of the syndrome and use different methodologies so that in many cases sufficient data are not available to compare patients. Bearing in mind these considerations, the aim of this study was to document systematically the verbal and nonverbal follow-up of a right-handed patient affected by crossed aphasia. We suggest that data from this patient and a critical review of the literature may shed new light upon models of lateralization of cognitive functions.

CASE REPORT

F.P. is a 55-year-old, male craftsman with 5 years of education. He is fully right-handed and scored 12/12 at the Edinburgh Handedness Inventory (Oldfield, 1971).

A few months after two transient ischemic attacks with completely recovered left hemiparesis and dysphasia, F.P. suddenly presented left hemiplegia and disordered speech in late December, 1989. Several days

later a CT scan showed a hypodense area in the right parietotemporo-occipital region with subcortical white matter involvement.

The patient first came to our observation in March, 1990. He was alert and cooperative, could walk unassisted, but showed left hemiparesis and speech disturbances. He underwent speech–language and neuropsychological evaluations and began discontinuous rehabilitative therapy. He underwent complete reevaluations 6, 15, 18, and 24 months after the stroke.

In July, 1990 and January, 1991 an MRI showed similar findings (Fig. 1): a widespread ischemic lesion in the territory of the middle cerebral artery, involving almost the whole temporal lobe and encroaching upon temporo-occipital gyri and the inferior parietal lobule. The supramarginal and the angular gyrus were only partially involved. The pole and mesial regions of the occipital lobe were spared, as were superior parietal areas. Other small hypointense areas were evident in the right capsulonuclear region. In particular, an oblong ischemic lesion involved the right globus pallidus and the posterior limb of the internal capsule.

Verbal Abilities

Clinical speech–language evaluations were performed using an Italian Standard battery (Basso, Capitani, and Vignolo, 1979). Results are summarized in Table 1.

At the first examination 3 months postonset, F.P. presented fluent speech with a monotonous, metallic voice. His communicative efficacy was very low because he produced a great number of neologisms and verbal paraphasias. He could repeat some words correctly but made many errors in repeating letters, syllables, nonwords, and longer sentences. He was able to read aloud only some letters and a few words. The patient made both literal paraphasias and errors due to left heminatention. Writing abilities were particularly impaired; literal paraphasias were abundant and his signature was altered.

Auditory and written comprehension were relatively spared only for single concrete words; F.P. had moderate difficulty in discriminating among semantically related words and marked difficulty in understanding simple commands.

Six months after onset, spontaneous speech was substantially unchanged, while language examination revealed appreciable improvement in repetition abilities: F.P. could repeat almost every stimulus correctly (except some nonwords). In reading aloud and writing to dictation only a limited recovery was seen, with reduction of phonological errors. Auditory and written comprehension were unchanged.

At the third examination 15 months after onset his speech had become more communicative with less stereotyped expressions, paraphasias, and

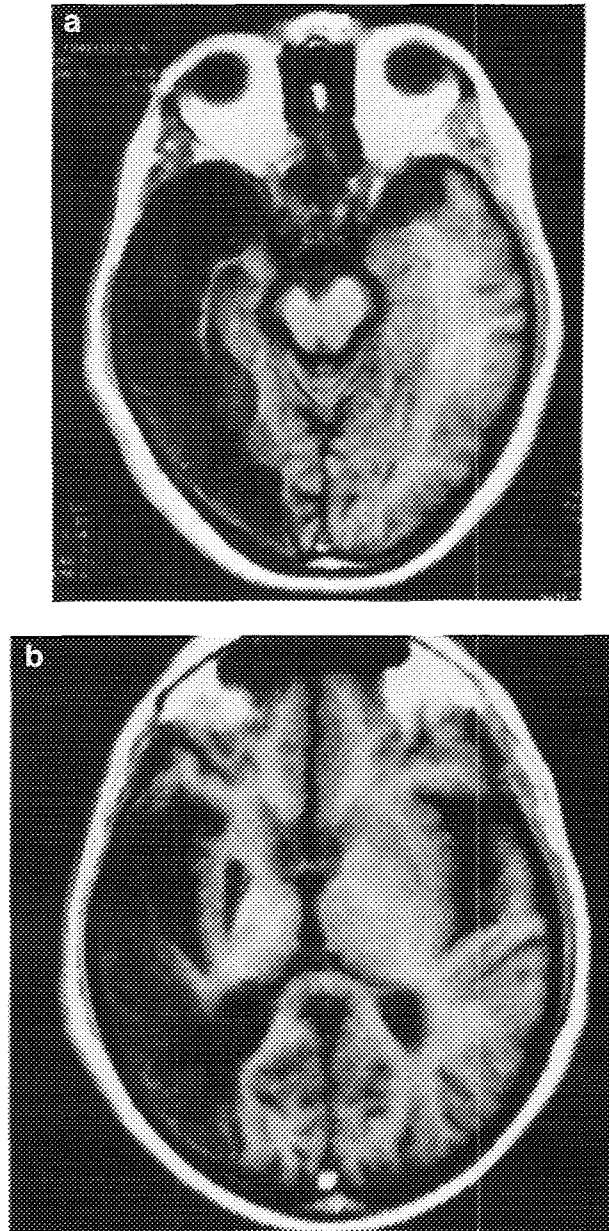


FIG. 1. (a-c) MRI scans showing the widespread ischemic lesion involving almost the whole temporal lobe and encroaching upon temporo-occipital gyri and the inferior parietal lobule. The supramarginal and the angular gyrus were only partially involved. An oblong ischemic lesion involving the right globus pallidus and the posterior limb of the internal capsule is evident in (b).

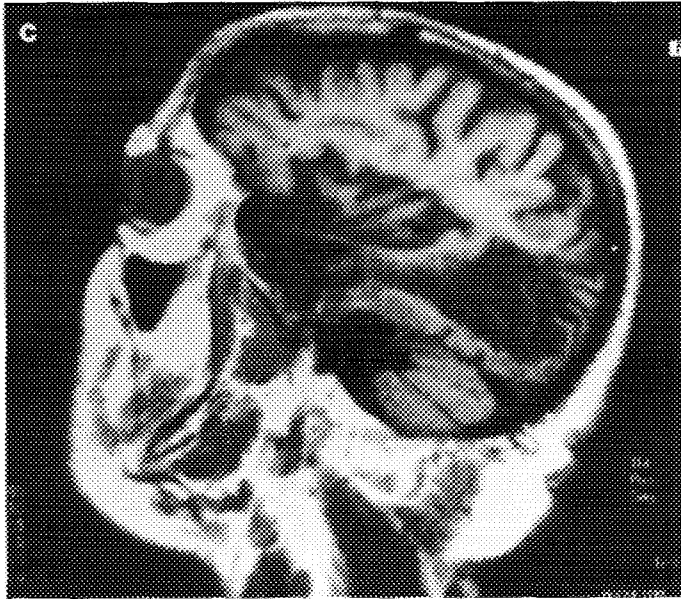


FIG. 1—*Continued*

anomias. Prosody was still monotonous. F.P. could repeat all stimuli flawlessly and read aloud with few errors (some errors due to heminattention persisted). In writing tasks errors were reduced although he made a relatively high number of literal substitutions, transpositions, and deletions. His signature was a phonologically implausible grapheme string. Auditory and written comprehension tests revealed persistent semantic and syntactic difficulties.

At this time he was given a supplementary battery of Italian language tests comprising phonological, semantic and syntactic tasks (B.A.D.A.; Miceli, Laudanna and Burani, 1990). Salient results are summarized in Table 2.

Phonemic discrimination and grapheme-phoneme matching. The patient correctly judged whether couples of auditorily presented CV stimuli were identical (93% correct) and flawlessly matched written and auditory CV syllables (98% correct).

Nonword transcoding tasks. The patient could transcode nonsense stimuli with a very low error rate. Repetition (83% correct) and reading (78% correct) were quite accurate, showing only a few phonological errors. Repetition errors were present only in longest, trisyllabic stimuli; reading errors were mainly localized in the initial parts of stimuli: Writing to dictation was less efficient (44% correct) because here F.P. inverted, deleted, and substituted a lot of graphemes. Stimulus length affected all

TABLE I
Summary of Serial Standard Language Examinations (Basso et al., 1979)^a

Token test	Months after stroke				
	3	6	15	18	24
	10/36	10/36	12/36	12/36	10/36
Spontaneous speech (see text)					
Oral naming	75	75	75	90	90
Automatic speech	+	+	+	+	+
Signature	-	-	-	+	+
Written naming	20	50	50	70	75
Oral comprehension					
Words	80	80	80	80	90
Sem. related words	35	35	35	75	70
Sentences	40	40	60	70	90
Repetition					
Letters	80	100	100	100	100
Syllables	80	100	100	100	100
Words	95	100	100	100	100
Nonwords	40	80	80	80	90
Sentences	60	60	70	80	90
Written comprehension					
Word	85	85	90	95	100
Sem. related word	45	45	65	85	85
Sentences	40	40	40	80	100
Reading aloud					
Letters	80	90	100	100	100
Syllables	30	50	90	100	100
Words	60	70	80	100	100
Nonwords	20	20	80	60	100
Sentences	40	40	80	40	100
Writing to dictation					
Letters	80	80	100	80	100
Syllables	60	70	90	90	100
Words	20	30	60	80	70
Nonwords	0	60	60	40	40
Sentence	0	0	0	70	70
Copy	20	20	60	100	100

^a All scores but Token test are given in percentages.

Note. (+) Correct; (-) altered.

three tasks but particularly writing; F.P. wrote correctly 7 out of 15 syllables, but no trisyllabic nonword.

Delayed nonword copy. F.P. correctly copied 4/4 nonsense syllables, but omitted the first part of two bi- and trisyllabic nonwords.

Auditory and written lexical decision. The task consisted in deciding whether auditorily or visually presented strings were meaningful. Word-

TABLE 2
Summary of Further Language Examinations (Miceli et al., 1990)

	Months after stroke		
	15	18	24
Phonological and nonlexical tasks			
Phonemic discrimination	56	NT	54/60
Grapheme-phoneme pairing	59	NT	60/60
Nonword repetition	30	NT	31/36
Nonword reading	35	NT	40/45
Nonwords writing to dictation	11	NT	22/25
Nonword delayed copy	4	NT	5/6
Lexical-semantic tasks			
Auditory lexical decision	45	42	38/80
Visual lexical decision	43	46	52/80
Auditory word comprehension	37	38	36/40
Visual word comprehension	27	27	39/40
Oral naming	34	NT	35/58
Written naming	13	NT	22/44
Naming to definition	4	NT	4/16
Word repetition	45	NT	45/45
Word reading	73	NT	92/92
Word writing to dictation	23	NT	32/46
Word delayed copy	1	NT	6/10
Grammatical-syntactical tasks			
Auditory grammaticality judgments	20	22	24/48
Visual grammaticality judgments	10	13	8/24
Auditory sentence comprehension	28	31	33/60
Visual sentence comprehension	18	19	26/45
Sentence repetition	18	NT	20/20
Sentence reading	1	NT	6/6
Auditory word span	2	NT	4
Auditory nonword span	2	NT	3

Note. NT, not tested.

stimuli were balanced for length and grammatical class; nonwords were obtained by changing one letter of meaningful stimuli. F.P. scored at chance level for both auditory and visual modality.

Single-word auditory and written comprehension. The patient had to point out the figure corresponding to the target stimulus on a two-choice display. Half the distractor items were phonologically similar to the stimulus and half were semantically similar. Auditory modality (87.5% correct) was better preserved than visual (67.5% correct). Errors were equally distributed among semantic and phonological distractors in both modalities.

Oral and written confrontation naming. The patient could correctly name 60% of objects, making three semantic approximations and some

visual confusions, but no phonemic paraphasia. Words were balanced for frequency and length, but neither factor affected accuracy. In written object naming, with another set of words balanced for frequency and length, accuracy was lower (32%) because of frequent literal substitutions, inversions or omissions. Written naming was significantly affected only by stimulus length: F.P. was able to write correctly 7/14 short words, but no long word (of 8 items; $\chi^2 = 3.4$, $df 1$, $p = .06$). Action naming was similar to word naming for both the auditory and the visual modality.

Oral naming to definition. The patient had to give concrete names in response to auditory definitions. He was correct in only 4 out of 16 items, giving in most cases responses not, or poorly, related to the target.

Word transcoding tasks. F.P. could correctly repeat all words. He made few errors in word reading (80% correct); most of them consisted of single or multiple literal substitutions, but a high percentage of them (16/19; 83%) regarded the first half of stimuli, often producing "backward completion" (words derived from literal substitutions or omissions in the first part of targets). Even when the patient produced nonsense responses, literal substitutions occurred in the first part of stimuli. Writing words under dictation was less accurate (50%); in this task, many grapheme substitutions were observed, but errors were equally distributed in the first (24/46; 51%) and in the second (49%) half of stimuli. It is worth mentioning that reading and writing lists were balanced for length, frequency, concreteness, and grammatical class: only stimulus length effect approached significance ($\chi^2 = 3.4$, $df 1$, $p = .06$) in word writing.

Delayed word copy. Only 1 stimulus out of 10 was reproduced correctly; in all cases, errors consisted in omissions or substitutions in the first part of stimuli.

Grammaticality judgments. The patient was asked to judge whether auditorily or visually presented sentences were well constructed or contained morphological or syntactic errors. F.P. achieved scores similar to chance level for both auditory and visual modality.

Sentence comprehension tasks. The patient was given semantically reversible sentences, 60 orally and 45 written and was asked to point out the picture corresponding to the sentence-stimulus in a two-choice display. Half the stimuli were in active form and half in passive form. In one third of stimuli the distractor item and the target differed in one morphological element, in one third they differed in one semantic element; in the remaining cases, the distractor contained an inversion of thematic roles with respect to the target. The patient scored at about chance level for both modalities tested.

Sentence transcoding tasks. F.P. repeated correctly most sentences (90%). He could read aloud only one sentence out of six, showing a clear position effect due to errors for left-most stimuli.

Auditory word span. The patient could correctly reproduce 70% of two-word series, but no three-word series.

Auditory nonword span. F.P. succeeded in reproducing only 30% of two-stimulus series.

At the subsequent examination, 18 months postonset, F.P.'s speech was more communicative, but his tone was still flat. Reading aloud was correct; both spontaneous writing and writing to dictation had improved, even though they still presented some literal substitutions, omissions, and inversions, with all kinds of stimuli. The patient could correctly sign his name. Auditory and written comprehension had also improved but only for single words and simple commands, while performance with complex sentences was unchanged.

In this occasion F.P. was given only the supplementary language tests that had revealed more severe deficits at the previous examination. He did not show any improvement in auditory or written lexical decision, single-word auditory or written comprehension, grammaticality judgment task, or sentence comprehension tasks.

At the last examination, 24 months postonset (December 1991), spontaneous speech had further improved, because anomias and paraphasias were rare. F.P. spoke quite fluently, at about 70 words per minute and with an average sentence length of 12.2 words. He used a relatively high percentage of open class words (55%) and a corresponding low percentage of closed class items. However, his percentage of omission of obligatory bound and free-standing grammatical morphemes was very low: in a sample of 124 words, F.P. omitted only three free-standing morphemes, two of which are not strictly obligatory in Italian.

Prosody was still flat.

F.P. completed repetition and reading tasks flawlessly and made few errors in standard writing tasks.

Auditory and written comprehension of single words had further improved, but no change was detected in coping with complex commands.

On this occasion, the patient was also given the complete supplementary language evaluation battery (Miceli et al., 1990).

Phonemic discrimination and grapheme-phoneme matching. Performance was similar to the previous one.

Nonword transcoding tasks. Repetition (86% correct), reading (89%), and writing to dictation (88%) were equally accurate. Reading errors were still distributed in the first part of stimuli.

Auditory and written lexical decision. Overall results were similar to the previous ones: 47.5% correct for auditory modality and 65% for visual modality, but F.P.'s response pattern had changed. In the auditory modality he correctly rejected a majority of nonwords (28/40) and showed a significant grammatical class effect for words: hit rate for nouns was the highest (7/10) and for function words the lowest (0/10), with intermediate

values for adjectives and verb forms ($\chi^2 = 10.1$, $df 3$, $p = .01$). Word frequency did not affect overall results probably because of a floor effect. However, it must be noted that F.P. missed no medium-frequency noun out of 5 but missed 3/5 low-frequency nouns. A similar pattern was observed for visual modality (correct rejection rate 36/40; hit rate for nouns: 6/10; hit rate for function words: 0/10), and also in this case grammatical class effect was significant ($\chi^2 = 10$, $df 3$, $p = .01$). Frequency did not significantly affect overall results, but there was a tendency toward a better performance with medium-frequency nouns (4/5 correct) than with low-frequency ones (2/5 correct).

Single-word auditory and written comprehension. The patient's performance had improved, particularly in visual modality, in which he tended to make only semantic confusions.

Oral and written confrontation naming. Oral naming showed little improvement. In written naming the number of graphemic errors was reduced, although there was still a tendency to produce short words more correctly. In both modalities similar scores were obtained for concrete nouns and actions. At this task, which involves black and white line drawings, F.P. produced a substantial number of verbal paraphasias that can be accounted for by visual confusion, both in oral (65% of errors) and in written naming (40% of errors). Oral and written naming was far better at standard aphasia evaluation battery which uses coloured pictures.

Naming to definition. This naming task remained the most difficult one: results were similar to those of the previous examination.

Word transcoding tasks. F.P. could repeat and read aloud all words without errors. Writing to dictation improved to 70% correct with a reduction of literal substitutions and inversions. Delayed copy also showed some improvement (60% correct).

Grammaticality judgment task. Scores were not different from chance level.

Sentence comprehension tasks. In these tasks, overall results were similar to the previous ones, but response pattern varied. Considering together auditory and visual modalities and active and passive forms (in which F.P.'s performances were similar), hit score was higher when there was a semantic distractor (25/35) than when the critical factor was a morphological variation (18/35) or the inversion of thematic roles (16/35). The effect of distractor type was significant ($\chi^2 = 6.2$, $df 2$, $p = .04$). This finding confirmed that the patient had improved in managing semantic elements, while he remained unable to process morphological and syntactic elements in order to comprehend a complex sentence. To verify this observation, the patient was given a sentence-matching task not included in the battery. Ten semantically nonreversible active sentences, of lengths matched to previous stimuli, were auditorily or visually presented

to the patient, who had to point to the corresponding picture on a two-choice display. F.P. scored 9/10 and 8/10.

Sentence transcoding tasks. F.P. repeated and read aloud all stimuli correctly (but here an attentional cue was used at the beginning of sentences).

Auditory word span. The patient reproduced correctly 3/5 four-word series and only 2 to 4 final items of six-word series. On a separate occasion, we gave F.P. another word span task according to Spinnler and Tognoni's (1987) standard instructions to compare his word span with that of a large, matched sample of normal controls. He scored 4, i.e., within normal range.

Auditory nonword span. F.P. reproduced consistently two-stimulus series and 30% of three-stimulus series.

Nonverbal Abilities

Heminattention. The tendency to neglect left-sided stimuli was investigated through the segment cancellation task (Albert, 1973). The patient was also tested with different materials on some occasions (letter cancellation task, sentence reading; Pizzamiglio, Judica, Razzano, and Zoccolotti, 1989). Finally, 15 and 24 months postonset the patient was given a reading task comprising 20 four- to nine-letter words arranged vertically. As in verbal tasks, F.P. showed throughout the follow-up a clear left neglect (Table 3). The last two examinations showed a partial recovery in barrage and in sentence reading (at the last examination he could compensate for his deficit when attentional cues were used; see sentence transcoding tasks in the previous section). F.P. did not show any improvement in a complex visual-search task (letter cancellation). It is important to note that in the vertical reading task F.P.'s performance greatly improved at the last evaluation.

Other tasks aimed to assess heminattention at representational level (for example: o'clock test; Grossi, Modafferi, Pelosi, & Trojano, 1989) were not given because of comprehension deficits.

Praxis. Ideomotor praxis was assessed by asking the patient to imitate gestures made by the examiner. The same 24-item test, made up in equal proportions of finger movements and whole arm movements, half meaningful and half meaningless, was given on each occasion (De Renzi, Motti, & Nichelli, 1980). Results at this test were congruent with those achieved at a standard, reduced 10-item test (Spinnler and Tognoni, 1987) reported in Table 3. Oral praxis was assessed by asking the patient to imitate 10 single mouth, lip, or tongue movements (Spinnler and Tognoni, 1987). Trunk praxis was not assessed systematically.

At the first examination, marked oral and ideomotor apraxias were present (Table 3). F.P. progressively recovered and 6 months postonset

TABLE 3
Summary of Serial Neuropsychological Assessments

	Months after stroke				
	3	6	15	18	24
Apraxia ^a					
Oral	12	20	20	20	20/20
Ideomotor	0	10	12	20	20/20
Constructional	0	5	5	5	5/14
Attention ^b					
Barrage	11	10	11	10	8/11
Letter cancellation	NT	NT	52	52	52/52
Sentence reading	NT	NT	6	6	3/6
Vertical word reading ^c	NT	NT	7	NT	1/20
Raven's PCM	NT	12	NT	NT	16

Note. NT, not tested.

^a Tests given according to instructions of a standard battery (Spinnler and Tognoni, 1987). Raw scores are reported. Oral apraxia score was in normal range 6 months after the stroke; ideomotor apraxia 18 months after the stroke; constructional apraxia never.

^b Tasks for neglect given according to standard instructions (Pizzamiglio et al., 1989). Number of errors in left hemifield are reported; all scores were over the cut-off points for normal subjects.

^c Only neglect-related errors, considered as errors in the first half of stimuli, are reported. Fifteen months postonset the patient made also two visual errors in the second part of stimuli; 24 months postonset only 1.

the oral praxis score was in normal range, while limb apraxia had recovered completely by 18 months postonset.

Constructional apraxia, as demonstrated by the copy of geometrical drawings (Spinnler and Tognoni, 1987), was present and almost unchanged throughout examinations (Table 3). On the last occasion F.P. was also given a simplified version of a battery to evaluate perceptual and representational spatial abilities (TERADIC, Grossi & Angelini, 1992), in order to obtain more information about the constructional deficit. All the tasks were modified to minimize the bias due to his attentional deficit (two choices given, one above the other), and the number of trials was reduced. Different deficits of spatial thought emerged, because F.P. had moderate difficulties in discriminating line orientation and angle size, in mentally assembling simple figures, and in analyzing complex geometrical pictures.

Affect and emotion. The patient exhibited a depressed mood throughout the observation period. F.P. often expressed feelings of hopelessness and showed a high level of distress/concern, even though we did not use specific rating scales because of his comprehension difficulties. Emotional prosody was monotonous and inappropriate to the dramatic content. We did not test singing abilities nor comprehension of emotionally laden expressions.

DISCUSSION

Analysis of Verbal and Nonverbal Follow-up Findings

Longitudinal study demonstrated that this patient's verbal and nonverbal abilities did not recover at a uniform rate. At the first examination F.P. was affected by a fluent aphasia with impaired spontaneous speech and comprehension skills. This picture is quite typical of moderate to severe sensory aphasia, with relative sparing of word repetition. Six months after the stroke, expressive and comprehension abilities had not changed, but repetition of nonsense stimuli had improved. Reading aloud also showed some early improvement, but writing remained the most impaired ability with a high number of literal substitutions, inversions, and omissions for all types of stimuli. At this stage, sensory transcortical aphasia could be considered the most appropriate label for these deficits.

Follow-up subsequently revealed a further recovery of phonological competence, particularly in transcoding tasks, while auditory and written comprehension recovered only for single words, and comprehension of complex sentences was unchanged. In these last examinations, the aphasiological picture was quite unexpected in crossed aphasia (see below). F.P. showed a disproportionately severe deficit of comprehension abilities with respect to other verbal skills: he could produce relatively short, well-constructed sentences with few paraphasias or anomias.

His verbal behavior was not easily classifiable at the third examination, making a supplementary language evaluation necessary for a more systematic assessment of linguistic systems and subsystems. We used thus a battery devised to investigate language processes in terms of cognitive models (Miceli et al., 1990). Through these tasks, we could document that 15 months postonset F.P. was able to perform flawlessly phonological and non-lexical operations, while he made many errors in writing tasks. Moreover, he had moderate difficulty with auditory and visual single-word lexical decision and comprehension, and with tasks involving multi-word syntactical processes.

Interpreting these deficits in terms of a cognitive model of single-word lexical processing, such as that adopted by Howard and Franklin (1987), one could not isolate a single linguistic subcomponent impaired. One would have to prospect multiple deficits at auditory and visual input lexicon, and more specific deficits of graphemic output, with a relatively preserved oral output. In particular, F.P.'s writing presented errors (letter deletions, insertions, transpositions, and substitutions) resulting in phonologically implausible responses; it was not influenced by stimulus familiarity or by lexical factors, but it was affected by stimulus length. Furthermore, the patient had the same difficulties in spontaneous writing, in taking dictation, and in delayed copy (although few data were available for this last task). Consequently, the picture closely resembled that ex-

pected in specific impairments of graphemic output buffer (Caramazza, Miceli, Villa, and Romani, 1987). These impairments at single word processing were associated with an inability to carry out grammatical-syntactic operations (but reduced verbal short-term memory could also contribute to failure at these tasks).

Long-term follow-up at 18 and 24 months after stroke showed a clear general recovery of linguistic processes except grammatical-syntactic competence. At 18 months postonset F.P. could repeat, read, and (less accurately) write to dictation with a relatively low error rate. At 24 months postonset he had completely recovered phonological competence explored by nonlexical tasks. Writing errors had also diminished. At single-word processing, the only task in which F.P. continued to show clear deficits was auditory and written lexical decision, even though on this occasion he showed a response pattern related to stimulus features: he had recovered the access to lexical representations for concrete nouns. This fact was also confirmed by the better result in sentence comprehension when the task could be solved through the activation of semantic elements. Similarly, his performance was good when the task could be solved on lexical grounds alone, i.e., with nonreversible sentences. F.P. showed quite stable deficits, instead, in sentence comprehension (while he could repeat and read sentences flawlessly), and in grammaticality judgments. He failed to a similar extent with active and passive forms and could not differentiate between morphologically similar alternatives and between sentences with inversion of thematic roles. Therefore, his performance in sentence understanding was quite similar to the so-called asyntactic comprehension reported in Broca's aphasia and conduction aphasia (Caramazza and Zurif, 1976; Caramazza, Basili, Koller and Berndt, 1981). Nonetheless, at this stage F.P. could repeat flawlessly every stimulus and showed no articulatory disturbances or agrammatic production, so that he could not be classified in either classical syndrome.

The dissociation between impaired syntactic comprehension and spared speech production merits several comments. Similar findings were reported by Caramazza et al. (1981) in a conduction aphasic with a selective verbal short-term memory defect. The authors proposed two alternative explanations of the syntactic deficit: one was based on their patient's decoding deficit at lexical level (impaired processing of function words), and the other took into account the short-term memory defect. The authors did not completely reject the former hypothesis (even though it could not explain the impaired comprehension of visually presented sentences), but they did not find sufficient evidence of specific lexical decoding deficits in their patient. They concluded from this that the patient's memory defect could entirely account for the comprehension impairment, adopting a theoretical model according to which working memory has a definite role in comprehension. Similar findings of co-occurrent deficits

of short-term memory and comprehension abilities have been reported in other patients (see McCarthy and Warrington, 1987, for a discussion), particularly in another crossed aphasic (Berndt, Mitchum and Price, 1991). However, in our case asyntactic comprehension was documented when verbal short-term memory had returned in normal range. Consequently, we are faced with a selective deficit in comprehending sentences whose interpretation is not semantically constrained. This deficit was evident both for auditory and visual modalities, but was not associated with analogous production defects. Thus an impairment of "central" syntactic competence, as for example of the syntactic parser (Caramazza and Zurif, 1976) does not seem reasonable. Our patient's deficit seems more strictly related to input analysis and therefore could be thought to be a decoding deficit (Caramazza et al., 1981). F.P. showed a moderate deficit in auditory and visual input lexicon (see lexical decision tasks), being quite successful only with concrete nouns (and tendentially with high-frequency items). He had marked difficulty in recognizing verbal forms or function words as real words, despite his intact repetition and reading skills. Such difficulties at lexical level could reasonably provoke deficits in more complex syntactic tasks. In particular, the chance level performance revealed in grammaticality judgments suggests a complete inability to analyze free-standing or bound morphemes which, on the other hand, he could successfully process at production stages. Could his parallel performance in auditory and visual modalities be more parsimoniously explained by a common deficit? Could he, for example, be more impaired in processing grammatical morphemes, which can be represented in the lexicon only in terms of syntactical description (as Caramazza et al., 1981, suggest)? We have no means to substantiate this claim, and we can only conclude that, 24 months postonset, F.P. had recovered some linguistic abilities (e.g., the specific defect at graphemic output buffer), but continued to show an impaired access to both auditory and visual lexical-semantic knowledge and a (probably related) defect of syntactic-grammatical competence.

Nonverbal recovery was not uniform, either. At the first examination, F.P. presented heminattention and oral, limb, and constructional apraxia. He had completely recovered oral praxis 6 months after the stroke and limb praxis at 15 months. Heminattention recovered partially, but was still evident at the last examination, while constructional praxis showed no improvement at all. It is worth mentioning that 15 months postonset, most of F.P.'s reading errors were consistent with findings in other patients with unilateral spatial neglect (Kinsbourne and Warrington, 1962), and that he showed neglect errors in delayed copy of words and nonwords but not in other writing tasks (unlike the patient described by Hillis and Caramazza, 1989). These findings would suggest that F.P.'s writing was affected at that stage by attentional bias only when he had to read from an

“inner screen” (as Baxter and Warrington, 1983, suggested for spelling performance). Twenty-four months postonset, this finding had disappeared. It could be argued that F.P. recovered full exploration of his internal “screen,” as his neglect disorder improved. This hypothesis is supported by the parallel, marked reduction of neglect errors in vertical reading. However, a strategy shift in delayed copy could not be excluded: The patient could have relied more heavily on a letter-by-letter phonological representation of the stimulus, since he also recovered orthographic-phonological conversion processes (according to Howard and Franklin’s definitions, 1987). Even with this caveat, F.P.’s behavior could be relevant to the issue of relationships between attentional and output graphemic processes, suggesting not that there is a uniform impairment in unilateral spatial neglect, but that dissociable attentional mechanisms can be selectively impaired after brain lesions (Caramazza and Hillis, 1990; Hillis and Caramazza, 1991). However, in another framework (Behrmann, Moscovitch, Black, & Mozer, 1991) it could also be assumed that the reduction of F.P.’s “peripheral” neglect disorder allowed sufficient performance in reading and writing at the last examination. No specific test of these different hypotheses was performed, nor is it possible to further discuss this issue here. More relevant to our aim is that, on closer scrutiny, F.P.’s cognitive profile remained consistent with current theoretical models independently of anomalous lateralization, and that a longitudinal study can document differential recovery of attentional mechanisms.

A last remark about constructional apraxia. Throughout follow-up the patient showed a stable inability to copy complex drawings, although he could complete simple figures such as squares and circles. These findings could suggest a defect in the elaboration of complex visuo-spatial information, an interpretation supported by data from supplemental visuo-perceptual and representational TERADIC tasks.

Issues on Characterization of Crossed Aphasia

Crossed aphasia is an exceptional finding related to anomalous lateralization of language abilities. Early studies tried to characterize this syndrome on the basis of an explanation of anomalous lateralization. Many authors (Brown & Wilson, 1973; Brown & Hécaen, 1976; Urbain, Seron, Remits, Cobben, Van der Linden, & Mouchette, 1978) claimed that the peculiar profile of crossed aphasia, regardless of the locus of lesion, consisted in low speech fluency, agrammatic production, phonemic paraphasias, and good outcome. The concept that typical pictures of crossed aphasia could be isolated gave rise to the proposal of strict diagnostic criteria. For example Habib, Joannette, Ali-Cherif, and Poncet (1983) suggested selecting such patients only if there were no left-handedness in the patient’s family, nor any other factor related to a different brain func-

tional organization (illiteracy, bilingualism, etc.). In subsequent years, these criteria were not always followed even in authoritative studies (Alexander et al., 1989), also because the claim of typical form had lost its appeal. Basso et al. (1985) demonstrated that in most cases clinico-anatomical correlations reflected what is found in left-sided lesions, or in other words that brain functional organization of the right hemisphere would be the mirror image of normal left organization. Basso et al. claimed that the only distinctive features in crossed aphasia were the relatively higher score in complex sentence comprehension tasks (Token test) and the relatively frequent dissociation between better speech and more impaired written production. Aphasic features could be predicted in nearly all cases on the basis of intrahemispheric lesion locus. The recent paper by Alexander et al. (1989) supported this view and led to the formal distinction between "mirror" and "anomalous" crossed aphasic syndromes. However, these authors noted that the term anomalous, otherwise vague, should be used only in reference to the intrahemispheric lesion locus (i.e., for fluent aphasia in patients with anterior lesion, 12 patients out of the 34 included in their review), and that in reference to aphasia classification the "anomalies" depended heavily upon the kind of classifying system (see also Crary, Wertz, & Deal, 1992). For example, when Hadar, Ticehurst, and Wade (1991) suggested that a number of crossed aphasia patients showed "specific" linguistic deficits while others did not, they referred, although not explicitly, to classical aphasia classification criteria. They claimed that in these "specific" cases, aphasia disturbances were not different from those expected in analogous left cerebral lesions, and consequently in these cases right lateralization mirrored the normal left one. On the other hand, Hadar et al. suggested that nonspecific cases of crossed aphasia could result from an anomalous, diffused right cerebral representation of language and are characterized by agrammatic production, reduced fluency, and good outcome (Brown and Hécaen's typical crossed aphasia) together with other nonverbal defects. In its strong form the hypothesis of Hadar et al. is falsified by findings in patients like F.P. (but also Basso et al., 1985, Cases 3 and 5; Faglia and Vignolo, 1990; Coppens and Robey, 1992, Case 2), with long-lasting specific aphasic defects associated with persistent neuropsychological deficits generally attributed to the right hemisphere.

Adopting the position of Alexander et al., F.P. can be considered to show "mirror" crossed aphasia, because he suffered from a predominantly posterior damage and presented fluent aphasia. In agreement with studies on normal aphasics, our patient's aphasiological picture at 3-6 months postonset was quite congruent with his intrahemispheric lesion site: lesions of the superior and middle temporal gyri have been reported in patients affected by Wernicke's aphasia with moderate to severe comprehension impairment (Naeser, Helm-Estabrooks, Haas et al., 1987),

and the extension of the lesion over temporo-occipital areas has been related with chronic transcortical sensory aphasia resulting from the evolution of Wernicke's aphasia (Rubens and Kertesz, 1983, p. 264).

F.P.'s aphasic features at later stages could not be easily classified within classical syndromes and was characterized by a major defect in comprehension in sharp contrast with the good repetition and reading. However, it is important to note that one specific feature of crossed aphasia according to Basso et al. (1985) was never shown by F.P., because his performance at the Token test (sentence comprehension) was consistently low. The second peculiar feature of crossed aphasia, the dissociation between oral and written output, was present at some stages but had disappeared by the last examinations, in which F.P. no longer produced graphemic substitutions, omissions, or inversions.

Up to this point, at the level of clinical description, our "mirror" case does present some unusual features respect with other crossed aphasic patients. However, we believe that, especially in crossed aphasia studies, a further assessment of language abilities can be exploited as suggested by Alexander et al. (1989). In recent years, some detailed cognitive and computational models of higher mental functions and language abilities have been developed. Their purpose is to isolate functional brain systems and subsystems involved in cognitive functions and to explain patients' behavior, in the event that some subsystems have been damaged. Two recent crossed aphasia case reports have tried to define the patients' functional damage in terms of cognitive models (Hadar et al., 1991; Berndt et al., 1991). In the former case, the authors succeeded in designating a specific impairment in speech processes, precisely in the access to an intact output lexicon (Hadar et al., 1991). In the latter case, the patient proved to be affected by a very specific verbal short-term memory impairment with an associated comprehension disorder (Berndt et al., 1991). However, in this case, the pattern of cognitive deficits was not what authors expected: they reported a dissociation between the perception of auditory/phonetic information and its storage, and a peculiar comprehension deficit in spite of normal sensitivity to syntactic structures. While the first finding could fit into coherent theoretical frameworks (Trojano, Stanzione, & Grossi, 1992), the second suggests a real cognitive anomaly that has to be explained by a different brain functional organization, or, from another angle, that needs the implementation of current cognitive models. This fact represents the unique contribution that crossed aphasia studies and, more generally, studies on anomalous lateralization of brain functions (Fischer, Alexander, Gabriel, Gould and Milione, 1991), can add to the current knowledge of brain functional organization.

From this point of view, we have tried to explain F.P.'s verbal and nonverbal performance within information processing models. For lin-

guistic abilities we have referred to a generally accepted model of single-word processing (Howard and Franklin, 1987). In our patient findings easily fit the model: for example, 15 months postonset, we saw a specific deficit of written output that could be interpreted as a consequence of selective impairment of graphemic output buffer. This finding is intriguing in that specific writing difficulties, particularly at a phonologic level, are frequently reported in crossed aphasics, although we have no means to establish whether they could be ascribed to a similar deficit. This deficit recovered in the late stage, when the main defect was that of access to lexical-semantic knowledge, which was parallel for auditory and visual modalities, and suggests damage to a single multi-modal component. In any case, this finding too was entirely consistent with current theoretical models, so that the uncommon picture found in our patient and in the patient described by Hadar et al. (1991) cannot be considered anomalous from a cognitive point of view. The only peculiarity is that the normally represented linguistic subsystems are redistributed with unusual lateralization between the two hemispheres.

Issues of Lateralization of Cognitive Functions

As mentioned above, a new approach to the description of crossed aphasia has recently been proposed, interpreting clinical findings in terms of cognitive models. In this case report we have also tried to follow this perspective, and we found some specific linguistic deficits entirely consistent with current theoretical models. The problem, then, becomes to attribute language subsystems and competence to one hemisphere or the other.

F.P. showed a relevant recovery during the first year postonset, but some linguistic abilities continued to improve until 2 years postonset. This pattern is consistent with the hypothesis that linguistic disturbances in crossed aphasia are not transitory and that recovery may also be slower than that reported in traditional studies on normal aphasics (e.g., Kertesz & McCabe, 1977).

In general terms, the recovery of functions in aphasic patients could be attributed to contralateral cerebral areas homologous to those lesioned or to ipsilateral areas, more likely those surrounding the lesion (Kertesz, Lau and Polk, 1993). It has been suggested that the contribution of either hemisphere is modulated by several subject- and lesion-related variables (Cappa and Vallar, 1992). Therefore, it is very difficult to infer which cortical area allows recovery in single patients, mainly when premorbid language lateralization may vary greatly, as in crossed aphasia (Coppens and Robey, 1992). However, recent studies (Kertesz et al., 1993) allow us to suggest that F.P.'s long-term recovery in comprehension is not

unexpected, given the relative sparing of supramarginal and angular gyri. The role of subcortical structures in recovery remains to be explored.

As for other language abilities, the relatively quick improvement of phonological competence might suggest a role of the contralateral (left) areas. Similarly, there is some evidence that in the case of left lesions in some normal right-handed patients, the contralateral (right) hemisphere can support some linguistic activities and particularly phonological competence (Grossi, Trojano, Chiacchio et al., 1991). However, on closer scrutiny, a number of phonological processes (for example, auditory-phonological conversion, grapheme-phoneme conversion, phonological output buffer) may have been gradually subsumed by other cerebral areas and it remains unclear whether this recovery could be based upon left hemisphere's phonological competence. This possibility could be verified by means of direct (Wada test) or indirect measurement of either hemisphere's contribution to language performance (Demeurisse, Hublet, Coekaerts et al., 1986; Perani, Papagno, Cappa et al., 1988). We did not perform such tests, but can reasonably claim that, on the other hand, our patient's graphemic output buffer and (access to) lexical-semantic knowledge, i.e., the two functions most stably impaired, were completely lateralized into the right hemisphere before the stroke and there was no left area that could promptly compensate for them.

The same difficulties would be encountered in trying to interpret anomalous lateralization of other cognitive subsystems. Actually, in the study of crossed aphasia, some attention—very little—has been paid to nonverbal functions generally ascribed to the right hemisphere. Basso et al. (1985) claimed that various nonverbal deficits may be associated with linguistic disturbances, thus confirming Henderson's hypothesis (1983) that language representation in the right hemisphere does not usually affect right hemisphere representation of attention and visuo-perceptual functions. Castro-Caldas, Confraria and Poppe (1987) claimed that only attentional and visuo-perceptual functions are completely independent of language abilities and remain localized in the right hemisphere. Moreover, these authors proposed that limb apraxia is rare in crossed aphasia because it is more strictly related to handedness, while oral apraxia is as frequent in crossed aphasics as in normal right-handers because it clusters with language abilities. Our follow-up findings did not strictly support this hypothesis, because oral apraxia recovered earlier than limb apraxia. But even in this respect, our data point out that a cross-sectional study can reveal only part of the picture, while longitudinal studies provide evidence of dynamic interactions of the two hemispheres in motor control.

When we adopted the same cognitive approach for nonverbal abilities as for linguistic skills, the picture became even more complicated. Findings were entirely consistent with cognitive models according to which

heminattention is not a unitary phenomenon (see also Halligan and Marshall, 1992). Even if we could not fully assess representational aspects of neglect, we were able to show that perceptual heminattention persisted after the patient had recovered the ability to process whole internal representations of words. We cannot yet explain even tentatively these findings in terms of functional lateralization.

Visuoconstructional abilities have traditionally been ascribed to right-hemisphere functioning, but visuoconstructional apraxia is not a unitary phenomenon either. Moreover, clinical and experimental evidence has failed to support specific accounts of this cognitive impairment in terms of right/left distinction (see Gainotti, 1985 for a discussion). Through more extensive testing we showed that F.P. was stably impaired in copying complex pictures, and that visuoperceptual and representational impairments could account for his distorted reproductions. This deficit could thus be seen as evidence of a visuoperceptual impairment which the left hemisphere could not compensate for. However, recent studies have shown that even this finding is not easily accounted for by right/left dichotomy (Mehta and Newcombe, 1991).

A final remark regards affect and emotion. F.P. showed a depressive reaction quite common in aphasics with left lesions, while his flat affective prosody could be expected in right hemisphere lesions. In this field theoretical hypotheses are somewhat less specific than those proposed for other cognitive functions. However, these findings are consistent with Ross and Rush's (1981) observations in right-damaged patients, suggesting that these patients may experience depression but be unable to express it. On the other hand, F.P.'s lesion did not involve the right frontal lobe whose lesion has been retained to cause indifference and inappropriate cheerfulness (Robinson and Price, 1982; but see Gainotti, 1989, for a thorough discussion). Moreover, it has been proposed (Cancelliere and Kertesz, 1990) that disorders of emotional expression and comprehension are quite consistently linked with basal ganglia lesions, like those found in F.P. Our patient's affect and emotional behavior could be consistent with the right intrahemispheric lesion site, thus suggesting that lateralization of affect/emotional processes was not influenced by reversed lateralization of language in his brain.

CONCLUSIONS

This case study allows some general considerations about clinical and theoretical aspects of crossed aphasia. Such patients may present a pattern of impairments and a clinical evolution greatly relevant to two areas: the implementation of cognitive models, for cases in which findings do not follow theoretical predictions, and our understanding of functional brain lateralization.

Our patient presented a complex picture of verbal and nonverbal deficits, and follow-up data helped to establish a more detailed picture of right localization of functions and of the interactions of the two hemispheres in compensating for cognitive impairments. This longitudinal study adopted an information processing methodology which shed new light upon problems related to anomalous lateralization of cognitive functions.

The analysis of verbal and nonverbal skills showed that our patient's cognitive profile was entirely consistent with current theoretical models. These findings, together with a critical review of the literature, suggested that there is no peculiar picture of verbal or nonverbal abilities in crossed aphasias, and that such patients may present variable cognitive profiles largely depending on single patient's functional lateralization of cognitive subsystems.

The recent hypothesis of two fundamental types of crossed aphasia (mirror and anomalous) could partially account for some linguistic performances during the first months of observation and for their relationship with the intrahemispheric lesion site. Findings in the affect/emotional domain were also consistent with some recent neuroanatomical hypotheses, but we could not find a comprehensive theoretical framework which could explain the co-occurrence of impairments in different language abilities and in nonverbal cognition. In other words, the entire cognitive pattern was beyond the limits of available theoretical accounts.

The main conclusion of this study is that components of the language-processing system can lateralize separately (see Caplan, 1987). Similarly, the constellation of attentional processes and nonverbal cognitive skills can be lateralized independently from language abilities in these anomalous cases, so that many different pictures can derive. This conclusion supports the concept that there is no obligatory link in the development of these functions (Fischer et al., 1991), but addresses only the phenomenonic observations of exceptions in functional brain lateralization. Despite the many detailed studies in literature, the nature of mechanisms through which lateralization occurs remains undetermined. We feel that attempts at comprehensive theories about the distribution of cognitive functions across hemispheres (e.g., Geschwind and Galaburda, 1985) must also account for the independent, anomalous lateralization of verbal and nonverbal skills demonstrated by the present longitudinal cognitive analysis.

REFERENCES

- Albert, M. L. 1973. A simple test of visual neglect. *Neurology*, **23**, 658-664.
- Alexander, M. P., Fischette, M. R., & Fischer, R. S. 1989. Crossed aphasias can be mirror image or anomalous. Case reports, review, and hypothesis. *Brain*, **112**, 953-973.
- Basso, A., Capitani, E., Laiacona, M., & Zanobio, M. E. 1985. Crossed aphasia: one or more syndrome? *Cortex*, **21**, 25-45.

- Basso, A., Capitani, E., & Vignolo, L. A. 1979. Influence of rehabilitation on language skills in aphasic patients. A controlled study. *Archives of Neurology*, **36**, 190-196.
- Baxter, D. M., & Warrington, E. K. 1983. Neglect dysgraphia. *Journal of Neurology, Neurosurgery and Psychiatry*, **45**, 1073-1078.
- Behrmann, M., Moscovitch, M., Black, S. E., & Mozer, M. 1990. Perceptual and conceptual mechanisms in neglect dyslexia. Two contrasting case studies. *Brain*, **113**, 1163-1184.
- Berndt, R. S., Mitchum, C. C., & Price, T. R. 1991. Short-term memory and sentence comprehension. An investigation of a patient with crossed aphasia. *Brain*, **114**, 263-280.
- Brown, J. W., & Hécaen, H. 1976. Lateralization and language representation. Observation on aphasia in children, left-handers, and "anomalous" dextrals. *Neurology*, **26**, 183-189.
- Brown, J. W., & Wilson, F. R. 1973. Crossed aphasia in a dextral. A case report. *Neurology*, **23**, 907-911.
- Cancelliere, A. E. B., & Kertesz, A. 1990. Lesion localization in acquired deficits of emotional expression and comprehension. *Brain and Language*, **13**, 133-147.
- Caplan, D. 1987. *Neurolinguistics and linguistic aphasiology: An introduction*. Cambridge: Cambridge Univ. Press. Pp. 347-368.
- Cappa, S., & Vallar, G. 1992. The role of the left and right hemispheres in recovery from aphasia. *Aphasiology*, **6**, 359-372.
- Caramazza, A., Basili, A. G., Koller, J. J., & Berndt, R. S. 1981. An investigation of repetition and language processing in a case of conduction aphasia. *Brain and Language*, **14**, 235-271.
- Caramazza, A., & Hillis, A. E. 1990. Levels of representations, coordinate frames, and unilateral neglect. *Cognitive Neuropsychology*, **7**, 391-455.
- Caramazza, A., Miceli, G., Villa, G., & Romani, C. 1987. The role of the graphemic buffer in spelling: Evidence from a case of acquired dysgraphia. *Cognition*, **26**, 59-85.
- Caramazza, A., & Zurif, E. B. 1976. Dissociation of algorithmic and heuristic processes in language comprehension: Evidence from aphasia. *Brain and Language*, **3**, 572-582.
- Carr, M. S., Jacobson, T., & Boller, F. 1981. Crossed aphasia: analysis of four cases. *Brain and Language*, **14**, 190-202.
- Castro-Caldas, A., Confraria, A., & Poppe, P. 1987. Non-verbal disturbances in crossed aphasia. *Aphasiology*, **1**, 403-413.
- Coppey, P., & Robey, R. R. 1992. Crossed aphasia: new perspectives. *Aphasiology*, **6**, 585-596.
- Crary, M. A., Wertz, R. T., and Deal, J. L. 1992. Classifying aphasias: cluster analysis of Western Aphasia Battery and Boston Diagnostic Examination results. *Aphasiology*, **6**, 29-36.
- De Renzi, E., Motti, F., & Nichelli, P. 1980. Imitating gestures. A quantitative approach to ideomotor apraxia. *Archives of Neurology*, **37**, 6-10.
- Demeurisse, G., Hublet, C., Coekaerts, M. J., Derouck, M., & Capon, A. 1986. Assessment of hemispheric dominance for language in crossed aphasia by two atraumatic methods. *Cortex*, **22**, 305-311.
- Faglia, L., & Vignolo, L. A. 1990. A case of crossed aphasia in which the integrity of the left hemisphere is assessed by NMR. *Italian Journal of Neurological Science*, **11**, 51-55.
- Fischer, R. S., Alexander, M. P., Gabriel, C., Gould, E., & Milione, J. 1991. Reversed lateralization of cognitive functions in right handers. Exceptions to classical aphasiology. *Brain*, **114**, 245-261.
- Gainotti, G. 1985. Constructional apraxia. In J. A. M. Fredericks (Ed.), *Handbook of clinical neurology*. Amsterdam: Elsevier. Vol. 45.

- Gainotti, G. 1989. Disorders of emotion and affect in patients with unilateral brain damage. In J. Grafman (Ed.), *Handbook of neuropsychology*. Amsterdam: Elsevier. Vol. 3.
- Geschwind, N., & Galaburda, A. M. 1985. Cerebral lateralization: Biological mechanisms, associations, and pathology: I. A hypothesis and a program for research. *Archives of Neurology, Chicago*, **42**, 428-459.
- Grossi, D., & Angelini, R. 1992. La riabilitazione dei disordini costruttivi. In A. Mazzucchi (Ed.), *La riabilitazione neuropsicologica*. Bologna: Il Mulino.
- Grossi, D., Modafferi, A., Pelosi, L., & Trojano, L. 1989. On the different role of the cerebral hemispheres in mental imagery. The o'clock test in two clinical cases. *Brain and Cognition*, **10**, 18-27.
- Grossi, D., Trojano, L., Chiacchio, L., Soricelli, A., Mansi, L., Postiglione, A., & Salvatore, M. 1991. Mixed transcortical aphasia: clinical features and neuroanatomical correlates. *European Neurology*, **31**, 204-211.
- Habib, M., Joannette, Y., Ali-Cherif, A., & Poncet, M. 1983. Crossed aphasia in dextrals: a case report with special reference to site of lesion. *Neuropsychologia*, **21**, 413-418.
- Hadar, U., Ticehurst, S., & Wade, J. P. 1991. Crossed anomic aphasia: Mild naming deficits following right brain damage in a dextral patient. *Cortex*, **27**, 459-468.
- Halligan, P. W., & Marshall, J. C. 1992. Left visuo-spatial neglect: a meaningless entity? *Cortex*, **28**, 525-535.
- Henderson, V. W. 1983. Speech fluency in crossed aphasia. *Brain*, **106**, 837-857.
- Hillis, A. E., & Caramazza, A. 1989. The graphemic buffer and attentional mechanisms. *Brain and Language*, **36**, 208-235.
- Hillis, A. E., & Caramazza, A. 1991. Deficit to stimulus-centred letter shape representations in a case of unilateral neglect. *Neuropsychologia*, **29**, 1223-1240.
- Howard, D., & Franklin, S. 1988. *Missing the meaning? A cognitive neuropsychological study of processing of words by an aphasic patient*. Cambridge: MIT Press.
- Kertesz, A., & McCabe, P. 1977. Recovery patterns and prognosis in aphasia. *Brain*, **100**, 1-18.
- Kertesz, A., Lau, W. K., & Polk, M. 1993. The structural determinants of recovery in Wernicke's aphasia. *Brain and Language*, **44**, 153-164.
- Kinsbourne, M., & Warrington, E. K. 1962. A variety of reading disability associated with right hemisphere lesions. *Journal of Neurology, Neurosurgery and Psychiatry*, **25**, 339-344.
- McCarthy, R. A., & Warrington, E. K. 1987. Understanding: a function of short-term memory? *Brain*, **110**, 1565-1578.
- Mehta, Z., & Newcombe, F. 1991. A role for the left hemisphere in spatial processing. *Cortex*, **27**, 153-167.
- Miceli, G., Laudanna, A., & Burani, C. 1990. *Batteria per l'analisi dei deficit afasici*. Milano, Ass. per lo Sviluppo delle Ricerche Neuropsicologiche.
- Miceli, G., Silveri, M. C., Romani, C., & Caramazza, A. 1989. Variation in the pattern of omissions and substitutions of grammatical morphemes in the spontaneous speech of so-called agrammatic patients. *Brain and Language*, **36**, 447-492.
- Naeser, M. A., Helm-Estabrooks, N., Haas, G., Auerbach, S. et al. 1987. Relationship between lesion extent in Wernicke's area on computed tomographic scan and predicting recovery of comprehension in Wernicke's aphasia. *Archives of Neurology*, **44**, 73-82.
- Ochipa, C., & Gonzalez-Rothi, L. J. 1989. Recovery and evolution of a subtype of crossed aphasia. *Aphasiology*, **3**, 465-472.
- Oldfield, R. C. 1971. The assessment and analysis of handedness: The Edinburgh Inventory. *Neuropsychologia*, **9**, 97-113.
- Perani, D., Papagno, C., Cappa, S., Gerundini, P., & Fazio, F. 1988. Crossed aphasia: functional studies with single photon emission computerized tomography. *Cortex*, **24**, 171-178.

- Pizzamiglio, L., Judica, A., Razzano, C., & Zoccolotti, P. 1989. Toward a comprehensive diagnosis of visuo-spatial disorders in unilateral brain damaged patients. *Psychological Assessment*, **5**, 199–218.
- Reinvang, I. 1987. Crossed aphasia and apraxia in an artist. *Aphasiology*, **1**, 423–434.
- Robinson, R. G., & Price, T. R. 1982. Post-stroke depressive disorders: a follow-up study of 103 patients. *Stroke*, **13**, 635–641.
- Ross, E. D., & Rush, A. J. 1981. Diagnosis and neuroanatomical correlates of depression in brain-damaged patients. *Archives of General Psychiatry*, **36**, 1344–1354.
- Rubens, A. B., & Kertesz, A. 1983. The localization of lesions in transcortical aphasias. In A. Kertesz (Ed.), *Localization in Neuropsychology*. New York: Academic Press. Pp. 245–268.
- Spinnler, H., & Tognoni, G. 1987. Standardizzazione e taratura italiana di test neuropsicologici. *Italian Journal of Neurological Sciences*, Supp. 8.
- Trojano, L., Stanzione, M., & Grossi, D. 1992. Verbal short-term memory and learning with auditory phonological coding defect. A neuropsychological case study. *Brain and Cognition*, **18**, 12–33.
- Urbain, E., Seron, X., Remits, A., Cobben, A., Van der Linden, M., & Mouchette, R. 1978. Aphasie croisée chez une droitnière. A propos d'une observation. *Revue neurologique*, **134**, 751–759.
- Walker-Batson, D., Wendt, J. S., Devous, M. D., Barton, M. M., & Bonte, F. J. 1988. A long-term follow-up case study of crossed aphasia assessed by single-photon emission tomography, language, and neuropsychological testing. *Brain and Language*, **33**, 311–322.
- Warrington, E. K. 1991. Right neglect dyslexia. A single case study. *Cognitive Neuropsychology*, **8**, 193–212.