

Patient With Unusual Hutchinson-Gilford Syndrome (Progeria)

Satoshi Matsuo, MD*,
Yoshihiro Takeuchi, MD*,
Shosei Hayashi, MD[†],
Akihiko Kinugasa, MD*, and
Tadashi Sawada, MD*

A patient with unusual Hutchinson-Gilford syndrome (progeria) is reported. This 7-year-old boy had all the characteristics of progeria, except for coxa valga and the "horse-riding" stance. A previous cerebral infarction was detected in the right putamen on cranial magnetic resonance imaging. During treadmill exercise test electrocardiography, ST depression suggested the existence of arteriosclerotic lesions. Skin fibroblast culture exhibited 76% DNA-repair capacity compared to normal. He has not manifested endocrinologic abnormalities. From these findings it is concluded that this patient has an incomplete case of Hutchinson-Gilford syndrome and that a correlation may exist between the clinical features and the degree of DNA-repair capacity.

Matsuo S, Takeuchi Y, Hayashi S, Kinugasa A, Sawada T. Patient with unusual Hutchinson-Gilford syndrome (progeria). *Pediatr Neurol* 1994;10:237-240.

Introduction

Hutchinson-Gilford syndrome (progeria) is a very rare genetic disease. Since the first description by Hutchinson in 1886 [1], 86 patients have been reported in the literature [2]. Children with progeria demonstrate many of the aspects of old age, except for senile cataracts, presbycusis, presbyopia, arcus senilis, osteoarthritis, and senile personalities [3]. No chromosomal abnormality has been detected in progeria, and both autosomal-dominant and autosomal-recessive modes of inheritance have been proposed [4]. The precise mode of inheritance cannot be

determined because patients with progeria cannot have children and because this syndrome is very rare. At the cellular level, the correlation between the ability of DNA repair and cell aging has been reported [5,6]. Wang et al. reported reductions in the amount of ultraviolet light-induced unscheduled DNA synthesis (UDS) in 4 progeria cell strains [7]; however, the correlation between the clinical features and the degree of DNA repair was not mentioned. Our patient manifested an interesting correlation between the clinical features and rate of DNA repair reduction.

Case Report

This 7-year-old boy is the second of 3 children; his 2 brothers are healthy. He was born at term to a 34-year-old mother and 36-year-old father after an uneventful pregnancy and delivery. He weighed 2,080 gm, and his anterior fontanel was larger than normal. In the neonatal period, cranial computed tomography (CT) was normal. At 8 months of age, he was referred to our hospital for evaluation of failure-to-thrive. He weighed 5.6 kg and his length was 66.4 cm. The anterior fontanel was 4 cm × 4 cm which was larger than average for his age. He was diagnosed as having progeria with characteristic features, such as loss of subcutaneous fat, alopecia, prominent scalp veins, micrognathia, thin lips, protruding ears, a high-pitched voice, a pyriform thorax, and stiffness of the joints. His facial features suggest a "plucked-bird appearance." However, he did not exhibit the "horse-riding" stance or coxa valga which are almost always present in progeria [3]. He demonstrated normal motor and mental development. We, therefore, assumed that he had incomplete progeria or another disease. We considered arteriosclerotic diseases, especially coronary disease, although no ischemic change was observed until age 6 years.

He was admitted to our hospital for further investigation at the age of 7 years. He weighed 15.5 kg (-1.9 S.D.) and height was 111.2 cm (-1.6 S.D.). Blood pressure was 82/52 mm Hg in the right upper arm. No abnormal reflex or paresis was present. The results of routine hematologic and chemical studies were all within normal limits. Oral and intravenous glucose tolerance tests disclosed a normal pattern. Plasma insulin-like growth factor I was normal (280 µg/L) and the maximal growth hormone responses to insulin, arginine, levodopa, and glucagon were 22.4, 34.2, 17.7, and 26.1 µg/L, respectively. The peak growth hormone level after growth-hormone-releasing hormone injection was 144 µg/L, which was considered to be greater than the normal range. Magnetic resonance imaging (MRI) revealed a previous brain infarction in the right putamen (Figs 1A, 1B), but no abnormal neurologic symptom was evident. We performed a skin biopsy to confirm the diagnosis after informed parental consent had been obtained. Skin fibroblast culture exhibited a 76% UDS level after ultraviolet light irradiation, in comparison with cells from a control subject (Fig 2). He has not complained of chest pain, but a treadmill exercise test, performed at age 7 years, demonstrated ST depression on electrocardiography (EKG), suggesting the existence of arteriosclerotic lesions. We administered low-dose aspirin (4.6 mg/kg) for its antithrombotic effect.

Discussion

Our patient demonstrated all the characteristics that are invariably present in progeria, except for coxa valga and

From the *Department of Pediatrics; [†] Division of Pediatrics; Children's Research Hospital; Kyoto Prefectural University of Medicine; Kawaramachi-Hirokoji, Kamigyo-ku; Kyoto 602, Japan.

Communications should be addressed to:
Dr. Matsuo; Department of Pediatrics; Kyoto Prefectural University of Medicine; Kawaramachi-Hirokoji, Kamigyo-ku; Kyoto 602, Japan.
Received September 24, 1993; accepted January 13, 1994.

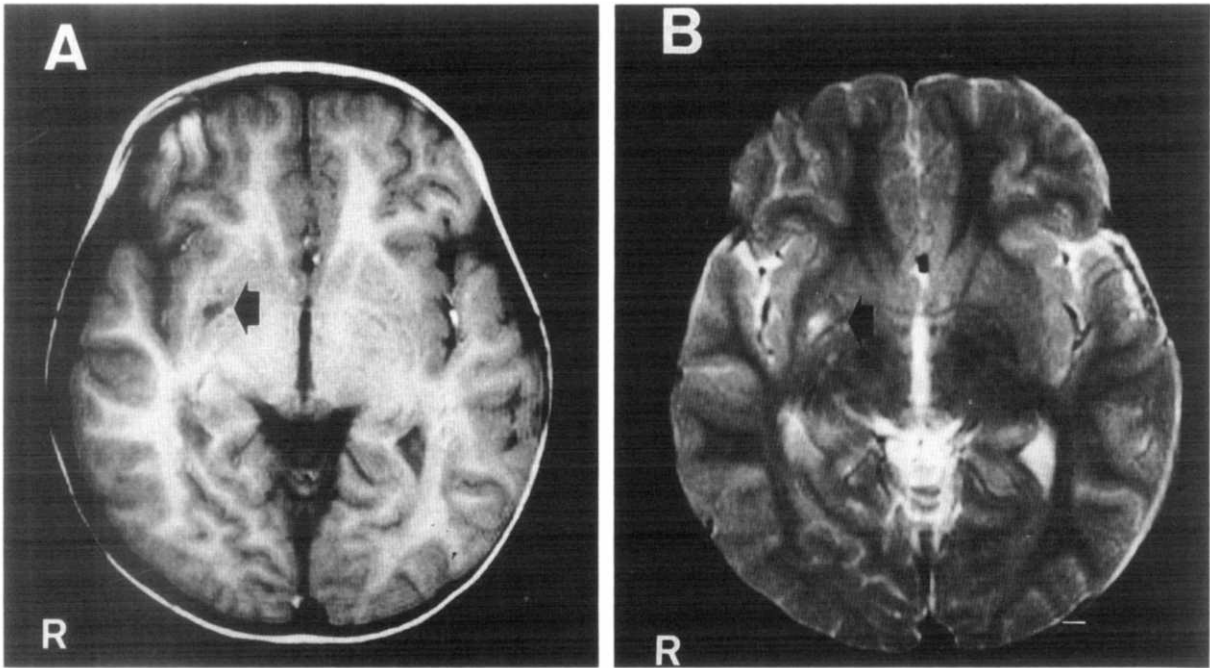


Figure 1. At the age of 6 years, MRI revealed a previous brain infarction in the right putamen (arrows). (A) T_1 -weighted spin echo axial view and (B) T_2 -weighted view.

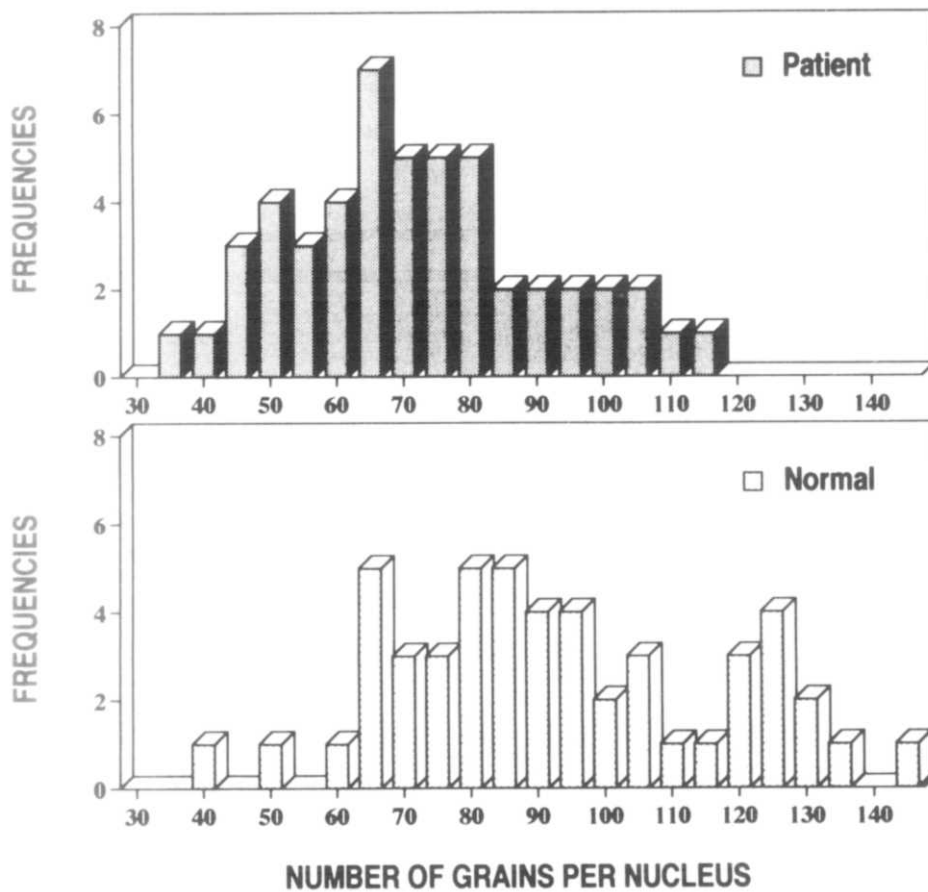


Figure 2. Frequency distribution pattern of UDS after ultraviolet light exposure (30 J/m^2). The number of grains per interphase nucleus was scored for 50 nuclei in each sample. A culture of his skin fibroblasts exhibited 76% UDS after ultraviolet light irradiation, in comparison with cells from a control subject: mean \pm S.D. was 73.2 ± 18.8 for the patient and 94.5 ± 24.7 for the normal control. We compared the UDS levels for the control and our patient using the Mann-Whitney test. The null hypothesis was rejected by $P < .01$, but the reduction was smaller than in the 4 previous reported progeria cell strains.

the horse-riding stance. We believed that this patient had an unusual or incomplete case of progeria because some constant progeria characteristics were absent in him. Later, he manifested arteriosclerotic lesions, such as cerebral infarction and coronary ischemic changes; therefore, we diagnosed him as having progeria.

Concerning endocrinologic findings in progeria, the existence of insulin resistance and a bioinactive form of growth hormone have been reported [8,9]. Recently, a reduction of insulin receptor gene expression in cells was demonstrated in 1 progeria patient [10]; our patient has not demonstrated insulin resistance. It is possible that he may manifest insulin resistance later and/or that he has an incomplete case of progeria. Plasma insulin-like growth factor I and the growth hormone responses were normal. The peak growth hormone level after growth-hormone-releasing hormone injection was greater than the normal range. This finding suggests that his growth hormone is a bioinactive form.

To our knowledge this is the first report of cerebral infarction in progeria without neurologic symptoms, although a few cases of cerebral infarction in progeria were reported recently [11,12]. In contrast to the reported patients, cranial MRI in our patient suggested a small artery lesion. The cardiovascular findings reported in patients with progeria are similar in many respects to changes associated with aging [13]. Baker et al. mentioned that not only the coronary artery, but also the aorta, carotid artery, and small arteries within the myocardium become arteriosclerotic [13]. Thus, it is likely that the small-vessel lesion demonstrated on MRI is arteriosclerotic. Progeric patients usually die of cardiac infarction due to coronary arteriosclerosis. At autopsy, coronary occlusions with myocardial infarctions have been found more frequently than cerebral vascular lesions [3]; however, technological improvements, such as in MRI, now allow for the early finding of small-artery lesions.

Even though many reports have referred to it [4,14,15], the genetic etiology of progeria has remained unknown. To elucidate the etiology of this syndrome, several investigations involving skin fibroblasts from patients were performed [5,6]. Wang et al. reported reductions in the amount of ultraviolet-light-induced UDS in 4 progeria cell strains [7]. The ultraviolet-light-induced UDS in the 4 progeria cell strains was 33–50% of the normal level, which indicated that a defect of DNA repair was present with the progeria. Our patient exhibited a moderate decrease in ultraviolet-light-induced UDS from normal (i.e., 76% of the normal control). The reduction was smaller than in the 4 previously reported progeria cell strains. There are two possibilities as to the pathogenesis of the clinical features in our patient: one is incompleteness of the genetic defect and the other is a genetically different disease than previously reported. Many findings, such as cerebral ischemia observed on MRI and cardiac ischemic changes on EKG, suggested the presence of arteriosclerotic lesions. Moreover, the patient's physical character-

istics are very similar to those of one with progeria. From these findings we conclude that our patient has an incomplete form of Hutchinson-Gilford syndrome. Because he did not manifest all of the characteristics that are invariably present in progeria, and because the reduction of ultraviolet-light-induced UDS was smaller than in the 4 previously reported progeria cell strains, we propose that the physical features and ultraviolet-light-induced UDS findings may be correlated: the milder the impairment of cellular DNA repair, the milder the extent of clinical involvement. There is no suitable explanation for the mechanism underlying the physical characteristics of Hutchinson-Gilford syndrome. The pathogenesis of the clinical features of Hutchinson-Gilford syndrome remains unknown.

Goto et al. demonstrated, by linkage analysis, that the genetic mutations in Werner syndrome—a syndrome that includes premature aging—lay on chromosome 8, band p12 [16]. Moreover, Legerski and Peterson succeeded in cloning a human DNA repair gene involved in xeroderma pigmentosum group C [17]. The genetic approach to the etiology of progeria will likely determine the pathogenesis of the clinical features.

The authors thank Drs. Suming Wang and Hiraku Takebe, the Department of Experimental Radiology, Faculty of Medicine, Kyoto University, for the measurement of unscheduled DNA synthesis.

References

- [1] Hutchinson J. Congenital absence of hair and mammary glands with an atrophic condition of the skin and its appendages in a boy whose mother had been almost totally bald from alopecia areata from the age of six. *Medico-Chirurgical Transactions* 1886;69:473-7.
- [2] DeBusk FL. Progeria. In: Behrman RE, ed. *Nelson textbook of pediatrics*, 14th ed. Philadelphia: W.B. Saunders, 1992;1765.
- [3] DeBusk FL. The Hutchinson-Gilford progeria syndrome. *J Pediatr* 1972;80:697-724.
- [4] Monu JU, Benka CL, Fatunde Y. Hutchinson-Gilford progeria syndrome in siblings. Report of three new cases. *Skeletal Radiol* 1990;19:585-90.
- [5] Epstein J, Williams JR, Little JB. Deficient DNA repair in human progeroid cells. *Proc Natl Acad Sci USA* 1973;70:977-81.
- [6] Stackniak ZD, Sharp ZD, Pool TB, Cameron IL. Impaired proliferation response after PDGF induction in fibroblasts from Hutchinson-Gilford progeria syndrome. *Cell Biol Int Rep* 1988;12:621-6.
- [7] Wang SM, Nishigori C, Yagi T, Takebe H. Reduced DNA repair in progeria cells and effects of gamma-ray irradiation on UV-induced unscheduled DNA synthesis in normal and progeria cells. *Mutat Res* 1991;256:59-66.
- [8] Rosenbloom AL, Kappy MS, DeBusk FL, Francis GL, Philpot TJ, Maclaren NK. Progeria: Insulin resistance and hyperglycemia. *J Pediatr* 1983;102:400-2.
- [9] Brown WT. Progeria: A human-disease model of accelerated aging. *Am J Clin Nutr* 1992;55:1222S-4S.
- [10] Briata P, Bellini C, Vignolo M, Gherzi R. Insulin receptor gene expression is reduced in cells from a progeric patient. *Mol Cell Endocrinol* 1991;75:9-14.
- [11] Wagle WA, Haller JS, Cousins JP. Cerebral infarction in progeria. *Pediatr Neurol* 1992;8:476-7.

[12] **Smith AS**, Wiznitzer M, Karaman BA, Horwitz SJ, Lanzieri CF. MRA detection of vascular occlusion in a child with progeria. *Am J Neuroradiol* 1993;14:441-3.

[13] **Baker PB**, Baba N, Boesel CP. Cardiovascular abnormalities in progeria. Case report and review of the literature. *Arch Pathol Lab Med* 1981;105:384-6.

[14] **Maciel AT**. Evidence for autosomal recessive inheritance of progeria (Hutchinson-Gilford). *Am J Med Genet* 1988;31:483-7.

[15] **Parkash H**, Sidhu SS, Raghavan R, Deshmukh RN. Hutchinson-Gilford progeria: Familial occurrence. *Am J Med Genet* 1990;36:431-3.

[16] **Goto M**, Rubenstein M, Weber J, Woods K, Drayna D. Genetic linkage of Werner's syndrome to five markers on chromosome 8. *Nature* 1992;355:735-8.

[17] **Legerski R**, Peterson C. Expression cloning of a human DNA repair gene involved in xeroderma pigmentosum group C. *Nature* 1992;359:70-3.