

# Sneddon and Antiphospholipid Antibody Syndromes Causing Bilateral Thalamic Infarction

P. David Charles, MD and  
Gerald M. Fenichel, MD

---

**A child suffered bilateral thalamic infarction secondary to Sneddon and antiphospholipid antibody syndromes. Her initial findings of hypersomnolence, mood disturbance, and amnesia are characteristic of bilateral thalamic infarction. Clinical and laboratory evaluation confirmed the diagnosis of both Sneddon and antiphospholipid antibody syndromes as the cause of her unusual stroke. The treatment of this patient, based on experience with adult patients, was long-term, high-intensity warfarin anticoagulation.**

---

Charles PD, Fenichel GM. Sneddon and antiphospholipid antibody syndromes causing bilateral thalamic infarction. *Pediatr Neurol* 1994;10:262-263.

---

## Introduction

Sneddon syndrome is livedo reticularis and ischemic cerebrovascular disease [1]; the diagnosis is based only on the clinical features and cannot be confirmed by laboratory tests. Antiphospholipid antibody syndrome is the association of vascular thrombosis, recurrent fetal loss, or thrombocytopenia with serum antiphospholipid antibodies [2]. One-third of patients with Sneddon syndrome have antiphospholipid antibodies and their presence predicts a more severe course [3,4]. Both syndromes are rare in adults [3-6] and even less common in children. We report a 16-year-old girl with both Sneddon and antiphospholipid antibody syndromes. She had bilateral paramedian thalamic infarction in the distribution of the thalamic arteries as described by Percheron [7,8]. The clinical features of bilateral thalamic infarction are distinctive and often do not suggest stroke.

## Case Report

This 16-year-old girl was the product of a normal pregnancy, labor, and delivery. Her growth and development were normal. She was in good health until the day of hospital admission when she told her teacher and classmates that she was sleepy. She became somnolent and was taken to a local emergency room. Respiratory and hemodynamic status and temperature were normal. Blood glucose and electrolyte concentrations were normal. Treatment with thiamine, 50% dextrose, and Narcan® did not alter her mental state. Urine and serum tests for drugs were negative. After a full day of observation with no change in status she was transferred to Vanderbilt University Medical Center.

Her vital signs included blood pressure 160/100 mm Hg, temperature 37.0°C, heart rate 72 beats/min, and respiratory rate 12 breaths/min. She was a mildly obese (80 kg) girl who appeared asleep but was difficult to arouse with vigorous stimulation. The general medical examination was normal with the exception of a physiologic split of the second heart sound and livedo reticularis of both arms. Glasgow coma scale was 8: eye opening to mildly painful stimuli, occasional spontaneous movement of all limbs (left greater than right), and moaning to loud verbal or mildly painful stimulation. She sometimes responded with single-word answers, often incorrectly. Language and spatial orientation could not be determined. Cranial nerves were normal. The pupils were equal, round, and reactive to light. Extraocular movements were intact. The face was symmetric. Corneal and gag reflexes were present. All limbs withdrew purposefully to painful stimuli (left greater than right), tendon reflexes were normal, and plantar response was flexor.

T<sub>2</sub>-weighted cranial magnetic resonance imaging (MRI) demonstrated bilateral thalamic lesions of high-signal intensity, left greater than right, which did not enhance after intravenous gadolinium administration (Fig 1). Magnetic resonance angiography of the cranial vasculature was normal. Positron emission tomography using F-18 FDG revealed hypometabolism of the left thalamic lesion. Metabolism of the right thalamus was normal. Repeated MRI on hospital day 5 disclosed bilateral gadolinium enhancement of the thalamic lesions. Transthoracic echocardiography was normal, but transesophageal echocardiography demonstrated a plaque-like echodensity on the anterior mitral valve leaflet and mild insufficiency of the mitral and tricuspid valves.

Laboratory studies included normal serum electrolyte concentrations, hepatic and renal function studies, and a complete blood count with indices. Platelet count was 165,000/mm<sup>3</sup>. Repeated urine and serum toxicology studies were negative. Examination of the cerebrospinal fluid (CSF) demonstrated clear and colorless fluid, opening pressure 220 mm, 1 mononuclear cell/mm<sup>3</sup>, 2 erythrocytes/mm<sup>3</sup>, glucose 59 mg/dl, and protein 31 mg/dl. Viral and bacterial cultures and cytology examination of the CSF were negative as were 3 sets of bacterial blood cultures. Other negative studies included human immunodeficiency viral antibodies, direct Coombs, anti-DNA antibodies, and antinuclear cytoplasmic antibodies, RPR, thyroid function tests, protein C and S antigen, antithrombin III activity, CH50, and dilute thromboplastin time. Serum concentrations of anticardiolipin antibody and antinuclear antibody (1+ speckled pattern, titer 1:160) were elevated.

Her level of consciousness waxed and waned for at least 10 days and then began to improve. The hypertension noted on the admission examination resolved without therapy on hospital day 2. The slightly elevated opening pressure on lumbar puncture was likely due to hypertension. She was never febrile during the 17 days of hospitalization. Speech and occupational therapy were started on hospital day 2 and continued after discharge. Two months after discharge, she exhibited emotional lability and impaired recent memory, calculations, and constructions. Cranial nerve function, strength, tendon reflexes, coordination, and gait were

---

From the Department of Neurology; Vanderbilt University School of Medicine; Nashville, Tennessee.

Communications should be addressed to: Dr. Fenichel; Department of Neurology; Vanderbilt University School of Medicine; 2100 Pierce Avenue; Nashville, TN 37212-3375.

Received December 7, 1993; accepted February 23, 1994.

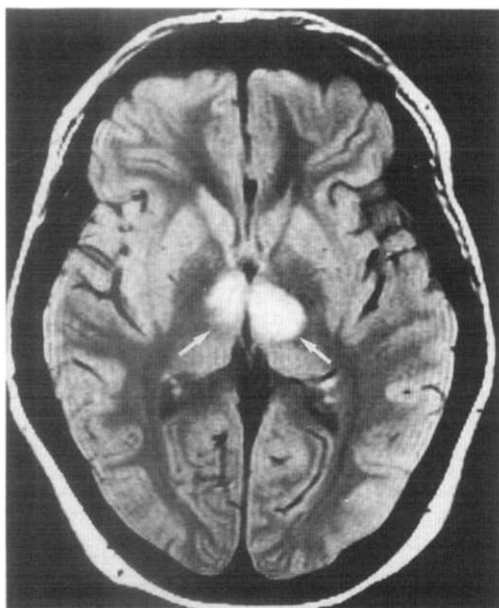


Figure 1. Proton-density, spin-echo weighted (TE: 20 ms, TR: 2,500 ms) cranial MRI demonstrating bilateral thalamic lesions (arrows).

normal. Stereognosis was abnormal in the right hand. Livedo reticularis persisted in the arms and was evident to a lesser extent in the legs.

## Discussion

Our patient suffered an unusual stroke syndrome from an unusual cause. Stroke, in an otherwise healthy child, requires an intensive investigation to determine the underlying cause. Two possible causes were identified: antiphospholipid antibody syndrome and Sneddon syndrome. Despite a normal transthoracic echocardiography, a transesophageal study was consistent with Libman-Sachs endocarditis, a condition associated with antiphospholipid antibody syndrome [9-11]. Lesions of Libman-Sachs endocarditis can embolize, but in our patient, the mitral valve lesion moved in concert with the mitral valve and was not vibratory when interrogated by M-mode, making embolization less likely. However, both the antiphospholipid antibody syndrome and Sneddon syndrome are independently associated with thrombotic cerebrovascular ischemia [2,3]. We believe that cerebrovascular thrombosis secondary to either Sneddon syndrome or antiphospholipid antibody syndrome or both is the most likely diagnosis.

This patient's initial symptom of sleepiness is common during bilateral paramedian thalamic ischemia [12]. Occlusion of the thalamic vasculature causes bilateral paramedian thalamic infarction [7,8]. Such infarction is characterized by amnesia and impairment of vigilance, mood, and vertical gaze [12]. Our patient did not have vertical gaze paresis, but did have hypersomnolence, poor memory, and mood disturbance. Her mood and memory im-

pairments have continued during 3 months of follow-up and are causing significant morbidity.

More than one-half of adults (53%) with serum antiphospholipid antibodies and a single thrombotic event have recurrences [6]. When the first event is arterial, then subsequent events are also likely to be arterial [6]. High-intensity anticoagulation with warfarin (INR  $\geq 3.0$ ) provides better antithrombotic protection than low- or intermediate-intensity warfarin or aspirin for such patients [6]. Clinical trials of plasma exchange or immunosuppressive therapy have not been reported. Stroke associated with antiphospholipid antibody syndrome is rare in children [13,14] and treatment is based on the adult experience. Long-term, high-intensity anticoagulation is the treatment of choice for adults with cardiac valvular lesions and cerebrovascular ischemia associated with serum antiphospholipid antibodies. We elected to treat this patient with long-term, high-intensity warfarin (INR 3-4.5) and aspirin (325 mg daily).

## References

- [1] Sneddon IB. Cerebrovascular lesions and livedo reticularis. *Br J Dermatol* 1965;77:180-5.
- [2] Sammaritano LR, Azzudin GE, Lockshin MD. Antiphospholipid antibody syndrome: Immunologic and clinical aspects. *Semin Arthritis Rheum* 1990;20:81-96.
- [3] Kalashnikova LA, Nasonov EL, Kushebaeva AE, Gracheva LA. Anticardiolipin antibodies in Sneddon's syndrome. *Neurology* 1990;40:464-7.
- [4] Levine SR, Langer SL, Albers GW, Welch KMA. Sneddon's syndrome: An antiphospholipid antibody syndrome? *Neurology* 1988;38:798-800.
- [5] Levine SR, Welch KMA. Cerebrovascular ischemia associated with lupus anticoagulant. *Stroke* 1987;18:257-63.
- [6] Rosove MH, Brewer PMC. Antiphospholipid thrombosis: Clinical course after the first thrombotic event in 70 patients. *Ann Intern Med* 1992;117:303-8.
- [7] Percheron G. Les artères du thalamus humain. Artere et territoire thalamiques polaires de l'artere communicante posterieure. *Rev Neurol* 1976;132:297-308.
- [8] Percheron G. Les artères du thalamus humain. Arteres et territoires thalamiques paramedians de l'artere basilaire communicante. *Rev Neurol* 1976;132:309-24.
- [9] Anderson D, Bell D, Lodge R, Grant E. Recurrent cerebral ischemia and mitral valve vegetation in a patient with antiphospholipid antibodies. *J Rheumatol* 1987;14:839-41.
- [10] Asherson RA, Gibson DG, Evans DW, Baguley E, Hughes GRV. Diagnostic and therapeutic problems in two patients with antiphospholipid antibodies, heart valve lesions, and transient ischaemic attacks. *Ann Rheumatol Dis* 1988;47:947-53.
- [11] Chartash EK, Lans DM, Paget SA, Qamae T, Lockshin MD. Aortic insufficiency and mitral regurgitation in patients with systemic lupus erythematosus and the antiphospholipid antibody syndrome. *Am J Med* 1989;86:406-12.
- [12] Massimo G, DeRenzi E, Crisi G. Bilateral paramedian thalamic artery infarcts: Report of eight cases. *J Neurol Neurosurg Psychiatry* 1987;50:900-9.
- [13] Roddy SM, Giang DW. Antiphospholipid antibodies and stroke in an infant. *Pediatrics* 1991;87:933-5.
- [14] Devilat M, Toso M, Morales M. Childhood stroke associated with protein C or S deficiency and primary antiphospholipid syndrome. *Pediatr Neurol* 1993;9:67-70.