

Cerebral Hyperemia in MELAS

T.I. Gropen, MD; I. Prohovnik, PhD; T.K. Tatemichi, MD; M. Hirano, MD

Background The pathophysiology of strokelike episodes in MELAS (mitochondrial encephalomyopathy, lactic acidosis, and strokelike episodes) is uncertain.

Case Description We studied a 24-year-old man with MELAS who had fluent aphasia and right hemianopia. Magnetic resonance imaging and computed tomography showed a large infarction in the parietal, temporal, and occipital lobes. We performed serial planar ^{133}Xe regional cerebral blood flow studies and single-photon emission computed tomography. Fifteen and 26 days after the strokelike episode, there was generalized hyperperfusion, highest in infarcted areas. Four and 8 months after the strokelike episode, the brain was still

hyperemic, with highest flow in noninfarcted tissue. Reactivity to CO_2 was less than normal within the infarct at 26 days but improved thereafter. In the noninfarcted region, vasomotor reactivity was impaired at 4 months, when resting flows were at their peak.

Conclusions We observed generalized cerebral hyperemia and fluctuating CO_2 reactivity in MELAS, possibly a consequence of local lactic acid production. In addition, this case suggests that nonquantitative functional imaging may be misleading in MELAS. (*Stroke*. 1994;25:1873-1876.)

Key Words • cerebral blood flow • diagnostic imaging • MELAS syndrome • mitochondrial encephalomyopathy

Since 1984, when Pavlakis et al¹ introduced the acronym MELAS for mitochondrial encephalomyopathy with lactic acidosis and strokelike episodes, much progress has been made in understanding its underlying genetic and biochemical basis. In most reported cases, MELAS has been associated with a point mutation of mitochondrial DNA and complex I deficiency.² However, the relation between laboratory abnormalities and clinical manifestations is not clear. Some characteristic symptoms such as nausea, vomiting, and exercise intolerance may be related directly to the lactic acidosis that results from impaired oxidative metabolism. The pathophysiology of strokelike episodes in MELAS is less certain. Some investigators have emphasized the importance of pathological changes in cerebral vessels,^{3,4} but abnormal brain metabolism has also been implicated.^{5,6}

We carried out a serial quantitative study of cerebral perfusion and hypercapnic reactivity after a strokelike episode in MELAS. Our observations support the possibility that local production of lactic acid may be the basis for strokelike events and other cerebral manifestations of MELAS, and they underscore the limitations of nonquantitative functional imaging in investigation of diseases with diffuse alterations of cerebral blood flow.

Case Report

In our patient, early development was normal except for short stature. Family history was notable for mental

retardation in the brother of his maternal grandmother and short stature in his mother and one of his two brothers. He was well until age 24, when he was admitted to a local hospital after a generalized seizure at home. Cerebrospinal fluid protein was 56 mg/dL but was otherwise normal. Computed tomography (CT) demonstrated extensive calcification of the basal ganglia but was otherwise normal. The electroencephalogram (EEG) was normal. Five days after admission, another seizure occurred, and postictally the patient was found to have a right hemianopia and aphasia. CT and magnetic resonance imaging (MRI) performed after the event revealed infarction in the left parietal, temporal, and occipital lobes. Seven days after the strokelike episode, the EEG showed left-sided delta activity and sharp waves.

Examination at Columbia-Presbyterian Medical Center 13 days after the strokelike episode revealed fluent aphasia with prosodic but empty speech; semantic paraphasic errors; severely impaired auditory comprehension, naming, reading, and writing; and less impaired repetition. In addition, we found poor memory, right hemianopia, pigmentary retinopathy, and right-sided hemisensory loss. Cerebral angiogram 14 days after the strokelike episode showed normal major vessels, including the carotid and vertebral arteries, but mild irregularity and slow filling of the calcarine branch of the left posterior cerebral artery. An EEG 26 days after the strokelike episode showed left-sided delta activity, left occipital sharp waves, and an isolated instance of a frontal maximal but diffusely reflecting spike and wave. No electrographic seizures were recorded. Other laboratory findings included a resting arterial lactate of 6.8 mmol/L (reference, 0.5 to 1.6 mmol/L), electromyographic evidence of myopathy, sensorineural hearing loss, and a point mutation in mitochondrial DNA-encoded transfer RNA^{Leu} (^{UUR}) (at 3243 base pairs) in the patient and his mother (analysis by M. Hirano in laboratory of E. Schon).

CT performed 13 days after and MRI performed 19 days after the strokelike episode were consistent with

Received January 28, 1994; final revision received May 2, 1994; accepted May 18, 1994.

From the Department of Neurology, State University of New York, Health Science Center at Brooklyn (T.I.G.), and the Departments of Neurology (I.P., T.K.T., M.H.), Psychiatry (I.P.), and Radiology (I.P.), Columbia-Presbyterian Medical Center, New York, NY.

Presented in part at the 117th annual meeting of the American Neurological Association, Toronto, Canada, October 19, 1992.

Reprint requests to Dr I. Prohovnik, Department of Brain Imaging, Psychiatric Institute, 722 W 168th St, New York, NY 10032.

© 1994 American Heart Association, Inc.

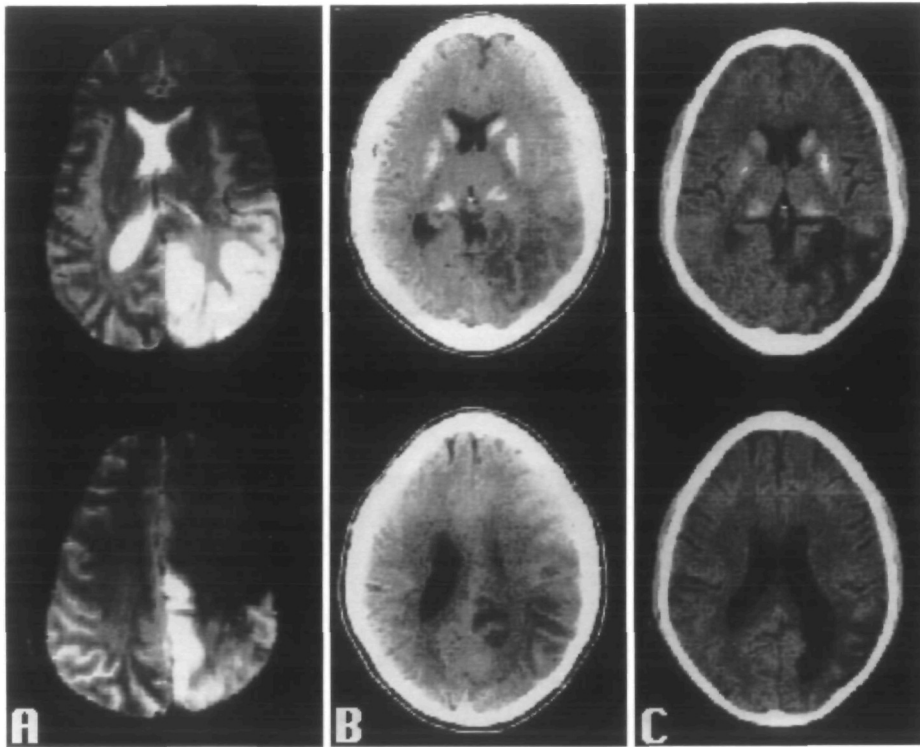


Fig 1. Magnetic resonance imaging performed 19 days (A) and computed tomography (CT) performed 13 days (B) after the strokelike episode show infarction involving the left parietal, posterior temporal, and occipital lobes in a multiterritorial distribution. CT performed 10 weeks after the strokelike episode (C) shows focal atrophy of the left parietal, temporal, and occipital lobes and enlargement of the left lateral ventricle. CT scans show extensive calcification of the basal ganglia.

infarction involving the left parietal, posterior temporal, and occipital lobes in a multiterritorial distribution (Fig 1A and 1B). Ten weeks after the strokelike episode, the patient exhibited mild dysnomia, dyslexia, memory impairment, and partial right hemianopia. CT then showed a chronic infarct, with focal atrophy of the left parietal, temporal, and occipital lobes and enlargement of the left lateral ventricle (Fig 1C). Eight months after the strokelike episode, the patient had only rare paraphasias while reading, and visual fields were full to confrontation.

Quantitative planar ¹³³Xe regional cerebral blood flow (rCBF) examinations (Novo Diagnostic Systems, Cerebrograph 32c) were performed at 15 and 26 days and at 4 and 8 months after the strokelike episode. This patient's ¹³³Xe rCBF values were interpreted in relation to a control group of 37 men aged 20 to 30 years (I.P., T.I.G., unpublished data) studied in our laboratory. Based on control group data, this patient's expected flow level (\pm SD) was 54 ± 9.0 mL/100 g per minute. We

considered hyperemia to be present only when normocapnic perfusion was at least 73 mL/100 g per minute, 2 SD above that expected for age and sex. We adjusted for end-tidal $Paco_2$ at the time of examination because rCBF is influenced by end-tidal $Paco_2$,⁷ and generally our patient was hypocapnic. Hypocapnia may have been a consequence of respiratory compensation for lactic acidosis. The initial resting study showed a well-demarcated area of high flow in the posterior left hemisphere (involving nine detectors in the left parietal and occipital lobes, posterior temporal lobe, and posterior frontal lobe) corresponding to the lesion on CT and MRI. This was defined as the infarct region, and all other regions of both hemispheres were considered noninfarcted. The Table provides flow values for both regions and estimates of cortical flow for end-tidal $Paco_2=40$ mm Hg (adjusted initial slope index), based on reactivity to CO_2 within the infarct and in noninfarcted regions. On day 26 and 4 months after the strokelike episode, there was generalized hyperemia. At 8 months, perfusion in the

Results of ¹³³Xe Regional Cerebral Blood Flow Studies

Region	Time After Strokelike Episode													
	15 Days		26 Days				4 Months				8 Months			
	Rest ISI	Rest CO ₂	Rest ISI	Rest CO ₂	Reac %	Adj ISI	Rest ISI	Rest CO ₂	Reac %	Adj ISI	Rest ISI	Rest CO ₂	Reac %	Adj ISI
Infarct	75	25	69	17	1.0†	86*	74	40	1.5	74*	52	31	1.9	61
Other	59	25	44	17	5.3	96*	88	40	0.9†	88*	62	31	1.8	72*

ISI indicates mean initial slope index (milliliters per 100 g per minute); Rest ISI, ISI during resting study; Rest CO₂, end-tidal $Paco_2$ during resting study (millimeters of mercury); Reac, hypercapnic reactivity (percent per millimeters of mercury); and Adj ISI, estimates of cortical flow adjusted for end-tidal $Paco_2=40$.

*Hyperemic adj ISI values, defined as perfusion at least 2 SD above that expected for age and sex after adjusting for end-tidal $Paco_2$ at the time of examination. In the present case, flow ≥ 72 mL/100 g per minute is considered hyperemic.

†Inadequate hypercapnic reactivity, defined as reactivity $< 1.5\%/mm$ Hg.

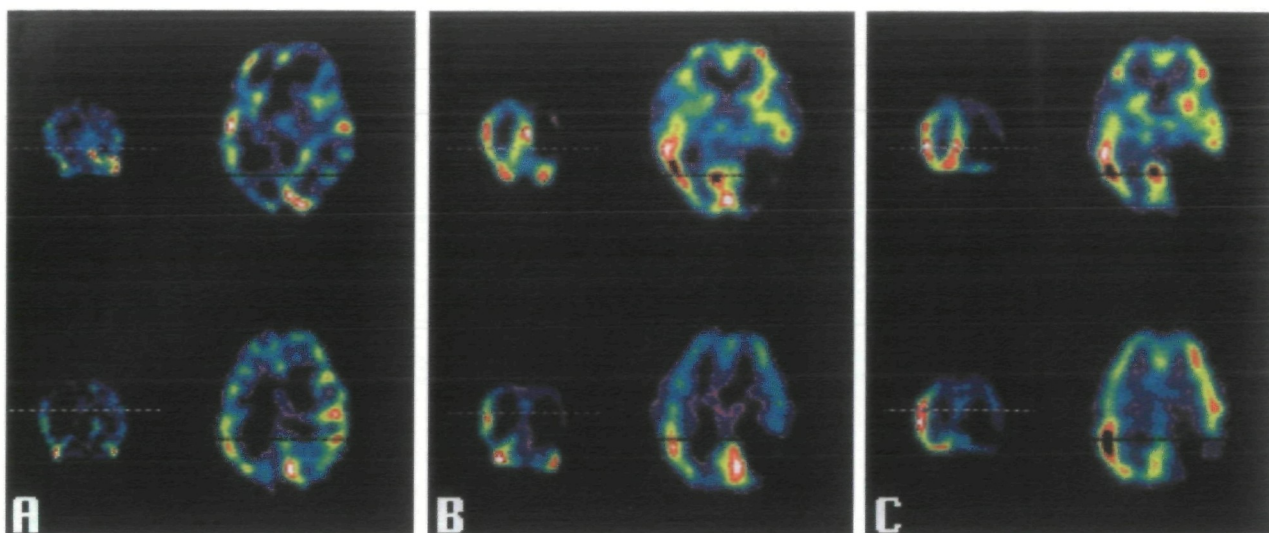


FIG 2. Single-photon emission computed tomography images at 15 days (A), 4 months (B), and 8 months (C) after infarction. At each date, axial and corresponding coronal images are shown at two levels. In all images, red represents highest tracer uptake; deep blue, lowest; and blue, green, and yellow, intermediate levels in ascending order. All images are normalized to their own maximum. On the initial study there is greater uptake in the left posterior hemisphere, corresponding to the infarct on computed tomography and magnetic resonance imaging. On later studies there is much lower tracer uptake in this region.

infarct region declined to a level approximately 1 SD above that expected for noninfarcted normal control subjects, but there was still hyperemia in noninfarcted areas.

Vasomotor response to hypercapnia was measured by ^{133}Xe rCBF after inhalation of 4% CO_2 . Reactivity was defined as percent change of flow per millimeter of mercury change of end-tidal PaCO_2 . Reactivity below 1.5%/mm Hg was considered impaired based on ^{133}Xe rCBF in normal subjects⁷ and a study correlating positron emission tomography measures of hemodynamic reserve and hypercapnic reactivity measured by ^{133}Xe rCBF.⁸ Reactivity to 4% hypercapnic challenge was below normal within the infarct region when first tested at 26 days but normal thereafter, improving on each subsequent examination. In the noninfarcted regions hypercapnic reactivity was initially normal when resting flows were at their nadir, but it was impaired at 4 months when resting flows were at their peak. At 8 months, when resting flows had declined somewhat, hypercapnic reactivity had improved (Table). Thus, in noninfarcted regions there appeared to be an inverse relation between flow and reactivity.

The first single-photon emission computed tomography (SPECT) scan used dual-isotope imaging to obtain cerebral blood flow and cerebral blood volume images, using *N*-isopropyl- p - ^{123}I jiodoamphetamine (^{123}I IMP) and $^{99\text{m}}\text{Tc}$ -labeled red blood cells, respectively. All subsequent scans used $^{99\text{m}}\text{Tc}$ -hexamethylpropyleneamine oxime (HMPAO). ^{123}I IMP SPECT, 15 days after the strokelike episode, showed 20% to 30% greater uptake within the infarct than in noninfarcted regions (Fig 2A), accompanied by greater volume in the posterior left hemisphere. Four months after the strokelike episode, $^{99\text{m}}\text{Tc}$ -HMPAO SPECT showed 50% to 60% less uptake in the infarct, and 8 months after the strokelike episode, there was still much less uptake in the infarct region (Fig 2B and 2C, respectively).

Discussion

We found generalized cerebral hyperemia in a patient with MELAS. Watahiki et al⁹ previously found generalized cerebral hyperperfusion in one patient studied 2 months after a strokelike episode. We extended that finding by showing that generalized hyperemia persisted 4 months after a strokelike episode and was present in the noninfarcted regions 8 months after the strokelike episode. It is not clear whether this hyperemia represents an active adaptive attempt to compensate for metabolic imbalance or a passive response to tissue acidosis. Watahiki et al also found that the hyperemia was accompanied by low values of cerebral metabolic rate (CMR) for oxygen and oxygen extraction fraction with preservation of CMR for glucose, indicating a reduction in use of oxygen relative to glucose, a pattern consistent with glycolysis to lactate or other intermediate metabolites. These studies provide evidence that the metabolic defect (and associated hyperemia) in MELAS can be expressed in cerebral tissue and suggest that hyperemia might be the result of limited oxidative glucose metabolism or increased lactic acid production. Alternatively, hyperemia in our patient may have been the result of ongoing epileptic activity, since ictal rCBF and CMR are increased severalfold.¹⁰ We believe that it is unlikely that frequent or continuous seizures are a basis for hyperemia because seizures were not observed after the strokelike episode, and two EEGs after the event did not show electrographic seizures. However, the metabolic demands imposed by seizures may have been important precipitants of strokelike episodes in MELAS because seizures are almost always a part of the clinical syndrome and are the most frequent presenting symptom.²

We found infarction in a multiterritorial distribution. The finding by us and others² of infarction in the distribution of multiple large vessels despite generally normal angiography argues against large-vessel occlusion. The possibility of stenosis or occlusion of small

arteries, arterioles, and capillaries was suggested by the finding of abnormal mitochondria in the vascular smooth muscle and endothelium of cerebral vessels.³⁻⁵ However, if MELAS-associated strokelike episodes resulted primarily from small-vessel pathology, there should be small infarcts rather than the typically large confluent region of infarction observed in this and other MELAS cases. Nevertheless, compromise of the microcirculation as a result of edema may contribute to the ultimate degree of tissue injury.

The variability of the vasomotor response to CO₂ deserves comment. The transient focal loss of hypercapnic reactivity in both infarcted and noninfarcted regions was unlikely to have resulted from diminished perfusion pressure because flow was increased and there was no severe stenosis or occlusion on the angiogram. Poor hypercapnic reactivity at times of high flow may be due to limited capacity of resistance vessels to dilate further, secondary to structural limitations. Another possibility is that both increased flow and decreased reactivity are the result of local lactic acidosis. There have been no other studies of hypercapnic reactivity in MELAS, but loss of vasomotor response to CO₂ and acute focal hyperemia have been documented in ischemic stroke, being attributed to lactic acidosis.^{11,12} Brain lactic acidosis has been documented in MELAS after strokelike episodes^{1,4,5} and in disorders of pyruvate metabolism¹³ by examination of cerebrospinal fluid. Local production of lactic acid may also explain the disappearance of CT lucencies in MELAS after intervals of 2 weeks to 2 months²; lactic acid can induce intracellular edema without obligatory progression to cell death in tissue culture experiments.^{14,15} Finally, local spread of lactic acid might explain the multivascular topography of lesions in MELAS. MELAS might be a model for lactic acid-related cell injury in more typical stroke.

The results of our study suggest that nonquantitative functional imaging by itself may be misleading in conditions with diffuse alterations in flow, such as MELAS. For example, SPECT performed 4 months after the strokelike episode showed the relative flow difference between the infarcted and noninfarcted regions but failed to detect the generalized hyperemia. Others also noted preservation of quantitative cerebral blood flow in regions of poor tracer uptake.¹⁶ Additionally, interpretation of asymmetries in tracer uptake may be complicated, as in subacute ischemic stroke, by diaschisis or hyperfixation of HMPAO.¹⁷ Quantitative functional imaging is therefore needed in future investigations of MELAS.

Strokelike episodes in MELAS may be a metabolic event, similar to the "metabolic stroke" attributed to toxic organic acid metabolites in patients with methylmalonic acidemia.¹⁸ First, structural and functional imaging findings are not typical of ischemic infarction. Second, a known and fundamental aspect of MELAS, lactic acidosis, may be the basis for its cerebral manifestations. Although our findings support a metabolic basis for strokelike episodes in MELAS, we recognize that several non-mutually exclusive pathogenic mechanisms may produce cerebral injury in this disorder. The relative significance of lactic acidosis, impaired microcirculation, and increased substrate demands might be

explored by examination of patients with the MELAS point mutation over the full course of the disease.

Acknowledgments

This study was supported in part by grants HL-28381, NS-27325, and NS-26179. We appreciate constructive criticisms by Lewis P. Rowland, MD, and Steven G. Pavlakakis, MD.

References

- Pavlakakis SG, Phillips PC, DiMauro S, De Vivo DC, Rowland LP. Mitochondrial myopathy, encephalopathy, lactic acidosis, and strokelike episodes: a distinctive clinical syndrome. *Ann Neurol*. 1984;16:481-488.
- Hirano M, Ricci E, Koenigsberger MR, Defendini R, Pavlakakis SG, De Vivo DC, DiMauro S, Rowland LP. MELAS: an original case and clinical criteria for diagnosis. *Neuromuscul Disord*. 1992;2:125-135.
- Ohama E, Ohara S, Ikuta F, Tanaka K, Nishizawa M, Miyatake T. Mitochondrial angiopathy in cerebral blood vessels of mitochondrial encephalomyopathy. *Acta Neuropathol*. 1987;74:226-233.
- Kishi M, Yamamura Y, Kurihara T, Fukuhara N, Tsuruta K, Matsukura S, Hayashi T, Nakagawa M, Kuriyama M. An autopsy case of mitochondrial encephalomyopathy: biochemical and electron microscopic studies of the brain. *J Neurol Sci*. 1988;86:31-40.
- Ihara Y, Namba R, Kuroda S, Sato T, Shirabe T. Mitochondrial encephalomyopathy (MELAS): pathological study and successful therapy with co-enzyme Q10 and idebenone. *J Neurol Sci*. 1989;90:263-271.
- Morita K, Ono S, Fukunaga M, Yasuda T, Higashi Y, Terao A, Morita R. Increased accumulation of n-isopropyl-p-(¹²⁵I)-iodoamphetamine in two cases with mitochondrial encephalomyopathy with lactic acidosis and strokelike episodes (MELAS). *Neuroradiology*. 1989;31:358-361.
- Tominaga S, Strandgaard S, Uemura K, Ito K, Kutsuzawa T, Lassen NA, Nakamura T. Cerebrovascular CO₂ reactivity in normotensive and hypertensive man. *Stroke*. 1976;7:507-510.
- Herold S, Brown MM, Frackowiak RSJ, Mansfield AO, Thomas DJ, Marshall J. Assessment of cerebral haemodynamic reserve: correlation between PET parameters and CO₂ reactivity measured by the intravenous ¹³³xenon injection technique. *J Neurol Neurosurg Psychiatry*. 1988;51:1045-1050.
- Watahiki Y, Tomiyama M, Nagata K, Shishido F, Kobayashi Y, Komatsu K, Goto A, Takada G. Positron emission tomographic study in patients with MELAS. *No To Hattatsu*. 1988;20:404-411.
- Kuhl DE, Engel J Jr, Phelps ME, Selin C. Epileptic patterns of local cerebral metabolism and perfusion in humans determined by emission computed tomography of ¹⁸FDG and ¹³NH₃. *Ann Neurol*. 1980;8:348-360.
- Lassen NA. The luxury-perfusion syndrome and its possible relation to acute metabolic acidosis localised within the brain. *Lancet*. 1966;2:1113-1115.
- Paulsen OB. Regional cerebral blood flow in apoplexy due to occlusion of the middle cerebral artery. *Neurology*. 1970;20:63-77.
- Brown GK, Haan EA, Kirby DM, Scholem RD, Wraith JE, Rogers JG, Danks DM. 'Cerebral' lactic acidosis: defects in pyruvate metabolism with profound brain damage and minimal systemic acidosis. *Eur J Pediatr*. 1988;147:10-14.
- Staub F, Baethmann A, Peters J, Weigt H, Kempfski O. Effects of lactic acidosis on glial cell volume and viability. *J Cereb Blood Flow Metab*. 1990;10:866-876.
- Lomneth R, Medrano S, Gruenstein EI. The role of transmembrane pH gradients in the lactic acid induced swelling of astrocytes. *Brain Res*. 1990;523:69-77.
- Satoh M, Ishikawa N, Yoshizawa T, Takeda T, Akisada M. N-Isopropyl-p-(¹²⁵I) iodoamphetamine SPECT in MELAS syndrome: comparison with CT and MR imaging. *J Comput Assist Tomogr*. 1991;15:77-82.
- Sperling B, Lassen NA. Hyperfixation of HMPAO in subacute ischemic stroke leading to spuriously high estimates of cerebral blood flow by SPECT. *Stroke*. 1993;24:193-194.
- Heidenreich R, Natowicz M, Hainline BE, Berman P, Kelley RI, Hillman RE, Berry GT. Acute extrapyramidal syndrome in methylmalonic acidemia: 'metabolic stroke' involving the globus pallidus. *J Pediatr*. 1988;113:1022-1027.