



0028-3932(93)E0032-6

## THE NATURE OF TACTILE AGNOSIA: A CASE STUDY

CATHERINE L. REED\* and RICHARD J. CASELLI†

Department of Psychology, University of Pennsylvania, Philadelphia, PA, U.S.A.; and

†Department of Neurology, Mayo Clinic, Scottsdale, AZ, U.S.A.

(Received 4 May 1993; accepted 5 November 1993)

**Abstract**—A chronic tactile agnostic with a small, MRI-documented left inferior parietal infarction underwent detailed somesthetic testing to assess (1) the acquisition of sensory data, (2) the manipulation of somatosensory percept and its association with previous knowledge, and (3) recognition occurring at a deeper taxonomic level. Results suggest that tactile agnosia can arise from faulty high-level perceptual processes, but that the ability to associate tactually defined objects and object parts with episodic memory can be preserved. Consistent with anatomic and physiologic studies in nonhuman primates, inferior parietal cortex (including Brodmann area 40, possibly area 39) appears to serve as a high-level somatosensory region.

### INTRODUCTION

TACTILE agnosia is a modality-specific disorder characterized by impaired ability to recognize objects tactually in the absence of more basic somesthetic dysfunction [8]. It is distinguished from basic somesthetic insensitivity, supramodal spatial disorders (hemi-neglect), or misnaming due to aphasia [3–5, 8, 34, 37]. This paper addresses the question of which step, or steps in the perceptual–mnemonic pathway have been rendered faulty in a tactile agnostic. Three broad possibilities are considered. The first is that the acquisition of sensory data is inaccurate either because of a disordered search strategy or because of interference of competing stimuli. The second is that the rudimentary sensory percept cannot be properly manipulated to permit a match with the stored mental representation at a generic level. The third is that the recognition level failure occurs at a deeper taxonomic level.

Regarding the first possibility, a prior study of patients with upper limb weakness (but no basic sensory deficits) due to stroke showed that hemiparesis alone causes little or no disturbance of tactile object recognition [4]. Nonetheless, normal subjects exhibit stereotypical methods for extracting particular tactile properties of objects [21]. For example, pressing is optimal for encoding hardness, whereas rubbing is optimal for encoding texture. These exploratory motor-tactile procedures are normally combined efficiently according to constraint satisfaction processes [19, 29]. Hence, in patients with tactile agnosia without evident disrupted movement, it is relevant to ask whether a normal motor-tactile search strategy is employed. Sensory integration itself might be faulty in that different somesthetic properties may influence the perception of each other [19, 29]. For example, does length influence the perception of width in tactile agnosics?

---

\*Address for correspondence: Catherine Reed, Department of Psychology, University of Pennsylvania, 3815 Walnut St., Philadelphia, PA 19104-6196, U.S.A.

Regarding the second possibility, objects must be recognized from various "viewpoints" (object orientation). For recognition to occur, the system needs to either use information which is constant to the object irrespective of the viewpoint [23] or mentally rotate an object to its canonical orientation [16, 17, 35]. Once the basic sensory input is encoded and grouped, the associative steps may proceed. The description of the object taken from its assumed orientation may be matched against stored knowledge of the object's form. Recognition occurs when a match is found. If mental rotation influences tactile object recognition, then mental rotation of handled objects should be impaired in tactile agnosics. A failure may also lie at the level of the semantic representations themselves, either because the representations are defective, or because they have been rendered relatively inaccessible. For example, the inability to tactually recognize a key might result from inexperience with a key [8], or difficulty in retrieving stored generic knowledge that a 3-in. rough metal object that is round at one end and elongated at the other may be a key. Mental imagery permits objects to be compared on the basis of learned physical attributes, and might be defective in tactile agnosics. If mental imagery is defective, then it is also relevant to ask whether such a defect is specific for haptic imagery, or due to defective mental imagery (including visual) in general.

Finally, regarding the third possibility, object memory may be more severely impaired at taxonomically deeper levels of hierarchical categorization. Objects identified at a basic category level (e.g. *a pen*) are categorized and differentiated most easily, and such categorical classification schemes are earliest to develop [32, 33]. Subordinate level categorization (e.g. *my pen*) requires intraclass discriminations among objects that share many features, and is more difficult. Tactile agnosia, therefore, may affect the various hierarchical levels of memory representation differently. Previous work has shown that tactile agnosics have moderate difficulty recognizing impersonal objects [4], but personal object recognition has not been assessed.

We now present our study of a patient with the smallest lesion we have yet encountered to be associated with tactile agnosia. Her unilateral deficit allows her left hand to act as a control for her impaired right hand. In order to identify which steps leading to tactile object recognition have been damaged in our patient, we performed a series of experiments designed to assess exploratory strategies, sensory interactions, mental rotation and mental imagery, and episodic object recognition.

## METHOD

### *Subject*

The patient, E.C., was a 62-year-old, fully right-handed [26], hypertensive woman with a high school education. In 12/89, she abruptly developed an unusual sensation in her right hand which she likened to numbness. Specifically, she noticed that although she could sense objects tactually in her purse or pocket, she was often unable to identify them unless she saw them. There was a transient sense of right hand weakness which resolved within a day. A CT head scan performed the day following onset was normal, but her sensory deficit persisted, with little subjective improvement. Nine months later she abruptly developed a left superior quadrantanopia due to a right infracalcarine occipital infarction, confirmed by MRI. Within the same vascular territory was a second focus of infarction involving the right mesial temporal lobe, due to the same cerebrovascular event as the right occipital infarction. Coincidentally noted, however, was a small left inferior parietal cortical infarction which corresponded to her 12/89 stroke.

Neurologic examination [24] at the Mayo Clinic in April, 1991 confirmed the left superior quadrantanopia without clinically detectable hemiachromatopsia; impaired right hand tactile object recognition; normal hand movement and language. Clinical cognitive assessment included the short test of mental status [20] (score 38 out of 38), the complex figure test [36] (normal copy, but defective recall), and clinical language assessment (normal sentence writing, spelling words, visual and tactile naming, reading aloud and spontaneous discourse). Her only impairments reflected visual memory due to the right mesial temporal infarct (complex figure test) and tactile

agnosia due to the left inferior parietal infarct. Intellect, language, and motor skills in particular were normal. She returned 1 year later for more extensive somesthetic testing.

### *Behavioral experiments*

*Establishing unilateral tactile agnosia (12/89 and 4/92 testing sessions).* Basic somatosensory function, intermediate somatosensory function, and tactile object recognition were assessed using tests described by CASELLI [4]. Testing was performed on two separate occasions, 1 year apart to establish the stability of the tactile agnosia. Additionally she underwent CASE IV [11] testing for vibratory detection threshold.

*The acquisition of sensory data (12/89 and 4/92).*

(i) Response time and exploration of common objects. The patient was videotaped identifying a subset of seven items that the patient did not recognize in the generic object recognition task. Each object was presented once to each hand. Response time (RT) was recorded from the first contact of the hand with the object to the vocal response. Accuracy was also recorded.

(ii) Combining sensory stimuli:

—Somatosensory somatosensory interaction: different dimensions. The effects of varying one dimension (length) on the perception of another (width) and of varying two dimensions (length and width) on the perception of another (depth) were assessed according to tests developed by CASELLI [4].

—Visual-somatosensory interaction: tactile and visual judgement of line orientation. This test, based upon the Judgement of Line Orientation (JLO) task by BENTON *et al.* [1], was modified by CASELLI [4] to include a tactile version of the test.

*The manipulation and association of the sensory percept (4/92).*

(i) Test of haptic mental rotation. Two alphabet letters (either P or F) were affixed to a card, and presented one at a time for the patient to identify tactually. The stimuli were either the letters or their mirror images. Further, they were rotated to one of the following orientations: 0/360 deg (upright), 60, 120, 180 or 240 deg. The patient was first asked to identify the letter, and then, determine whether the stimulus was a mirror image or not. If she failed to identify the letter correctly, she was told the letter was either a P or an F, and asked to choose. If she still failed to correctly identify the letter, she was told its identity and then asked to determine whether the stimulus was the letter itself or its mirror image.

(ii) Test of haptic and visual mental imagery. The patient was asked to compare a series of object pairs in relation to a particular physical property. For example, "Which is harder, an orange or an apple?" Some physical properties required visual mediation (relative complexity of shape or size) and others required tactual mediation (relative hardness, temperature, roughness); half of the comparisons were easy and half were difficult [18].

*Episodic object recognition: test of personal object discrimination (4/92).* This test required the patient to select her personal belongings from a set of five items. Objects were chosen that were commonplace so that five generically similar items could be presented as distractors. The patient either possessed only one such item (such as a wallet), or a small number of exact duplicates (such as a house key). If she possessed several of certain common items, she or her husband was asked to bring in her favorite (such as a necklace). To equate the difficulty of this task with generic object recognition, personal object discrimination was examined in three tasks. In the first task the patient knew what items were going to be tested because she submitted a prescribed set of 14 of her own personal objects before testing. Before each trial, she was given the category of the object (e.g. wallets) and was then instructed to select her personal belonging (e.g. her own wallet) from a set of five generically similar objects (e.g. wallets). In the second task the patient did not know the set of items to be tested; her husband submitted a prescribed set of her personal items. Without being told the category of the object, she was instructed to select her personal belonging ("Which object is yours?") from a set of five objects of the same object category (e.g. all wallets). The third task was similar to the second task with the exception that the distractors were from different object categories (e.g. belt, brush, wallet, curler, ruler, and cup).

### *Neuroanatomical analysis*

Using the template method of DAMASIO and DAMASIO [9], the lesions depicted by MRI were mapped onto a set of neuroanatomical templates.

## RESULTS

### *Behavioral experiments*

*Establishing unilateral tactile agnosia.* The results from the somesthetic tests and tactile object recognition are summarized in Tables 1 and 2, respectively. For many of these tests, the patient's unimpaired, non-dominant left hand served as a control for assessing performance of the right hand.

(i) Basic somatosensory function. E.C.'s performances on the semiquantitative tests of light

Table 1. Basic somatosensory function

<i>Somatosensory sensation tests</i>				
<i>Date</i>	4/91		4/92	
<i>Hand</i>	left	right	left	right
Light touch	normal	normal	normal	normal
Proprioception	normal	normal	normal	normal
Vibratory sensation	normal	normal	normal	normal
2-point discrimination (mm)	3.5	3.5	3.5	3.5
<i>Intermediate somatosensory tests</i>				
<i>Date</i>	4/91		4/92	
<i>Hand</i>	left	right	left	right
Extinction	none	none	none	none
Weight (ratio)	35	35	35	35
Texture	100%	100%	100%	100%
Dimension: L-R (in., no side)		1		1
Dimension: True perceived (in.)	3.75	4.75	4.75	5.75
Shape	100%	100%	100%	80%
Substance	100%	43%	100%	75%

Table 2. Tactile object recognition

<i>Date</i>	4/91		4/92	
	left	right	left	right
<i>Hand</i>				
Generic objects (total)	90%	50%	92.5%	62.5%
Generic large objects	100%	71.4%	95.2%	66.7%
Generic small objects	77.8%	36.8%	89.5%	57.9%
Visual object recognition	100%			

touch, proprioception, and vibratory sensation, were normal for both hands in 4/91 and 4/92. The quantitative test of two-point discrimination was also normal with a consistent distance of 3.5 mm for both hands. CASE IV demonstrated a normal vibratory detection threshold bilaterally. The left dorsal index finger showed a 3.21  $\mu\text{m}$  displacement (76th percentile) and the right dorsal index finger showed a 4.55  $\mu\text{m}$  displacement (86th percentile).

(ii) Intermediate somatosensory tasks:

—Extinction, Weight and Texture. There was no extinction to double simultaneous stimulation in tactile, visual or auditory modalities. Weight perception (discriminating differentially weighted eggs) and texture perception (discriminating four grades of sandpaper) was normal in that E.C. achieved perfect scores with each hand on 4/91 and 4/92.

—Dimension. The intermanual difference of all three perceived dimensions summed for all 4 blocks was 1 in. on 4/91 and 4/92. E.C.'s score was compared to the scores of 11 neurologically normal patients (mean age 50). The mean intermanual difference for the control group was 1.3 in. (S.D. = 0.8 in.). Thus, E.C.'s score was within normal range. The absolute value of the difference between the summed actual dimensions and perceived dimensions for all four blocks in 4/91 was 3.75 in. for the left and 4.75 in. for the right hand. In 4/92 it was 4.75 in. for the left and 5.75 in. for the right. These values are all within two standard deviations of the normal controls whose respective values were 2.8 in. (S.D. = 2.0 in.) for the left and 2.7 in. (S.D. = 1.8 in.) for the right hand.

—Shape. E.C. identified all five shapes with each hand in 4/91, but she missed one shape with her right hand in 4/92. Given her intact performance in one of the testing sessions, it is reasonable to believe that basic shape processing is only slightly impaired in her right hand.

—Substance. The patient was more impaired when she had to identify materials. Although she correctly identified all stimuli with her unaffected left hand, she recognized only 43% in 4/91 and 75% in 4/92 with her right hand.

(iii) Tactile object recognition. E.C. was tested for tactile object recognition in both 4/91 and 4/92. Her performance remained stable between testing sessions. On both occasions, she demonstrated impaired tactile object recognition with the right hand (50% in 4/91, 62.5% in 4/92) compared to her unimpaired left hand (90% in 4/91, 92.5% in 4/92). Thus, a significant asymmetry was found in the performance of the left and right hands, indicating impaired tactile object recognition. Visual object recognition was 100% during both testing sessions. She correctly named all objects she accurately identified tactually and visually.

When the patient guessed the identity of an object, the majority of her errors were structural in nature. For example, she mistakenly identified a pine cone as a brush, a ribbon as a rubber band, and a snail shell as a bottle cap. Other errors were descriptions of the object material. For example, a razor was identified as plastic. Generic object recognition was better for large objects overall, but the intermanual difference was similar for large and small objects, suggesting that size was not a significant factor. However, she had greater success identifying objects within certain categories of small objects, such as pin-like items, than she did in other categories containing larger objects, such as desk accessories.

In summary, our patient has a unilateral tactile agnosia which affects the right hand only. The right hand has relatively preserved basic and intermediate somesthetic function. The left hand is unimpaired and thus may act as a control for assessing right hand performance. No other factors that might adversely influence tactile object recognition, including apraxia, aphasia, or hemiparesis were present.

*The acquisition of sensory data.* Table 3 summarizes the results for this section.

(i) Response time and exploration strategies of common objects. E.C. made no recognition errors with her unimpaired hand. Her accuracy improved with her impaired hand to 71% (5/7). The average time for identification with the left "control" hand was approx. 3 sec. In contrast, the average response time with the impaired right hand was approx. 17 sec. Even when the times for only the recognized objects were examined, the average time to recognize objects with the right hand was approx. 8.34 sec, still considerably longer than the left, non-dominant hand.

Table 3. The acquisition of sensory data

<i>Hand</i>	Left	Right
Course of exploration (7 objects) (tested 4/92)		
Mean overall RT	3 sec	17 sec
Mean correct RT	3 sec	8.34 sec
Mean number of exploratory procedures per object	2	> 3
<i>Date</i>	4/91	4/92
Visual-somatosensory interaction		
Tactile judgement of line orientation (left/right lines)	1/6	7/6
Visual judgement of line orientation (left/right lines)	18/30	NA

When left and right hands were compared for the *types* of motor-tactile procedures used to apprehend information about the object, the two hands executed the same procedures. The unimpaired hand recognized objects quickly, often just by grasping the object. She would first grasp the object and then rub it before identifying it. However, the right hand required additional information and executed additional procedures. On average, the control hand executed two separate procedures for identifying an object; it grasped the object and then rubbed it. In contrast, the impaired hand executed more than three separate procedures for identifying an object: it grasped the object, rubbed it, pressed it, and followed its contours, and then repeated the sequence. The sequence of exploration is similar to that found in normal patients when exploring for detailed object information [21]. The impaired right hand executed *more* than three procedures for 70% of the trials; the left hand executed no more than three exploratory procedures for any of the objects.

(ii) Combining sensory stimuli.

—Somatosensory-somatosensory interaction: different dimensions. When one dimension (length) was varied and perceived width was measured, (actual width held constant), a significant ( $P < 0.007$ , one-tailed *t*-test) difference was noted in the normal left hand perception of width when length was varied for the first block pair; however, no other significant interactions were seen either in the controls or in our patient. When two dimensions were varied (length and width) and perceived depth was measured, all depth perceptions were the same in E.C., despite minor alterations in perceived depth in some control subjects. In summary, there was no discernible alteration of interaction between multiple dimensions, affecting her impaired right hand.

—Visual-somatosensory interaction: tactile and visual judgement of line orientation. E.C.'s performance with her left hand was slightly abnormal. Although she made only one error with left lines, which was within normal range, she made six errors with right lines, which was abnormal when compared to 10 normal controls (mean age 49 years) with respective scores of 2.4 (left hand, left line S.D. = 1.7) and 3.6 (left hand, right line S.D. = 1.1). E.C.'s performance with her impaired right hand was relatively normal. With her right hand, her left line error score was seven and her right line error score was six which are both within normal limits when compared to normal control scores of 3.8 (right hand, left line S.D. = 3.1) and 5.2 (right hand, right line S.D. = 2.0) for the left and right lines, respectively.

E.C. scored 18/30 on the visual JLO, which is slightly below normal range. It suggests a disorder of spatial orientation that is affecting visual judgement. It is possible that this could have adversely affected her tactile JLO since she had to visually match the somesthetically perceived target angle.

*The manipulation and association of the sensory percept.*

(i) Test of haptic mental rotation. E.C. correctly identified the orientation of the letter (whether it was mirror reversed or not) in 55% of rotation trials (11/20) and 50% of 0-deg trials (2/4) with her impaired right hand. This score is little better than chance, suggesting that her mental rotation abilities are more impaired than might be expected by her impaired letter recognition alone (71% correct). It should be noted that orientation scores were for known letters; the patient either guessed the identity of the letter or was told before she made an orientation judgement. Considering only the letters she correctly identified herself, she guessed the correct orientation only 50% of the time. In contrast, with her unimpaired left hand she correctly judged the orientation of the letters in 85% of rotation trials (17/20) and 100% of 0-deg trials (4/4). She made no errors in identifying the letters with her left hand.

(ii) Test of haptic and visual mental imagery. E.C. was correct on 86% (31/36) of the imagery

judgements regarding tactile or visual properties. For easy discriminations, she was 100% correct for primarily tactile properties (roughness, hardness, temperature, weight) and 100% for primarily visual properties (size, shape). For difficult discriminations, she was 67% correct (8/12) for primarily tactile properties and 83.3% (5/6) for primarily visual properties. When her performance was compared to five normal control subjects (mean age 27.5), her imagery judgements were within normal limits. These results suggest that the patient had no difficulty accessing somatosensory and visual knowledge about objects since she could make fine-level discriminations about objects properties (see Table 4).

Table 4. Manipulation and association of the sensory percept (tested 4/92)

	Left hand	Right hand
Haptic mental rotation	91.7%	54%
	Patient	Controls
Haptic and visual imagery		
Total (36 items)	86%	87%
Visual mediation—easy (6 items)	100%	100%
Visual mediation—difficult (6 items)	83.3%	72.2%
Haptic mediation—easy (12 items)	100%	100%
Haptic mediation—difficult (12 items)	67%	65%

*Episodic object recognition: Test of personal object discrimination.* The results are summarized in Table 5. Overall, in three tasks requiring the patient to discriminate her personal item from an array of impersonal items, E.C. was 91.7% (22/24) correct with her left control hand. With her impaired right hand, she correctly identified 75% (18/24) of her personal effects.

Table 5. Episodic object recognition (tested 4/92 and 4/93)

	Left hand	Right hand
Personal object discrimination		
Overall	91.7%	75%
Known object set and category with same category distractors	100%	78.6%
Unknown object set and category with same category distractors	83.3%	66.7%
Unknown object set and category with different category distractors	75%	75%

(i) Select from Like Objects: Set of Personal Items and Category of Object Known. E.C. made no errors in selecting her personal item from a set of impersonal but generically related items with her left control hand. With her impaired right hand, she correctly recognized 78.6% (11/14) of her personal effects. She failed to recognize her house key, car key and pen. When asked how she was able to identify personal objects with her impaired hand, she reported that she searched for a unique feature of the personal item, such as a small teardrop crystal on her necklace, and reasoned that the item must be her own.

(ii) Select from Like Objects: Set of Personal Items and Category of Object Unknown. E.C. correctly identified 83.3% (5/6) of her personal items from an array of same category

distractors with her left control hand and 66.7% (4/6) of her personal items with her impaired right hand. Although she failed to recognize her pen with both hands, she also failed to recognize her ring with her impaired hand.

(iii) Select from Unlike Objects: Set of Personal Items and Category of Object Unknown. E.C. correctly distinguished 75% (3/4) of her items with both hands. She could not recognize her hair curler with either hand. Hence, although personal object recognition was still impaired with her right hand, it was better than generic object recognition (75% vs 62.5%, respectively).

#### *Neuroanatomical analyses*

Figure 1 shows the MRI and corresponding template analysis of the infarctions. The scan reveals two lesions. Most relevant for this study is the *left* inferior parietal infarction. Experience to date [3, 4] suggests that damage which includes this area produces tactile agnosia. It corresponds to Brodmann area 40 and, to a lesser degree, 39. The *right* hemisphere infarction corresponds to Brodmann areas 17 (infracalcarine), 18 and 36 (parahippocampal gyrus). Although this second lesion could also affect certain aspects of her behavior (e.g. nonverbal aspects of memory), other patients with lesions in similar areas do not have any observable tactile deficits [4]. Further, E.C. did not describe any new somatosensory symptoms at the time of onset.

## DISCUSSION

Our results suggest that tactile agnosia is a high-level perceptual disorder that can result from a failure to integrate accurately acquired somesthetic features into a haptic mental image which can then be manipulated.

We first investigated whether the acquisition of sensory data was inaccurate because of interference of competing stimuli or because of a disordered search strategy. In our patient, basic and intermediate somesthetic function was relatively preserved, indicating that submodal somatosensory input was sufficiently decoded. Multidimensional processing of object structure was also preserved, indicating that competing dimensional parameters did not interfere with sensory decoding of each individual parameter (e.g. length did not impede the perception of width). However, although normal object exploration patterns were executed, exploration was overly repetitive during object identification tasks. Her behavior and self reports suggest that our patient had difficulty combining accurately decoded object parts into cohesive tactile representations.

Next, we examined whether the rudimentary sensory percept could be properly manipulated and associated to permit a match with the stored mental representation at a generic level. Haptic mental rotation was impaired even when the alphabet letter was correctly identified when manipulated by the affected hand, indicating an inability to manipulate the somesthetic percept that was not due to impaired somatosensory orientation in view of preserved tactile orientation (tactile JOL task). Further, haptic mental imagery was normal, indicating intact knowledge about tactile properties of objects. Thus, our patient's tactile agnosia did not result from a failure to associate the normally integrated percept with previously acquired memories.

Last, we investigated whether the recognition level failure was more severe at deeper taxonomic levels. We found no evidence of impaired association between the percept and episodic memory. Rather, tactile object recognition appeared to be facilitated by preserved



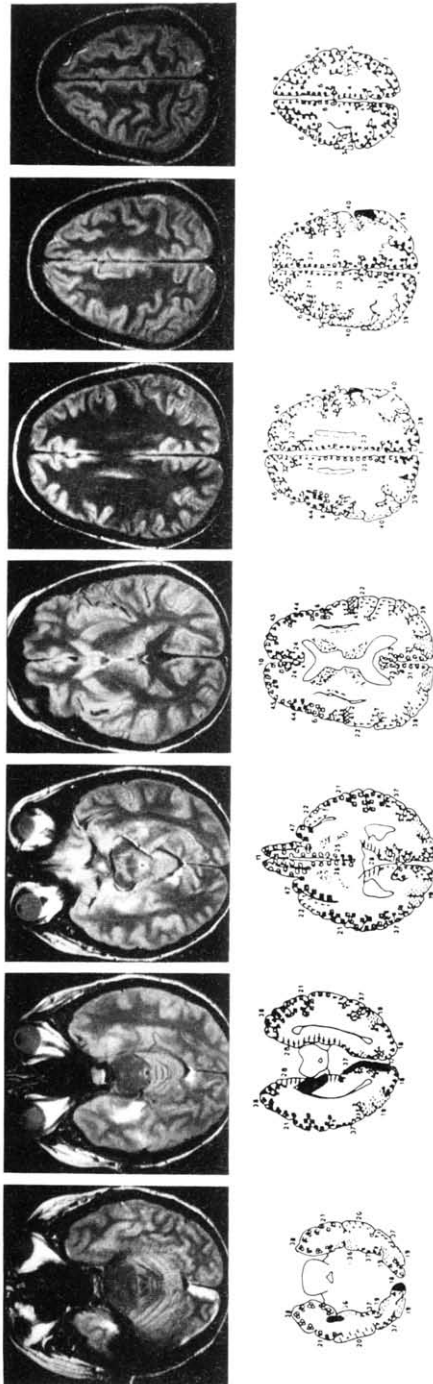


Fig. 1. MRI and anatomical templates in the top row show the proton density weighted MRI transverse sections depicting two discrete areas of infarction. The relevant lesion is located in the left inferior parietal lobe, and involves part of Brodmann area 40 and to a lesser degree area 39. The second and larger area of infarction involves right mesial temporal, retrosplenial, and mesial occipital cortices.



access to episodic memories associated with personal objects. In contrast to prosopagnosia, generic object recognition was more impaired than personal object recognition. The tactile object recognition failure was unilateral, suggesting that identification fails before entry into topographically distributed representations (which, if accessed then facilitate recognition). Our results, therefore, are most consistent with tactile agnosia resulting from a high-level perceptual disorder which involves the integrating of basic sensory information to form a tactile representation and manipulating that representation.

Despite our patient's problems with forming a coherent tactile percept with her impaired hand, she was still able to learn and recognize with effort objects she initially failed to recognize. This occurred despite damage to right mesial temporal structures (with evidently impaired visual memory on the complex figure test). We suspect the reason lies in her preserved ability to access episodic memory. The initial somesthetic and visual object recognition tasks (which included her unimpaired hand as well as her impaired hand) permitted her to identify all objects in the set at least twice, and those which she failed to recognize (with her impaired hand only) comprised a smaller subset. Despite impaired sensory integration processes, preserved interaction between perceptual processes and episodic memory permitted the learning of new objects.

That certain object features can be used to evoke associated stored personal memories suggests that tactile object recognition is an interactive system—both bottom-up perceptual information and top-down object knowledge drive object recognition [25]. Tactile perceptual processes drive information to levels holding stored information about particular types of objects. Similarities between the tactile-motor input and stored representations permit the recognition and categorization of an object and its parts. Basic features of an object become activated when an object is felt. Consequently, higher-level representations of objects with those features become activated as well. Newly activated memorized information can then feed back down to lower levels thus activating more memories, affecting the perceptual processes themselves. That is, episodic memory and stored object knowledge should exert top-down influences on tactile sensory information during the tactile object recognition process. For within-class discrimination tasks, feature values are the basis for identification. If the object recognition system can activate a critical defining feature from episodic and semantic memory, then it can identify which object is the personal item. Therefore, tactile object recognition is facilitated if the patient can use previous experience with the object and its features.

The availability of episodic object information demonstrated by our patient's tactile object recognition performance suggests a different mechanism for the recognition failure between tactile agnosia and prosopagnosia. Both tactile agnosics and prosopagnosics have normal exploratory strategies [30] and preserved abilities to perceive the values of a finite set of physical properties [38]. However, prosopagnosics have normal categorical face recognition such that they correctly identify a human face as a human face, including attributes such as age, gender, and expression, but have impaired episodic object recognition [10, 38]. Conversely in our patient, access to episodic memory regarding an object is preserved and facilitates recognition, but there is greater impairment of generic object recognition manifesting as a failure at more superficial taxonomic levels. Whether there are also taxonomically deeper forms of tactile agnosia which would be analogous to prosopagnosia remains an open question.

The formulation of tactile agnosia as a high-level perceptual somesthetic disturbance fits well with anatomical and physiological data supporting a somatosensory role for inferior

parietal cortices. SI is bounded ventrolaterally by SII (parietal operculum), which has been mapped in many animal species [15, 31, 39] and in humans [22, 27]. In cats [6, 7, 11] and monkeys [2, 14], two other somatosensory areas contiguous to SII have been described, and labelled SIII (inferior parietal cortex) and SIV (posterior insular and retroinsular cortex). Each region contains its own somatotopic representation of the body, and the somatotopic patterns differ between regions. Human neuroanatomical counterparts to SIII and SIV have not been studied to date. In the monkey, area 7b below the intraparietal sulcus and abutting the posterior parietal operculum is thought to be the simian homologue of SIII [2]. Human homologies, inferred from modern cytoarchitectonic data of the inferior parietal lobule [12, 13], and anatomical studies supporting the existence of a ventral or perisylvian parietofrontal somatosensory network [15, 28], suggest that SIII may include areas PF and PG within Brodmann areas 40 and 39, respectively, as these areas extend posteriorly from the parietal operculum, and are inferior to the intraparietal sulcus. Our behavioral data lend further support to the idea that the inferior parietal lobule has a somatosensory function.

In conclusion, we have demonstrated that a selective disruption in tactile object recognition can result from a modality specific somesthetic integration step that combines the preserved submodal features into a coherent somesthetic image. Failure of this integration step is correlated with damage to a small area in the inferior parietal lobule.

*Acknowledgements*—This research was supported by grants awarded to Dr Reed from NIMH (NS-09339), to Dr Caselli from the Mayo Foundation, and to Dr Martha Farah from NIMH (R01-MH48274), ONR (N00014-91-J-1546), and the McDonnell-Pew Program in Cognitive Neuroscience (90-36). The authors wish to thank Dr Martha Farah for her helpful comments on this project.

## REFERENCES

- BENTON, A. L., HAMSHER, K. DE S., VARNEY, N. R. and SPREEN, O. *Contributions to Neuropsychological Assessment*. Oxford University Press, New York, 1983.
- BURTON, H. and ROBINSON, C. J. Organization of the SII parietal cortex: multiple somatic sensory representations within and near the second somatic sensory area of cynomolgous monkeys. In *Cortical Sensory Organization*, C. N. WOOLSEY (Editor), Vol. 1, pp. 67–119. Humana Press, Clifton, New Jersey, 1981.
- CASELLI, R. J. Ventrolateral and dorsomedial somatosensory association cortex damage produces distinct somesthetic syndromes. *Neurology* **43**, in press.
- CASELLI, R. J. Rediscovering tactile agnosia. *Mayo Clin. Proc.* **66**, 129–142, 1991.
- CASELLI, R. J. Bilateral impairment of somesthetically mediated object recognition in humans. *Mayo Clin. Proc.* **66**, 1357–1364, 1991.
- CLEMO, H. R. and STEIN, B. E. Somatosensory cortex: a “new” somatotopic representation. *Brain Res.* **235**, 162–168, 1982.
- CLEMO, H. R. and STEIN, B. E. Organization of a fourth somatosensory area of cortex in cat. *J. Neurophysiol.* **50**, 910–925, 1983.
- CRITCHLEY, M. *The Parietal Lobes*, pp. 86–155. Hafner Publishing Company, New York, 1971.
- DAMASIO, H. and DAMASIO, A. R. *Lesion Analysis in Neuropsychology*. Oxford University Press, New York, 1989.
- DAMASIO, A. R., DAMASIO, H. and VAN HOESEN, G. W. Prosopagnosia: Anatomic basis and behavioral mechanisms. *Neurology* **32**, 331–341, 1982.
- DARIAN-SMITH, I., ISBISTER, J., MOK, H. and YOKOTA, T. Somatic sensory cortical projection areas excited by tactile stimulation of the cat: A triple representation. *J. Physiol. (London)* **182**, 671–689, 1966.
- DYCK, P. G., KARNES, J., O'BRIEN, P. C. and ZIMMERMAN, I. R. Detection threshold of cutaneous sensation in humans. In *Peripheral Neuropathy*, P. G. DYCK, P. K. THOMAS, J. W. GRIFFIN, P. A. LOW and J. F. PODUSLO (Editors), 3rd edn, pp. 706–728. W. B. Saunders, Philadelphia, 1993.
- EIDELBERG, D. and GALABURDA, A. M. Inferior parietal lobule: Divergent architectonic asymmetries in the human brain. *Arch. Neurol.* **41**, 843–852, 1984.
- FRIEDMAN, D. P. Body topography in the second somatic sensory area: Monkey SII somatotopy. In *Cortical Sensory Organization*, C. N. WOOLSEY (Editor), Vol. 1, pp. 121–165. Humana Press, Clifton, NJ, 1981.
- FRIEDMAN, D. P., MURRAY, E. A., O'NEILL, J. B. and MISHKIN, M. Cortical connections of the somatosensory

- fields of the lateral sulcus of macaques: Evidence for a corticolimbic pathway for touch. *J. comp. Neurol.* **252**, 323–347, 1986.
16. JOLICOEUR, P. The time to name disoriented natural objects. *Mem. Cognit.* **13**, 289–303, 1985.
  17. JOLICOEUR, P. Mental rotation and the identification of disoriented objects. *Can. J. Psychol.* **42**, 461–478, 1988.
  18. KLATZKY, R. L., LEDERMAN, S. and MATULA, D. E. Imagined haptic exploration in judgments of object properties. *J. exp. Psychol., Learn. Mem. Cognit.* **17**, 314–322, 1991.
  19. KLATZKY, R. L., LEDERMAN, S. and REED, C. Haptic integration of object properties: Texture, hardness, and planar contour. *J. exp. Psychol., Hum. Percept. Perform.* **15**, 45–57, 1989.
  20. KOKMEN, E., NAESSENS, J. M. and OFFORD, K. P. A short test of mental status: Description and preliminary results. *Mayo Clin. Proc.* **62**, 281–288, 1987.
  21. LEDERMAN, S. J. and KLATZKY, R. L. Hand movements: A window into haptic object recognition. *Cognit. Psychol.* **19**, 342–368, 1987.
  22. LUEDERS, H., LESSER, R. P., DINNER, D. S., HAHN, J. F., SALANGA, V. and MORRIS, H. H. The second sensory area in humans: Evoked potential and electrical stimulation studies. *Ann. Neurol.* **17**, 177–184, 1985.
  23. MARR, D. *Vision*. Freeman, San Francisco, 1982.
  24. MAYO CLINIC AND MAYO FOUNDATION. *Clinical Examinations in Neurology*, 6th edn, pp. 255–275. Mosby Year Book Publishers, St Louis, 1991.
  25. MCCLELLAND, J. L. and RUMELHART, D. E. An interactive model of context effects in letter perception: Pt. 1. An account of basic findings. *Psych. Rev.* **88**, 375–407, 1981.
  26. OLDFIELD, R. C. The assessment and analysis of handedness: The Edinburgh inventory. *Neuropsychologia* **9**, 97–112, 1971.
  27. PENFIELD, W. and JASPER, H. *Epilepsy and the Functional Anatomy of the Human Brain*. Little, Brown & Co., Boston, 1954.
  28. PONS, T. P., GARRAGHTY, P. E., FRIEDMAN, D. P. and MISHKIN, M. Physiological evidence for serial processing in somatosensory cortex. *Science* **237**, 417–420, 1987.
  29. REED, C. L., LEDERMAN, S. J. and KLATZKY, R. L. Haptic integration of planar size with hardness, texture, and planar contour. *Can. J. Psychol.* **44**, 522–545, 1990.
  30. RIZZO, M., HURTIG, R. and DAMASIO, A. R. The role of scanpaths in facial recognition and learning. *Ann. Neurol.* **22**, 41–47, 1987.
  31. ROBINSON, C. J. and BURTON, H. Somatotopographic organization in the second somatosensory area of *M. fascicularis*. *J. comp. Neurol.* **192**, 43–67, 1980.
  32. ROSCH, E. Principles of categorization. In *Cognition and Categorization*, E. ROSCH and B. B. LLOYD (Editors), pp. 28–48. Lawrence Erlbaum, Hillsdale, NJ, 1978.
  33. ROSCH, E., MERVIS, C. B., GRAY, W. D., JOHNSON, D. M. and BOYES-BRAEM, P. Basic objects in natural categories. *Cognit. Psychol.* **8**, 382–439, 1976.
  34. SEMMES, J. A non-tactual factor in astereognosis. *Neuropsychologia* **3**, 295–315, 1965.
  35. TARR, M. J. and PINKER, S. Mental rotation and orientation-dependence in shape recognition. *Cognit. Psychol.* **21**, 233–282, 1989.
  36. TAYLOR, L. B. Localisation of cerebral lesions by psychology testing. *Clin. Neurosurg.* **16**, 269–287, 1968.
  37. TEUBER, H. L. Preface: Disorders of higher tactile and visual functions. *Neuropsychologia* **3**, 287–295, 1965.
  38. TRANEL, D., DAMASIO, A. R. and DAMASIO, H. Intact recognition of facial expression, gender, and age in patients with impaired recognition of facial identity. *Neurology* **38**, 690–696, 1988.
  39. WOOLSEY, C. N. and FAIRMAN, D. Contralateral, ipsilateral, and bilateral representation of cutaneous receptors in somatic areas I and II of cerebral cortex of pig, sheep, and other animals. *Surgery* **19**, 684–702, 1946.