

NONPENETRATING TRAUMA TO THE CAROTID ARTERY: SEVEN CASES AND A LITERATURE REVIEW

Maria S. Li, MD, CM, Baird M. Smith, MD, CM, Jose Espinosa, MD, Rea A. Brown, MD, FRCS(C), Peter Richardson, MD, FRCS(C), and Robert Ford, MD, FRCS(C)

Nonpenetrating carotid trauma is uncommon and frequently missed on initial examination. The cases of seven patients seen over a period of 21 years are presented and 100 cases from the most recent literature are reviewed. Causes and mechanisms of injury, clinical presentation, investigations, management, and outcome are discussed. Causes of injury were three motor vehicle collisions, two falls, one sports injury, and one blow to the face. Clinical presentation was early in four and delayed in three. The earliest symptoms and signs were a change in mental status, headache, unprovoked fall, focal weakness, neglect, and dysphasia. Doppler studies may be useful in screening, but a definitive diagnosis is made with the help of angiography. Two patients were treated surgically; one died, one with delayed symptoms from a pseudoaneurysm recovered completely. Five patients were given anticoagulants; all survived with permanent deficits related to their pretreatment neurologic status. The outcome in 100 recent cases from the literature has improved compared with previous reports. The overall mortality was 12%. The outcome in our seven cases supports recent trends toward a strategy of early anticoagulation and selective surgical treatment.

BLUNT CAROTID INJURY is an uncommon event occurring in less than 1 of 1000 blunt injuries.¹ It occurs much less commonly than penetrating arterial injuries but appears to be increasing. Since two reviews of the literature in 1967 and 1980^{2,3} the volume of trauma, the use of computed tomographic (CT) scanning and an awareness on the part of physicians of blunt carotid injury have risen.

We report seven angiographically documented cases seen from 1972 to 1993 at a tertiary care teaching hospital and review the recent literature, documenting improved outcome. The possible influence of treatment on outcome is reviewed.

CASE REPORTS

Case 1. A 21-year-old female passenger was travelling at 80 km/hr when her car swerved and rolled over. She did not lose consciousness and walked away from the crash. One hour later, at a peripheral hospital, she was found to have a right hemothorax and multiple rib fractures. She was transferred to our institution because of deterioration in her level of consciousness.

Initial physical examination showed facial bruising, minor

abrasions, and a fluctuating level of consciousness. A CT scan of her head showed subtle right temporal edema.

The next morning the patient was difficult to arouse. A soft-tissue swelling was noted on the right side of the neck at the site of her shoulder safety belt. Neurologic examination showed right gaze preference, left visual field cut, left upper motor neuron seventh nerve palsy, no spontaneous movement but withdrawal to left side pain, and left hyperreflexia. Computed tomographic scan showed a large right temporoparietal infarct.

Angiography was performed to determine the source of the infarct; it revealed an irregular narrowing of the right internal carotid (IC) artery just distal to the bulb extending to the skull base with filling defects suggesting thrombus (Fig. 1).

The patient was given anticoagulants (heparin, 2500–5000 U IV bolus once, followed by an IV drip at 1000 U/hour titrated to maintain PTT 1.5–2 times normal or INR of 1.5. This was stopped when coumadin was therapeutic at a dose of 10 mg PO when the patient was able to tolerate oral/nasogastric intake). Surgical intervention was not indicated for a completed stroke. She improved and returned to karate class 5 months later. One year after injury there were minor residual deficits including left upper quadrantanopsia, subtle left upper motor neuron facial palsy, slight pronator drift, and left hyperreflexia. The patient also had seizures and mild cognitive deficits. She was disoriented and could not use the subway. She was unable to return to school, in part also because of her emotional lability since the injury.

Case 2. Three days after a minor skiing injury a 49-year-old man developed a right supra-orbital headache and fell without provocation. Within 15 minutes he became hemiplegic on the left side and was transferred to a local hospital, where he was given anticoagulants (see Case 1) and subsequently treated for increased intracranial pressure and herniation from a hemispheric stroke.

An angiogram, obtained to elucidate the cause of the stroke, showed irregularities in the right internal carotid artery at C-

From the Department of Surgery, Montreal General Hospital, McGill University, Montreal, Quebec.

Presented at the Annual Meeting of the Trauma Association of Canada, September 12, 1992, Ottawa, Canada.

Winner of the clinical research award sponsored by Merck Sharp & Dohme. Winner of the award for best resident paper.

Address for reprints: Dr. Rea A. Brown, Department of Surgery, Montreal General Hospital, 1650 Cedar Ave., Montreal, Quebec, H3G 1A4, Canada.

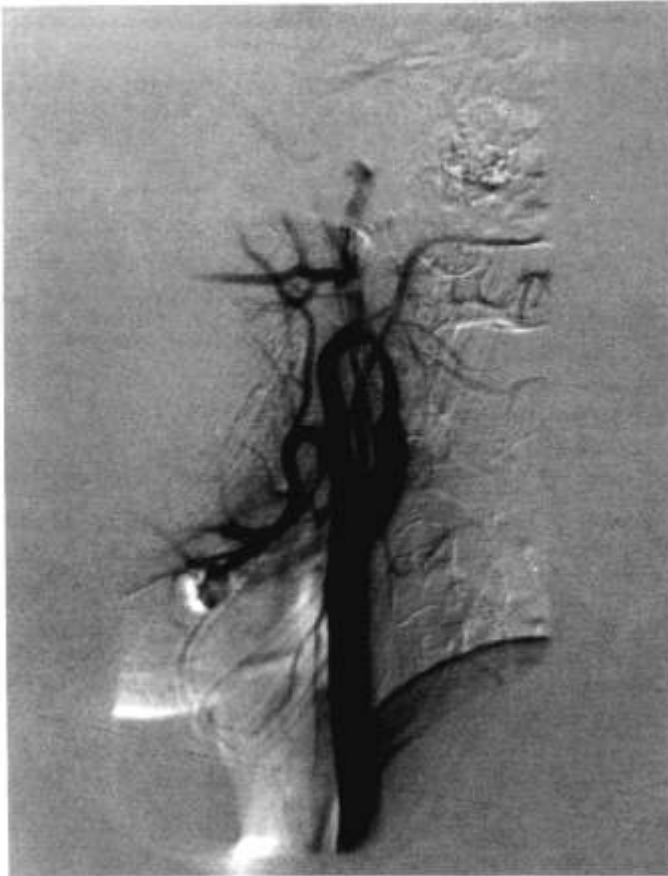


Figure 1. Case 1. Angiogram of right internal carotid showing an irregular narrowing representing dissection just past the bifurcation.

1-2. There was an intimal flap and the middle cerebral artery was only partially revascularized.

The patient was transferred to our institution 2 weeks after the injury with a left facial droop, left hemiplegia, and left hemianesthesia. A CT scan showed a large right-middle cerebral artery (MCA) infarct with ipsilateral ventricular compression and a 4-mm shift of the septum pellucidum. A follow-up angiogram obtained 25 days after the onset of symptoms showed irregularity of the petrous portion of the IC and an aneurysm of the cervical segment with narrowing of the lumen by 50%. Normal flow was seen in the right cavernous sinus, the right anterior, and the right middle cerebral arteries, demonstrating good collateral flow.

Three years later he was able to walk with a cane although he had left-sided spasticity and some left upper extremity sensory loss. Seizures were controlled with anticonvulsant medication.

Case 3. A 20-year-old woman driver wearing a shoulder safety belt was hit by a truck. After laparotomy for repair of a liver laceration, she became drowsy, agitated, confused, and dysphasic. Physical examination revealed left pupillary dilation, right homonymous hemianopsia, right facial droop, right hemiparesis, and extensor plantar responses. There was a mild bruise on her neck. Angiogram showed occlusion of the left ICA 2 cm from the origin and complete occlusion of the MCA above the frontal branches. There was delayed retrograde filling of the left MCA through collaterals.

At operation a 15 × 3 mm serpentine thrombus was removed with a Fogarty catheter and modest flow was achieved. Postoperatively the patient deteriorated and died 3 days later of transtentorial herniation secondary to massive infarction and edema. Autopsy revealed frontal contusions and necrosis, brainstem ischemia and hemorrhage, but the left ICA and MCA were patent.

Case 4. A 30-year-old healthy restrained female passenger travelling at 55 km/hr was involved in a frontal impact. One and a half hours later the patient had a decreasing level of consciousness, left-sided weakness, and numbness. Physical findings included a right pupil sluggishly reactive to light, strength at 4/5 on the left, decreased sensation of pinprick on the left, and an equivocal left plantar reflex. Other injuries included a right clavicle fracture and three finger fractures.

The patient was treated with aspirin after an initial head CT scan produced normal results. An MR-angiogram showed an irregularity in the right internal carotid artery leading to complete occlusion of its proximal one third.

Follow-up examination 3 months later showed mild left-sided weakness apparent in the patient's gait. There was no diplopia. A CT scan of her head 1 month after injury revealed a right posterior temporal infarct. A follow-up MR-angiogram showed recanalization of the carotid although there was a segmental stenosis.

Case 5. A 31-year-old musician was punched in the left cheek. He had a headache and felt unwell but only came to the emergency room 2 weeks later after he suddenly fell to the floor. At that time, he had a headache and a numb distal right upper extremity.

Neurologic examination revealed expressive and receptive dysphasia, agraphia, acalculia, right-left and digital agnosia, and right sided weakness at 4/5. Doppler ultrasound examination of the carotids showed a complete block of the left internal carotid with retrograde flow through the left ophthalmic artery. An angiogram showed a flame-shaped filling then a block distally in the left internal carotid. The left cavernous carotid and middle cerebral artery filled via the ophthalmic artery. There was also filling of the left internal carotid circulation from the right side.

The patient was given heparin and then coumadin (see protocol, Case 1). His speech and cognitive functions improved but had not returned to normal 1 month later. His strength normalized. The patient later committed suicide.

Case 6. A 20-year-old man sustained trauma to the left side of his head during a rugby game. Within 30 minutes he fell and noticed right facial and arm weakness and a frontal headache; he later had difficulty speaking. On admission the patient had right upper motor neuron seventh nerve palsy. Strength was 1/5 in the biceps and triceps with no power distally. The initial CT scan and angiogram were interpreted as normal. The patient was given heparin because a stroke was suspected.

Because the physical findings were not explained by the CT scan findings, four days later an angiogram was repeated. This film showed a smooth tapered segmental narrowing to 1 mm at the horizontal portion of the left middle cerebral artery. Tapered occlusions were seen in the opercular branches and a minimal irregularity was seen in the horizontal part of the anterior cerebral artery. We believed that this embolus arose from the carotid artery.

A follow-up CT scan obtained 25 days after the injury showed an infarct of the left basal ganglia and anterior internal capsule. The patient developed transient ischemic attacks when the level of his anticoagulation became subtherapeutic. He returned to full activity 1 month after discharge and 3 years later had only mild right arm hyperreflexia.

Case 7. Two months after admission to the hospital for paranoid schizophrenia and a borderline personality disorder a 25-year-old man developed confusion, slurred speech, and a right leg weakness. His past medical history included a seven story fall 3 years earlier. A CT scan of his head was interpreted as normal. Angiography revealed a large saccular aneurysm from the medial wall of the left internal carotid 4.5 cm above a narrowed bifurcation. Minor irregularities in the neck of the aneurysm and multiple branch occlusions of the MCA were seen indicating embolization. On cross-compression there was

good evidence of collateral flow through the right anterior and middle cerebral arteries via the anterior communicating artery.

The patient underwent a left carotid endarterectomy and aneurysmorrhaphy with subsequent occlusion of the artery; however, there was retrograde flow through the ophthalmic artery. Six months after surgery the results of the patient's neurologic examination were normal. Later, the patient committed suicide.

Cases 6 and 7 are different from the five preceding cases because in case 6 we did not have definite documentation of carotid injury though we assumed the pathologic state was an embolism from the carotid. In case 7, the lesion was a pseudoaneurysm, which may have a more benign natural history than a dissection.

REVIEW OF THE LITERATURE

After reviewing our seven cases (Table 1), it was not clear that better outcome was related to surgical treatment. This prompted a sequential retrospective review of the last 100 cases in the literature to determine the correlation between different treatments and outcome. Pretreatment neurologic status, CT scan results, shock, and posttreatment angiography results were also correlated with outcome.

The information was obtained by doing a Medline search for the last 100 cases reported in the English and French literature.⁴⁻²⁹ Three series were excluded because there was insufficient information about individual cases.^{1,30,31}

RESULTS

Age and Sex of Patients

Most of these injuries happen in young patients. Sixty-six percent of patients were between 15 and 45 years old. Fifty-three were male, 36 were female (Table 2).

Causes of Injury

Vehicular collisions caused 62% of injuries. Falls, sports mishaps, assaults, direct blows, and miscellaneous causes followed in order of frequency. Miscellaneous causes were two strangulations, one collision with a

person, one birth injury, one plane crash, and one case of intraoral trauma (Table 2).

Presentation

There are rarely external signs of trauma; only 11 of our patients had bruising of the neck. Three had a change in carotid pulsation. The earliest sign is usually a change in the level of consciousness or mental status. Over 70% will eventually have some lateralizing sign in the form of facial or extremity weakness. Less evident localizing signs include Horner's syndrome, visual field defect, or neglect. Some may have headache or seizures (Table 3).

The manifestations of cerebral ischemia appear within 24 hours in 45% of cases. In some, signs may be delayed long after injury; 18% appeared after 24 hours.

Head injury (20%), shock (14%), chest/rib injury (11%), facial fractures (10%), extremity fractures (8%), neck injury (6%), spinal injury (2%), or other trauma may mask blunt carotid injuries.

Diagnostic Studies

Computed tomographic scans, Doppler ultrasound studies, MR-angiograms, and conventional angiograms are used to diagnose blunt carotid injuries. Often the CT scan may be confounded by other lesions including contusions (3 cases), subarachnoid hemorrhages (2 cases), subdural hematomas (2 cases), or local areas of edema. Initial CT scans can appear normal. Doppler ultrasound studies were positive in the four cases in which they were used. Angiography localized the lesion definitively. The majority of lesions were cervical, just past the bifurcation (Table 4).

TREATMENT AND OUTCOME

Of one hundred patients, 30 were treated surgically (24 with revascularization, three with bypass, three with occlusion), 31 were given anticoagulants only (28 heparin and coumadin, and three aspirin), six were both anticoagulated and surgically treated, and 33 received supportive care. Forty-two percent regained normal function; morbidity was 46% and mortality was 12%.

Table 1
Summary of cases from Montreal General Hospital

Age/Sex	Cause	Lesion	Latency	Treatment	Time to Treatment (hours)	Outcome
21/F	MVC	RICA dissection	24 hours	Heparin	36	Field cut; 7th nerve palsy
49/M	Fall	RICA dissection; pseudoaneurysm	72 hours	Heparin	48	Left anaesthesia; contractures; use of cane
20/F	MVC	LICA, MCA occlusion	18 hours	Thrombectomy	7	Death
30/F	MVC	RICA dissection	1½ hours	Aspirin	<24	Left weakness
31/M	Blow	LICA dissection	2 weeks	Heparin	8	Mild cognitive deficit then suicide
20/M	Sport	LMCA, ACA dissection	½ hour	Heparin	8	Hyperreflexia
25/M	Fall	LICA pseudoaneurysm	3 years	Repair; thrombectomy	24	Normal then suicide

MVC = motor vehicle crash; R = right; L = left; ICA = internal carotid artery; MCA = middle cerebral artery; ACA = anterior cerebral artery.

Table 2
Distribution of cases by age and cause of injury

	Number of Patients
Age in Years	
<15	8
15-30	47
31-45	19
46-60	10
61+	4
Not mentioned	12
Causes of Injury	
Motor vehicle crashes (except motorcycles)	53
Motorcycle crashes	8
Bicycle crashes	1
Falls	10
Sports	7
Assaults	6
Direct blows	5
Others	10

Table 3
Initial clinical findings

	Number of Patients
Hemiparesis	60
Change in mental status or level of consciousness	33
Dysphasia or dysarthria	15
Neck bruise or swelling	11
Monoparesis	9
Horner's syndrome	5
Facial droop	3
Headache	3
Seizures	3
Visual field defect	2
Neck bruit	2
Neglect	1
Decreased carotid pulse	1

Initially, the best results seem to be achieved with surgical intervention (Table 5). Patients who underwent revascularization and/or bypass had the highest percentage of normal outcomes (59%) and the lowest morbidity (29%).

Other factors that need to be taken into account in considering outcome are pretreatment neurologic status, shock, head CT scan result, posttreatment patency on angiography, and severity of associated injuries. These factors not only have prognostic significance but also influence treatment and thus play a role in outcome (Table 6).

Pretreatment Neurologic Status and Outcome

Seventy percent (12 of 17) of the patients who had at most only moderate neurologic deficits returned to normal; 18% (3 of 17) had only subtle deficits after treatment.

In the patients who had severe deficits initially (hemiplegia), revascularization seemed to produce the best result. Fifty-six percent of the surgically treated patients

Table 4
Results of investigations

	Number of Patients
Head CT scans	
Normal	20
Infarct	18
Other	5
Doppler	
Decreased flow	2
Dissection	1
Pseudoaneurysm	1
Angiogram	
Dissection	45
Occlusion	43
Pseudoaneurysm	8
Avulsion	1
Multivessel lesions	3
Location on angiogram	
Intracranial	5
Skull base, C-1	7
C-2, C-3	9
Bifurcation	6
Cervical	2
Avulsion at siphon	1

became normal (5 of 9); one died. The anticoagulated patients were left with moderate neurologic deficits in 63% (5 of 8) of cases. The patients treated with supportive care were divided; of 21, six (29%) were normal and seven (33%) were left with moderate neurologic deficits. Comatose patients were left with moderate or worse deficits 74% of the time (20 of 27 patients).

Pretreatment Shock and Outcome

Fourteen patients were in shock at initial examination: four (29%) became normal, four died, and of the remaining six, four were left with a severe neurologic deficit.

Pretreatment CT Scan Result and Outcome

A normal neurologic examination result was the eventual outcome in 33% (6 of 18) of patients whose CT scan initially appeared normal, but only 5% (1 of 20) of those whose initial CT scan showed an infarct eventually had normal results on neurologic examination.

Posttreatment Angiogram Results and Outcome

Over half (12 of 22) of the patients with patent vessels on angiograms became normal as opposed to only 27% (4 of 15) of those with occluded vessels. It is interesting to note that some patients with severe coma, infarctions on their initial CT scans, and occlusions on angiograms posttreatment still had a normal or very good outcome.

TREATMENT AND PREDICTORS OF OUTCOME

Revascularization

Fourteen of 24 patients had severe neurologic deficits (grade 4) or were in a coma (grade 5) before treatment.

Table 5
Outcome of different treatments

Treatment	Number of Patients	Outcome by Grade					
		1	2	3	4	5	6
Revascularization	24	14 (58)	1 (4)	5 (21)		1 (4)	3 (13)
Bypass	3	2 (67)			1 (33)		
Occlusion	3		1 (33)				2 (67)
Anticoagulation & surgery	6	3 (50)	1 (17)	2 (33)			
Anticoagulation	28	10 (36)	2 (7)	8 (29)	2 (7)	4 (14)	2 (7)
Anti-platelet	3	2 (67)	1 (33)				
Support	33	11 (30)	5 (15)	8 (24)	2 (6)	2 (6)	5 (15)
Totals	100	42	11	23	5	7	12

The numbers in parentheses are percentages of patients in each category. Outcome is recorded in columns 1 through 6 from best to worst. The grading system is as follows: 1 = normal; 2 = mild neurologic deficit = functional, independent in activities of daily living, e.g., slight dysphasia, cognitive deficit or motor tone; 3 = moderate deficit = improved but has residual cognitive deficit, cranial nerve palsies, or weakness; 4 = severe deficit = evident cognitive dysfunction or hemiparesis preventing function; 5 = comatose; 6 = deceased.

Table 6
Predictors of outcome

	Number of Patients	Outcome by Grade					
		1	2	3	4	5	6
Neurologic status							
1	2	2					
2	7	5	1		1		
3	8	5	2	1			
4	45	17	5	16	1	2	4
5	27	4	3	5	4	4	7
CT scan							
Normal	18	6	3	6			3
Infarct	20	1	7	5	2	2	3
Angiogram							
Patent	22	12	3	6	1		
Occluded	15	4		6	1	2	2
Shock	14	4	1	1	2	2	4

Seven patients survived to become normal (grade 1) or to have mild neurologic deficits (grade 2). Four had moderate deficits, one remained in a coma and two died. Unfortunately the preoperative status of ten patients was unknown.

Three patients had normal preoperative CT scans but none of them returned to normal; two died. Also, two of five patients with patent vessels on postoperative angiograms had moderate neurologic deficits. Seven postoperative angiograms showed occluded vessels and two patients in this group returned to normal function (Table 7).

Anticoagulation and Surgical Treatment

Six patients who received anticoagulants and also underwent surgery did particularly well. Four of six became normal or had mild residual deficits despite poor preoperative grades and infarcts apparent on CT scans. Four of six angiograms showed vessel patency after treatment (Table 8).

Anticoagulation

Twenty-eight patients were treated with anticoagulation. Eight of 11 patients who initially were in grades 1,

Table 7
Outcome with revascularization

	Number of Patients	Outcome by Grade				
		1	2	3	5	6
Preoperative grade						
4	9	5 (56)	1 (11)	2 (22)		1 (11)
5	5	1 (20)		2 (40)	1 (20)	1 (20)
NM	10	8 (80)		1 (10)		1 (10)
Preoperative CT						
Normal	3		1 (33)			2 (67)
Infarct	3			2 (67)		1 (33)
NM	18					
Postoperative angiogram						
Patent	5	3 (60)		2 (40)		
Occluded	7	2 (29)		2 (29)	1 (14)	2 (29)
NM	12					

NM = not mentioned. Numbers in parentheses are percentages.

Table 8
Outcome with anticoagulation and surgery

	Number of Patients	Outcome by Grade		
		1	2	3
Preoperative neurologic grade				
2	1	1 (100)		
4	4	2 (50)		2 (50)
5	1		1 (100)	
Preoperative CT				
Normal	3	2 (67)		1 (33)
Infarct	3	1 (33)	1 (33)	1 (33)
Shock	1		1 (100)	
Postoperative angiogram				
Patent	4	2 (50)	1 (25)	1 (25)
Occluded	1			1 (100)

Numbers in parentheses are percentages.

2, or 3 became neurologically normal. Seventeen patients were in neurologic grades 4 or 5. Only three became normal or had mild deficits. Seven had moderate deficits and seven had severe deficits or worse. Ten were hypotensive. Six of ten patients who were in shock were left with moderate neurologic deficits or worse. After treat-

ment, five angiograms showed patent vessels although the patients were left with varying degrees of neurologic deficit. Four angiograms showed occlusions and four showed persistent pseudoaneurysms (Table 9).

Supportive Care

The group of 32 patients who received supportive care did surprisingly well given their degree of initial deficits. Thirty of them initially had severe neurologic deficits or coma. Twelve of them became normal or were left with mild deficits; eight had moderate deficits, five died, and the rest remained the same. The two who initially were in grades 1 or 2 became normal. Again, shock is an indicator of bad prognosis; the one patient who was in shock died. Even without anticoagulation seven follow-up angiograms showed patent vessels (Table 10).

Aspirin, Bypass, Occlusion

There were very few patients treated with aspirin, bypass, or occlusion. Three patients with moderate to severe deficits were treated with aspirin and became normal or had mild residual deficits.

Three patients were treated with bypass. One who initially was in grade 3 became normal although the follow-up angiogram showed an occluded vessel and the other patient initially in a coma improved but had severe deficits.

Three patients were treated with carotid occlusion. Two had subdural hematomas and shock and later died. The other patient with moderate neurologic deficits and an infarct on CT scan initially was left with mild deficits.

DISCUSSION

Management of internal carotid artery trauma is challenging. It is an uncommon entity that can easily be

missed on initial examination. The reasons for this are that it is unsuspected, there are few if any external signs, it is often masked by more obvious injuries, its manifestations are attributed to head injury, there is often a delay in signs, and the results of the initial head CT are often normal. Early diagnosis and immediate treatment with anticoagulation alone or with surgery improve the chances of good outcome.

Early diagnosis can only be achieved by suspecting the injury and following the patient with repeated neurologic examinations. By the time lateralizing signs appear, infarction may already have occurred. Thus one must always keep in mind the causes and mechanisms of blunt carotid injury and intervene before infarction takes place.

The pathogenesis of injury is traction on the carotid, followed by a tear in the intima or media, platelet aggregation, and thrombus formation with subsequent embolization causing cerebral ischemia.

Five often quoted mechanisms of vessel wall damage³²⁻³⁴ are (1) hyperextension^{15,24,26} with compression of the artery against the transverse processes of the cervical spine; (2) hyperflexion, with compression of the artery between the mandible and the spine; (3) direct blows^{4,14,20,21,25}; (4) intraoral trauma¹⁵; and (5) basal skull fracture causing tearing of the intracranial portion of the carotid artery.¹⁹ Any movement or trauma that distracts or compresses the artery can create injury. In the 100 cases we reviewed, two injuries were caused by strangulation. Previous reports have suggested shoulder safety belt injuries^{7,8,28} or mandible fractures⁵ as causal forces. Some think that dissection could be caused by traction of the hypoglossal nerve against the carotid.²⁹

Seven of the 100 cases could be explained by sudden deceleration causing compression of the carotid by the safety belt. Five cases were associated with mandible fractures. One of our seven cases may have been caused

Table 9
Outcome with anticoagulation

	Number of Patients	Outcome by Grade					
		1	2	3	4	5	6
Pretreatment neurologic grade							
1	1	1 (100)					
2	5	3 (60)	1 (20)		1 (20)		
3	5	4 (80)		1 (20)			
4	8	1 (13)	1 (13)	5 (63)		1 (13)	
5	9	1 (11)		2 (22)	2 (22)	2 (22)	2 (22)
Pretreatment CT							
Normal	3	1 (33)	1 (33)	1 (33)			
Infarct	3		1 (33)	2 (67)			
Shock	10	4 (40)		1 (10)	2 (20)	2 (20)	1 (10)
Posttreatment angiogram							
Patent	5	1 (10)	1 (10)	2 (20)	1 (10)		
Occluded	4	1 (25)		1 (25)	1 (25)	1 (25)	
Persistent PA	4	2 (50)	1 (25)	1 (25)			
Improved	2	2 (100)					
No change	1	1 (100)					

Numbers in parentheses are percentages.

Table 10
Outcome with supportive care

	Number of Patients	Outcome by Grade					
		1	2	3	4	5	6
Pretreatment neurologic grade							
1	1	1 (100)					
2	1	1 (100)					
4	21	6 (29)	3 (14)	7 (33)	1 (5)	1 (5)	3 (15)
5	9	2 (22)	2 (22)	1 (11)	1 (11)	1 (11)	2 (22)
Pretreatment CT							
Normal	7	1 (14)	1 (14)	4 (57)			1 (14)
Infarct	7		2 (29)		1 (14)	1 (14)	3 (43)
Shock	1						1 (100)
Posttreatment angiogram							
Patent	7	5 (71)	1 (14)	1 (14)			
Occluded	2			2 (100)			

Numbers in parentheses are percentages.

by a safety belt compressing the carotid while two were related to hyperextension.

Blunt carotid trauma should be suspected in young patients who have a sudden unexplained change in mental status or who demonstrate neurologic deficit after trauma. This is especially true if they have a change in the carotid pulse, a bruit, an external bruise on the neck or along the course of the shoulder safety belt, and normal results on CT scan of the head. A complete neurologic examination should be done to rule out any lateralizing findings such as dysphasia, visual field cut, facial droop, pronator drift, neglect, weakness, or asymmetric reflexes.

If a patient has an accident in which blunt carotid trauma is a possibility, normal CT scan results, and an unexplained change in mental status, Doppler ultrasound studies may be a useful screening modality. If the Doppler ultrasound study produces negative results the patient can be followed with serial neurologic examinations. The four reported Doppler ultrasound studies in the 100 cases all produced positive results.^{14,15,18,26} The role of MR-angiography is still not defined but it may be a valuable diagnostic aid if angiography is contraindicated. Angiography is the gold standard and should be done if the patient has any ipsilateral external signs of neck injury on physical examination associated with a change in the level of consciousness or lateralizing neurologic findings unexplained by CT scanning.

Individual institution experience with blunt carotid trauma is limited. Some authors³⁵⁻³⁷ suggest aggressive surgical treatment of these lesions because of the previously reported¹⁶ figures of death or severe neurologic impairment in 86% of cases in the nonsurgical group compared with 53% in the surgical group. Other more recent authors believe that conservative management produces good results.^{1,10,11,33,34,38} Our small series and literature review support initial nonsurgical treatment. Revascularization might be considered for cases of progressive neurologic deficit.

Once the diagnosis is radiographically confirmed, the

first line of treatment is anticoagulation to prevent thrombi and emboli in the asymptomatic or minimally symptomatic patient. Our literature review suggests that patients with good neurologic grades have a good outcome without surgical treatment. Eight of 11 anticoagulated and 2 of 2 supportively treated patients in grades 1 to 3 became normal or had slight residual neurologic deficits. Eight of ten surgically treated patients became normal but we did not know their preoperative deficits. Furthermore, 9 of 18 postoperative angiograms showed occluded vessels and three of these patients returned to normal (three were functional and three died). Three patients treated with either bypass or occlusion had occluded vessels on follow-up angiograms but normal results on neurologic examination. Others with patent vessels were not neurologically intact at follow-up suggesting that carotid revascularization was not solely the determinant of good outcome. In addition the surgical mortality was greater than that associated with nonsurgical care. Fabian makes a good point that patients with bilateral carotid lesions who are anticoagulated do not go on to develop symptoms on the opposite side.¹⁰

On initial review, it appears that patients who had severe neurologic deficits at initial examination seem to fare better with surgical management. Seven of 14 surgically treated, 3 of 17 anticoagulated, and 12 of 30 supportively treated patients became normal or had mild residual deficits. These numbers by themselves are misleading, however, since ten in the anticoagulated group were hypotensive. Thus one must keep in mind when examining the numbers that treatment and outcome were influenced by the patients' other injuries and by the individual's collateral circulation. For these reasons it is difficult to produce a management algorithm or to envision a truly valid randomized prospective study about management of carotid dissection. Our recommendation for this group of patients is to use the neurologic examination, the head CT, the angiogram, and the severity of associated injuries as guides to treatment. Stable results on neurologic examinations, no infarction on CT

scans, good collateral circulation (shown with cross compression during angiography), no shock, all encourage nonsurgical treatment. Revascularization and postoperative anticoagulation may be considered for patients with progressive neurologic deterioration and poor collateral circulation if anticoagulation alone fails. The postoperative anticoagulation helps prevent thrombus or embolus formation from the suture line. This strategy may include those who may have high cervical lesions to which access is difficult.

The patient who is in a coma with advanced infarction on CT scans does not seem to improve with surgery because infarction has already occurred and there is risk of hemorrhage from reperfusion. Nevertheless some of these patients have excellent recovery with anticoagulation and supportive care because of good autoregulation, good collateral circulation, and deficits that may be from cerebral edema and mass effect instead of infarction.

CONCLUSION

Blunt carotid trauma, although rare, is increasing in incidence. The overall mortality (12%), and morbidity (46%), are improved from previous reports and may be attributed to a higher index of suspicion for the lesion, greater use of CT scanning, faster transport from the time of injury to treatment, better supportive care, microsurgical techniques, and better monitoring. The most important determinant of good outcome is early diagnosis from an awareness of the causes and mechanisms of blunt carotid trauma. Doppler ultrasound studies can be used as a screening tool, but the gold standard is still angiography. We suggest anticoagulation as the primary treatment. It is difficult to recommend surgery. The review of cases from our institution as well as those in the literature show that conservative management provides good results in patients with little initial deficit. The neurologic examination results, the delay in diagnosis, the initial CT scan results, the adequacy of collateral circulation, and the associated injuries guide the treatment in patients with poorer grades of neurologic function. More research needs to be done to evaluate the differences in outcome between those patients treated surgically and those treated with anticoagulation alone. Unanswered questions include whether surgical treatment would spare the patient the long convalescence and the subtler cognitive deficits that limit a higher degree of function that are seen with anticoagulation. From this study it is hard to justify a generally surgical strategy; we support trends toward anticoagulation.

REFERENCES

- Davis J, Holbrook T, Hoyt D, et al: Blunt carotid artery dissection: Incidence, associated injuries, screening, and treatment. *J Trauma* 30:1514, 1990
- Yamada S, Kindt G, Youmans J: Carotid artery occlusion due to nonpenetrating injury. *J Trauma* 7:333, 1967
- Krajewski L, Hertzner N: Blunt carotid artery trauma: Report of two cases and review of the literature. *Ann Surg* 191:341, 1980
- An TL: Case report: Fatal thrombosis of internal carotid artery following minor blunt trauma to the neck. *J Forensic Sci* 34:699, 1989
- Atkinson TJ, Anavi Y, Gornish M: Internal carotid artery thrombosis after blunt maxillofacial trauma. *Oral Surg Oral Med Oral Pathol* 72:408, 1991
- Ballard JL, Bunt TJ, Fitzpatrick B: Bilateral traumatic internal carotid artery dissections: case report. *J Vasc Surg* 15:431, 1992
- Benito M, Garcia F, Fernandez-Quero, et al: Lesion of the internal carotid caused by a car safety belt. *J Trauma* 30:116, 1990
- Chedid M, Deeb Z, Rothfus W, et al: Major cerebral vessels injury caused by seatbelt shoulder strap: Case report. *J Trauma* 29:1601, 1989
- Englund R, Harris JP, May J: Blunt trauma to the internal carotid artery. *Ann Vasc Surg* 2:362, 1988
- Fabian T, George S, Croce M, et al: Carotid artery trauma: Management based on mechanism of injury. *J Trauma* 30:953, 1990
- Fakhry SM, Jaques PF, Proctor HJ: Cervical vessel injury after blunt trauma. *J Vasc Surg* 8:501, 1988
- Fukuda I, Megaru K, Matsusita S, et al: Traumatic disruption of bilateral vertebral arteries and internal carotid arteries: Case report. *J Trauma* 29:263, 1989
- Kallero K, Bjorck C, Bergqvist D: Carotid artery injury caused by blunt cervical trauma. *Acta Chir Scand* 153:155, 1987
- Maiuri F, Gallichio B, Corriero G: Extracranial internal carotid artery aneurysm. *Acta Neurol (Napoli)* 9:372, 1987
- Martin RF, Eldrup-Jorgensen J, Clark D: Blunt carotid trauma to the carotid arteries. *J Vasc Surg* 14:789, 1991
- McNab A, Fabinyi G, Milne P: Blunt trauma to the carotid artery. *Aust NZ J Surg* 58:651, 1988
- Mears G, Leonard R: Blunt carotid artery trauma: a case report. *J Emerg Med* 6:281, 1988
- Mooney R, Bessen H: Delayed hemiparesis following nonpenetrating carotid artery trauma. *Am J Emerg Med* 4:341, 1988
- Morgan M, Besser M, Johnston I, et al: Intracranial carotid artery injury in closed head trauma. *J Neurosurg* 66:192, 1987
- Moses BH, Tolson MA, Boyd CR: Fifteen year review of extracranial carotid injury. *J Med Assoc Ga* 76:129, 1987
- Pozzati E, Giuliani G, Poppi M: Blunt traumatic carotid dissection with delayed symptoms. *Stroke* 20:412, 1989
- Price DB, Vernose G, Jabourian Z: Thrombosis of the carotid artery following blunt trauma. *Trans PA Acad Ophthalmol Otolaryngol* 41:880, 1989
- Sharma S, Rajani M, Mishra N: Extracranial carotid artery aneurysm following accidental injury: ten years experience. *Clin Radiol* 43:162, 1991
- Sherlock DJ, Nightingale S, Gardecki T, et al: Case report: Squash injury to the internal carotid artery. *Eur J Vasc Surg* 1:285, 1987
- Steimle R, Jacquet G, Godard J, et al: Traumatismes fermes des arteres carotides et vertebrales extra-craniennes; a propos de 11 cas. *Chirurgie* 113:130, 1987
- Stonebridge PA, Clason AE, Jenkins AM: Traumatic aneurysm of the extracranial carotid artery due to hyperextension of the neck. *Eur J Vasc Surg* 4:423, 1990
- Ueda T, Kikuchi H, Karasawa J, et al: Traumatic stenosis of the internal carotid artery in children. *Surg Neurol* 26:368, 1986
- Weimann S, Ruml E, Flora G: Carotid occlusion caused by seat belt trauma. *Eur J Vasc Surg* 2:193, 1988
- Wozasek G, Balzer K: Strangulation of the internal carotid artery by the hypoglossal nerve. *J Trauma* 30:332, 1990
- Mokri B, Piepgras D, Houser W: Traumatic dissection of the extracranial internal carotid artery. *J Neurosurg* 68:189, 1988
- Welling R, Saul T, Tew J, et al: Management of blunt injury to the internal carotid artery. *J Trauma* 27:1221, 1987
- Fleming J, Petrie D: Traumatic thrombosis of the internal carotid artery with delayed hemiplegia. *Can J Surg* 11:166, 1968
- Stringer W, Kelly D: Traumatic dissection of the extracranial carotid artery. *Neurosurgery* 6:123, 1980
- Zelenock G, Kazmers A, Whitehouse W, et al: Extracranial internal carotid artery dissections. *Arch Surg* 117:425, 1982
- Batzdorf U, Bentson J, Machleder H: Blunt trauma to the cervical carotid artery. *Neurosurgery* 5:195, 1979
- Pellegrini R, Manzetti GW, DiMarco RF: The direct surgical management of lesions of the high carotid artery. *J Cardiovasc Surg* 25:20, 1984
- Sundt T, Pearson B, Piepgras D, et al: Surgical management of aneurysms of the distal extracranial internal carotid artery. *J Neurosurg* 64:169, 1986
- Richardson J, Simpson C, Miller F: Management of carotid artery trauma. *Surgery* 104:673, 1988