

## Ischemic stroke in congenital (type II C) defective antithrombin III

Ida Martinelli, Marco Moia, Arnaldo Arbini, Armando Tripodi, and Pier Mannuccio Mannucci

Angelo Bianchi Bonomi Hemophilia and Thrombosis Center, Institute of Internal Medicine, University and IRCCS Maggiore Hospital, Milan, Italy

**Summary.** Type II C is a subtype of defective antithrombin III deficiency in which there is a molecular defect in the heparin binding site. Usually, heterozygous patients with this defect have little or no thrombotic symptoms. Ischemic stroke has never been described. We report the case of a young woman who had an episode of right-sided hemiparesis. The computed tomographic scan showed an ischemic lesion in the left hemisphere. There were no previous thrombotic episodes in the patient's history and the sole risk factor for thrombosis was taking of an oral contraceptive. Her family history was mildly positive for thrombosis (superficial thrombophlebitis in two relatives). Laboratory tests showed normal antithrombin III antigen, low heparin cofactor activity and an increased slow-moving peak in crossed-immunoelectrophoresis with heparin. The same pattern was found in 7 of 20 relatives. Thus, a diagnosis of congenital type II C defective antithrombin III was made. This report suggests that young patients with ischemic stroke should be screened for defective antithrombin III.

**Key words:** Cerebral ischemia – Antithrombin III – Oral contraceptives

### Introduction

Antithrombin III (AT III) is the major protein that inhibits the serine proteases of the intrinsic and common pathways of blood coagulation, mainly thrombin and activated factor X [1]. Congenital AT III deficiency, inherited as an autosomal dominant trait, predisposes to venous thromboembolism. Its relation to arterial thrombosis is not clearly established [1]. Two main phenotypes of congenital AT III defects have been recognized [14]: type I, in which there are concomitantly low levels of AT III activity and antigen; and type II, in which low

levels of AT III activity contrast with normal levels of AT III antigen. Type II is further subdivided into three phenotypes. One of these, type II C, consists of mutations of DNA encoding the protein domain responsible for binding heparin and heparin-like substances, which markedly accelerate inactivation of serine proteases [2].

Type II C leads to peculiar clinical features, being characterized by a much lower frequency of venous thromboembolic complications than in the other types of AT III defects in the heterozygous state [3]. That the type II C defect is less severe is also indicated by the fact that homozygotes with moderately severe clinical symptoms have been described, whereas homozygosity for other AT III defects has not been reported, probably because it is incompatible with life. There is no clear explanation for the fact that the type II C AT III defect is less severe, although it is surmised that the integrity of the AT III domain responsible for inactivation of coagulation enzymes minimizes the importance of the defect in acceleration by heparin-like substances.

We describe the case of a young woman with heterozygous type II C AT III defect who developed an ischemic stroke. Stroke, and arterial thromboses in general, are rare in congenital AT III deficiency [6], and have not been reported for heterozygous type II C.

### Case report

On 23 March 1991 a previously healthy 34-year-old woman suddenly developed headache and paresthesia of her right side. Neurological examination revealed right-sided hemiparesis and right homonymous hemianopsia. Approximately 3 h after the onset of symptoms, a computed tomographic (CT) scan was normal. On day 2, two low-density areas became apparent: one about 2.5 cm in the left parieto-occipital hemisphere and a smaller one at the level of the left thalamus (Fig. 1). Left carotid and vertebral angiography performed on day 12 showed no significant abnormality. Chest X-ray, electrocardiogram and echocardiography were normal.

Correspondence to: P. M. Mannucci, A. Bianchi Bonomi Hemophilia and Thrombosis Center, Via Pace, 9, I-20122 Milan, Italy

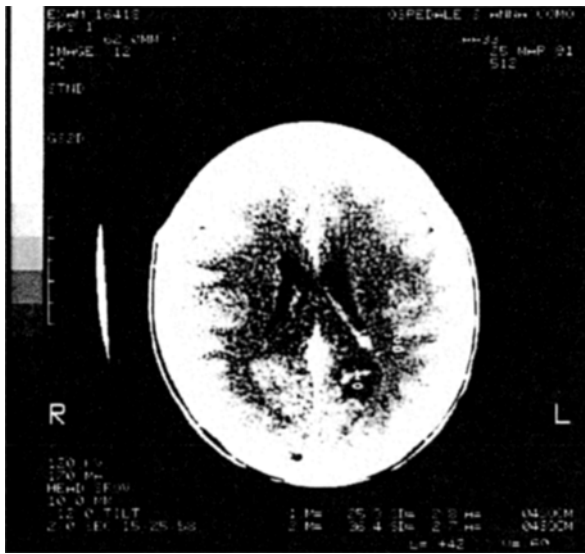


Fig. 1. Computed tomographic scan shows two low-density areas, one in the left parieto-occipital hemisphere and one in the left thalamus

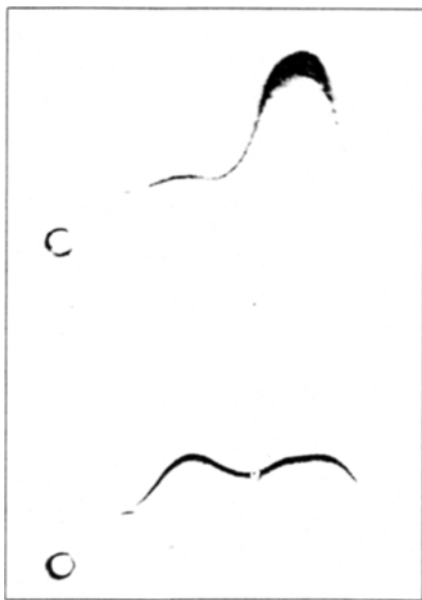


Fig. 2. Crossed-immunoelectrophoresis with heparin (25 IU/ml) of normal plasma (upper panel) and patient plasma (lower panel). Cathode is on the left

In the patient's clinical history there were three operations under general anesthesia and two pregnancies without mishaps; there had been no prophylaxis against thrombosis. She did not smoke and had neither arterial hypertension nor diabetes or dyslipidemia. Oral contraceptives (triphasic pill: levonorgestrel 0.05, 0.075, 0.125 mg; ethinyloestradiol 0.03, 0.04, 0.03 mg), taken for 4 years until the day of the episode, were the only possible risk factor for thrombosis. The family history was mildly positive for thrombosis: her mother and maternal aunt had had recurrent superficial thrombophlebitis.

Table 1. Antithrombin III (AT III) in the propositus and her family members

Generation	Relation to propositus	Heparin cofactor activity (%)	Progressive AT III activity (%)	AT III antigen concentration (%)
I	Father	89	—	83
	Mother	65	103	98
	Maternal uncle	101	—	—
	Maternal aunt	110	—	—
	Maternal uncle	65	—	98
	Maternal aunt	59	—	102
II	Propositus	62	94	107
	Brother	98	—	108
	Sister	90	—	90
	Sister	63	—	108
	Maternal cousin	98	—	100
	Maternal cousin	93	—	100
	Maternal cousin	64	—	107
	Maternal cousin	100	—	—
	Maternal cousin	89	—	—
	Maternal cousin	96	—	—
	Maternal cousin	96	—	—
	Maternal cousin	59	—	118
Maternal cousin	71	—	113	
III	Son	100	—	95
	Daughter	98	—	106
Normal laboratory range		80–120	80–120	80–120

During hospitalization the patient was treated with subcutaneous heparin followed by aspirin; her condition gradually improved and on 9 April she was discharged, presenting only paresthesia of her right side and right temporal hemianopsia. These symptoms still persist, 1 year after the stroke. A CT scan performed 9 weeks after the event confirmed the presence of the two low-density areas in the left hemisphere.

The patient was referred to the Hemophilia and Thrombosis Center 4 months after the stroke. A laboratory examination gave normal values for hemocytometry, liver and renal function; there was no evidence of immunological diseases. Coagulation tests, including prothrombin time, activated partial thromboplastin time, thrombin time, fibrinogen, factor VII, protein C and protein S (both determined by immunological and functional methods), were within the normal range. The heparin cofactor activity of AT III, which measures the capacity of heparin to accelerate the inactivation of thrombin [12], was low (62% of normal); progressive AT III activity, which measures the capacity to inactivate thrombin with no heparin added [12], was normal (94% of normal) and AT III antigen, which is a measure of the total immunological protein concentration [10], was also normal (107%). The crossed-immunoelectrophoresis [15] pattern was normal in the absence of heparin, but showed an abnormal slow-moving peak in the presence of heparin, indicating that the molecule had poor heparin-binding capacity (Fig. 2). This pattern of results is consistent with a diagnosis of congenital type II C AT III defect. Data from the propositus and all the family members studied

are shown in Table 1. The same abnormalities were present in 7 of 20 relatives.

## Discussion

Whether low AT III activity is a predisposing factor for cerebral arterial thrombosis is still controversial. Only six cases of ischemic stroke associated with familial AT III defects have been previously reported. Of these, four patients had type II C AT III defects: three were homozygotes [4, 13, 16], whereas the status of the fourth patient could not be precisely established because she was an orphan and childless [7]. The other two patients had type II A [5] and type I [8] AT III defects, characterized by defective thrombin inactivation but normal heparin cofactor activity.

This is the first case of ischemic stroke as the sole thrombotic episode in a young woman heterozygotic for type II C AT III defect. The case is peculiar, not only because arterial thrombosis is rare in congenital AT III defects, but also because thrombosis is infrequent in type II C defect. In our patient, oral contraceptives could have played a causal role, as several studies have demonstrated an association between oral contraceptive intake and stroke occurring at a young age [9].

In conclusion, this report suggests that young patients with ischemic stroke as the sole thrombotic symptom should be screened for AT III defect and strengthens a previous suggestion [11] that the measurement of heparin cofactor activity is the method of choice for screening thrombophilic patients, since immunological assays might miss qualitative defects.

## References

1. Beresford CH, Antithrombin III deficiency. *Blood Rev* 2:239, 1988
2. Cooper DN, The molecular genetics of familial venous thrombosis. *Blood Rev* 5:55, 1991
3. Finazzi G, Caccia R, Barbui T, Different prevalence of thromboembolism in the subtypes of congenital antithrombin III deficiency: review of 404 cases. *Thromb Haemost* 58:1094, 1987
4. Fischer AM, Cornu I, Sternberg C, Meriane F, Dautzenberg MD, Chafa O, Beguin S, Desnos M, Antithrombin III Alger: a new homozygous AT III variant. *Thromb Haemost* 55:218, 1986
5. Girolami A, Marafioti F, Rubertelli M, Vicarioto MA, Cappelato G, Mazzucato M, Antithrombin III Trento: a "new" congenital AT III abnormality with a peculiar crossed-immunoelectrophoretic pattern in the absence of heparin. *Acta Haematol (Basel)* 72:73, 1984
6. Hart RG, Kanter MC, Haematologic disorders and ischemic stroke: a selective review. *Stroke* 21:1111, 1990
7. Imamura T, Yoshida T, Yamadori A, Matsuo T, Congenital antithrombin III abnormality and cerebral arterial thrombosis. *Stroke* 92:1090, 1991
8. Johnson EJ, Prentice CRM, Parapia LA, Premature arterial disease associated with familial antithrombin III deficiency. *Thromb Haemost* 63:13, 1990
9. Longstreth WT, Swanson PD, Oral contraceptives and stroke. *Stroke* 15:747, 1984
10. Mancini G, Carbonara AO, Heremans JF, Immunochemical quantitation of antigens by single radial immunodiffusion. *Immunochemistry* 2:235, 1965
11. Mannucci PM, Tripodi A, Laboratory screening of inherited thrombotic syndromes. *Thromb Haemost* 57:247, 1987
12. Odegard OR, Lie M, Abilgaard U, Heparin cofactor activity measured with an amidolytic method. *Thromb Res* 6:287, 1975
13. Sakuragawa N, Takahashi K, Kondo S, Koide T, Antithrombin III Toyama: a hereditary abnormal antithrombin III of a patient with recurrent thrombophlebitis. *Thromb Res* 31:305, 1983
14. Sas G, Hereditary antithrombin III deficiency: biochemical aspects. *Haematologica (Pavia)* 17:81, 1984
15. Sas G, Pepper DS, Cash JD, Plasma and serum antithrombin III: differentiation by crossed immunoelectrophoresis. *Thromb Res* 6:87, 1975
16. Ueyama H, Hashimoto Y, Uchino M, Sasaki Y, Uyama E, Okajima K, Araki S, Progressing ischemic stroke in a homozygote with variant antithrombin III. *Stroke* 20:815, 19