

References

- Back, E., Voiculescu, I., Brunger, M., Wolff, G. (1989) 'Familial ring (20) chromosomal mosaicism.' *Human Genetics*, **83**, 148-154.
- Borgaonkar, D. S., Lacassie, Y. E., Stoll, C. (1976) 'Usefulness of chromosome catalog in delineating new syndromes.' *Birth Defects*, **12**, 87-95.
- Callen, D. F., Eyre, H. J., Ringenbergs, M. L., Freemantle, C. J., Woodroffe, P., Haan, E. A. (1991) 'Chromosomal origin of small ring chromosomes in man: characterization by molecular genetics.' *American Journal of Human Genetics*, **48**, 769-782.
- Fueta, Y., Mita, T., Matsuoka, S. (1987) 'Susceptibility of chimera mice to epileptic convulsion.' *Sangyo Ika Daigaku Zasshi*, **9**, 1-7.
- Gardiner, R. M. (1990) 'Genes and epilepsy.' *Journal of Medical Genetics*, **27**, 537-544.
- Gilman, S. (1992) 'Advances in neurology.' *New England Journal of Medicine*, **326**, 1671-1676.
- Kosztolanyi, G., Mehes, K., Hook, E. B. (1991) 'Inherited ring chromosomes: an analysis of published cases.' *Human Genetics*, **87**, 320-324.
- Lehesjoki, A.-E., Koskiniemi, M., Sistonen, P., Miao, J., Hästbacka, J., Norio, R., de la Chapelle, A. (1991) 'Localization of a gene for progressive myoclonus epilepsy to chromosome 21q22.' *Proceedings of the National Academy of Sciences, USA*, **88**, 3696-3699.
- Leppert, M., Andersson, V. E., Quattlebaum, T., Stauffer, D., O'Connell, P., Nakamura, Y., Lalouel, J.-M., White, R. (1989) 'Benign familial neonatal convulsions linked to genetic markers on chromosome 20.' *Nature*, **337**, 647-648.
- Schinzl, A. (1984) *Catalogue of Unbalanced Chromosome Aberration in Man*. Berlin/New York: de Gruyter, p. 675.
- Wilson, M. G., Towner, J. W., Coffin, G. S. (1981) 'Genetic and clinical studies in 13 patients with the Wolf-Hirschhorn syndrome.' *Human Genetics*, **59**, 297-307.

Acquired Stuttering after a Second Stroke in a Two-year-old

Ruth Nass
Bea Schreter
Linda Heier

Stuttering is a disorder which affects the rhythms of speech, so that the speaker is unable to articulate what he or she wants to because of an involuntary and repetitive prolongation or cessation of a sound (according to the International Classification of Diseases, World Health Organization 1977). Some degree of dysfluency is common as language skills evolve during the preschool years, particularly as mean length of utterance reaches six to eight words between the ages of three and four years. Unlike developmental dysfluencies, however, stuttering may be a rule-governed psycholinguistic disorder (Wall and Meyers 1985, Aram *et al.* 1990). Stuttering occurs at linguistically significant points in an utterance (Goldman-Eisler 1968, Silverman 1972, Gordon *et al.* 1986). It is seen more

frequently in children with developmental disorders of speech and language (Bloodstein 1974, Hall 1977, Blood and Seider 1981, Merits-Patterson and Reed 1981, Nippold 1990). There is a genetic predisposition (Kidd *et al.* 1981) which, as in dyslexia for example (Galaburda *et al.* 1985), could reflect subtle underlying neuropathology. The cause of developmental stuttering is unknown. Anomalous dominance and/or abnormalities of interhemispheric connections are among the main theories. As with the aphasias, extrapolation about the neuro-anatomical basis of developmental childhood stuttering may be possible from the acquired disorder.

Acquired stuttering from brain injury is relatively uncommon in adults and has rarely been reported in children (Aram *et al.* 1990, Meyers *et al.* 1990), possibly because the distinction between developmental stuttering and normal developmental dysfluencies can be a difficult one. We report a 27-month-old girl with a transient acquired stutter occurring in association with a presumed second central nervous system insult.

Case report

At one year of age this previously healthy child, with a vocabulary of a few words, developed a dense right hemiparesis without apparent aphasia in association with an infarction involving the left basal ganglia and extending to the cortex. Despite a thorough

investigation, including angiography, no etiology was found. A mild hemiparesis persisted, and handedness shifted to the left (although there was no family history of sinistrality). At 21 months, when evaluated in a special nursery school by a speech pathologist using the Preschool Language Scale (Zimmerman *et al.* 1979), speech and language were reported to be normal. By 27 months she had a mean length of utterance of four words, but then she developed a marked stutter which affected mainly (but not solely) the initial phoneme of words throughout the sentence, and which lasted for seven weeks. The number of repetitions was much greater than would be seen with a typical developmental dysfluency. No secondary mannerisms were noted. Speech was hypophonic. No aphasia was apparent, and the Preschool Language Scale was again age-appropriate. The stutter was noted by her nursery-school teachers and considered serious enough for her to be referred for speech therapy. The speech pathologist at the nursery school noted that blocking was excessively long for a typical developmental dysfluency. According to her mother, the stutter started and stopped rather abruptly. One week after the stutter ceased, her Bayley Scale score was 113. Her EEG during the period of stuttering was normal. As can be seen in Figures 1 to 3, MRI scans obtained about five weeks into her course revealed the previous infarction and also areas of high signal on the T₂-weighted image in the periventricular white matter bilaterally, consistent with multi-infarction. (The putatively new white matter lesions could conceivably have been missed by the earlier CT scan. However, the clear change in this child's clinical status supports our contention that the white matter pathology was new. A delayed effect of an earlier white matter insult is also possible.) Further investigations, with special emphasis on cardiac (echocardiogram) and hematological (protein S, protein C, antithrombin III) status again revealed no etiology for stroke.

Discussion

This child's susceptibility to stuttering after a second central nervous system insult may be due to anomalous dominance. Rasmussen and Milner's (1977) carotid amygdala data suggest that this child—because of her age, the location of her lesion and current handedness—is highly likely to have become right-hemisphere language-dominant due to the original left-hemisphere stroke. Her new subcortical disease may have interfered with already tenuous interhemispheric connections. Further reorganization could have occurred over several weeks and resulted in the resolution of her stutter. The supposed abruptness of onset and cessation are based entirely on maternal report; her course may actually have been more gradual and physiological, particularly for cessation.

Aram *et al.* (1990) assessed the speech of children with unilateral acquired brain injury for discontinuity (*e.g.* stuttered and non-fluent speech hesitations) and rate (*e.g.* the number of syllables spoken per second of conversational speech). Children with both acquired left- and right-brain injury produced more stuttering-like non-fluencies than controls. Of the five patients with greater than 4 per cent dysfluent speech, three had left- and two had right-sided lesions: but neither the site nor the size of lesion predicted dysfluent speech. However, children with left-sided lesions had a slower speech rate (syllables per second) than controls. Neither lesion group produced a greater number of normal non-fluencies than controls. Only one of the 30 brain-damaged children had a sufficient number of non-fluencies to be classified as having a stutter of mild to moderate severity. This contrasts with the finding of linguistic problems (albeit subtle) in virtually all children with acquired left-hemisphere damage (Aram 1991). Meyers *et al.* (1990) reported the development of stuttering during the course of language recovery eight months after a left-hemisphere, predominantly subcortical, stroke in a child aged seven years.

Aram *et al.* (1990), reporting on the rarity of dysfluency after early-acquired unilateral brain injury, said that it was inconsistent with the view that the neurological basis of developmental stuttering is the lack of dominant-hemisphere control for synchronizing the bilaterally innervated speech mechanisms (Travis 1931, Orton 1937). The rarity of stuttering in the child with acquired injury could, however, be a reflection of aphasia type and/or location of injury. Transient stutter may be masked by the period of overall aphasia-related non-fluency. As with the age versus type of aphasia argument, different types and different locations of pathology in younger versus older patients may have more to do with the kind of aphasia seen (fluent versus non-fluent) than the putative degree of intrahemispheric specialization as related to age (Eslinger and Damasio 1981).

Acquired stuttering in the adult is reported after left, right or bilateral cortical injury (Helm *et al.* 1978,

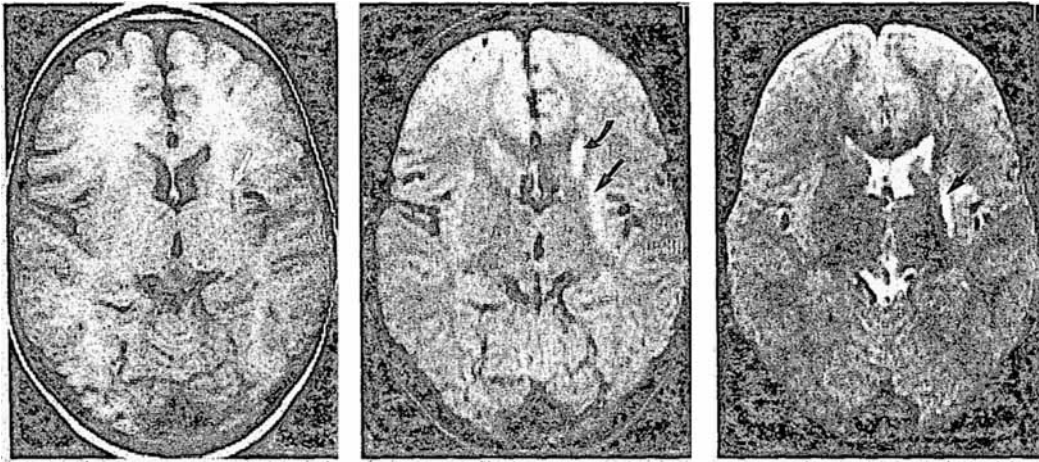


Fig. 1. Axial images through level of basal ganglia. (left) Spin echo (SE) short TR/short TE. (middle) SE long TR/short TE. (right) SE long TR/long TE. A small linear hypo-intensity is detected on short TR image in region of left basal ganglia (arrows). Corresponding hyperintensity is seen on long TR images, as well as hyperintensity involving left caudate. Appearance is consistent with an old stroke.

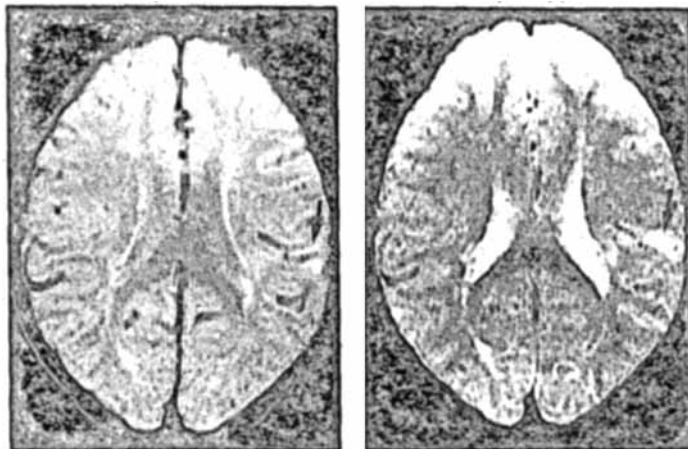


Fig. 2. Axial images at level of body of corpus callosum. (left) SE long TR/short TE. (right) SE long TR/long TE. The long TR images show hyperintensity extending into cortex of left parietal lobe (arrows).

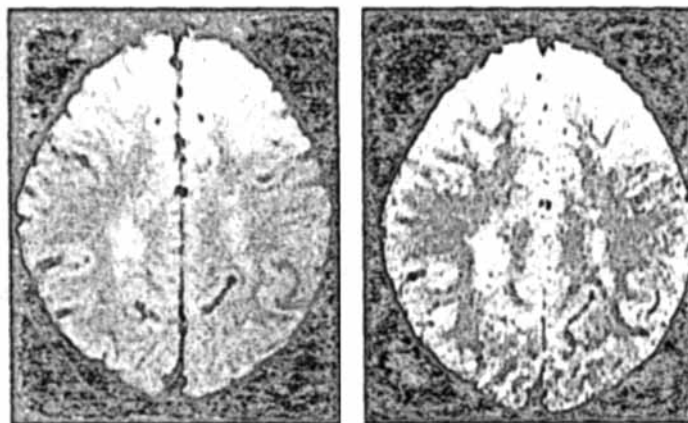


Fig. 3. (left): Spin echo long TR/short TE axial image, demonstrating hyperintensity in white matter of centrum semiovale bilaterally. (right) Corresponding spin echo long TR/long TE image, demonstrating same lesions. They are consistent with ischaemic change in white matter.

Rosenbek *et al.* 1978, Horner and Massey 1983, Fleet and Heilman 1985, Ardila and Lopez 1986, Helm-Estabrook *et al.* 1986, Ludlow *et al.* 1987). Acquired lesions in adulthood have cured stuttering (Jones 1966, Helm-Estabrook *et al.* 1986), as well as rekindled childhood stuttering (Rosenbek *et al.* 1978, Helm-Estabrook *et al.* 1986). Reorganization of language lateralization could underlie acquired stuttering in these instances.

The finding of an increased frequency of left-handedness among people who stutter (Dellatolas *et al.* 1990) also supports the theory that anomalous dominance is a cause of stuttering, because left-handed individuals may have atypical language organization (see Herron 1980 for review). Dichotic listening patterns may be atypical in people who stutter (Andrews *et al.* 1972, Brady and Berson 1972, Rosenfield and Goodglass 1980, Strub *et al.* 1987). Strub *et al.* (1987) reported atypical planum temporale asymmetries in the siblings of such individuals. Atypical planum asymmetries may be more common in left-handed people (LeMay 1981, Witelson 1990, Steinmetz *et al.* 1991). Callosal morphology also differs in left- vs. right-handed people (Witelson 1989) and in those with left- vs. right-hemisphere language dominance (O'Kusey *et al.* 1988), potentially resulting in additive effects of anomalous dominance and atypical interhemispheric connections.

Subcortical pathology both unilateral and bilateral is also reported in acquired stuttering in adults (Helm *et al.* 1978, Rosenbek *et al.* 1978, Horner and Massey 1983, Fleet and Heilman 1985, Ardila and Lopez 1986, Helm-Estabrook *et al.* 1986, Bhatnagar and Andy 1989). Ludlow *et al.* (1987) found that the internal and external capsules, the frontal white matter

and the striatum were more frequently damaged in the group with acquired stuttering than in the other patients with penetrating head injury. In this cohort with penetrating head injury, stuttering did not correlate with cortical pathology of either hemisphere, but with unilateral lesions of the pyramidal or extrapyramidal systems (Ludlow *et al.* 1987).

Documentation of subcortical pathology supports the view that damage to callosal pathways co-ordinating the activity of both hemispheres during speech may underlie stuttering (Soroker *et al.* 1990). Several experimental psychological studies show that people who stutter perform tasks requiring synchronous movements of the two hands anomalously more often than controls (Vaughn and Webster 1989, Webster 1990); this is consistent with the position that faulty interhemispheric communication underlies stuttering.

Our patient's original left-hemisphere insult may have set the stage for transient stuttering associated with the development of new white matter disease. As such, her course provides a clue to the underlying pathophysiology of the individual with a developmental stutter.

Accepted for publication 11th May 1993.

Acknowledgement

The authors thank an anonymous reviewer for his/her useful comments.

Authors' Appointments

*Ruth Nass, M.D., New York University Medical Center, New York.
Bea Shreter, M.A.C.C.C.;
Linda Heier, M.D.;
New York Hospital, Cornell University Medical Center, New York.

*Correspondence to first author at Department of Pediatric Neurology, New York University Medical Center, 400 East 34th Street, New York, NY 10016, USA.

SUMMARY

An almost two-year-old left-handed girl with a history of a left-hemisphere stroke at the age of one year developed a transient stutter with newly acquired white matter infarctions. Her course suggests that developmental stuttering may reflect anomalous dominance and/or atypical interhemispheric connectivity.

RÉSUMÉ

Bégaiement acquis après une seconde attaque chez une fillette de deux ans

Une fillette gauchère de près de deux ans, avec une anamnèse d'une attaque hémiparétique gauche à l'âge d'un an, présente un bégaiement transitoire à l'occasion d'infarctissements nouveaux de la substance blanche. Son évolution suggère qu'un bégaiement de développement peut traduire une dominance anormale et/ou une connectivité interhémisphérique typique.

ZUSAMMENFASSUNG

Erworbenes Stottern nach einem zweiten Schlaganfall bei einer Zweijährigen

Ein fast zweijähriges linkshändiges Mädchen, das im Alter von einem Jahr einen linksseitigen Schlaganfall hatte, entwickelte durch weitere Infarkte im Bereich der weißen Substanz ein vorübergehendes Stottern. Dieser Verlauf zeigt, daß das Stottern in der Entwicklung Ausdruck einer nicht normalen Dominanz und/oder einer atypischen interhemisphärischen Verknüpfung sein kann.

RESUMEN

Tartamudeo adquirido después de un segundo ictus en una niña de dos años de edad

Una niña de casi dos años de edad, zurda, con una historia de un ictus en el hemisferio izquierdo al año de edad, sufrió una tartamudez transitoria después de un nuevo infarto de sustancia blanca. El curso que siguió sugiere que el tartamudeo de desarrollo puede reflejar una dominancia anómala y/o una conexión atípica interhemisférica

References

- Ardila, A., Lopez, M. (1986) 'Severe stuttering associated with right hemisphere disease.' *Brain and Language*, **18**, 17-85.
- Andrews, G., Quinn, P., Sorby, W. (1972) 'Stuttering: an investigation into cerebral dominance for speech.' *Journal of Neurology, Neurosurgery and Psychiatry*, **35**, 414-415.
- Aram, D. (1991) 'Acquired aphasia in children.' In Sarno, M. (Ed.) *Acquired Aphasia, Second Edition*. New York: Academic Press.
- Meyers, S., Ekelman, B. (1990) 'Fluency of conversational speech in children with unilateral brain lesions.' *Brain and Language*, **38**, 105-122.
- Blood, G., Seider, R. (1981) 'The concomitant problems of young stutterers.' *Journal of Speech and Hearing Disorders*, **46**, 31-33.
- Bloodstein, O. (1974) 'The rules of early stuttering.' *Journal of Speech and Hearing Disorders*, **39**, 379-394.
- Bhatnagar, S., Andy, O. (1989) 'Alleviation of acquired stuttering with human centromedian thalamic stimulation.' *Journal of Neurology, Neurosurgery and Psychiatry*, **52**, 1182-1184.
- Brady, J., Berson, J. (1972) 'Stuttering, dichotic listening, and cerebral dominance.' *Archives of General Psychiatry*, **32**, 1449-1452.
- Dellatolas, G., Annesi, I., Jallon, P., Chavance, M., Lellouch, J. (1990) 'An epidemiological reconsideration of the Geschwind-Galaburda hypothesis of cerebral lateralization.' *Archives of Neurology*, **47**, 778-782.
- Eslinger, P., Damasio, A. (1981) 'Age and type of aphasia in patients with stroke.' *Journal of Neurology, Neurosurgery and Psychiatry*, **44**, 377-381.
- Fleet, W., Heilman, K. (1985) 'Acquired stuttering from a right hemisphere lesion in a right hander.' *Neurology*, **35**, 1343-1346.
- Galaburda, A., Sherman, G., Rosen, G. (1985) 'Developmental dyslexia: four consecutive patients with cortical anomalies.' *Annals of Neurology*, **18**, 222-233.
- Goldman-Eisler, F. (1968) *Psycholinguistics: Experiments in Spontaneous Speech*. New York: Academic Press.
- Gordon, P., Luper, H., Peterson, H. (1986) 'The effects of syntactic complexity on the occurrence of dysfluencies in 5 year old non-stutterer.' *Journal of Fluency Disorders*, **11**, 151-155.
- Hall, P. (1977) 'The occurrence of dysfluencies in language disordered school age children.' *Journal of Speech and Hearing Disorders*, **42**, 364-369.
- Helm, N., Butler, R., Benson, D. F. (1978) 'Acquired stuttering.' *Neurology*, **28**, 1159-1165.
- Helm-Estabrook, N., Teo, R., Geschwind, N., Freeman, M., Weinstein, C. (1986) 'Stuttering: disappearance and reappearance with acquired brain lesion.' *Neurology*, **36**, 1109-1112.
- Herron, J. (1980) *Neuropsychology of Left Handers*. New York: Academic Press.
- Horner, J., Massey, E. (1983) 'Progressive dysfluency associated with right hemisphere lesion.' *Brain and Language*, **18**, 71-85.
- Jones, R. (1966) 'Observations on stammering after localized cerebral injury.' *Journal of Neurology, Neurosurgery and Psychiatry*, **29**, 142-145.
- Kidd, K., Heimbuch, R., Records, M. (1981) 'Vertical transmission of susceptibility to stuttering with sex modified expression.' *Proceedings of the National Academy of Sciences*, **78**, 606-610.
- LeMay, M. (1981) 'Are there radiological changes in the brains of individuals with dyslexia?' *Annals of Dyslexia*, **31**, 135-141.
- Ludlow, C., Rosenberg, J., Salazar, A., Grafman, J., Smutok, M. (1987) 'Site of penetrating brain lesions causing chronic acquired stuttering.' *Annals of Neurology*, **22**, 60-66.
- Merits-Patterson, R., Reed, J. (1981) 'Dysfluencies in the speech of language delayed children.' *Journal of Speech and Hearing Research*, **24**, 55-58.
- Meyers, S. E., Hall, N. E., Aram, D. M. (1990) 'Fluency and language recovery in a child with a left hemisphere lesion.' *Journal of Fluency Disorders*, **15**, 159-174.
- Nippold, M. (1990) 'Concomitant speech and language disorders in stuttering children.' *Journal of Speech and Hearing Disorders*, **55**, 51-60.
- O'Kusky, J. (1988) 'The corpus callosum is larger with right hemisphere cerebral speech dominance.' *Annals of Neurology*, **24**, 379-383.
- Orton, S. (1937) *Reading, Writing and Speech Problems in Children*. London: Chapman & Hall.
- Rasmussen, T., Milner, B. (1977) 'The role of early left brain injury in determining lateralization of cerebral speech functions.' In Diamond, S., Blizard, D. (Eds.) *Evolution and Lateralization of the Brain*. New York: New York Academy of Sciences.
- Rosenbek, J., Messert, B., Collins, M., Wertz, R. (1978) 'Stuttering following brain damage.' *Brain and Language*, **6**, 82-96.
- Rosenfield, D., Goodglass, H. (1980) 'Dichotic testing of cerebral dominance in stutterers.' *Brain and Language*, **11**, 170-180.
- Silverman, E. (1972) 'Preschoolers' speech dysfluency.' *Perceptual and Motor Skills*, **35**, 1002-1005.
- Soroker, N., Bar-Israel, Y., Schechter, I., Solzi, P. (1990) 'Stuttering as a manifestation of right subcortical stroke.' *European Neurology*, **30**, 268-270.
- Steinmetz, H., Volkman, J., Jancke, L., Freund, H. (1991) 'Anatomic left-right asymmetry of language-related cortex is different in left and right handers.' *Annals of Neurology*, **29**, 315-320.
- Strub, R., Black, F., Naeser, M. (1987) 'Anomalous dominance in sibling stutterers: evidence from CT scan asymmetries, dichotic listening, neuro-

- psychological testing and handedness.' *Brain and Language*, 30, 338-350.
- Travis, L. (1931) *Speech Pathology*. New York: Appleton.
- Vaughn, C., Webster, W. (1989) 'Bimanual handedness in adults who stutter.' *Perceptual and Motor Skills*, 68, 375-382.
- Wall, M., Meyers, F. (1985) *Clinical Management of Childhood Stuttering*. Baltimore, MD: University Park Press.
- Webster, W. (1990) 'Evidence in bimanual finger tapping of an attentional component to stuttering.' *Behavioral and Brain Research*, 37, 93-100.
- Witelson, S. (1989) 'Hand and sex differences in the isthmus and genu of the corpus callosum.' *Brain*, 112, 799-835.
- (1990) 'Neuroanatomic asymmetries: a review.' In F. Boller, F. (Ed.) *Handbook of Neuropsychology*. New York: Raven Press.
- World Health Organization (1977) *Manual of the International Statistical Classification of Diseases, Injuries and Causes of Death*. Geneva: WHO, p. 202.
- Zimmerman, I., Steiner, V., Pond, R. (1979) *Preschool Language Scale*. San Antonio, TX: Psychological Corp.

The Spasmodic Upper-body Squeeze: a Characteristic Behavior in Smith-Magenis Syndrome

Brenda M. Finucane
Deborah Konar
Barbara Haas-Givler
Michael B. Kurtz
Charles I. Scott, Jr.

The advent of high-resolution cytogenetic analysis has allowed the delineation of small interstitial chromosome deletions which formerly went unrecognized. Since the first report of an interstitial deletion of 17p11·2 in 1982, a specific behavioral and physical phenotype has emerged as the Smith-Magenis syndrome (SMS) (Smith *et al.* 1986, Greenberg *et al.* 1991). Characteristic physical features include brachycephaly (83 per cent), midface hypoplasia (94 per cent), ear malformations (68 per cent) and brachydactyly (81 per cent). Mental impairment is generally moderate. Behaviorally, these patients often pose severe management problems due to aggressive and self-mutilatory symptoms (70 per cent). Greenberg

et al. (1991) described onychotillomania (pulling out of fingernails and toenails) and polyembolokoilomania (insertion of foreign objects into various bodily orifices). Head-banging and hand-biting, along with severe sleep disturbance (51 per cent), are other common findings (Colley *et al.* 1990, Greenberg *et al.* 1991).

Over a two-year period, we have identified 11 patients with deletion 17p11·2 through the genetics service at an educational and vocational center for people with mental retardation. Ascertainment of people with SMS was based on a survey at our facility of current and former clients with severe self-injurious and aggressive behaviors, and/or characteristic physical findings. On diagnosis, it became evident that several patients with SMS manifested an unusual hand- or arm-clasping behavior, particularly as an expression of happiness or excitement. Years before their diagnosis, teachers at our center had referred four of these patients for genetic evaluation based on their behavioral similarities, particularly with regard to 'self-hugging'. No specific diagnosis had been reached at that time. When one of the self-hugging children was subsequently diagnosed with SMS, the other three were re-evaluated and also found to have deletion 17p11·2.

Patients

Of 11 patients with SMS, seven were female and four were male; they were aged between seven and 51 (mean 24). All patients had deletion 17p11·2 documented in peripheral blood and/or skin fibroblasts. No patient had a seizure