

Management of a Giant Middle Cerebral Artery Fusiform Serpentine Aneurysm with Distal Clip Application and Retrograde Thrombosis: Case Report and Review of the Literature

Michael Bruce Horowitz, M.D., Howard Yonas, M.D., Charles Jungreis, M.D.,
and T.K. Hung, Ph.D.

Department of Neurosurgery, Department of Radiology, Department of Engineering, University of Pittsburgh Medical Center, Presbyterian University Hospital, Pittsburgh, Pennsylvania

Horowitz MB, Yonas H, Jungreis C, Hung TK. Management of a giant middle cerebral artery fusiform serpentine aneurysm with distal clip application and retrograde thrombosis—case report and review of the literature. *Surg Neurol* 1994;41:221–5.

Giant fusiform aneurysms are rare vascular anomalies that due to their size are often difficult to manage. We describe one such aneurysm that was managed with a superficial temporal to middle cerebral artery bypass followed by the application of a single clip just distal to the vascular dilation. Follow-up angiography has shown aneurysm obliteration by the process of retrograde thrombosis.

KEY WORDS: Giant fusiform aneurysm

Intracranial aneurysms with a diameter greater than or equal to 2.5 cm are defined as giant [19]. The reported incidence of such aneurysms in large series varies from 3% to 13% [19,20,32]. Many authors divide giant aneurysms into two categories, saccular and fusiform, based upon the anomaly's angiographic and operative appearance. One interesting variant of the fusiform aneurysm is the giant middle cerebral artery serpentine aneurysm. We report a case of one such aneurysm managed by superficial temporal artery (STA) to middle cerebral artery (MCA) bypass followed by immediate application of a single clip distal to the fusiform dilation. This technique led to aneurysm occlusion through a mechanism of retrograde thrombosis.

Case Report

An otherwise healthy 19-year-old man suffered a new onset complex-generalized seizure. After recovery from

his postictal state, the patient was noted to have a normal neurologic exam. Evaluation by computed tomography (CT) (General Electric 9800, Milwaukee, Wisconsin) revealed a large, left frontotemporal, mixed density mass representing a 6-cm diameter giant, mostly thrombosed MCA aneurysm. Angiography confirmed the diagnosis. The giant fusiform aneurysm appeared to represent a gross dilation of a branch vessel arising from the horizontal MCA. A serpentine vascular channel within the aneurysm was surrounded by a large volume of thrombus. Superselective angiography of the aneurysm demonstrated a single vessel entering and exiting the vascular dilation with very delayed distal perfusion of territory normally supplied by the anterior MCA division (operculo-frontal territory) (Figure 1). Instillation of 40 mg of sodium amytal into the aneurysm led to the immediate development of an expressive dysphasia consisting primarily of paraphasias and word finding difficulties. This dysphasia resolved within 10 minutes. Cerebral magnetic resonance imaging (MRI) (General Electric Signa, 1.5T, Milwaukee, Wisconsin) obtained as a baseline study demonstrated the giant aneurysm containing both chronic and acute thrombus. A flow void within the mass was consistent with the serpentine vascular channel demonstrated by angiography (Figure 2).

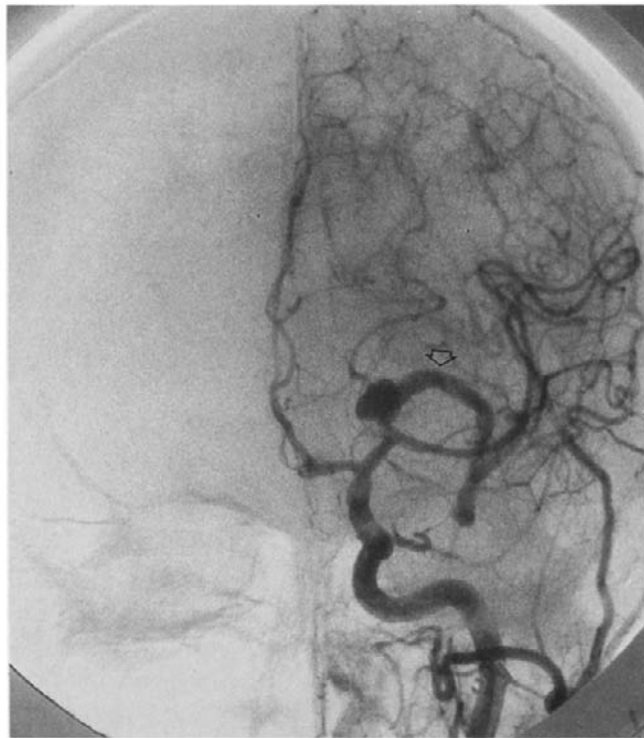Operative Procedure

Because the distal vessel perfused critical regions in this otherwise normal individual, plans were made for a STA–MCA bypass followed by an obliteration of the vascular anomaly.

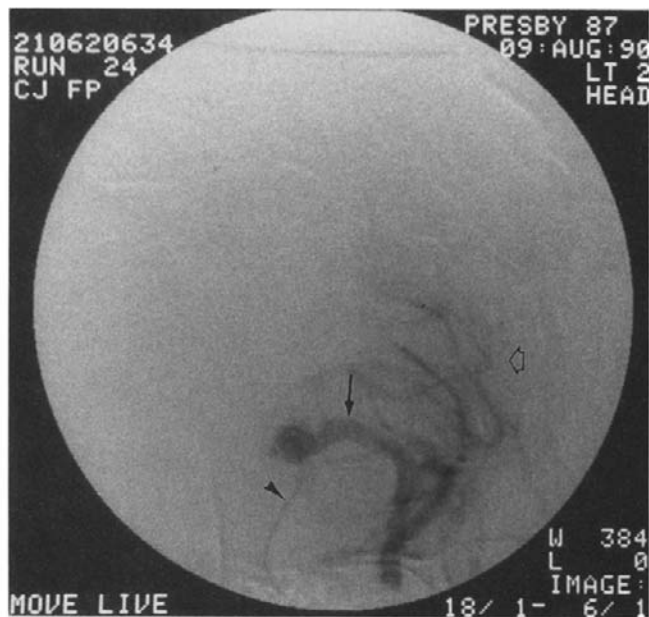
At surgery the giant aneurysm was visible near the surface of the Sylvian fissure. The fissure was divided distally exposing the MCA branch exiting the aneurysm. An end-to-side STA–M3 anastomosis was then completed. After the bypass, the aneurysm was dissected further. It soon became evident that exposure of the

Address reprint requests to: Michael Bruce Horowitz, M.D., 9402 Presbyterian University Hospital, 230 Lothrop Street, Pittsburgh, PA 15213.

Received May 18, 1993; accepted June 7, 1993.



A



B

Figure 1. (A) Left ICA angiogram displaying the serpentine vascular channel (arrow) traversing the left MCA branch giant aneurysm and filling anterior sylvian branches. (B) Microcatheter (arrowhead) with selective catheterization of the aneurysmal channel shows to better advantage the serpentine channel (arrow) and distal MCA branches filling from it (open arrow).

proximal aspect of the aneurysm would require significant dominant temporal and frontal lobe retraction. With the knowledge that this fusiform anterior MCA branch had no side branches arising from its dilated segment,

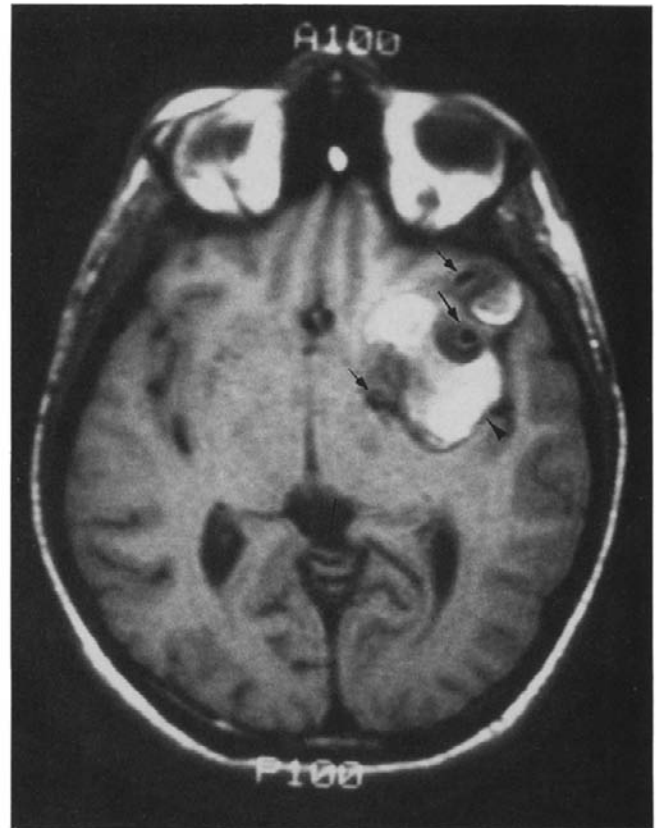

Figure 2. MRI (TR600/TE20; GE Signa, 1.5T) showing a portion of the left MCA aneurysm. Axial images of the serpiginous lumen containing flowing blood can be seen (arrows) surrounded by thrombus (arrowhead).

a clip was placed across the parent vessel just distal to the dilation and proximal to the STA-MCA anastomosis (Figures 3 and 4). If a postoperative angiogram showed an absence of thrombosis, presumably due to continued runoff through an unappreciated branch arising from the aneurysm wall, we were prepared to trap the aneurysm proximally using an endovascularly placed detachable balloon.

Postoperative Course

Aneurysm thrombosis and patency of the STA-MCA bypass was confirmed by angiography, MRI, and CT scanning. A 1-mm residual portion of the most proximal aneurysm lumen continued to opacify 1 week after surgery, however, this was not felt to pose an additional significant risk of hemorrhage. The patient was discharged 7 days after surgery with no neurologic deficits. Follow-up angiography 18 months later showed the aneurysm remained thrombosed and the bypass remained patent (Figure 4A,B).

Discussion

Incidence and Presentation

Depending on the series, the reported incidence of giant intracranial aneurysms is 3% to 13% [19,20,32]. Fe-

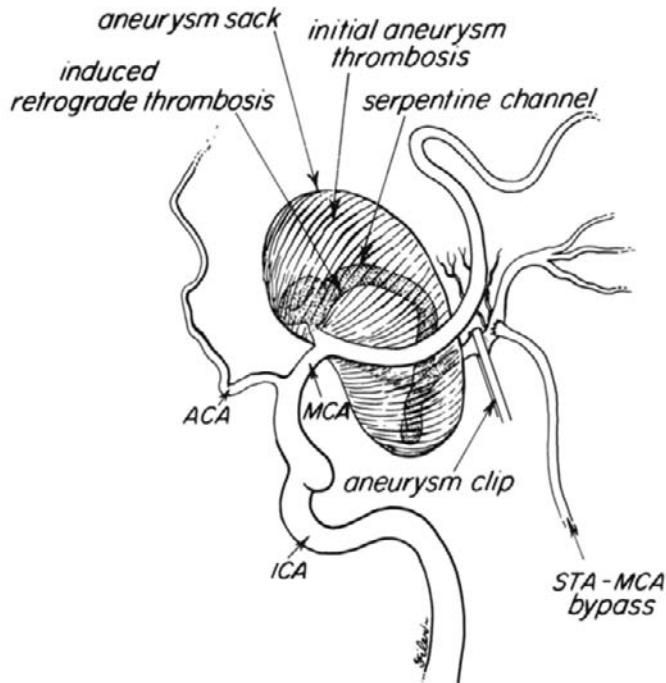
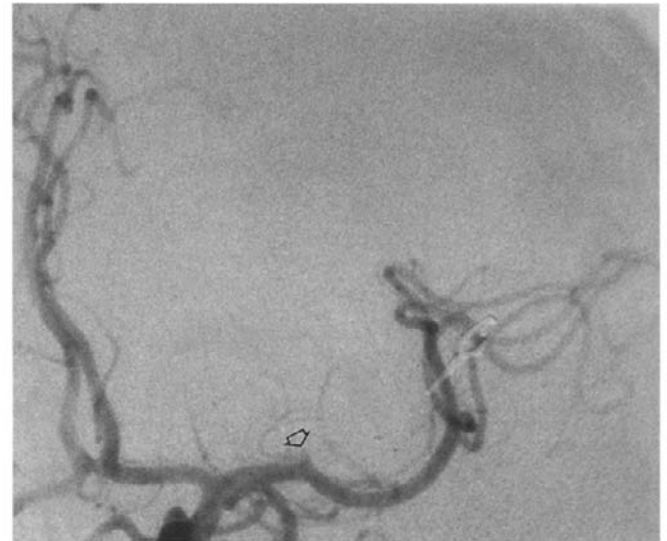


Figure 3. Diagram illustrating the clip position and the resultant retrograde thrombosis.

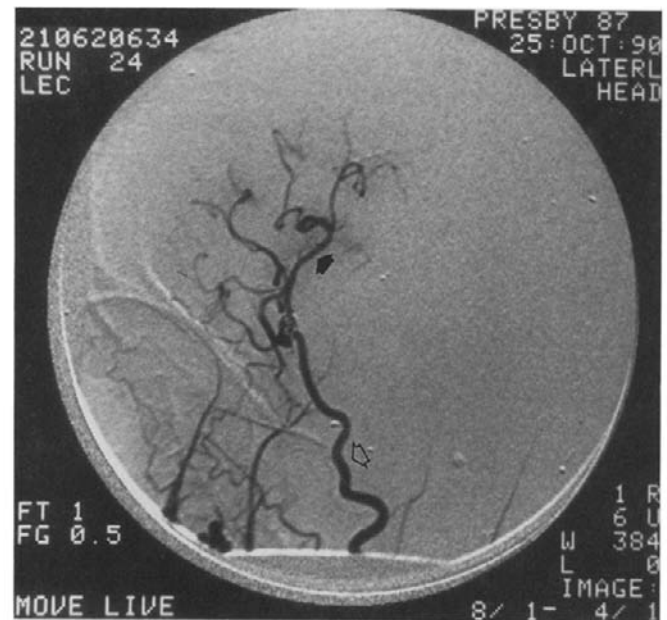
males outnumber females 3 : 1. Peak age for occurrence is 30 to 60 years [14]. The most common form of presentation is secondary to the aneurysm's mass effect. Symptoms include pituitary and hypothalamic impairment, seizures, hemiparesis, visual disturbance, chronic headache, cerebrospinal fluid rhinorrhea, and altered mental status [14,19]. A number of authors believe giant aneurysms rarely rupture and have attributed this to the protective, thick, laminated clot lining the interior wall [15,22]. Others have taken exception to this and report hemorrhage rates of 30% to 81% [7,14,19,20,30]. The impression that giant aneurysms present infrequently with subarachnoid hemorrhage (SAH) may be because they often present with symptoms of mass effect and are brought to the clinician's attention before they bleed [20].

Giant Serpentine Fusiform Aneurysms

Although giant aneurysms are most commonly located along the internal carotid artery (ICA) [20,25,30,32], the subgroup identified as giant serpentine fusiform aneurysms are more commonly located along the MCA [5,9,21,35]. The term "fusiform" applies to lesions in which the dilation is elongated and involves the total circumference of the arterial wall [29]. The CT appearance of such lesions is that of a round or oval, mixed density mass. Post-contrast studies show intense homogeneous enhancement of the regions representing the patent vascular channel within the aneurysm. Peripheral



A



B

Figure 4. (A) Left ICA angiogram 18 months after surgery. The aneurysm is thrombosed. A proximal 1-mm portion of the original channel can be seen (arrow); (B) Left lateral external carotid artery angiogram demonstrates patent STA-MCA bypass (open arrow) with rapid filling of the anterior MCA territory (arrow).

enhancement of the mass' outer margin is characteristic [21]. The presence of two separate layers of enhancement separated by a hypodense region has been called the target sign and indicates there is enhancement of the wall and the lumen with interposed thrombus [21]. Angiography of giant serpentine aneurysms reveals unusually delayed opacification of the tortuous intra-aneurysmal channel [9,17,21].

Histopathologically, fusiform aneurysms have 1- to 4-mm thick fibrous tissue walls often rich in small blood

vessels [9,21]. This vasculature is responsible for the peripheral enhancement seen on angiography. The vessels from which fusiform aneurysms arise do not contain focal defects in the medial layer and internal elastic lamina as do saccular aneurysms [25,29]. Rather, inflammatory lesions of the arterial wall and degenerative connective tissue disorders seem to predispose to their formation [29]. Enlargement seems to be a consequence of arterial pulsations against a weakened vessel wall [2]. These histopathologic findings may explain why fusiform aneurysms are more commonly located at sites other than arterial bifurcations [25,35]. The explanation for the predominance along the MCA remains speculative [9].

Management

The goal for management of intracranial aneurysms is exclusion of the vascular lesion from the native circulation. This may be achieved by directly clipping the aneurysm neck, excising the aneurysm and repairing the parent vessel, sacrificing the parent vessel, trapping the aneurysm distally and proximally both with and without a distal revascularization procedure, and placing material inside the aneurysm to promote its thrombosis [1,2,4,6-14,20,23,25,32,34].

The preoperative plan for the case presented here was to perform a STA-MCA bypass followed by trapping of the fusiform anterior MCA aneurysm using distal clip and proximal balloon or clip occlusion. The Amytal test results indicated that the territory supplied by the diseased vessel was critical for speech. This test, however, did not elucidate the quality of collateral flow to this region. In our experience the preferred way to accurately demonstrate the effects of occluding a vessel that supplies a particular vascular territory is by utilizing selective balloon occlusion followed by clinical examination and blood flow studies [16]. In this particular case, however, there was no normal proximal vessel in which to place the balloon for the vessel at its bifurcation was aneurysmally dilated. Testing the effect of occluding blood flow through the involved vessel would have required inflating a balloon in the proximal aneurysm. This maneuver was fraught with the potential risk of aneurysm rupture or thrombus dislodgement and distal embolization. Balloon occlusion of the ipsilateral internal carotid artery would have provided information concerning collateral flow through the anterior and posterior communicating arteries, but would not have given specific information regarding the adequacy of more distal collaterals. It is these collaterals that would come into play after occlusion of the diseased vessel. Because preoperative adequate evaluation of collateral blood flow was dangerous, we felt an STA-MCA bypass was prudent prior to aneu-

rysm manipulation. The use of EC-IC bypass in similar situations has been espoused by other authors [2,4,10,12,14,20,27,34,37]. Nevertheless, its performance does not guarantee safe interruption of any intracranial vessel [23].

After completion of the bypass and partial dissection of the aneurysm, it became apparent that proximal ligation of the aneurysmal vessel would not be achieved without extensive dominant frontal and temporal lobe retraction. The decision was made, therefore, to clip the vessel just distal to its dilation thus interrupting outflow and allowing for retrograde thrombosis. This approach at first seems contraindicated for one might think that with the outflow occluded the aneurysm would be more prone to rupture because of increased intraluminal pressure.

An examination of the Bernoulli equation suggests that such distal fusiform aneurysm occlusion is a reasonably safe undertaking. The Bernoulli equation:

$$\frac{1}{2}(DV_a^2) + P_a + DGZ_a = \frac{1}{2}(DV_b^2) + P_b + DGZ_b + DGH_L + (DL\gamma v)/(\gamma t)$$

is applicable to determine the pressure variation between two sections (*a* and *b*) within an artery. V_a and V_b are the velocity at these two sections, P_a and P_b the corresponding pressures, Z_a and Z_b the elevations, D represents the density of blood, G the gravitational acceleration, and DGH_L the energy loss from sections *a* to *b*. The last term in the equation represents the effect of pulsating flow on the changes in pressure from sections *a* to *b*. For a patient in the near prone position Z_a equals Z_b . Since the clip is applied at the distal end of the cerebral aneurysm, the velocity in the aneurysm (V_b) becomes insignificant in comparison with that at section *a* (V_a). In fact, the secondary flow or vortices in the aneurysm can be considered as a stagnant region. Thus one can neglect $\frac{1}{2}(DV_b^2)$ and DGH_L in estimating the pressure at section *b*. Therefore, the equation reduces to $\frac{1}{2}(DV_a^2) + P_a = P_b$. If velocity V_a is equal to 60 cm/s (normal minimal mean velocity), P_b will be higher than P_a by 1800 dynes/cm² which is about 0.15 mm Hg. The increase in intraluminal pressure from distal outflow occlusion will be no greater than 0.6 mm Hg when V_a is as high as 120 cm/s. This magnitude of pressure in the aneurysm is less than the normal variations with daily activity and should pose no significant increased risk to aneurysm rupture while achieving stagnation of flow and associated clot formation within the aneurysm.

Conclusion

This study demonstrates that some giant MCA serpentine aneurysms may be safely and successfully managed

by STA-MCA bypass followed by application of a single clip distal to the fusiform dilation.

References

- Alksne FJ, Smith RW. Stereotaxis occlusion of 22 consecutive anterior communicating artery aneurysms. *J Neurosurg* 1980;52:790-3.
- Ammerman BJ, Smith DR. Giant fusiform middle cerebral aneurysm: successful treatment utilizing microvascular bypass. *Surg Neurol* 1977;7:255-7.
- Belec L, Cesaro P, Brugieres P, Gray F. Tumor-simulating giant serpentine aneurysm of the posterior cerebral artery. *Surg Neurol* 1988;29:210-5.
- Bushe KA, Bockhorn J. Extracranial-intracranial arterial bypass for giant aneurysms. *Acta Neurochir* 1980;54:107-15.
- Cantu RC, LeMay M. A large cerebral aneurysm presenting as a bizarre vascular malformation. *Br J Radiol* 1966;39:317-9.
- Cuatico W, Cook AW, Tyshchenko V, Khatib R. Massive enlargement of intracranial aneurysms following carotid ligation. *Arch Neurol* 1967;17:609-13.
- Drake CG. Ligation of the vertebral (unilateral or bilateral) or basilar artery in the treatment of large intracranial aneurysms. *J Neurosurg* 1975;43:255-74.
- Ecker A, Riemenshneider P. Deliberate thrombosis of intracranial arterial aneurysm by partial occlusion of the carotid artery with arteriographic control. *J Neurosurg* 1951;8:348-53.
- Fodstad H, Liliequist B, Wirell S, Nilsson PE, Boquist L, Abdul-Rahman A. Giant serpentine intracranial aneurysm after carotid ligation. *J Neurosurg* 1978;49:903-9.
- Fujii K, Fukui M, Matsubara T, Nagata S, Fujiwara S, Matsushima T, Hasuo K. Microsurgical procedures for management of giant cerebral aneurysm causing increased intracranial pressure. *Surg Neurol* 1989;32:366-71.
- Fukamachi A, Hirato M, Wakao T, Kawafuchi J. Giant serpentine aneurysm of the posterior cerebral artery. *Neurosurg* 1982;11(2):271-6.
- Gebler BR, Sundt TM. Treatment of intracavernous and giant carotid aneurysms by combined internal carotid ligation and extra-intracranial bypass. *J Neurosurg* 1980;52:1-10.
- Hodes JE, Aymard A, Gobin YP, Rufenacht D, Bien S, Reizine D, Gaston A, Merland JJ. Endovascular occlusion of intracranial vessels for curative treatment of unclippable aneurysms: report of 16 cases. *J Neurosurg* 1991;75:694-701.
- Hosobuchi Y. Direct surgical treatment of giant intracranial aneurysms. *J Neurosurg* 1979;51:743-56.
- Jain KK. Surgery of intracranial berry aneurysms: a review. *Can J Surg* 1965;8:172-87.
- Linsky ME, Sekhar LM, Horton JA, Hirsch WL, Yonas H. Aneurysms of the intracavernous carotid artery: a multidisciplinary approach to treatment. *J Neurosurg* 1991;75:525-34.
- Lukin RR, Chambers AA, McLaurin R, Tew J. Thrombosed giant middle cerebral aneurysms. *Neuroradiology* 1975;10:125-9.
- Lyall A. Large aneurysm of the circle of Willis with spontaneous cure by thrombosis. *Br Med J* 1936;2:282.
- Morley TP, Barr HWK. Giant intracranial aneurysms: diagnosis, course and management. *Clin Neurosurg* 1969;15:73-94.
- Onuma T, Suzuki J. Surgical treatment of giant intracranial aneurysms. *J Neurosurg* 1979;51:33-36.
- Patel DV, Sherman IC, Hemmati M, Ferguson RJL. Giant serpentine intracranial aneurysms. *Surg Neurol* 1981;16:402-7.
- Sadik R, Budzilovich GN, Shulman K. Giant aneurysm of middle cerebral artery. *J Neurosurg* 1965;22:177-81.
- Samson DS, Neuwelt EA, Beyer CW, Ditmore QM. Failure of extracranial-intracranial arterial bypass in acute middle cerebral artery occlusion: case report. *Neurosurgery* 1980;6(2):185-8.
- Scott RM, Ballantine HT. Spontaneous thrombosis in a giant middle cerebral artery aneurysm. *J Neurosurg* 1972;37:361-3.
- Segal HD, McLaurin RL. Giant serpentine aneurysm. *J Neurosurg* 1977;46:115-20.
- Sekhar LN, Nelson PB. A technique of clipping giant intracranial aneurysms with the preservation of the parent artery. *Surg Neurol* 1983;20:361-8.
- Serbinenko FA, Filaton JM, Spallone A, Tchurilov MV, Lazarey VA. Management of giant intracranial ICA aneurysms with combined extracranial-intracranial anastomosis and endovascular occlusion. *J Neurosurg* 1990;73:57-63.
- Silverberg GD, Reitz BA, Ream AK. Hypothermia and cardiac arrest in the treatment of giant aneurysms of the cerebral circulation and hemangioblastoma of the medulla. *J Neurosurg* 1981;55:337-46.
- Smith RR, Parent AD. End-to-end anastomosis of the anterior cerebral artery after excision of a giant aneurysm. *J Neurosurg* 1982;56:477-580.
- Sonntag VKH, Yuan RH, Stein BM. Giant intracranial aneurysms: a review of 13 cases. *Surg Neurol* 1977;8:81-3.
- Spetzler RF, Schuster H, Roski RA. Elective extracranial-intracranial arterial bypass in the treatment of inoperable giant aneurysms of the internal carotid artery. *J Neurosurg* 1980;53:22-7.
- Sundt TM, Piepgras DG. Surgical approach to giant intracranial aneurysms. *J Neurosurg* 1979;51:731-42.
- Terao H, Muraoka I. Giant aneurysm of the middle cerebral artery containing an important blood channel. *J Neurosurg* 1972;37:352-6.
- Tognetti F, Andreoli A, Testa C. Giant fusiform aneurysm of the middle cerebral artery treated with extracranial-intracranial arterial bypass and drake tourniquet. *Surg Neurol* 1984;22:33-5.
- Tomasello F, Albanense V, Cioffi FA. Giant serpentine aneurysms: a separate entity. *Surg Neurol* 1979;12:429-32.
- Ventureyra ECG, Choo SH, Benott BG. Super giant globoid intracranial aneurysm in an infant. *J Neurosurg* 1980;53:411-6.
- Vlahovitch B, Fuentes JM, Reynaud C, Benbouzid, Mazariegos R. Serie de 17 cas d'aneurysmes geants intra-craniens. Suites chirurgicales eloignees et effets hemodynamiques des occlusions arterielles. *Neurochirurgie* 1985;31:255-63.
- Whittle IR, Dorsch NW, Besser M. Spontaneous thrombosis in giant intracranial aneurysms. *J Neurol Neurosurg Psychiatry* 1982;45:1040-7.