

Case Reports

Weber syndrome caused by intracerebral hemorrhage in a hemophiliac boy

Masashi Mizuguchi, MD, Hirotsugu Kano, MD, Masami Narita, MD, Rou-Fuie Chen, MD
and Fumio Bessho, MD

Department of Pediatrics, Faculty of Medicine, University of Tokyo, Tokyo, Japan

Received 14 June 1993; accepted 23 July 1993

A rare occurrence of the Weber syndrome in childhood is reported. The patient was a 7-year-old hemophiliac with recurrent intracerebral bleeding into the right cerebral peduncle and pontine base. Left hemiparesis involving the face and tongue developed and was later accompanied by right oculomotor nerve palsy.

Key words: Weber syndrome; Childhood; Intracerebral hemorrhage; Hemophilia A

The basal part of the mesencephalon includes the fibers of the oculomotor nerve and corticospinal tracts. Localized lesions in this region produce the Weber syndrome, a combination of contralateral hemiparesis and ipsilateral oculomotor nerve palsy, which is uncommon in childhood. We describe here a 7-year-old boy who developed the syndrome after intracerebral hemorrhage.

CASE REPORT

A boy born in April 1984 was noted to bleed from the lips repeatedly and persistently at the age of 9 months. The family history was negative. The diagnosis of hemophilia A was made at the age of 1 year, based on prolonged activated partial thromboplastin time (85.5 s) and low factor VIII activity (1.6% of normal activity). He developed recurrent hemarthrosis of the right ankle that was treated with transfusion of factor VIII concentrates. He started to complain of headache and vomiting on 3 December 1991, and awkwardness of the left arm on 4 December. History of a previous trauma was denied. At admission on 5 December, left hemipar-

esis involving the face was noted. Blood examination was unremarkable with negative antibody against human immunodeficiency virus. Computerized tomography (CT) and magnetic resonance imaging (MRI) studies demonstrated a fresh hematoma in the right cerebral peduncle (lower midbrain) and pontine base (upper pons). Following admission, transient diplopia developed but disappeared within hours. Replacement of factor VIII was reinforced. After a rapid recovery, he was discharged on 21 December. However, he was readmitted on 5 January 1992 because of another attack of headache, vomiting and left hemiparesis. On admission, he was obtunded but had normal orientation. Paresis of the left extremities, especially the arm, was remarkable with hyperactive deep tendon reflexes and positive Babinski sign. Muscles innervated by left cranial nerves VII, IX, X and XII were also weak. Optic fundi were normal, as well as sensations and autonomic functions. Following admission, he became alert and nausea disappeared, although in February he repeatedly complained of headache, diplopia and/or aggravation of paresis. On examination, ptosis and mydriasis of the right eye were noted. Light reflexes and accommodation were prompt. Movement of the right eye was limited on lateral lower gaze, which caused diplopia. Diplopia of a lesser degree was also noted on right upper gaze. CT and MRI (Fig 1) revealed re-bleeding

Correspondence address: M. Mizuguchi, MD, Department of Pediatrics, Faculty of Medicine, University of Tokyo, 7-3-1 Hongo, Bunkyo-ku, Tokyo 113, Japan. Fax: (81) (3) 3816 4108.

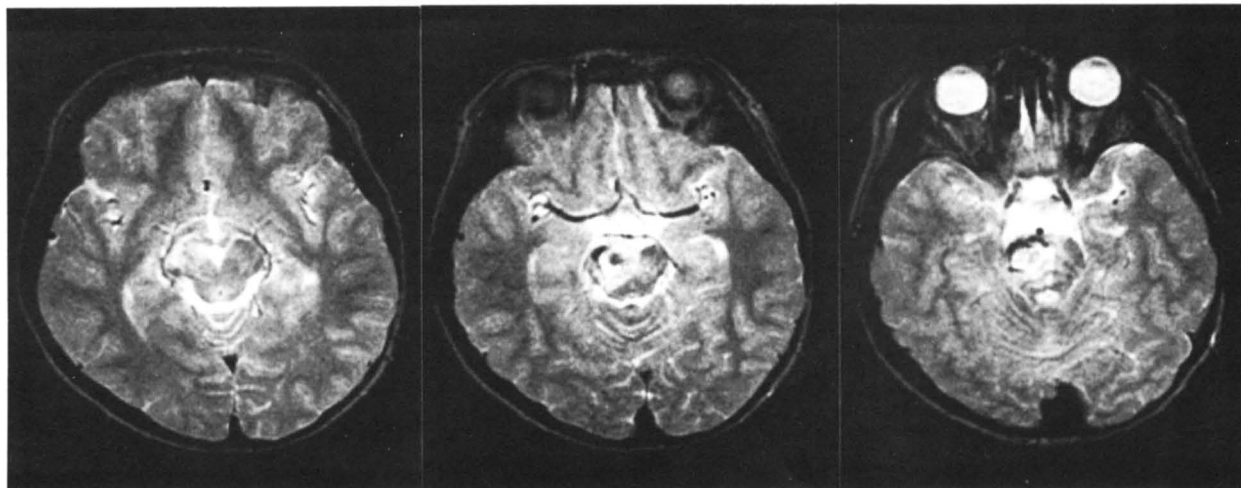


Fig 1. Findings of magnetic resonance imaging on 6 February 1992. T₂-weighted images (1.5 T, spin echo; T_R/T_F: 3,000/90).

in the same region as that of the previous hemorrhage. Administration of factor VIII was further increased. The ocular symptoms disappeared within several months, accompanied by improvement in hemiparesis. Presence of a malformative vascular lesion was suspected but not evidenced by MRI and angiography.

DISCUSSION

The symptomatology of our case is easily explained by the localization of the hematoma. The ocular signs were ascribed to the involvement of the right oculomotor nerve fibers innervating the palpebra levator, the extrinsic (superior and inferior rectus) and intrinsic ocular muscles; the left spastic hemiparesis to that of the right corticospinal fibers; and the paresis of the left lower cranial nerves to that of the right corticonuclear fibers [1]. This combination of signs are compatible with a diagnosis of the Weber syndrome. Although patients with the Weber syndrome occasionally show rigidity and dystaxia of the contralateral side due to the involvement of the substantia nigra and corticopontine fibers [1], our case did not have these signs.

The most common cause of the Weber syndrome is infarction due to thrombosis of the posterior cerebral artery or the interpeduncular branches of posterior choroidal artery [1,2]. Other mechanisms, such as hemorrhage, aneurysm or tumor, are occasionally respon-

sible [1–6]. The syndrome is rarely encountered in pediatric practice; several cases associated with tumors have been reported previously [5,6]. Our report is the first childhood case caused by a cerebrovascular accident. Regardless of the development of CT and MRI, recognition of brainstem syndromes, such as the Weber syndrome, remains valuable in the precise topographic diagnosis of neurologic lesions.

ACKNOWLEDGEMENTS

The authors are grateful to Professor S. Kamoshita (the University of Tokyo) for his advice.

REFERENCES

1. Duus P. *Neurologisch-topische Diagnostik*. Stuttgart: Georg Thieme, 1983.
2. Orgogozo JM, Bogousslavsky J. Lacunar syndromes. In: Toole JF, eds. *Handbook of clinical neurology*, vol 54. Amsterdam: Elsevier, 1989; 235–69.
3. Weber HD. A contribution to the pathology of the crura cerebri. *Med Chir Trans* 1863; **46**: 121–39.
4. Sugita K. Weber syndrome (in Japanese). *Nippon Rinsho (Osaka)* 1982; **40 (Suppl)**: 786–7.
5. Bushe KA, Glees P. *Chirurgie des Gehirns und Rückenmarkes im Kindes- und Jugendalter*. Stuttgart: Hippokrates, 1968.
6. Bucy PC, Keplinger JE. Tumors of the brain stem with special reference to ocular manifestations. *Arch Ophthalmol* 1959; **62**: 541–54.