

Ipsilateral Constructional Apraxia

Donald W. Lewis, MD; Thomas Geller, MD

ABSTRACT

Two boys, aged 7 and 12 years, with nondominant (right) hemispheric acquired vascular lesions and left visual-field disturbances had right spatial constructional disabilities, contralateral to that which would be expected. These unusual disturbances may represent the previously unreported phenomena of ipsilateral neglect or ipsilateral constructional apraxia. (*J Child Neurol* 1994;9:41-44).

Uncommon in childhood, constructional apraxias represent a group of disorders of higher cortical function manifested by disturbances of performance of visual-spatial tasks.¹⁻⁶ Generally attributed to focal disturbances of the nondominant parietal lobe, affected patients have a selective, reproducible inability to attend to the contralateral visual field and inability to perform assembly functions within that contralateral visual space.¹

A variety of tasks have been developed to probe for this disability including stick construction, block arranging, block design, block building, three-dimensional construction apraxias, drawing from model, and drawing from verbal command.⁴ The last is a commonly employed office technique in which the patient is asked to draw a house, person, or clock face. Such tests can elicit striking evidence of lateral neglect, usually in the left visual field.

Two children (aged 7 and 12 years) with nondominant (right) hemispheric vascular lesions and left visual-field disturbances had *right* spatial constructional apraxias. The unusual ipsilateral nature of their disorders of written motor performance may represent the previously unreported phenomena of either ipsilateral constructional apraxia or ipsilateral neglect.

CASE STUDIES

Case 1

A previously healthy 7-year-old right-handed boy presented with left focal clonic status epilepticus in association with a large

inflammatory mass in his right neck adjacent to his right carotid artery. Initial head computed tomographic (CT) scan was normal, and cerebrospinal fluid had 1 white blood cell/mm³, a glucose level of 72 mg/dL, and a protein level of 42 mg/dL. Electroencephalogram (Figure 1) demonstrated periodic lateralizing epileptiform discharges emanating from the right-parietal region. Follow-up head CT scan demonstrated sulcal effacement in the right-parietal region consistent with an infarct in the distribution of the posterior division of the right middle cerebral artery (Figure 2).⁷

Residual deficits included a left hemiparesis (arm greater than leg) and left inferior quadrant visual-field inattention, demonstrated by the extinction of double simultaneous stimulus on the left. Confrontational visual fields were full.

His drawing of a clock face and line bisections is shown in Figure 3. No other visuospatial deficits were elicited. Over a 6-month interval, his visual fields returned to normal and the practical abnormality was no longer demonstrated. Complex partial seizures continued to occur, requiring the administration of chronic antiepileptic medication. A follow-up CT scan was normal.

Case 2

A 13-year-old right-handed boy, whose parents were also right-handed, had suffered a perioperative right-hemispheric infarct-

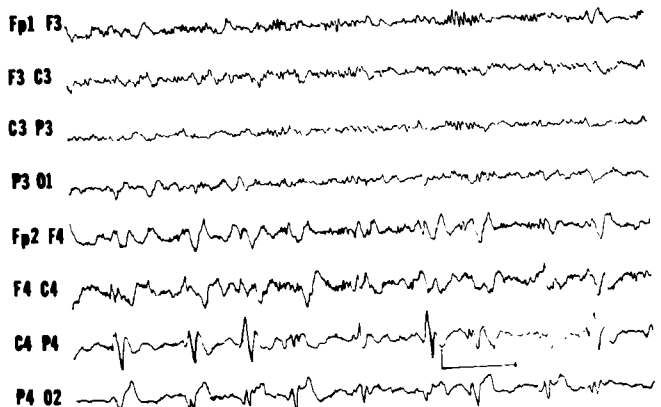


Figure 1. Patient 1. EEG demonstrating paroxysmal lateralizing epileptiform discharges emanating from the right-parietal region. (From Lewis & Tucker.⁷ Reproduced with permission from Pediatrics 1986;77:714.)

Received Oct 9, 1992. Received revised Jan 25, 1993. Accepted for publication Feb 3, 1993.

From the Division of Pediatric Neurology (Dr Lewis), Departments of Pediatrics and Neurology, Naval Hospital, Portsmouth, and the Eastern Virginia Medical School (Dr Geller), Medical College of Hampton Roads, Norfolk, VA.

Presented at the 19th annual Child Neurology Society meeting, Atlanta, GA, Oct 1990.

Address correspondence to Dr D.W. Lewis, Department of Neurology, EVMS, 825 Fairfax Avenue, Norfolk, Virginia, 23507.

The opinions expressed herein are the views of the authors and are not to be construed as official policy of either the US Navy or the Department of Defense.

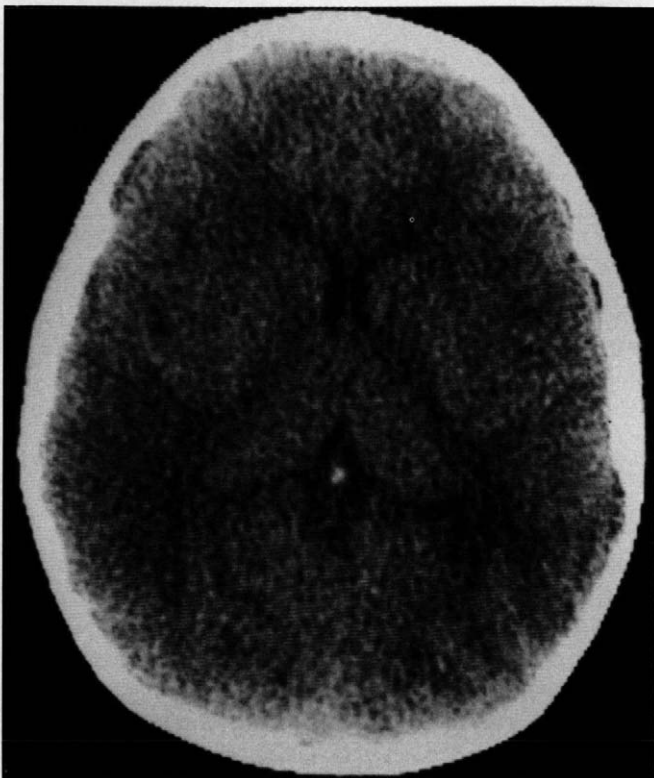


Figure 2. Patient 1. CT scan shows mild sulcal effacement in the right parietal region. (From Lewis & Tucker.⁷ Reproduced with permission from *Pediatrics* 1986;77:714.)

tion at age 6 years during the resection of a low-grade right-hemispheric astrocytoma.

His residual static deficits included a spastic left hemiparesis, complex partial seizures, and a dense left homonymous hemianopsia with macular sparing. CT scan showed extensive right-hemispheric damage (Figure 4). Neither CT nor magnetic resonance imaging (MRI) scan with gadolinium enhancement revealed residual tumor, although there was stable, nonenhancing, high signal (T_2) abnormality at the genu of the corpus callosum, which was thought to be ischemic in origin.

His clock face drawing is shown in Figure 5 and demonstrates a constructional apraxia. His performance on a visual exploratory task, the random letter cancellation test, demonstrates no spatial neglect. Six months later, another clock face drawing showed persistent inattention or practic disturbance in the right superior quadrant (Figure 6).

Educationally, he proved to be a challenge given both his left visual-field deficits and right spatial orientation disturbances.

DISCUSSION

Although controversy exists in the definition and localization of constructional apraxias, a unilateral lesion in either parietal lobe can result in an inability to construct objects in space.¹⁻⁶ When the lesion is in the dominant (left) hemisphere, the visual-spatial disturbance is less severe, and drawings are oversimplified figures and copies of images presented to the patient.¹ When the lesion is in the non-

dominant (right) hemisphere, the patient typically fails to reproduce the spatial relationships and shows a striking neglect for the left half of the space.

Because unilateral spatial neglect and constructional disabilities often coexist in focal brain-damaged patients, the distinction between spatial neglect and spatial practice disturbances becomes a point of debate. Attempts have been made to separate the relative contribution of each in the constructional disabilities of such patients. Villa et al⁸ showed that regardless of faults attributed to unilateral spatial neglect, patients with right-parietal damage had the poorest performance on constructional tasks.

These two children with acquired nondominant (right) hemispheric dysfunction manifest selective inability to draw detail within the right visual space, contralateral to that which would have been expected. Is this ipsilateral disturbance a spatial neglect or a constructional apraxia?

Although uncommon, adults with ipsilateral inattention to stimuli have been described.⁹⁻¹⁵ Ipsilateral neglect as an ictal phenomenon and ipsilateral tactile extinction have been reported.^{9,10} Additionally, ipsilateral inattention to left visual-field stimuli as a consequence of left hemispheric insult has been recorded.¹¹⁻¹⁵ To our knowledge, interictal ipsilateral hemispatial neglect or apraxia due to right-parietal insult have not been previously reported.

These two children did not demonstrate neglect on random number cancellation tests, nor did their line

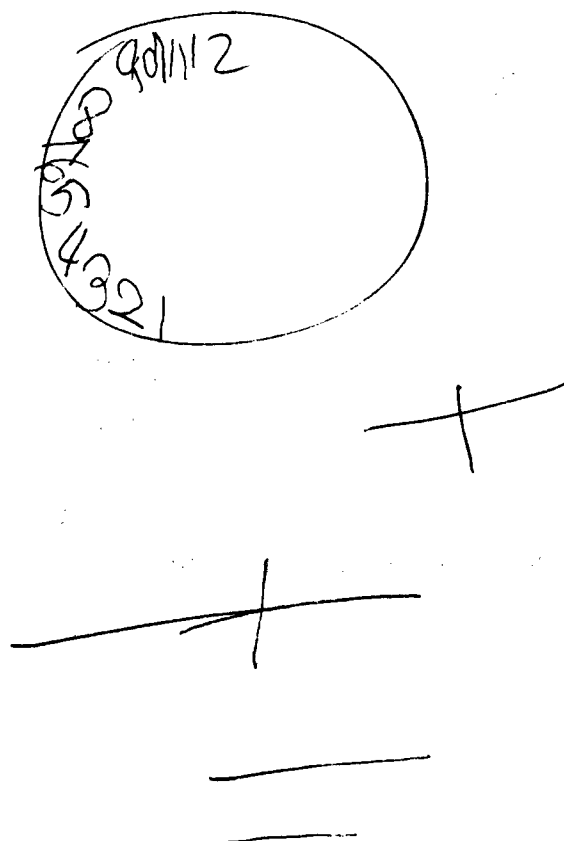


Figure 3. Clock face drawing with line bisections for patient 1.

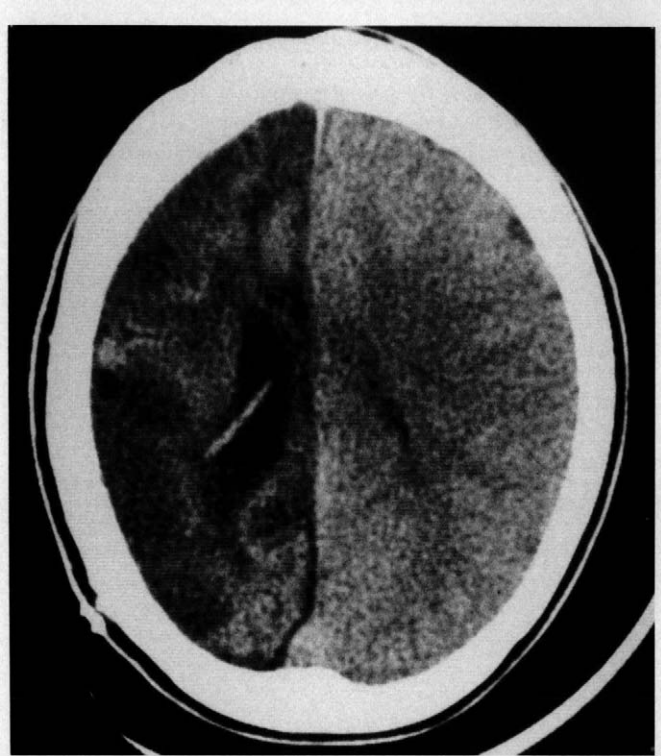


Figure 4. CT scan for patient 2 demonstrating extensive encephalomalacia of the right hemisphere after his infarct.

bisections show spatial disturbances. Because they had no other demonstrable practic disturbances, their drawings may simply be anomalous clock faces. Idiosyncratic ways of drawing clock faces have prompted many to abandon their use as part of mental status examinations, but the striking laterality of these two drawings is difficult to dismiss.

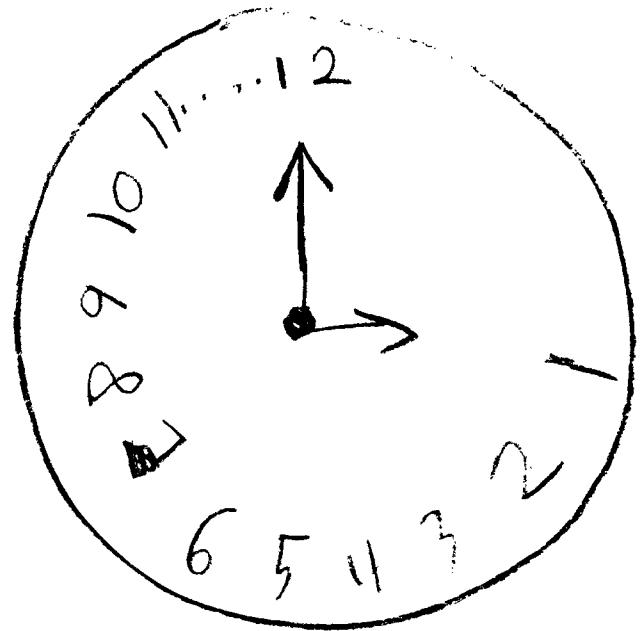


Figure 6. Clock face drawing for patient 2, 6 months after the initial drawing, showing improvement but with persistent right superior field abnormality.

These patients were instructed to complete the clock face design within a circle. If this is an ipsilateral neglect syndrome, perhaps confinement of the visual-spatial task to a limited, enclosed region somehow focuses the deficit, whereas a less bounded task such as random number cancellation failed to demonstrate the disorder.

We propose, alternatively, that these two boys had ipsilateral spatial practic disturbances, constructional apraxias, resulting from nondominant hemispheric lesions and that such disturbances can exist separately and distinctly from unilateral spatial neglect.

Acknowledgment

The authors express their appreciation to Teresa Fly for her assistance with preparation of this manuscript.

References

1. Gainotti G: Constructional apraxia, in Frederiks J (ed): *Handbook of Clinical Neurology*, Vol 1. New York, Elsevier, 1985, pp 491-505.
2. Geschwind N, Damasio AR: Apraxia, in Frederiks J (ed): *Handbook of Clinical Neurology*, Vol 1. New York, Elsevier, 1985, pp 423-432.
3. Heilman KM, Valenstein E, Watson RT: Neglect and related disorders. *Semin Neurol* 1984;4:209-219.
4. Benton A: Constructional apraxia: An update. *Semin Neurol* 1984;4:220-222.
5. Geschwind N: The apraxias: Neural mechanisms of disorders of learned movements. *Am Sci* 1975;63:188-194.
6. Heilman KM, Valenstein E: Mechanisms underlying hemispatial neglect. *Ann Neurol* 1979;5:166-170.
7. Lewis D, Tucker S: Central nervous system involvement in cat scratch disease. *Pediatrics* 1986;77:714-721.
8. Villa G, Gainotti G, DeBonis C: Constructive disabilities in focal brain-damaged patients. *Neuropsychologia* 1986;24:497-510.

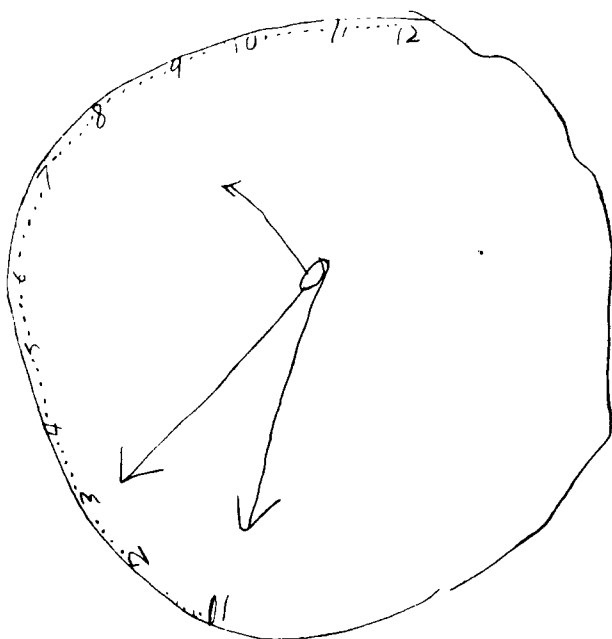


Figure 5. Clock face drawing for patient 2, with failure to complete drawings on the right.

9. Heilman KM, Howell GJ: Seizure-induced neglect. *J Neurol Neurosurg Psychiatry* 1980;43:1035-1040.
10. Schwartz AS, Marchock PL, Kreinick CJ, et al: The asymmetric lateralization of tactile extinction in patients with unilateral cerebral dysfunction. *Brain* 1979;102:669-684.
11. Welman AJ: Right-sided unilateral visual-spatial agnosia asomatognosia, and anosognosia with left-hemisphere lesions. *Brain* 1969;92:572-582.
12. Sparks R, Goodglass H, Nichel B: Ipsilateral vs contralateral extinction in dechotic listening resulting from hemispheric lesions. *Cortex* 1970;6:249-260.
13. Lynn GE, Benitez JT, Eisenbrey AB, et al: Neuroauditory correlates in cerebral hemisphere disease. *Audiology* 1972;11:115-134.
14. Albert ML: A simple test of visual neglect. *Neurology* 1973;23:658-664.
15. Schwartz AS, Marchock PL, Flynn RE: A sensitive test for tactile extinction: Results in patients with parietal and frontal lobe disease. *J Neurol Neurosurg Psychiatry* 1977;40:228-233.