

Shaken Baby Syndrome: Identification and Prevention ▪ for Nurse Practitioners ▪

Deborah Coody, MSN, RN, CPNP, Mary Brown, MSN, RN, CPNP,
Diane Montgomery, MSN, RN, CPNP, Abbie Flynn, MSN, RN-C, NNP, and
Robert Yetman, MD

Shaken baby syndrome is a less widely recognized form of physical child abuse. It is defined as vigorous manual shaking of an infant who is being held by the extremities or shoulders, leading to whiplash-induced intracranial and intraocular bleeding and no external signs of head trauma; often identifying shaken baby syndrome is difficult because of the lack of obvious external signs. Shaken baby syndrome should be considered in infants with seizures, failure to thrive, vomiting associated with lethargy or drowsiness, respiratory irregularities, coma, or death. With the increased awareness of child abuse, more attention has been focused on morbidity and death caused by the violent shaking of infants. This article describes the clinical findings of shaken baby syndrome, explores the characteristics of families at risk for abuse, and discusses implications for nurse practitioners. J PEDIATR HEALTH CARE. (1994). 8, 50-56.

Head injury is a leading cause of morbidity and death among children (Gordon, 1989); it is the most frequent cause of morbidity and death in abused children (Billmire & Meyers, 1985). An estimated 2.7 million children in the United States were the victims of child abuse in 1991, and at least 1,033 of these children died of abuse (National Coalition for the Prevention of Child Abuse, 1991). Of the child abuse victims, 55% were 1 year of age or younger. With the increased awareness and reporting of child abuse, more attention has been focused on the damage caused by the violent shaking of infants, a previously less widely recognized form of physical abuse.

The first article describing infantile whiplash injuries was published by Guthkelch in 1971; the term "whiplash shaken baby syndrome" was established by John Caffey in 1972. This syndrome, which is now commonly referred to as "shaken baby syndrome," or SBS, involves vigorous manual shaking of infants who are being held by the extremities or shoulders, with whiplash-induced intracranial and intraocular bleeding, but with no external signs of head trauma.

▪ CASE STUDY

L.D. is a 6-month-old female who was brought to a pediatric emergency center by her parents after she had a seizure at a day care center. She had no previous history of seizures and was afebrile. Her parents reported that she had been in good health except for requiring treatment for an arm fracture at 4 months after she had "rolled over on her arm the wrong way." The parents were both 19 years of age, and L.D. was their only child. L.D. recently started attending a state-subsidized day-care program on her mother's return to work. Both parents described L.D. as "fussy all the time; she cries no matter what we do." Initial physical examination revealed a lethargic yet irritable infant with decreased tone throughout the body. She had a tense anterior fontanelle and split sutures but no evidence of external trauma to the head and neck. Her head circumference measured 46.0 cm, greater than the 90th percentile for her age. Full extraocular movements were

Deborah Coody, MSN, RN, CPNP, is an assistant professor of pediatrics at the University of Texas Medical School at Houston.

Mary Brown, MSN, RN, CPNP, is a clinical instructor at the University of Texas School of Nursing at Houston.

Diane Montgomery, MSN, RN, CPNP, is a clinical instructor at the University of Texas Medical School at Houston.

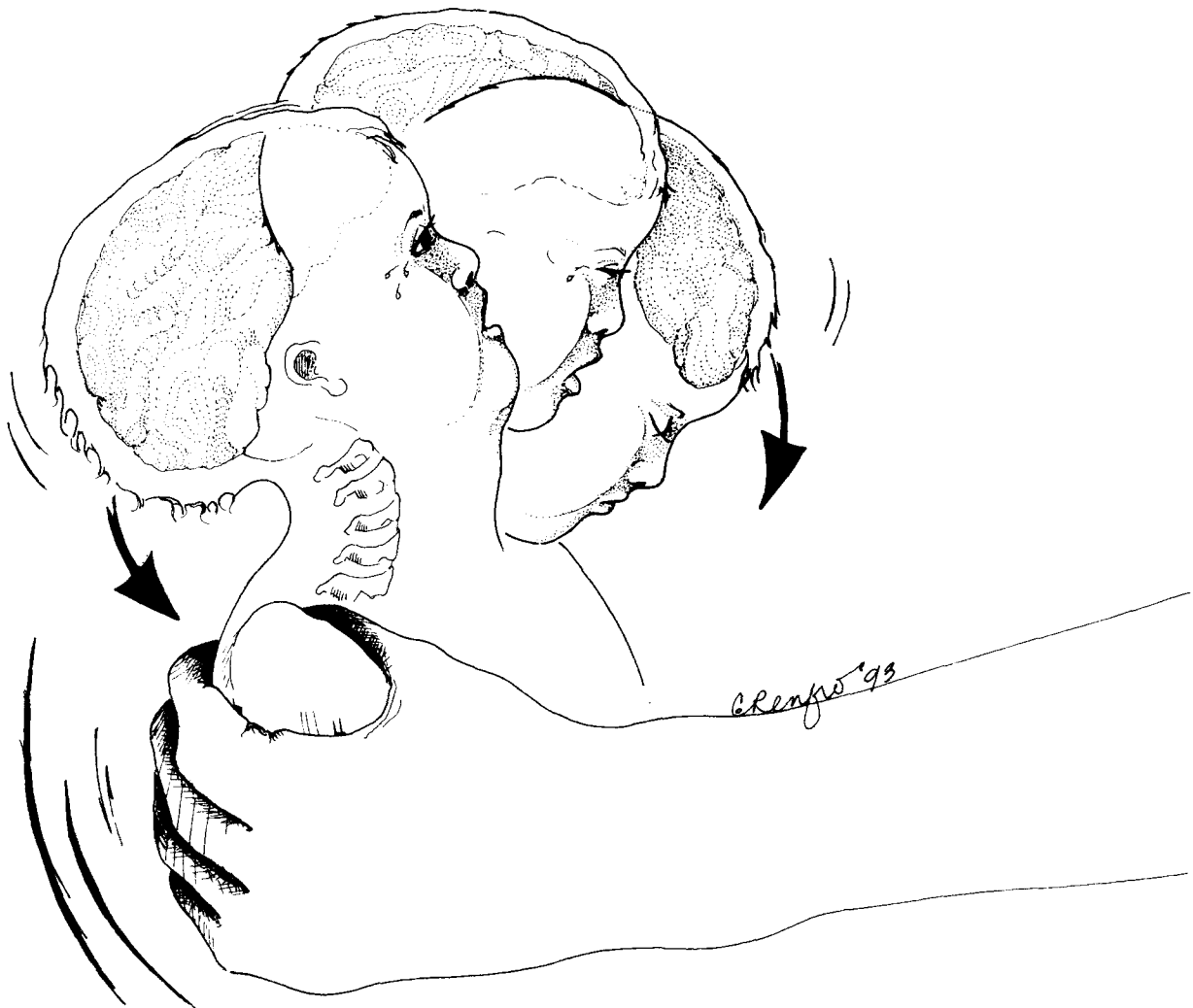Abbie Flynn, MSN, RN-C, NNP, is a clinical instructor at the University of Texas Medical School at Houston.

Robert Yetman, MD, is an associate professor of pediatrics at the University of Texas Medical School at Houston.

Reprint requests: Deborah Coody, MSN, RN, CPNP, Assistant Professor, Department of Pediatrics, University of Texas Medical School at Houston, 6431 Fannin, 3.020 MSB, Houston, TX 77030.

Copyright © 1994 by the National Association of Pediatric Nurse Associates & Practitioners.

0-91-5245/94/\$3.00 + 0 25/1/47066



■ **FIGURE 1** Vigorous shaking produces acceleration-deceleration of the infant's head and results in the whiplash injury.


noted on the right, but no extraocular movements were detected on the left. Funduscopy examination showed massive retinal hemorrhages bilaterally. Dark red ecchymotic areas were found on both upper arms, and yellowish-green ecchymoses were noted on her abdomen and posterior thighs. The remainder of the physical examination was normal.

Liver and coagulation studies were normal. Lumbar puncture produced xanthochromic fluid with 40,000 red blood cells, 850 white blood cells (80% polymorphonuclear, 20% lymphocyte), protein of 38 mg/dl and glucose of 76 mg/dl. Blood and cerebrospinal fluid cultures were negative. Skull radiographs showed widened coronal and sagittal sutures but no fracture; no fractures were evident on radiographs of ribs, yet a calcified area of healing was noted on the right proximal humerus. Computerized tomography (CT) showed diffuse cerebral edema and reduced ventricular size with some enlargement of the subarachnoid space. Seizures contin-

ued for 2 days and were treated with phenobarbital, hydantoin, and valproate sodium. The patient regained consciousness over a period of 2 weeks but remained in a vegetative state, opening and closing her eyes but not responding meaningfully to any stimuli. The ocular hemorrhages disappeared and were replaced by a pale yellow disc, still present 1 year after her admission. She remained retarded, quadriplegic, and blind.

■ **THE WHIPLASH INJURY**

When a baby is shaken, the shaker usually grabs the child around the thorax. The pressure that is applied around the chest inhibits venous return, causing the blood to pool in larger vessels including those that drain the blood from the head. An infant's head is relatively larger and heavier than the older child's head, and it is supported by weaker neck muscles (Dykes, 1986). Vigorous shaking of an infant produces acceleration-deceleration of the infant's head. Because of the time lag



■ **FIGURE 2** Scattered dome-shaped retinal hemorrhages. *Note.* From "Shaken baby syndrome" by R.F. Swengel, D.W. Scharre, & C.E. Mein, 1990, *American Family Physician*, 41, pp. 1145-1152. Copyright 1990 by the American Academy of Family Physicians. Reprinted by permission.

between movement of the skull and movement of its contents during a shaking episode, rotational forces lead to shearing and tensile stress on the bridging cortical veins (Figure 1). This stress on the attachments between the outer surfaces of the brain and inner surfaces of the skull can cause tearing of the cortical veins, resulting in subdural hematomas. Cerebral injury in children causes increased cerebral blood volume; thus the blood vessels of the head contain an increased amount of blood under increased pressure. Because wall tension in a cylindrical structure increases as the product of pressure and radius (Spaide, Swengel, Scharre, & Mein, 1990), blood vessels in the head are more likely to rupture from the trauma caused by shaking. Intracranial hemorrhages, cerebral hyperemia, and edema increase intracranial pressure. Transmitted by the optic nerve sheaths, this pressure can reduce venous outflow from the eye. Sudden distention of the sheaths may be the cause of the optic nerve sheath hemorrhages seen in SBS. Retinal hemorrhages in SBS result from compression of the thorax, high intracranial pressure secondary to hemorrhage and edema, and blood acceleration backward through venous channels into the retinal vascular tree (Spaide, 1987).

Intracranial injury is the major cause of death and morbidity in SBS. Subdural hematomas are the most common intracranial lesions seen, followed by subarachnoid hemorrhages, cerebral contusions, and acute interhemispheric subdural hematomas.

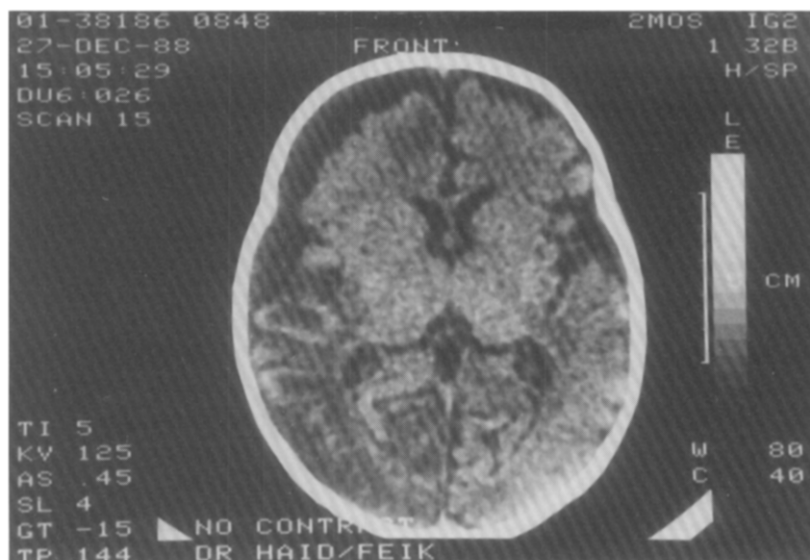■ CLINICAL PRESENTATION

SBS is difficult to diagnose because the child usually has little or no external evidence of trauma and parents do not voluntarily give a history of abuse. A complete his-

tory and a thorough physical examination are necessary to make the diagnosis. These children are generally under the age of 1 year, and most are less than 6 months old (Spaide et al., 1990). They usually have vague symptoms similar to those of infectious processes commonly associated with infants and children. For this reason, SBS is often not considered in the diagnosis. The most common symptoms include vomiting, irritability, listlessness, lethargy, bradycardia, apnea, seizures, coma, bulging or full fontanels, large head circumference, hypothermia, poor feeding response, failure to thrive, or other vague symptoms indicative of other conditions (Brenner, Fischer, & Mann-Gray, 1988; Dykes, 1986; Ludwig & Warman, 1984; Spaide et al., 1990).

Although ocular findings may be present, they are often missed.

Although ocular findings may be present, they are often missed. These findings include orbital and lid ecchymosis, hyphema, subconjunctival hemorrhage, anisocoria, disconjugate eye movement, papilledema, sixth-nerve palsy, and retinal detachment (Dykes, 1986). The most classic finding of SBS, however, is retinal hemorrhages, which are bilateral in most cases (Figure 2). Newborns commonly have retinal hemorrhages from birth trauma, which usually resolve within 1 month of birth. The presence of retinal hemorrhages in children under 4 years of age, with the possible exception of the first month of life, is highly suggestive of SBS (Carter & McCormick, 1983). SBS is also characterized by subdural and/or subarachnoid hemor-



■ **FIGURE 3** Computerized tomography scan on the day of admission in a 2-month-old girl with seizures and bilateral retinal hemorrhages. Subdural hematomas are seen in the frontal and temporal regions. Note. From "Shaken baby syndrome" by R.F. Spaide, R.M. Swengel, D.W. Scharre, & C.E. Mein, 1990, *American Family Physician*, 41, pp. 1145-1152. Copyright 1990 by the American Academy of Family Physicians. Reprinted by permission.

rhages with minimal or absent signs of external craniofacial trauma (Hadley, Sonntag, ReKate, & Murphy, 1989). Occasionally evidence of ecchymotic grip marks are found on the child's shoulders, upper arms, or thorax from the infant being grasped firmly for shaking.

■ DIAGNOSTIC EVALUATION

The diagnostic evaluation for SBS is based on signs and symptoms observed at examination. The practitioner who initially evaluates the young child with common symptoms of SBS may not initially order complete ophthalmologic examinations, skull radiography, CT, or magnetic resonance imaging (MRI). Differential diagnoses of SBS include seizure disorder, meningitis, failure to thrive, viral syndromes, shock, apnea episode, sudden infant death syndrome, hydrocephalus, or rupture of a congenital aneurysm. After screening blood and urine studies show no evidence of infection or metabolic problems, further investigations are warranted. Unfortunately, the condition of many children remains undiagnosed because the children have signs that do not appear to originate from trauma.

Any child who has unexplained lethargy or seizures should immediately have an ophthalmologic examination to rule out abuse. Although retinal hemorrhages are common from birth trauma, after the neonatal period retinal hemorrhages in infants should be considered to be caused by child abuse unless proved otherwise (Kessler & Siegel-Stein, 1984). A lumbar puncture is performed very carefully in children with symptoms of seizures or vomiting associated with lethargy or drows-

ness. Blood-contaminated cerebrospinal fluid, or a "bloody tap," is difficult to interpret. The needle tip can easily enter the anterior internal venous plexus, causing venous blood to exude from the needle hub. When cerebrospinal fluid collected in three or four tubes becomes progressively clearer, this is good indication that the lumbar puncture has been "traumatic" or caused by the procedure itself. Grossly bloody fluid that does not clear can be a manifestation of a subarachnoid hemorrhage (Apolo, 1987).

Diagnostic radiologic studies include radiographs, CT scan, and MRI. A skull fracture, which may or may not be found on radiologic studies, is usually in the occipital or parietal regions and is the result of direct trauma (Spaide et al., 1990). Associated radiologic findings that may be found include broken ribs, chest bruises, spiral fracture of extremities, metaphyseal lesions, and epiphyseal separation (Spaide et al., 1990). The CT scan, an extremely sensitive and relatively non-invasive technique to assess intracranial pathologic condition, has been used as a key diagnostic study in identifying SBS. CT is used initially because it is usually obtained more quickly and is less expensive than MRI. The CT scan shows intracranial hemorrhages associated with vigorous shaking or blunt trauma with or without skull fracture (Alexander, Sato, Smith, & Bennett, 1990), and it is superior to skull radiography in diagnosing depressed skull fractures, hairline fractures, and mild compression fractures often missed on plain radiography (Figure 3). The CT is effective in exhibiting a combination of cerebral edema and contusional hem-

■ TABLE 1 Families at risk for abuse

Characteristics of parents	Characteristics of child	Environmental and other factors
Poor nurturing/abuse during childhood	Physical anomalies	Financial difficulties
Low self esteem/depression	Developmentally delayed	Unemployment
Social isolation	Physically delayed	Illness
Inadequate knowledge of normal developmental behavior	"Difficult" temperament, as described by parent	Divorce or relationship difficulties
Free expression of violence; difficulty controlling impulses	Does not meet expectations of parent(s)	Housing problems
Substance abuse	May remind parent of someone else	Lack of family support

Compiled from Heindl, K., Krall, C., Salus, M., & Broadhurst, D. (1979); Kempe, C.H., & Helfer, R.E. (1980); Kessler, D.B., & Hyden, P. (1991); Whaley, L.F., & Wong, D.L. (1991); Wissow, L.S. (1990).

orrhages (Ellison, Tsai, & Largent, 1978). The most common finding of SBS on the CT is subdural hematoma, a lesion almost always traumatic in origin. Other findings include cerebral contusion and subarachnoid hemorrhages. In a follow-up CT, the brain may show atrophy, multiple hypodense areas, and ventricular enlargement (Alexander et al., 1990). A normal CT scan does not eliminate the diagnosis of SBS if other signs of abuse are also present (Bennett & French, 1980). The MRI offers an even more detailed study than does the CT scan. It offers better contrast sensitivity and clarity and obtains more vivid evidence of injury. Disadvantages of the MRI include its high cost, lack of availability, and the requirement for sedation in a child already compromised with intracranial injuries.

■ SEQUELAE

SBS may cause death, permanent brain damage, or long-term disability. Developmental delay, spasticity, quadraparesis, hearing loss, hydrocephalus, seizure disorder, microcephaly, and blindness are frequently seen results of SBS (Spaide, Swengel, Scharre, & Mein, 1990). Less severe cases may result in chronic brain damage. Mild to moderate mental retardation and developmental delay with no apparent cause may not be found until the child enters school (Caffey, 1974). Possibly some children with mental retardation were actually undiagnosed SBS victims. Developmental delay can also be associated with SBS where the increased intracranial pressure interfered with the blood supply to the pituitary gland (Dykes, 1986). Therefore the practitioner should consider SBS in children with impaired growth and hypopituitarism.

■ FAMILIES AT RISK FOR ABUSE

Although nursing, medical, and behavioral scientists have identified numerous factors that place children at

risk for child abuse (Table 1), the determination has not yet been made whether these risks are exactly the same for infants of SBS. However, it is reasonable to infer that these risk factors may be similar for SBS. Spaide et al. (1990) recognized the following three factors that contribute to the impairment of the parent-child relationship in SBS:

- a. Behavioral difficulties of the parent;
- b. Social and stress management problems in the family;
- c. The child's behavior leading to the abuse.

The parent may have an unconscious desire to be nurtured by the child, because the parent may not have received adequate nurturing experiences during childhood (Whaley & Wong, 1991). Young infants who sleep most of the time and cry often while awake, such as the 20% to 30% of infants in whom colic develops,

Any child who has unexplained lethargy or seizures should immediately have an ophthalmologic examination to rule out abuse.

give very little "nurturing" to the needy parent (Spaide et al., 1990). If the parent's expectations of a submissive, nurturing infant are not met, the parent may feel rejected, leading to further breakdown of the parent-child relationship and increasing the likelihood of shaking secondary to frustration. Many parents who would never consider striking their child may resort to shaking their child as a less violent approach, not knowing the possible sequelae of the event.

■ IMPLICATIONS FOR NURSE PRACTITIONERS

Pediatric nurse practitioners (PNPs) are in a strategic position to offer primary and secondary prevention in-

■ TABLE 2 Educational materials

Title	Description	Source
"Never Shake a Baby" Media campaign	16 × 20-inch poster 8 1/2 × 11-inch poster 7-minute video	Ohio Institute on Child Abuse Prevention 1-800-858-5222
"Crying-What Can I Do?" "Discipline and Child Abuse"	Guides for parents in preventing child abuse	Kidsrights Catalogue 1-800-892-KIDS
"The Parents' Checklist" "About Preventing Child Abuse"	Parent information booklet	Scriptographic Publications 1-800-628-7733
"The First Five Years"	Book for new parents; anticipa- tory guidance	American Academy of Pediatrics 1-800-433-9016
"The First Year-Caring for Your Baby"	Booklets for new parents; antic- ipatory guidance	Ross Laboratories (free)
"Your Baby and Crying" "You and Your Baby-The Phenomenon of Early Development"		
"Brazelton on Parenting: Newborn Topics"	Videotapes for health profes- sionals	Pipher Films, Inc. Ross Laboratories (free)
Growth and Develop- ment Ruler	Quick-check for developmental milestones—birth to 24 months	Houston Area Chapter of NAPNAP—Mary Brown (713)792-7824
Various child abuse topics	Pamphlets/booklets	National Committee for Preven- tion of Child Abuse (312)663-3520

terventions, to identify the family at risk, and to recognize victims of SBS. Primary prevention interventions, taken to ensure that child abuse will never occur, begin with teaching all new parents, potential parents and caretakers, and the general public about SBS and the mechanism of injury involved (Table 2). PNPs in hospital nurseries and outpatient settings have a responsibility to educate new parents about normal child development and the danger of shaking infants, to foster bonding, and to assess families for risk of abuse. Secondary prevention interventions, provided to families identified to be at risk for abuse, are based on information that these parents have a lack of knowledge of normal child development and have unrealistic expectations of their children. PNPs have the appropriate background and training to offer instruction, anticipatory guidance, and education in these areas. In the office setting, PNPs have the critical opportunity to assess the quality of interactions between parent and child and to intervene or refer families at risk for abuse. The PNP should discuss effective discipline techniques and techniques that do not work and should not be used. The PNP can model appropriate interactive behavior during the examination, teaching by example. The office setting also provides an ideal opportunity to offer parenting classes about normal developmental stages of infants,

common problem areas such as crying and colic, and dealing with difficult situations effectively. Tertiary prevention interventions, taken after abuse has already occurred in an effort to prevent further abuse (Kessler & Hyden, 1991), include referrals to child protective services, legal indictments, and rehabilitative measures. Unfortunately, tertiary prevention has been the main focus within health care systems for much too long. PNPs must make a concerted effort to prevent child abuse and/or identify and intervene in the early stages in a way that causes the least trauma to the child. A coordinated effort needs to be established to develop programs that provide anticipatory guidance to parents and prevention programs and treatment for children and their families (National Association of Pediatric Nurse Associates and Practitioners, 1992).

REFERENCES

- Alexander, R. A., Sato, Y., Smith, W., & Bennett, T. (1990). Incidence of impact trauma with cranial injuries ascribed to shaking. *American Journal of Diseases of Children, 144*, 724-726.
- Apolo, J. O. (1987). Bloody cerebrospinal fluid: Traumatic tap or child abuse? *Pediatric Emergency Care, 3*, 93-95.
- Bennert, H. S., & French, J. H. (1980). Elevated intracranial pressure in whiplash shaken infant syndrome detected with normal computerized tomography. *Clinical Pediatrics, 19*, 633-634.

- Billmire, M. E., & Phillips, T. J. (1985). Serious head injury in infants: Accident or abuse? *Pediatrics*, *75*, 340-342.
- Brenner, S. L., Fischer, H., & Mann-Gray, S. (1988). Race and the shaken baby syndrome: Experience at one hospital. *Journal of the National Medical Association*, *81*, 183-184.
- Caffey, J. (1972). On the theory and practice of shaking infants, its potential residual effects of permanent brain damage and mental retardation. *American Journal of Diseases of Children*, *124*, 161-169.
- Caffey, J. (1974). The whiplash shaken baby syndrome: manual shaking by the extremities with whiplash-induced intracranial and intraocular bleedings, linked with residual permanent brain damage and mental retardation. *Pediatrics*, *54*, 396-403.
- Carter, J. E., & McCormick, A. Q. (1983). Whiplash shaking syndrome: Retinal hemorrhages and computerized axial tomography of the brain. *Child Abuse and Neglect*, *7*, 279-286.
- Dykes, L. J. (1986). The whiplash shaken infant syndrome: What has been learned? *Child Abuse and Neglect*, *10*, 211-221.
- Ellison, P. H., Tsai, F. Y., & Largent, J. A. (1978). Computerized tomography in child abuse and cerebral contusion. *Pediatrics*, *62*, 151-154.
- Gordon, V. L. (1989). Recovery from a head injury: A family process. *Pediatric Nursing*, *15*, 131-133.
- Guthkelch, A. N. (1971). Infantile subdural haematoma and its relationship to whiplash injuries. *British Medical Journal*, *2*, 430-431.
- Hadley, M. N., Sonntag, V. K., ReKate, H. L., & Murphy, A. (1989). The infant whiplash-shaken injury syndrome: A clinical and pathological study. *Neurosurgery*, *24*, 536-540.
- Heindl, K., Krall, C., Salus, M., & Broadhurst, D. (1979). *The nurse's role in prevention and treatment of child abuse and neglect* (Publication #HDS 7930202). Washington, DC: National Center on Child Abuse and Neglect, Department of Health, Education and Welfare.
- Kempe, C. H., & Helfer, R. E. (1980). *The battered child* (3rd ed.). Chicago: University of Chicago Press.
- Kessler, D. B., & Hyden, P. (1991). Physical, sexual and emotional abuse of children. *Clinical Symposia*, *43*, 2-3, 31-32.
- Kessler, D. B., & Siegel-Stein, F. (1984). Retinal hemorrhage, meningitis, and child abuse. *New York State Journal of Medicine*, 59-60.
- Ludwig, S., & Warman, M. (1984). Shaken baby syndrome: A review of 20 cases. *Annals of Emergency Medicine*, *13*, 104-107.
- National Association of Pediatric Nurse Associates and Practitioners, 1992, *Position Statement on Child Abuse*, Cherry Hills, NJ: Author.
- National Coalition for the Prevention of Child Abuse, 1991, *1991 statistics*, Chicago: Author.
- Spaide, R. F. (1987). Shaken baby syndrome: Ocular and computed tomographic findings. *Journal of Clinical Neuro-ophthalmology*, *7*, 108-111.
- Spaide, R. F., Swengel, R. M., Scharre, D. W., & Meine, C. E. (1990). Shaken baby syndrome. *American Family Physician*, *41*, 1145-1152.
- Whaley, L. F., & Wong, D. L. (1991) *Nursing care of infants and children* (4th ed.). Chicago: Mosby-Year Book, Inc.
- Wissow, L. S. (1990). *Child advocacy for the clinician: An approach to child abuse and neglect*. Baltimore: Williams and Wilkins.

The JOURNAL is abstracted and/or indexed in the *International Nursing Index*, the *Cumulative Index to Nursing & Allied Health Literature*, and MEDLINE.

This JOURNAL has been registered with Copyright Clearance Center, Inc., 222 Rosewood Dr., Danvers, MA 01923. Consent is given for the copying of articles for personal or internal use of specific clients. This consent is given on the condition that the copier pay directly to the Center the per-copy fee stated on the first page of each article for copying beyond that permitted by U.S. Copyright Law. This consent does not extend to other kinds of copying, such as for general distribution, resale, advertising and promotional purposes, or for creating new collective works. All inquiries regarding copyrighted material from this publication other than those that can be handled through Copyright Clearance Center should be directed to the Associate Journal Publisher, Mosby-Year Book, Inc., 11830 Westline Industrial Dr., St. Louis, MO 63146, phone (314)579-2808; fax (314)432-1380.
