

Pure sensory seizures

MITSUTOSHI YAMAMOTO, ATSUSHI OKUDAIRA, ICHIRO KOHIRA, TOSHIAKI KUGOH*, ISAO FUKUNISHI* & KIYOSHI HOSOKAWA*

*Department of Neurology, Kagawa Prefectural Central Hospital, and *Department of Neuropsychiatry, Kagawa Medical School*

Correspondence to Dr M. Yamamoto, Department of Neurology, Kagawa Prefectural Central Hospital, 5-4-16 Bancho, Takamatsu 760, Japan

A 62-year-old woman, who frequently had numbness seizures in the right half of her body, is reported. Weakness and consciousness disturbance did not occur during the seizure, and an abnormal electroencephalogram was not observed during the seizure or between seizures. The seizure was completely inhibited by a single-blind administration of phenytoin. It also disappeared on administration of carbamazepine, suggesting that the numbness seizures in this patient were of an epileptic nature.

Key words: epilepsy; sensory seizure; partial seizure; numbness; phenytoin.

INTRODUCTION

Sensory seizures, one of many manifestations of epileptic seizures, usually occur in combination with other signs such as motor seizures, and pure sensory seizures are considered to be very rare. We did not recognize any epileptic changes or abnormality in an electroencephalogram (EEG) during seizures in the patient we will describe, but succeeded in diagnosing a pure sensory seizure, by the single-blind administration of antiepileptic drugs.

CASE REPORT

A 62-year-old woman visited Kagawa Prefectural Central Hospital with recurrent attacks of numbness in the right half of the body including the face, which started suddenly at the beginning of December 1987. The patient reported that she had several seizures a day that disappeared within about 1 min. She was admitted to the Department of Neurosurgery for precise examination in January 1988. The patient reported no notable past or family history of similar problems. Since there were no abnormal findings in brain CT-scan, cerebral angiography, and EEG, transient ischaemic attacks were diagnosed and adminis-

tration of ticlopidine was started. However, the numbness seizures did not subside, so the patient was referred to the Department of Neurology. When administration of carbamazepine at a dose of 400 mg/day was started for suspected epileptic seizures, the numbness seizures disappeared. She then continued to receive examination and treatment from the Department of Neurology.

No abnormal neurological findings other than senile tremor were observed at this time. The numbness was described as similar to that experienced during an electric shock, and the seizures were observed about 3 to 30 times, on most days. The patient reported that the numbness seizures often originated in the right scapular region, and the seizures were limited to the right half of the body including the face. Most of the seizures subsided within 1 min. She reported that the seizures also occurred during sleep at night. Numbness seizures observed during the daytime were not related to her activity at the time, and she could even continue to hold on to something at the moment of the seizure. Weakness and disturbance of consciousness were not observed and she could also speak normally during the experience. No abnormalities other than mild diabetes were noted on urinalysis, complete blood counts, blood chemical tests, and cerebro-

spinal fluid analysis. There were no abnormal findings in the CT-scan, but MRI demonstrated numerous small infarctions in the white matter mainly in the region of the middle cerebral artery (Fig. 1.). There were no abnormalities detected in any EEG including a sleep EEG.

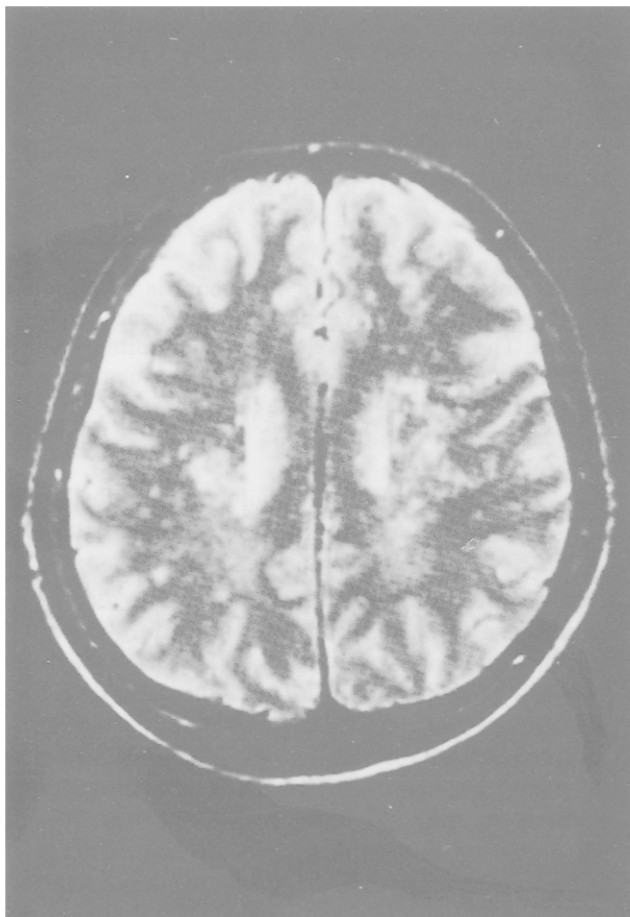


Fig. 1: Magnetic resonance imaging (MRI).T₂ weighted image.

The clinical course after admission and treatment is shown in Fig. 2. When administration of carbamazepine was discontinued, numbness seizures reappeared 3 days later. Therefore, diazepam and bromazepam were administered, but the symptoms did not improve. The patient was asked to record the frequency of the seizures from 15 February 1988. After the patient's consent was obtained, single-blind cross-over administration of a placebo and phenytoin was started. (Both drugs were given in the form of the same amount of powder.) Seizures were slightly inhibited by 100 mg/day of phenytoin, and were completely inhibited by 200 mg/day. However, the seizures occurred again when it was replaced by a

placebo. The patient was admitted to Kagawa Medical School Hospital on 30 March, in order to be examined with video-telemetric EEG during her numbness seizures. The patient was given a single-blind administration at this time as well, and the seizures appeared again when phenytoin was discontinued. EEG recording during a seizure was obtained more than 10 times; however, no epileptic abnormality was observed. Administration of phenytoin in doses of 200 mg/day was resumed from 9 April, and numbness seizures have been completely inhibited up to the present time.

DISCUSSION

The numbness seizures in this patient were considered to be pure sensory seizures unaccompanied by disturbances of consciousness or weakness. The numbness as reported by this patient belongs to the so-called 'somatic sensations'. The site of lesions which manifest altered somatic sensations is considered to be the second sensory area. Stimulation of this site produces variable paresthesiae on most commonly, the same side, the opposite side or both sides of the face, limbs and body¹. This kind of somatic sensory seizure itself is considered to be rare; however, its frequency in patients with epilepsy is not presently known. Penfield and Jasper¹ reported two cases of pure sensory seizures originating from the second sensory area, and Lessors *et al.*² reported sensory seizures in a case of glioblastoma multiforme. Devinsky *et al.*³ found sensory seizures in three of 14 patients with simple partial seizures, but a pure sensory seizure was found in only one patient. Altered somatic sensation was observed only three times during 60 non-motor seizures in their 14 patients. Thus the frequency of pure sensory seizures is rare.

Epilepsy should be differentiated from other diseases presenting similar sensory seizures, including transient ischaemic attacks, organic brain diseases such as brain tumour, and psychogenic disorders known as so-called 'pseudo-seizures'. Numerous small infarctions were recognized on MRI of this patient. This organic brain damage may have contributed to the cause of epileptic seizures in this patient, although there were no lesions in the grey matter. Although it is desirable to confirm abnormalities with an EEG during seizures in the diagnosis of epileptic sensory seizures, no abnormality was apparent in the record of

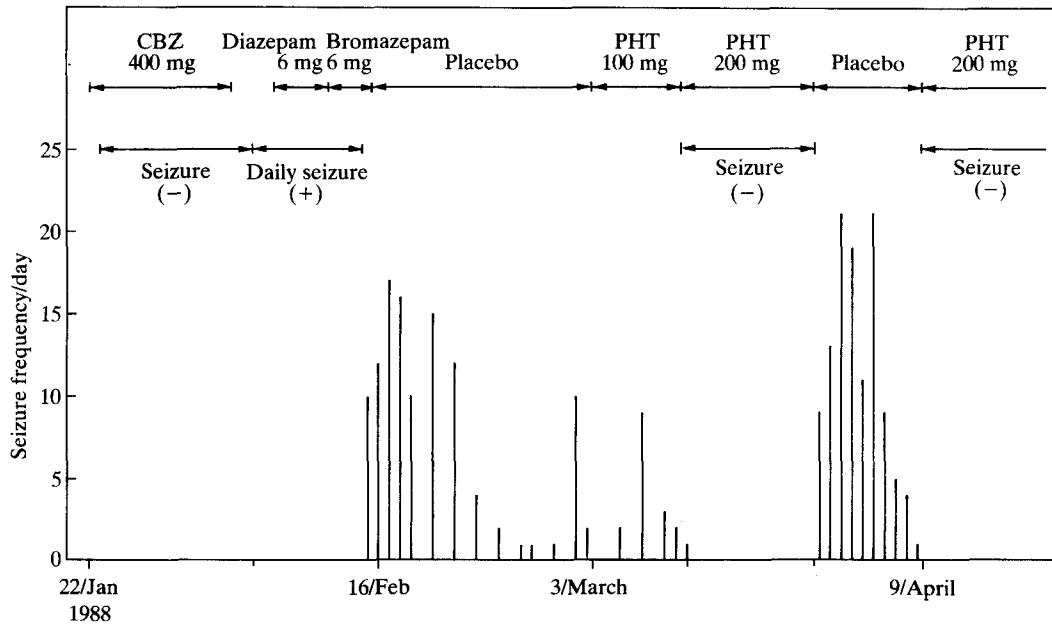


Fig. 2: Clinical course of treatment. CBZ, carbamazepine; PHT, phenytoin; this graph is based on the record kept by the patient.

EEG obtained from our patient during her seizures. Therefore, differentiation from a pseudo-seizure became important. This patient's seizures seem to be caused by epilepsy as no psychogenic disorder was observed, as the seizure was completely inhibited by the antiepileptics, carbamazepine and phenytoin, and particularly as the efficacy of phenytoin was confirmed by single-blind administration.

Devinsky *et al.*³ recorded 87 seizures in 14 patients with epilepsy, who suffered from simple partial seizures, by video-telemetric EEG, and observed an abnormal EEG in only 2%. An abnormal EEG during seizures was seen in 15% of 60 non-motor seizures studied, and was observed in 33% of 27 motor seizures. Thus, epilepsy cannot be excluded from the diagnosis on the basis of a normal EEG alone. Conse-

quently, it is not uncommon that no abnormality in an EEG during seizures is detected in pure sensory seizures of the simple partial seizure type reported here. In such cases, single-blind administration of an antiepileptic drug is considered to be useful as a therapeutic diagnostic method.

REFERENCES

1. Penfield, W. and Jasper, H. *Epilepsy and the Functional Anatomy of the Brain*. Boston, Little Brown, 1954: p. 77, p. 396.
2. Lessor, R.P., Leuders, H., Conomy, J.P. *et al.* Sensory seizure mimicking a psychogenic seizure. *Neurology* 1983; **33**: 800-802.
3. Devinsky, O., Kelley, K., Porter, R.J. *et al.* Clinical and electroencephalographic features of simple partial seizures. *Neurology* 1988; **38**: 1347-1352.