

Cerebral Infarction Immediately After Ingestion of Hydrogen Peroxide Solution

Scott J. Sherman, MD, PhD; Leslie V. Boyer, MD; William A. Sibley, MD

Background We report the clinical and neuroimaging findings of a patient who sustained multiple cerebral infarcts after the ingestion of concentrated hydrogen peroxide solution sold as a "health food" product.

Case Description An 84-year-old man sustained focal neurological deficits immediately after ingesting 30 mL of 35% hydrogen peroxide solution. Physical examination disclosed a left hemiparesis, frontal release signs, and cerebellar dysfunctions. Magnetic resonance imaging revealed multiple cerebral

and cerebellar infarctions in the anterior, middle, and posterior vascular territories.

Conclusions The likely mechanism of pathogenesis involves cerebral oxygen gas embolization. The use of hyperbaric therapy should be considered in treating hydrogen peroxide poisoning. (*Stroke*. 1994;25:1065-1067.)

Key Words • cerebral infarction • embolism • hydrogen peroxide • hyperbaric oxygenation

Concentrated hydrogen peroxide (35%) is a commercially available oxidant with widespread applications in the chemical and manufacturing industries. Recently this concentrated form of hydrogen peroxide has been sold as "Food Grade Hydrogen Peroxide for Hyper-Oxygenation Therapy" by merchants claiming sundry health benefits.¹ Although instructions for dilution to nontoxic concentrations may accompany the sale of the product, no clear warning of the potential for serious morbidity or mortality is given. We now report a case of extensive neurological damage immediately subsequent to the purposeful ingestion of 35% hydrogen peroxide taken as a health remedy. We propose that the likely mechanism of tissue damage in the central nervous system involves oxygen gas embolization of the cerebral vasculature.

Case Report

An 84-year-old right-handed man ingested approximately 30 mL of 35% hydrogen peroxide after diluting it in a small volume (100 to 300 mL) of water. The patient purchased the hydrogen peroxide after being told by an acquaintance that it would be a beneficial remedy for arthritis. Although the patient did have extensive pre-existing cerebrovascular disease and had undergone left carotid endarterectomy in the remote past, he had never had a stroke. By history, his premorbid functioning was normal.

Within 3 minutes after the ingestion, the patient slumped over and became unresponsive. After awakening, the patient remembered mixing the hydrogen peroxide and swallowing the solution. He recalled a "fizzy"

sensation in the mouth but had no recall of subsequent events.

When paramedics arrived on the scene, they found the patient with his eyes open but unresponsive to verbal command. There was foamy material around the mouth and nose. Initial vital signs in the field were as follows: blood pressure was 186/90 mm Hg, pulse was 94 beats per minute and regular, and respiratory rate was 20 per minute. His color was pale but not cyanotic. He had a vigorous gag reflex.

In the emergency department, the patient was noted to have a decreased level of consciousness (Glasgow Coma Scale score of 11). There was purposeful movement of the right arm. A dense left hemiparesis was noted along with flattening of the left nasolabial fold. A left Babinski was present.

A computed tomographic scan of the brain without contrast showed only diffuse atrophy (Figure, panel 1A). Arterial blood gas drawn while the patient received 40% supplemental oxygen by mask showed the following: pH, 7.38; PCO₂, 38; and PO₂, 176. The chest roentgenogram revealed a left lower lobe consolidation and a small left pleural effusion, which resolved by the next day.

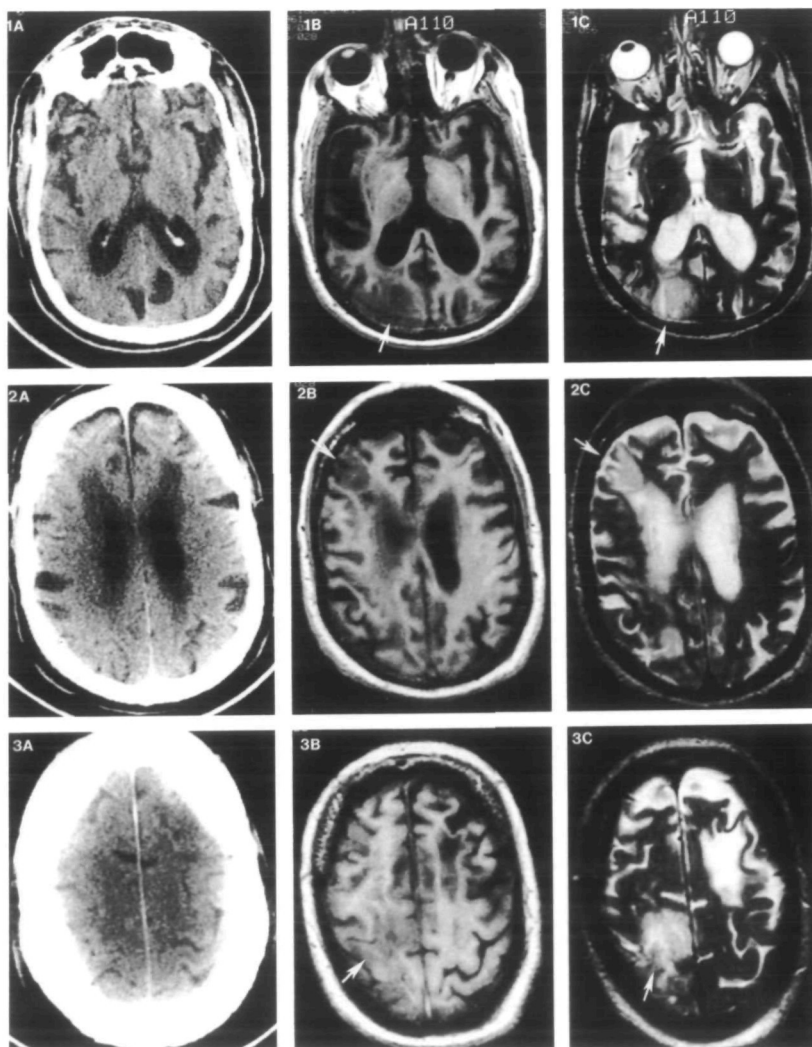
On the fifth hospital day, a cranial magnetic resonance imaging scan showed multiple, bilateral areas of infarction (Figure, panels 1B and 1C). On the right there were distinct areas of infarction in the frontal, posterior parietal, and occipital regions. There were multiple right cerebellar infarcts. On the left there was a single frontal infarct. The absence of a flow void in the left supraclinoid carotid artery and findings of a limited magnetic resonance angiogram were consistent with left carotid artery occlusion. This finding was confirmed by Doppler ultrasound studies.

The patient showed initial improvement in the level of consciousness during the first 5 days; however, severe neurological deficits remained. These deficits showed good clinical correlation with the magnetic resonance findings (Figure, panels 1B and 1C). At the time of discharge on the 14th hospital day, he was able to answer

Received September 22, 1993; final revision received January 24, 1994; accepted January 31, 1994.

From the Departments of Neurology (S.J.S., W.A.S.) and Surgery (L.V.B.), University of Arizona, Health Sciences Center, Tucson, Ariz.

Correspondence to Scott J. Sherman, MD, PhD, Department of Neurology, University of Arizona, Health Sciences Center, Tucson, AZ 85724.



Axial T₁-weighted (1B, 2B, 3B) and T₂-weighted (1C, 2C, 3C) magnetic resonance imaging sequences were obtained on the fifth hospital day. These are compared with analogous images (1A, 2A, 3A) of a computed tomographic scan obtained on admission, which serve as a baseline study. The initial computed tomographic scan was obtained too soon to reflect acute ischemic changes but does effectively rule out the possibility that the cortical infarcts were present before the ingestion of hydrogen peroxide. Acute infarcts (arrows) are present in the territories of the posterior (1B, 1C), middle (2B, 2C), and anterior (3B, 3C) cerebral arteries. Additional areas of infarction (not shown in these sequences) were present, as discussed in the text.

simple questions appropriately. The left arm and leg continued to show a paresis consistent with an upper motor neuron lesion. There was a prominent grasp reflex on the right. There were signs of cerebellar dysfunction on the right as manifested by ataxia of the arm and inability to perform rapid alternating movements.

Discussion

This case report illustrates an unusual toxicity of a commercially available compound. Thirty milliliters of 35% hydrogen peroxide when fully decomposed into reaction products will produce 3.5 L of oxygen gas.² Multiple cerebral infarctions occurring immediately after the ingestion of this solution were probably due to oxygen gas embolism.

Several pathophysiological mechanisms could ultimately lead to cerebral damage after ingestion of hydrogen peroxide. The initial foaming reaction produced as the hydrogen peroxide is ingested could lead to laryngospasm, bronchospasm, and pulmonary aspiration. The ensuing hypoxemia could lead to central nervous system damage directly or could cause cardiopulmonary arrest with subsequent cerebral anoxia. This mechanism is likely to have occurred in at least two of the previous case reports.^{3,4}

Undissociated hydrogen peroxide remaining in the stomach would be readily absorbed through the mucosa and enter into the portal venous system. Once the hydrogen peroxide reached the mesenteric blood, it would begin to undergo rapid gaseous dissociation because of the high concentration of the enzyme catalase present in erythrocytes.⁵ The presence of gas in the portal venous system has been documented after hydrogen peroxide ingestion.⁶ Embolization could then proceed to involve the vena cava, right heart chambers, and the pulmonary arterial tree. One clinical report demonstrated the presence of massive amounts of gas in the right side of the heart after ingestion of hydrogen peroxide.⁷

Arterial gas embolization may occur by at least three mechanisms. Gas bubbles that have formed in the venous system can travel from the right atrium to the left atrium via a patent foramen ovale. Some of the hydrogen peroxide dissolved in venous blood could remain undissociated until crossing the pulmonary capillary bed and then undergo catalysis in the arterial circulation. Finally, pulmonary aspiration of hydrogen peroxide could lead to direct embolization of the arterial system after absorption from the pulmonary capillaries.

The case presented here is most consistent with neurological damage due to gas embolization of the

cerebral vasculature. The patient did not present with initial circulatory collapse, as described in several previous reports of serious hydrogen peroxide poisoning.^{3,4,7} Rather, there was rapid onset of focal neurological deficits occurring in the setting of adequate arterial pressure, pulse rate, and oxygen saturation. As shown in the Figure, the right hemisphere sustained infarcts in the territories of the anterior, middle, and posterior cerebral arteries. In addition, there were left frontal and multiple right cerebellar infarcts. This pattern of damage is most consistent with arterial gas embolization. The relative sparing of the left hemisphere is also consistent with gas embolization. The occluded left carotid artery may have had a protective effect because gas bubbles following the ascending blood flow would be less likely to enter a circuitous collateral circulation to the left hemisphere.

We believe that this report demonstrates that cerebral gas embolization is a potential consequence of the ingestion of hydrogen peroxide. Although to date there have been no reports of the use of hyperbaric therapy in the treatment of hydrogen peroxide toxicity, it is a well-accepted treatment for cerebral nitrogen gas em-

bolization caused by decompression sickness. Furthermore, even delayed hyperbaric therapy has been shown to reverse neurological deficits in cerebral air embolization.⁸ We therefore suggest that hyperbaric therapy be considered in a stabilized patient showing focal neurological deficits after the ingestion of hydrogen peroxide.

References

1. Dept of Health and Human Services. *Hyper-Oxygenation Therapy*. Rockville, Md: US Food and Drug Administration, Federal-States Relations; 1989.
2. Humberston CL, Dean BS, Krenzelok EP. Ingestion of 35% hydrogen peroxide. *Clin Toxicol*. 1990;28:95-100.
3. Zecevic D, Gasparec C. Death caused by hydrogen peroxide. *Z Rechstmed*. 1979;84:57-59.
4. Giusti GV. Fatal poisoning with hydrogen peroxide. *Forensic Sci*. 1973;2:99-100.
5. Beutler E. *Red Cell Metabolism: A Manual of Biochemical Methods*. 2nd ed. Orlando, Fla: Grune & Stratton, Inc; 1975:89-147.
6. Rackoff WR, Merton DF. Gas embolism after ingestion of hydrogen peroxide. *Pediatrics*. 1990;85:593-594.
7. Christensen DW, Faught WE, Black RE, Woodward GA, Otwell TD. Fatal oxygen embolization after hydrogen peroxide ingestion. *Crit Care Med*. 1991;20:543-544.
8. Armon C, Deschamps C, Adkinson C, Fealey RD, Orszulak TA. Hyperbaric treatment of cerebral air embolism sustained during an open-heart surgical procedure. *Mayo Clin Proc*. 1991;66:565-571.